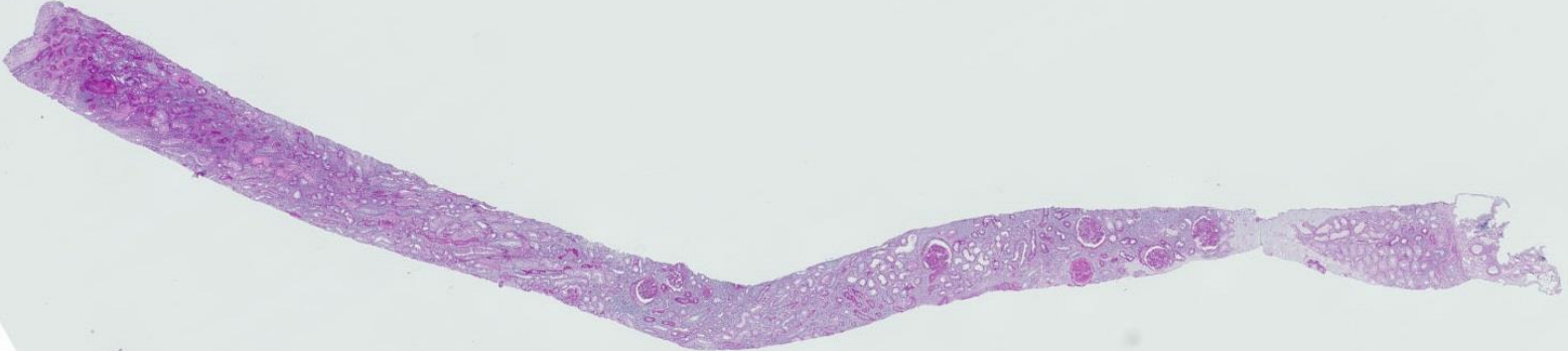
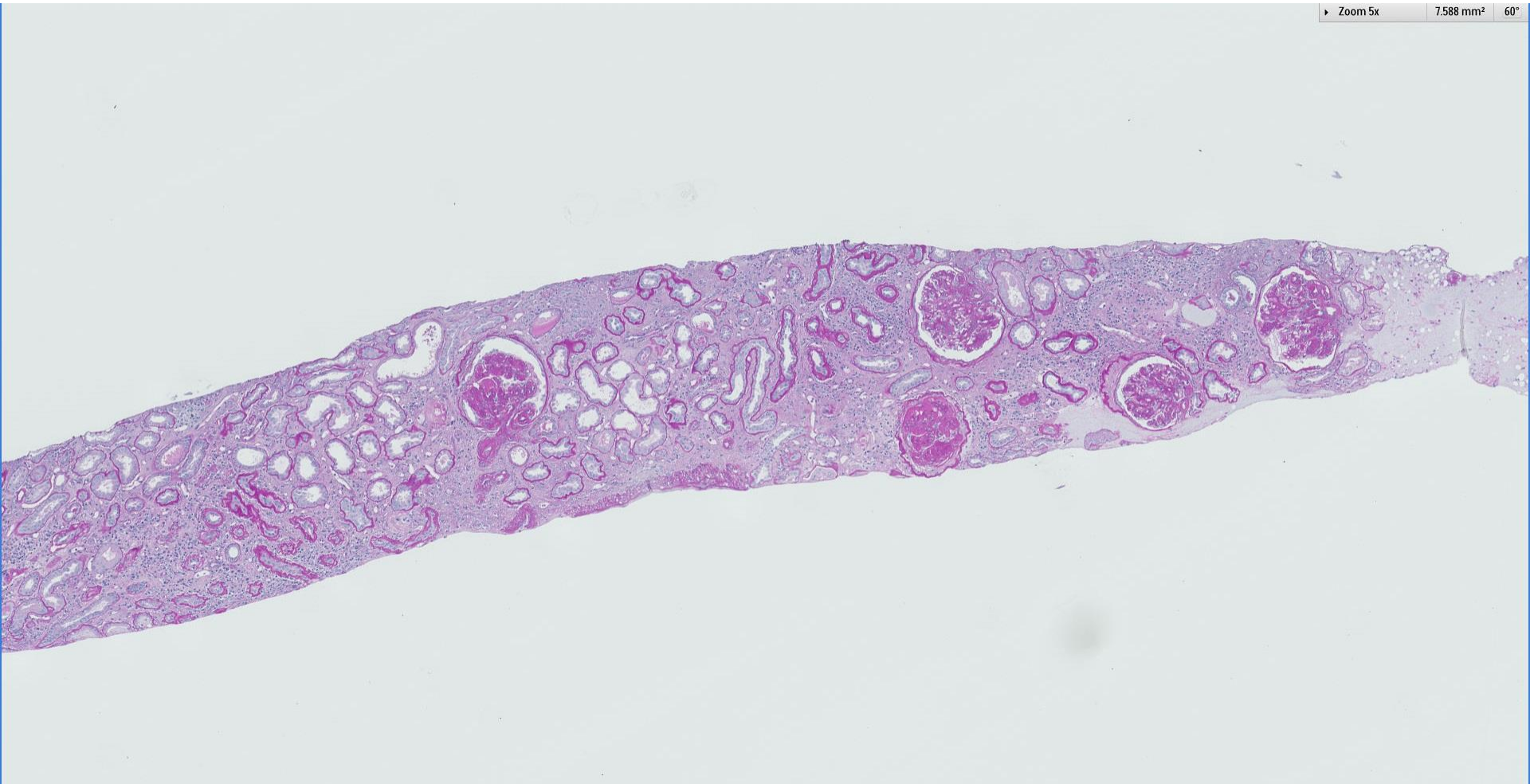


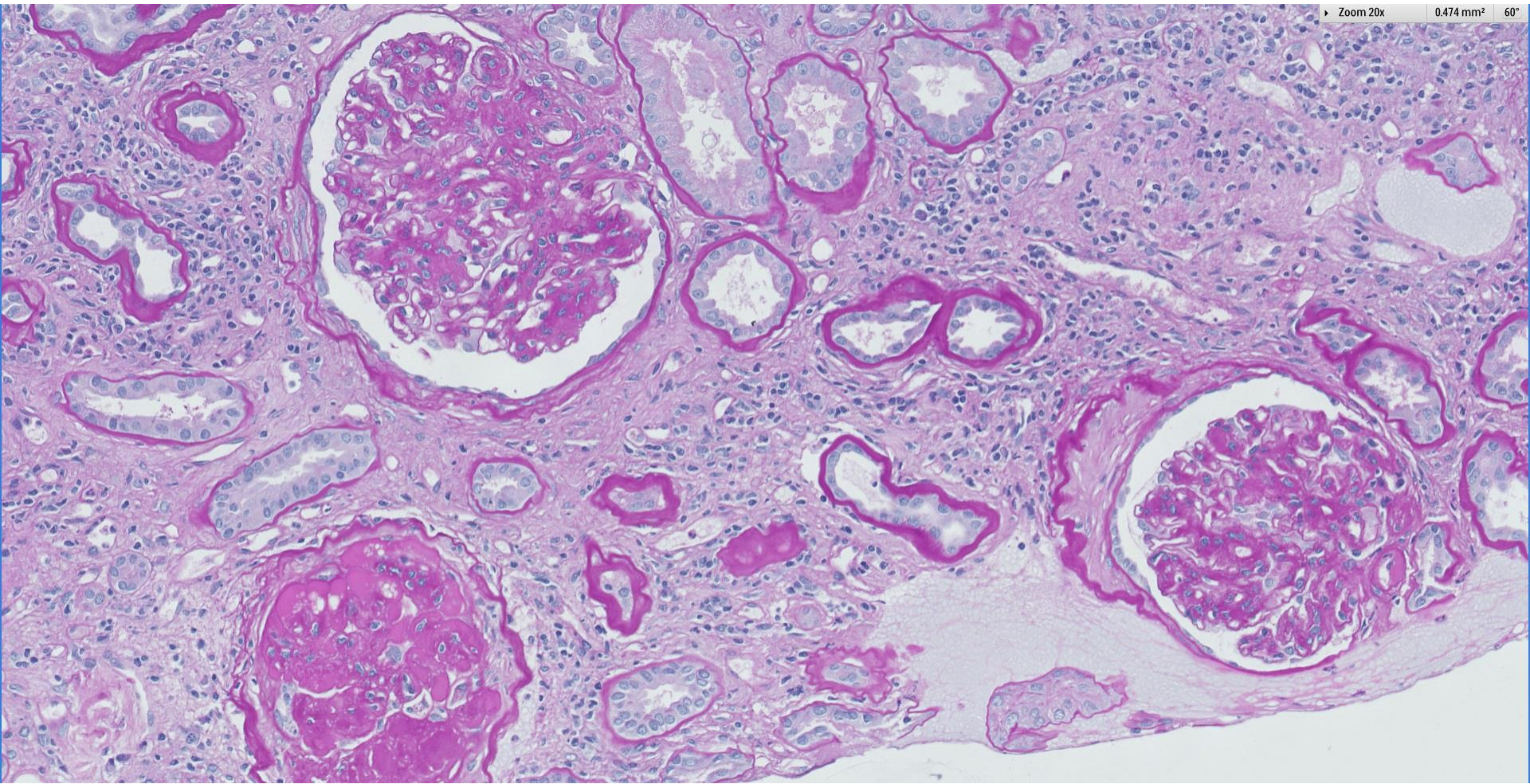
## Case 74

55 year old Chinese man, with history of diabetes and hypertension. Presented with worsening renal function associated with nephrotic range proteinuria and haematuria, with pyuria.





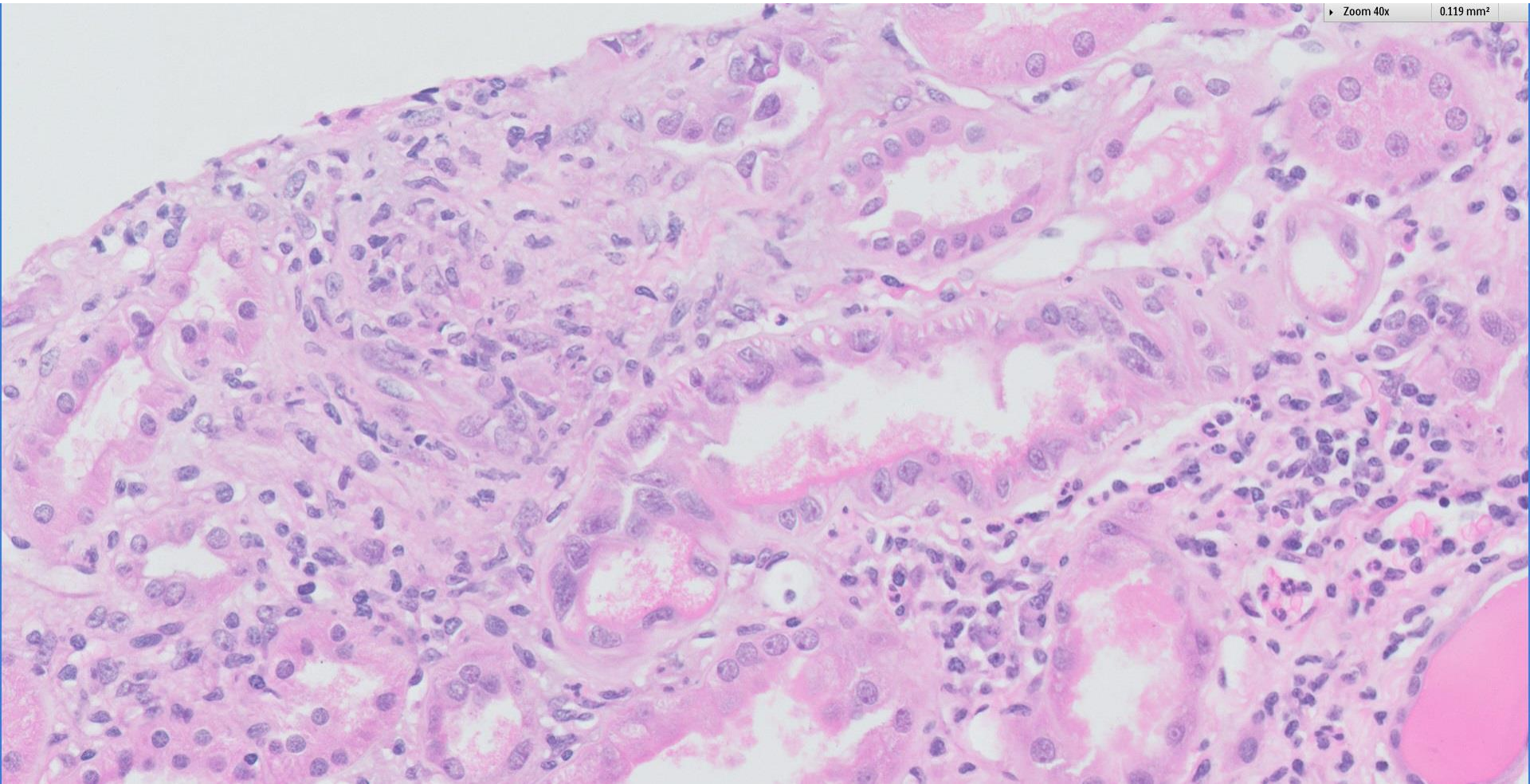






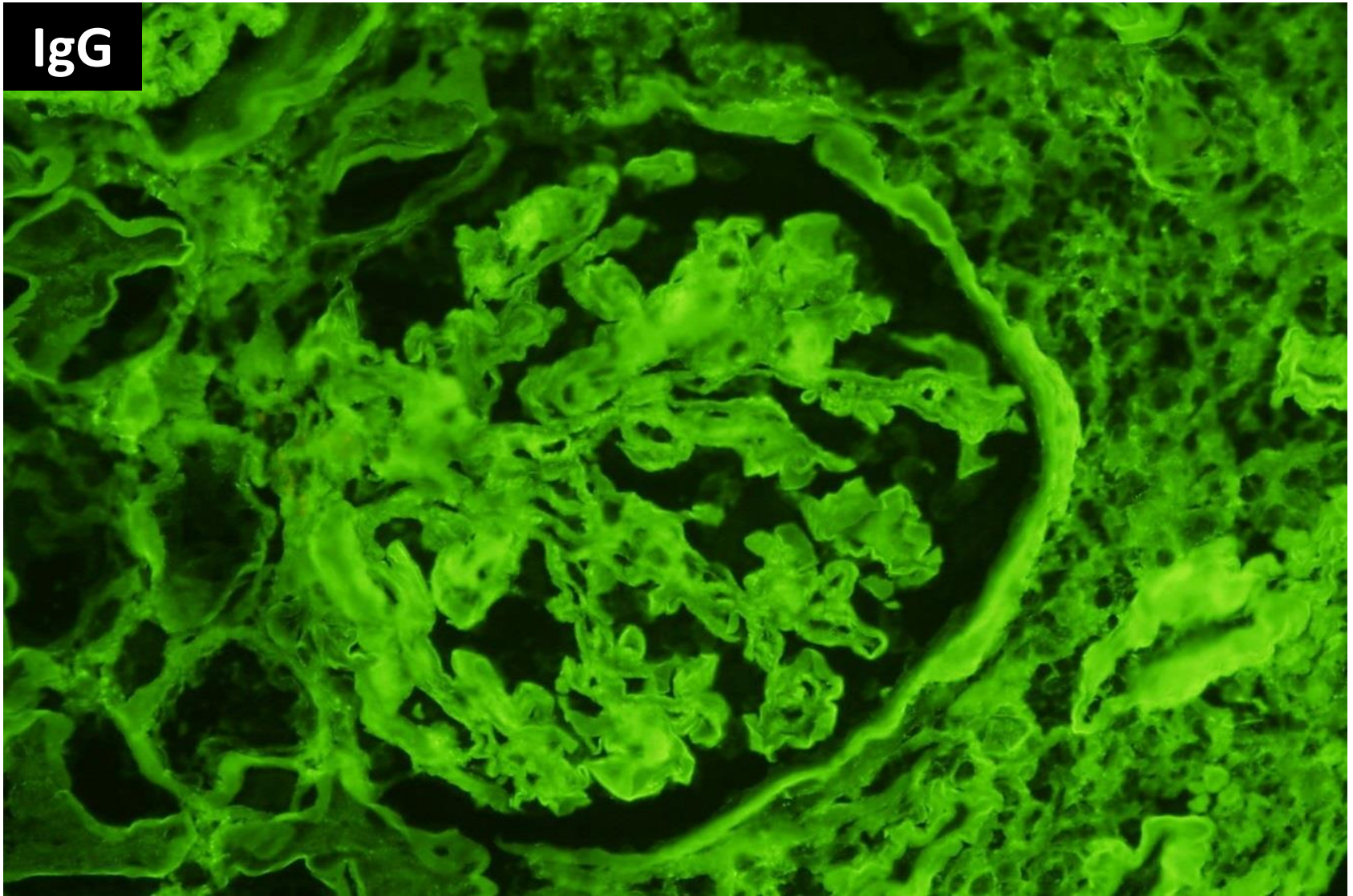
Zoom 40x

0.119 mm<sup>2</sup>

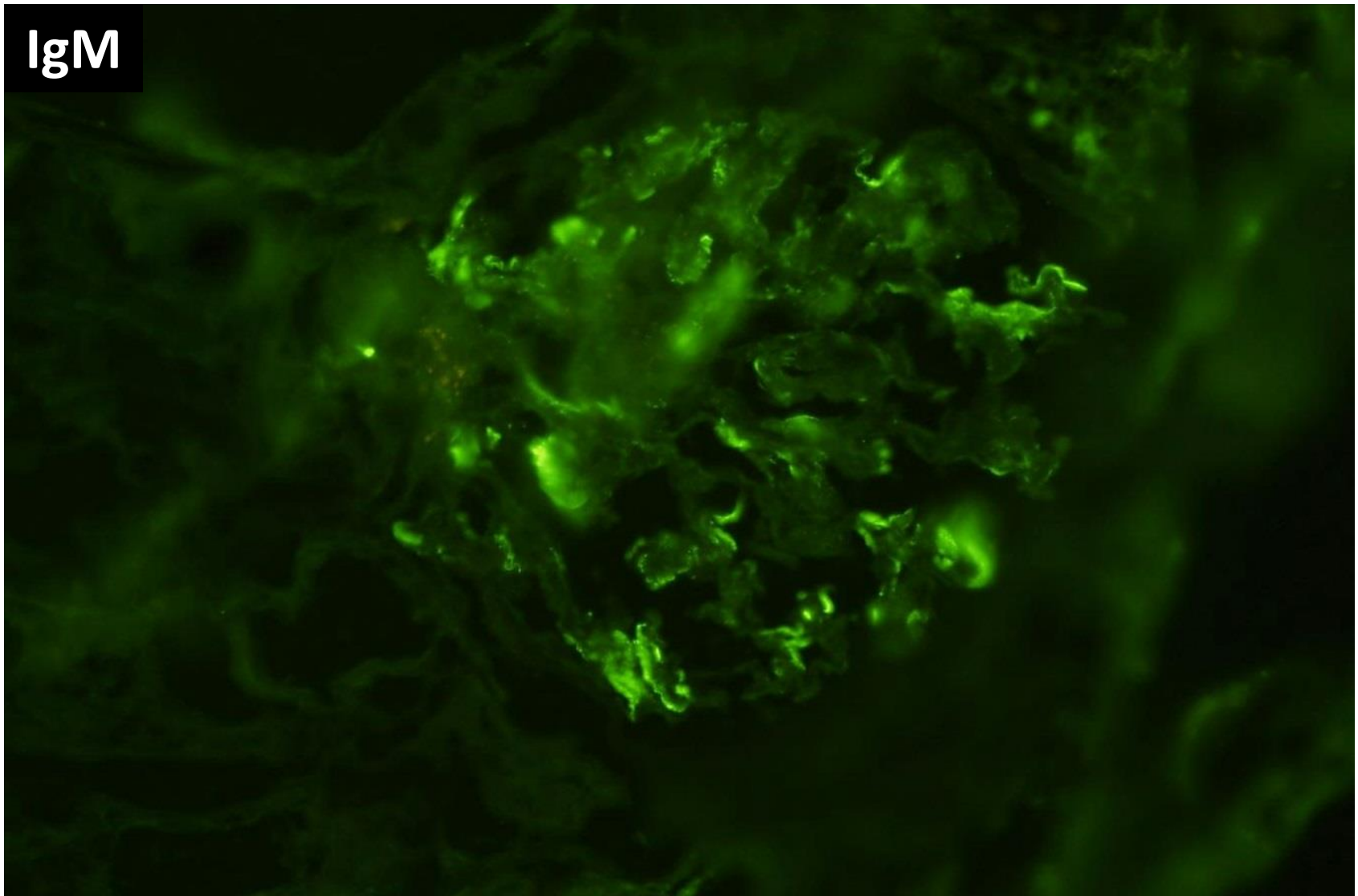




IgG

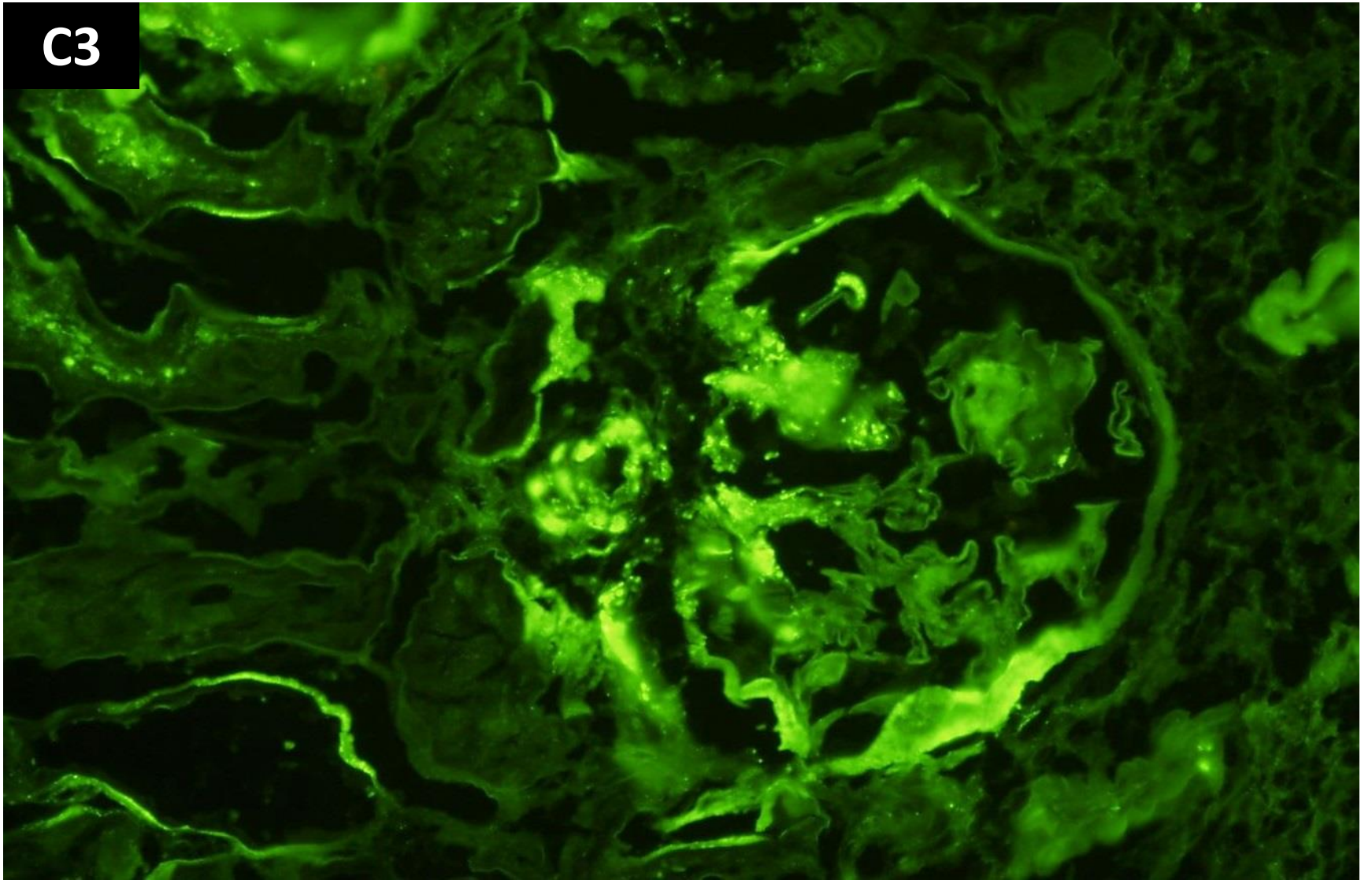


IgM

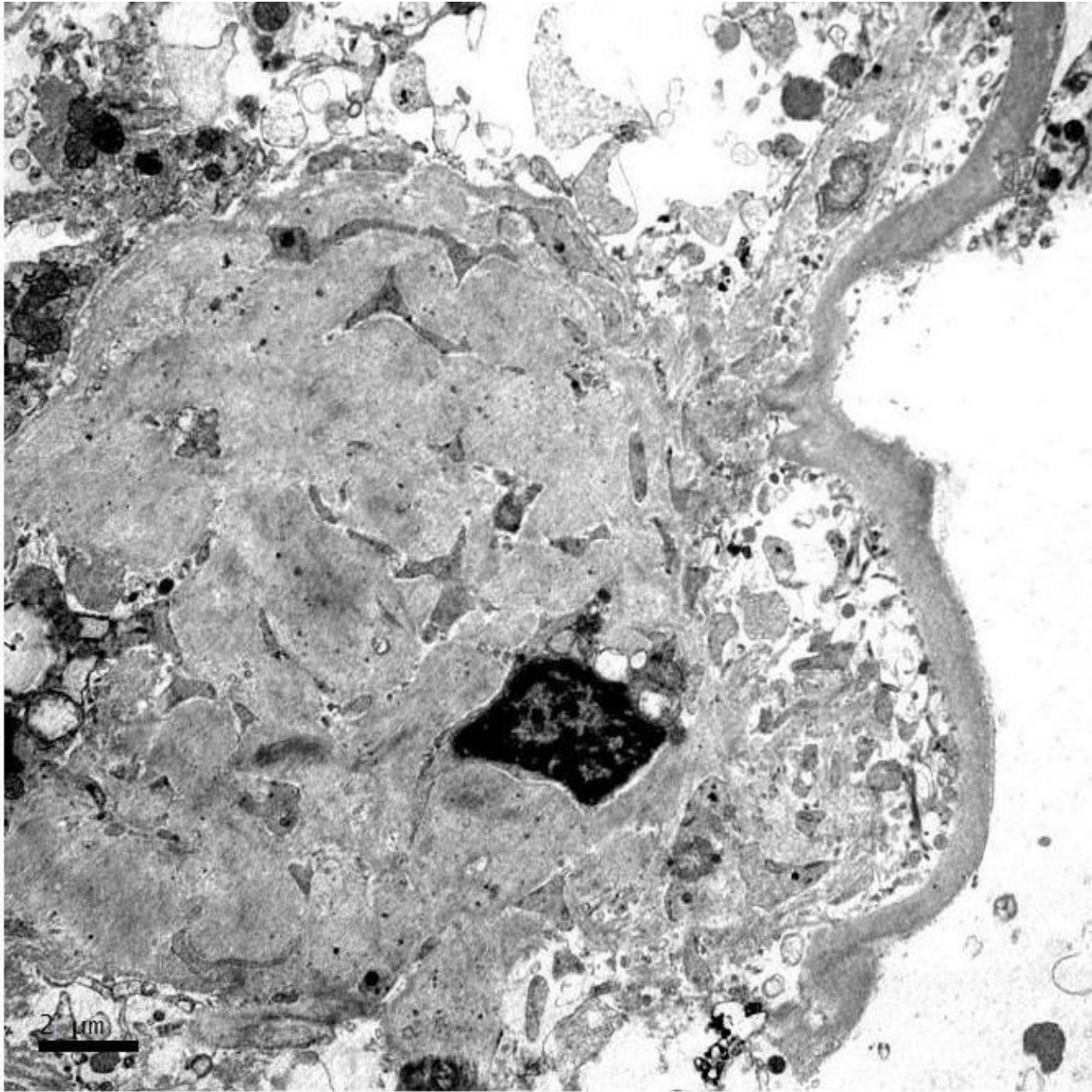


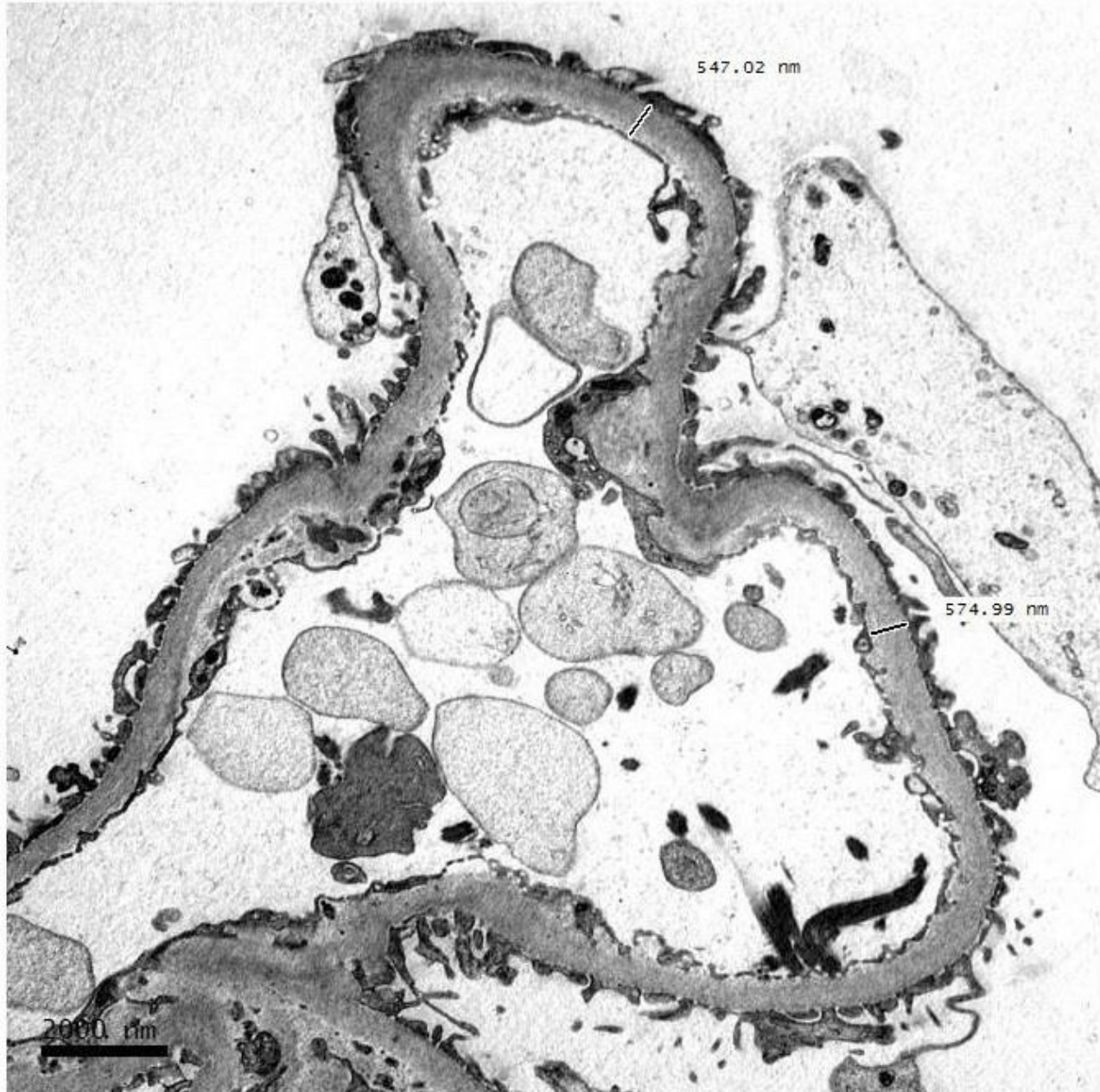

C3













# RENAL BIOPSY CLINICOPATHOLOGICAL WORKSHOP 2018



**PATHOLOGY**



Division of Pathology  
Singapore General Hospital



Department of Renal Medicine  
Singapore General Hospital



**MEDICINE**