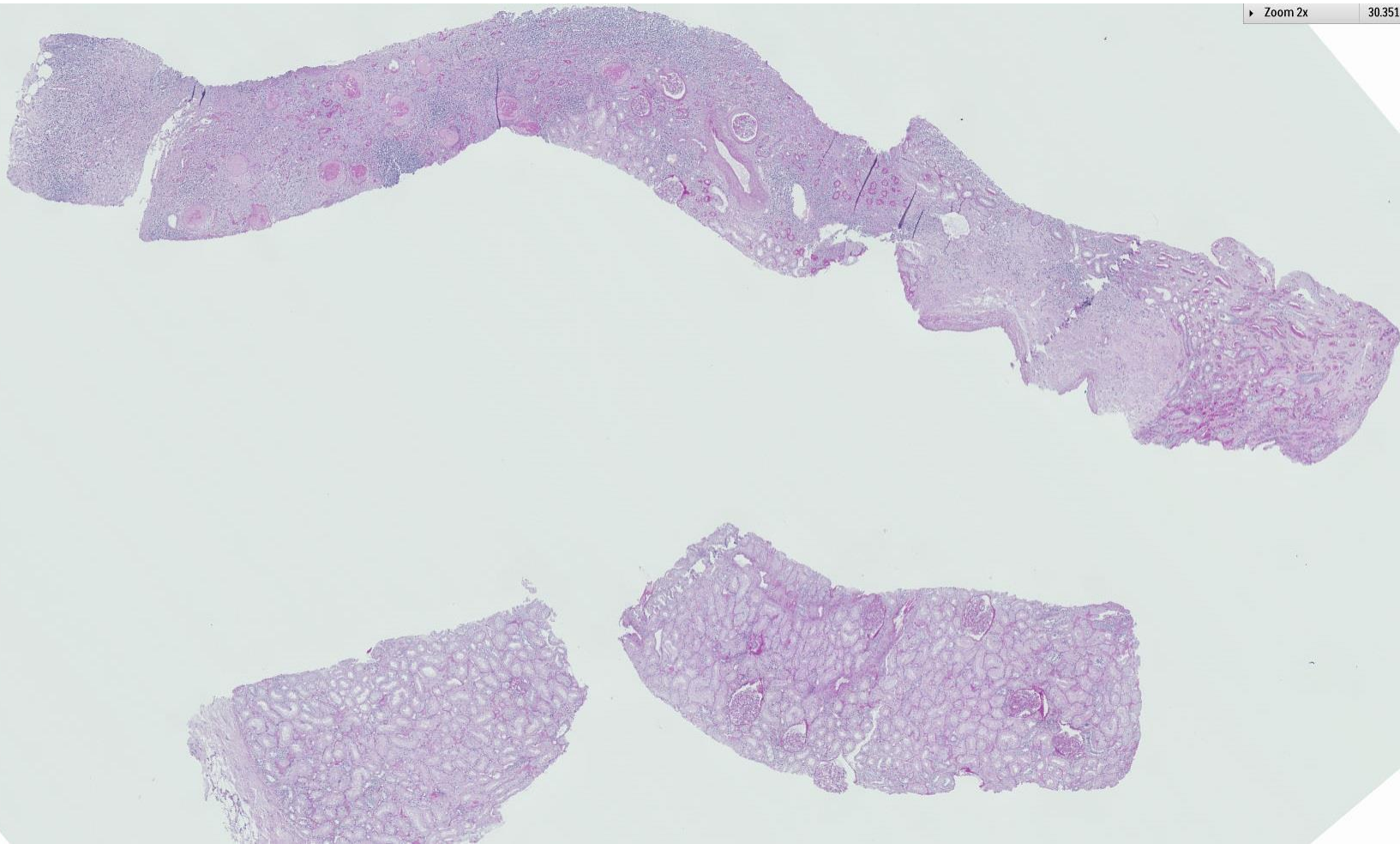
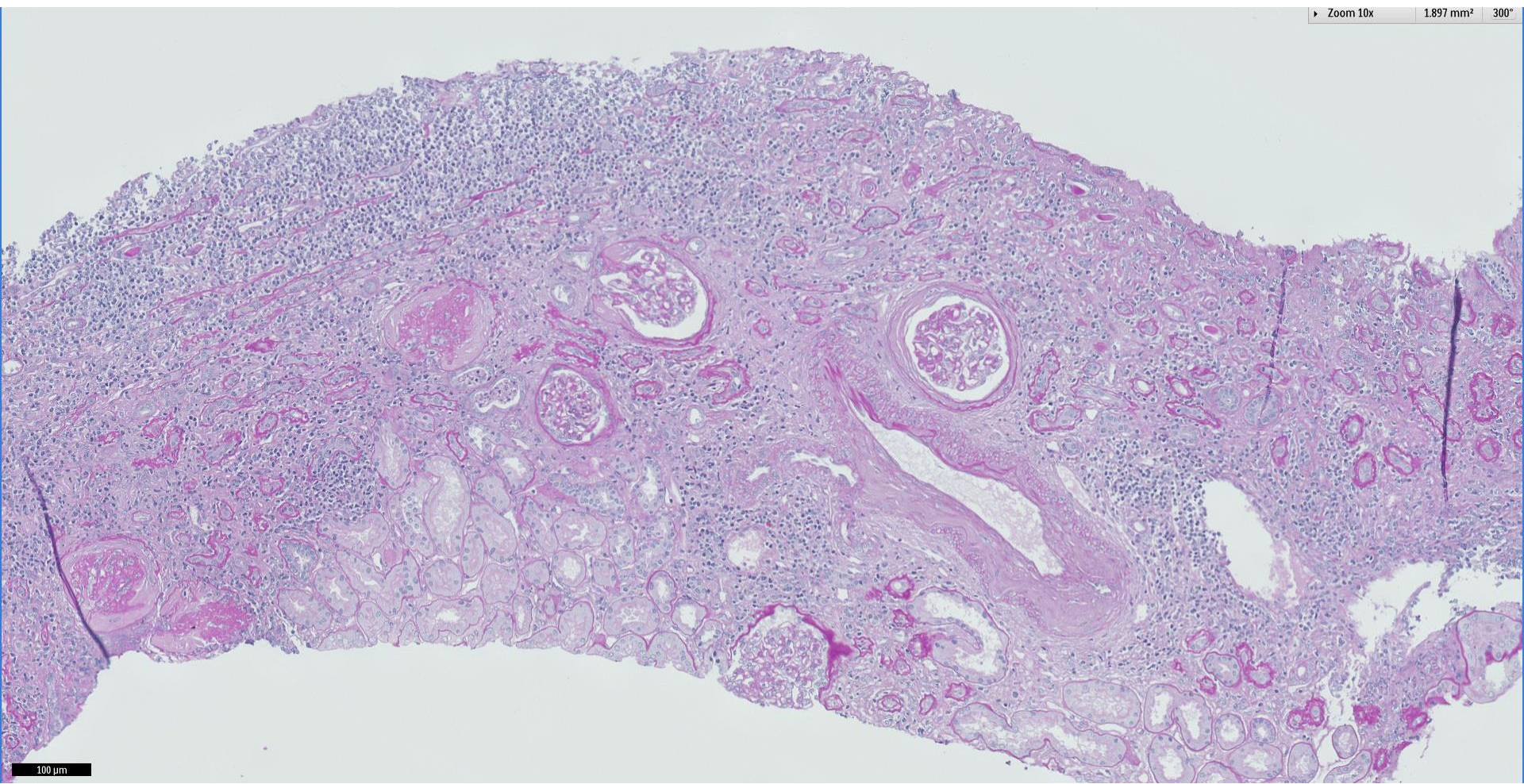


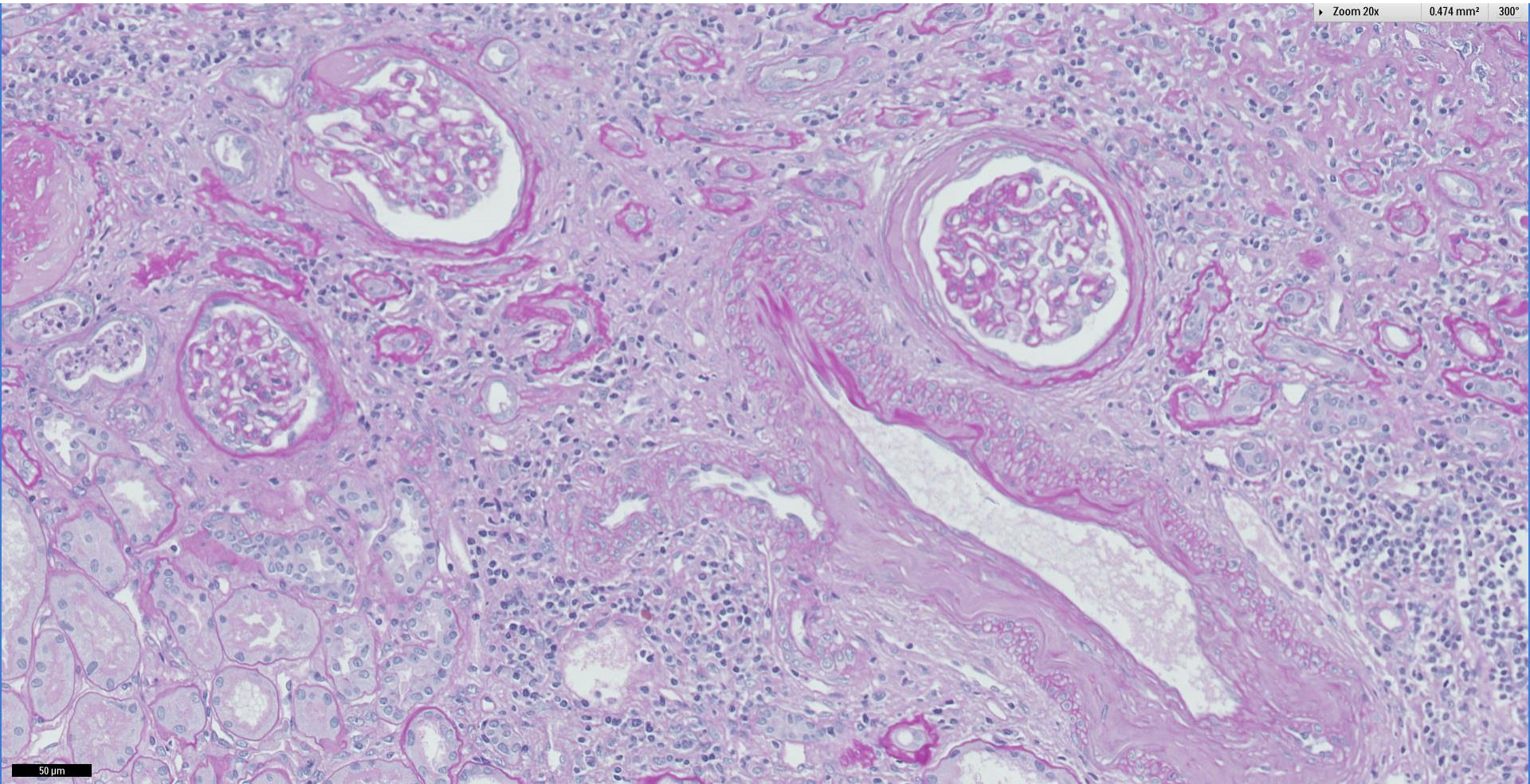
Case 67

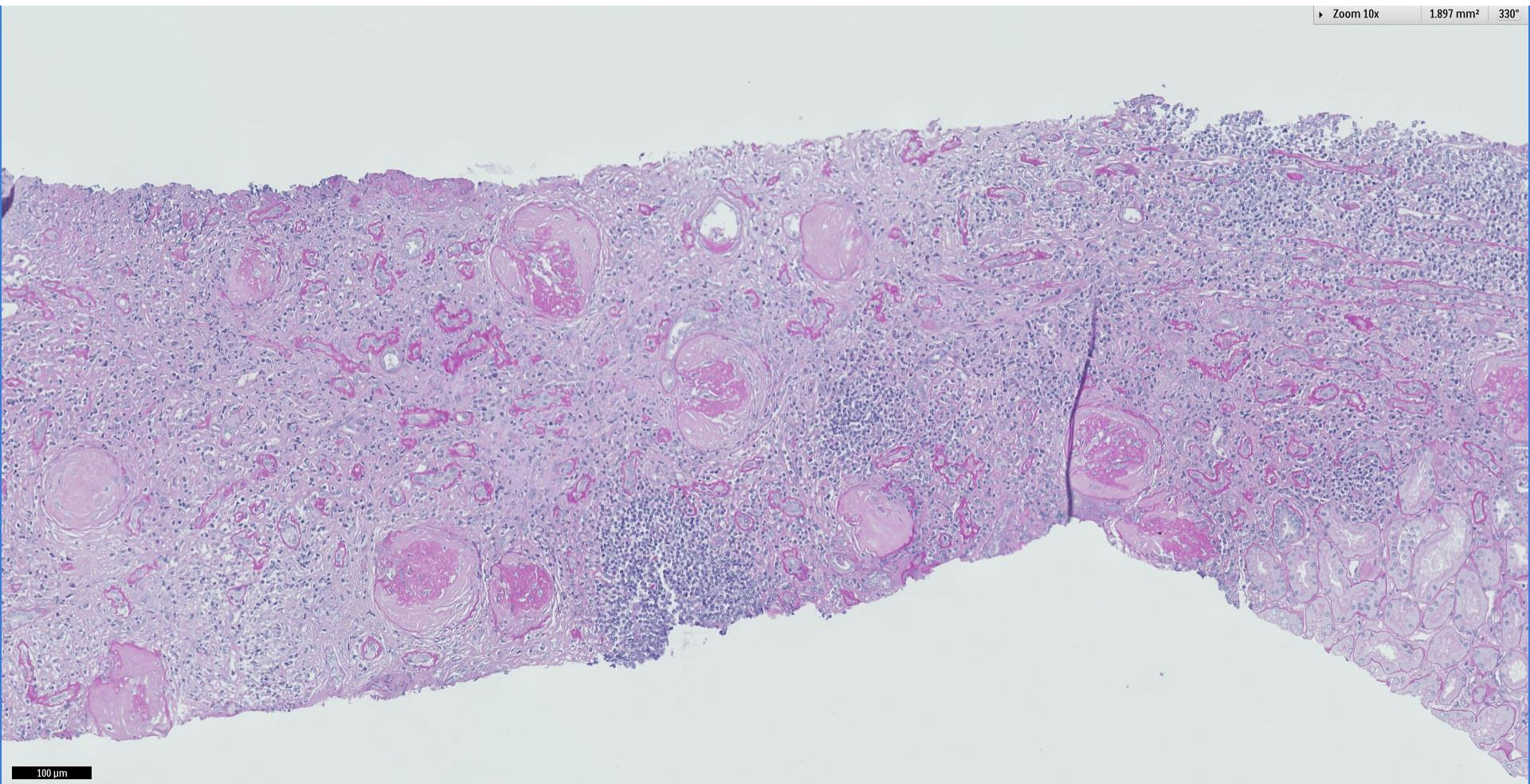
63 year old Chinese man, history of autoimmune pancreatitis. Underwent MRCP and found to have a wedge shaped hypodensity on the kidney, hence proceeded for kidney biopsy. Clinically there was mild AKI but no haematuria or proteinuria.



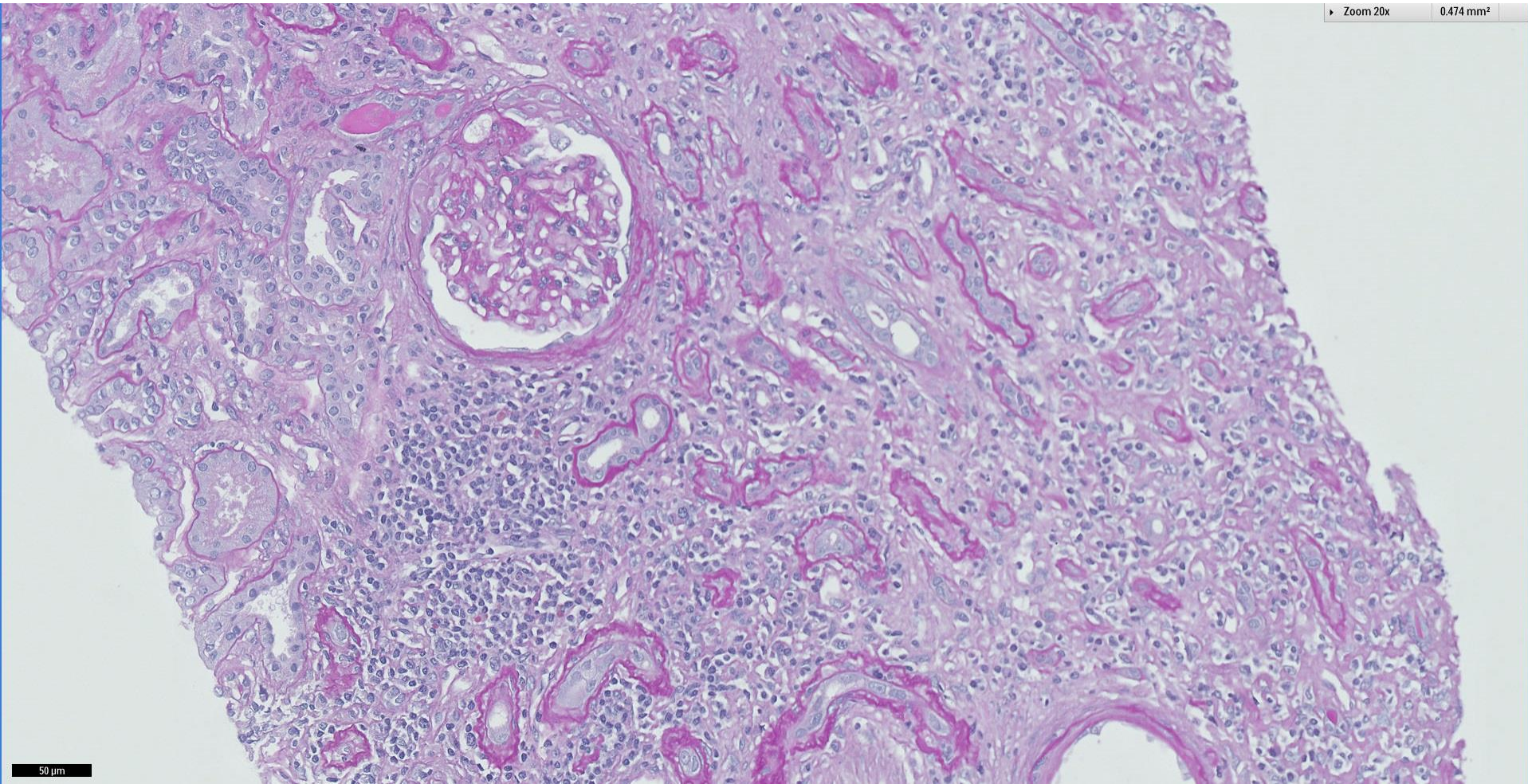


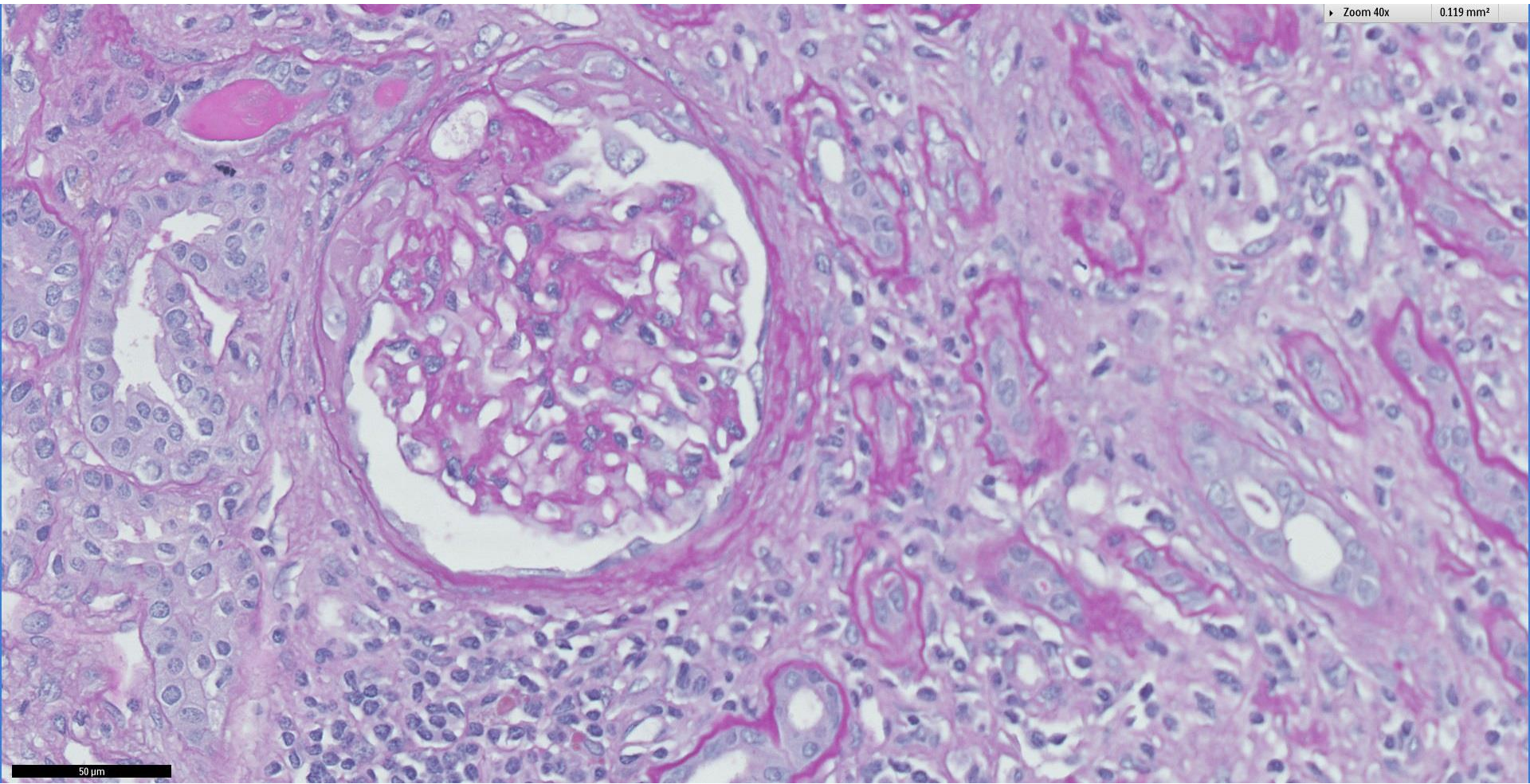
100 μm

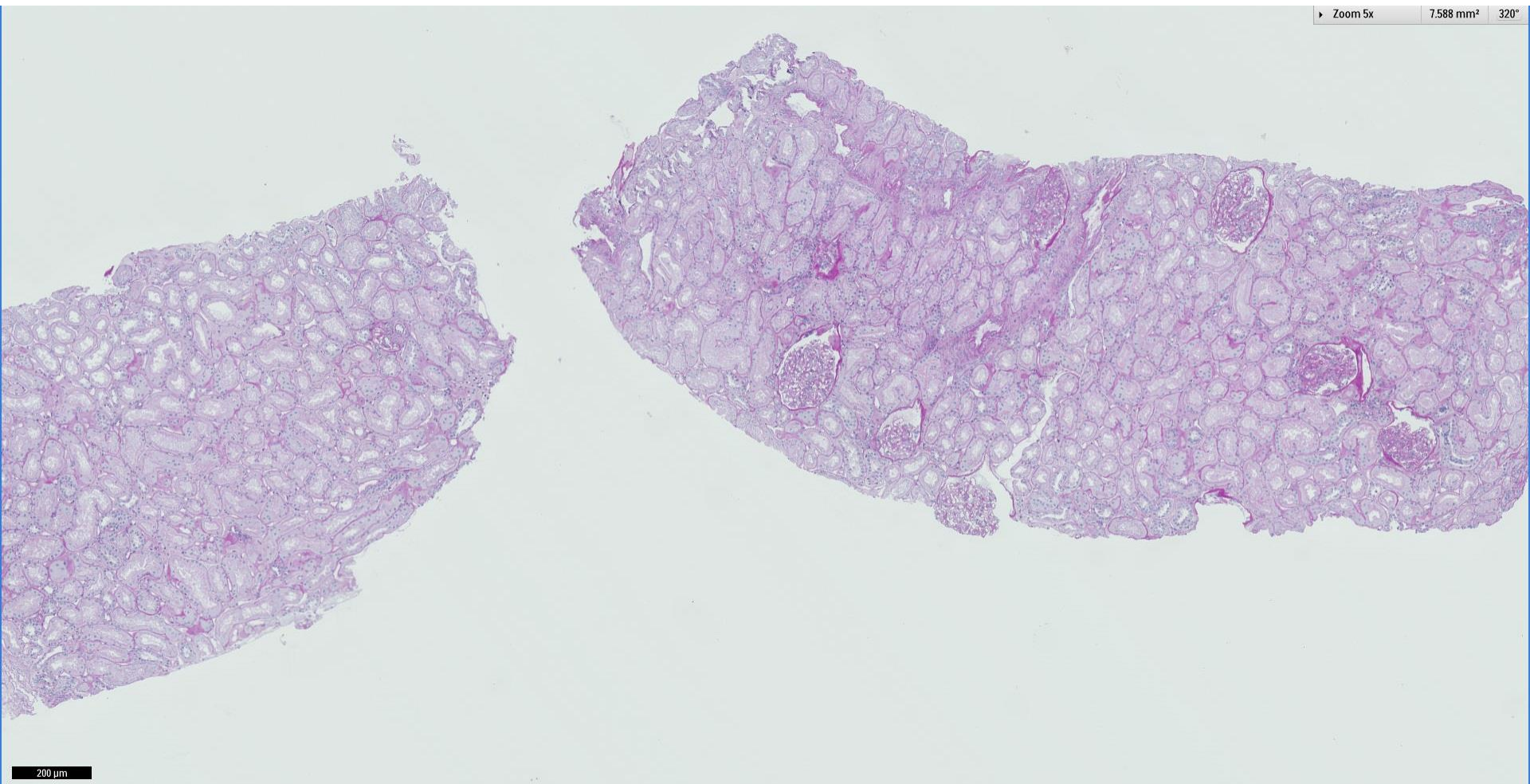




100 μ m



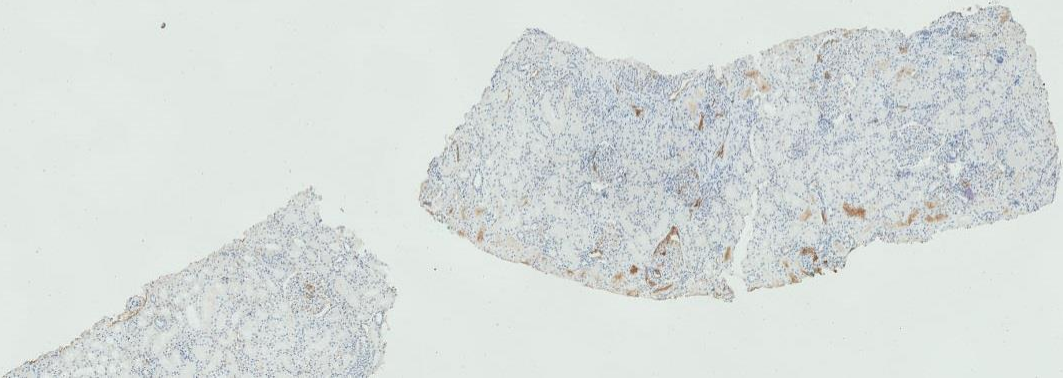
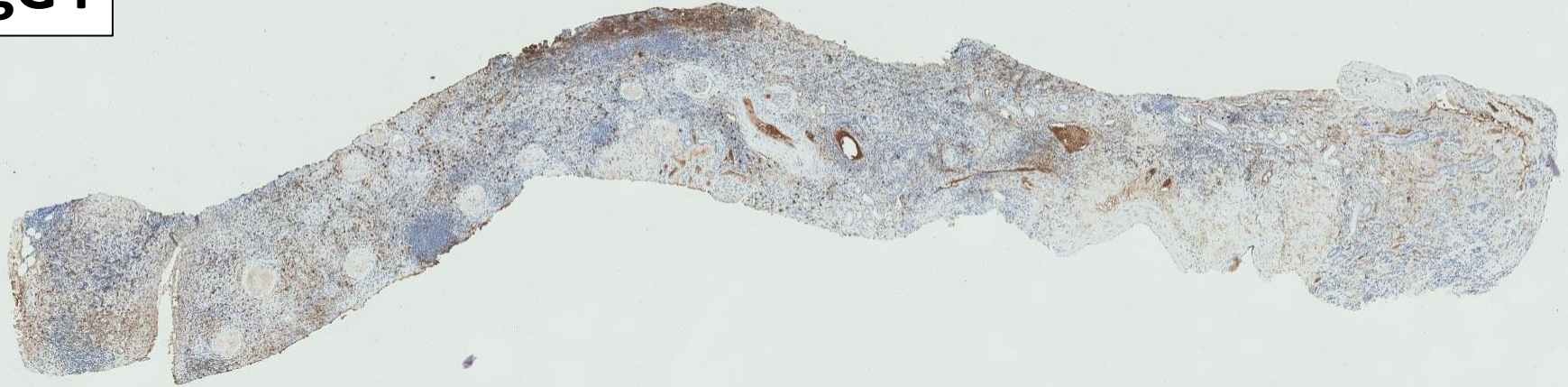



200 μ m

IgG4

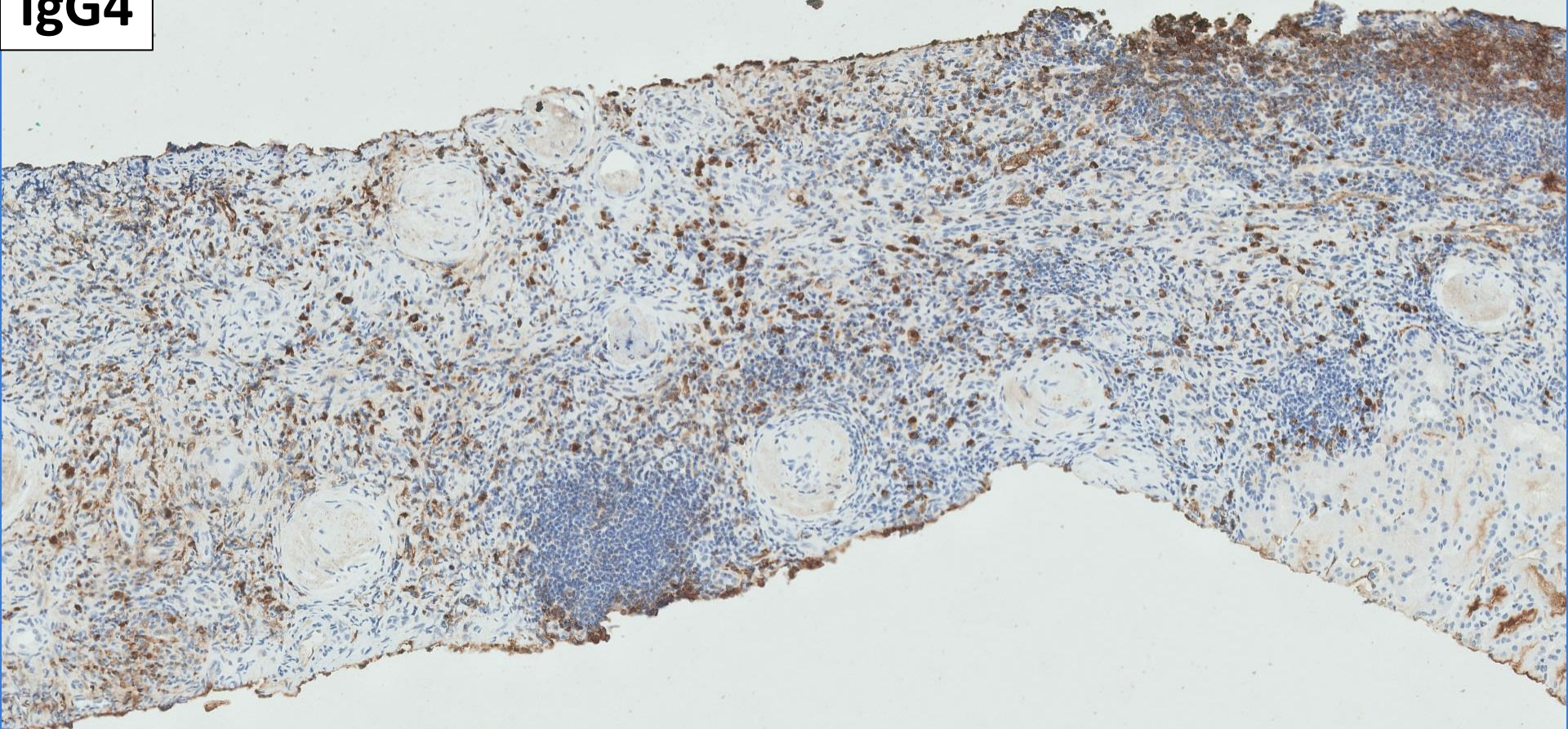
Zoom 2x 30.351 mm² 300°



500 μ m

IgG4

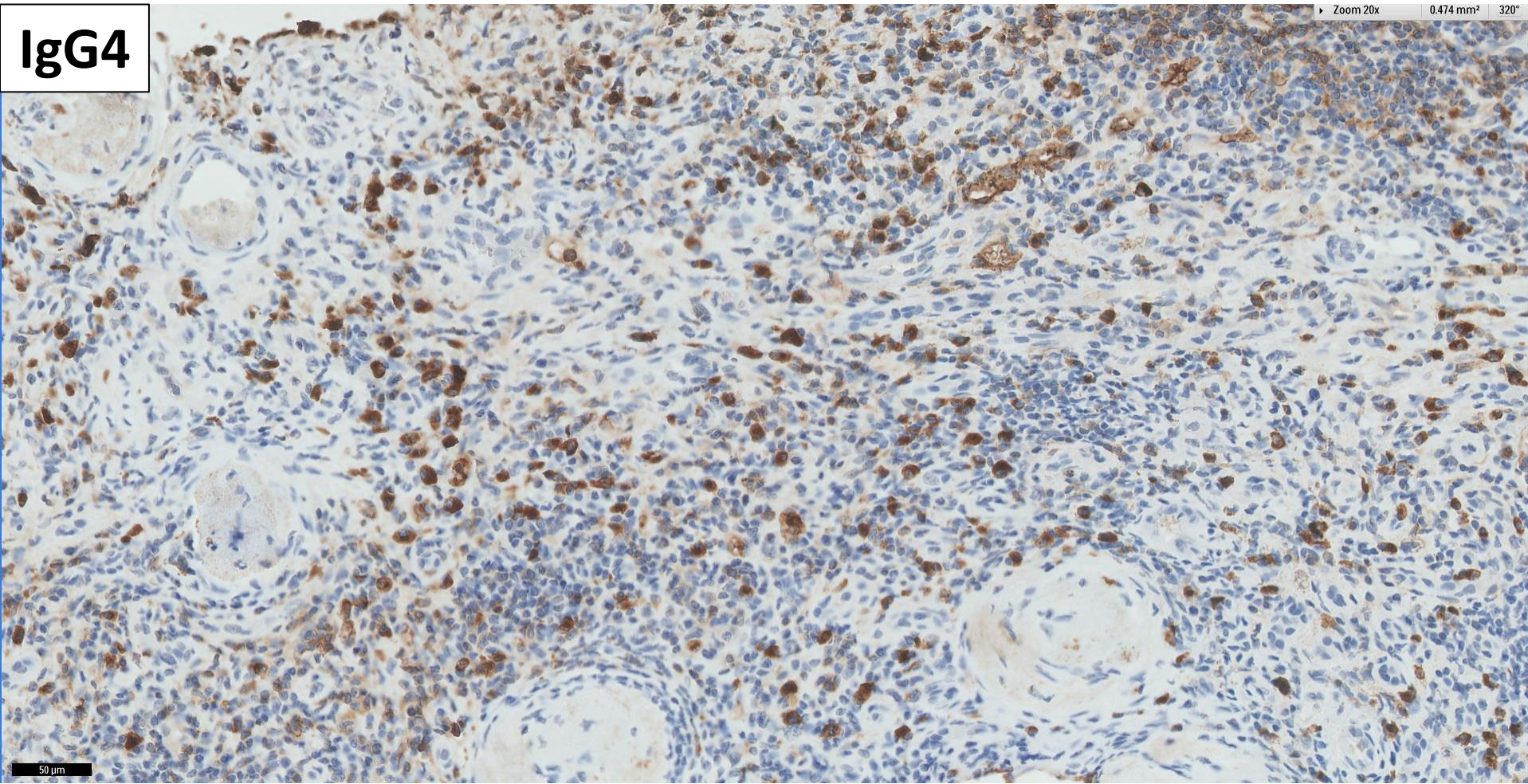
Zoom 10x 1.897 mm² 320°



100 µm

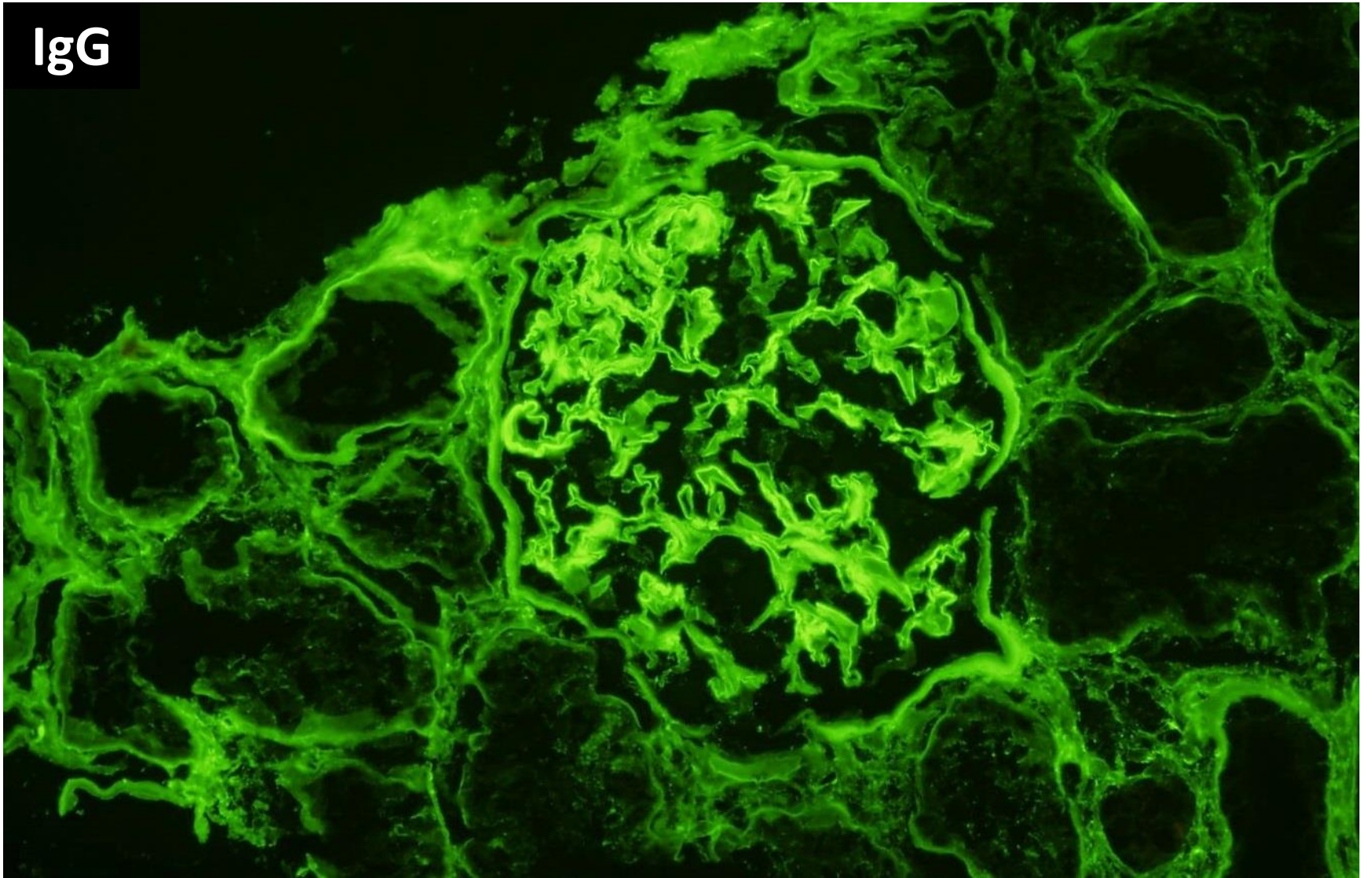
IgG4

Zoom 20x 0.474 mm² 320°

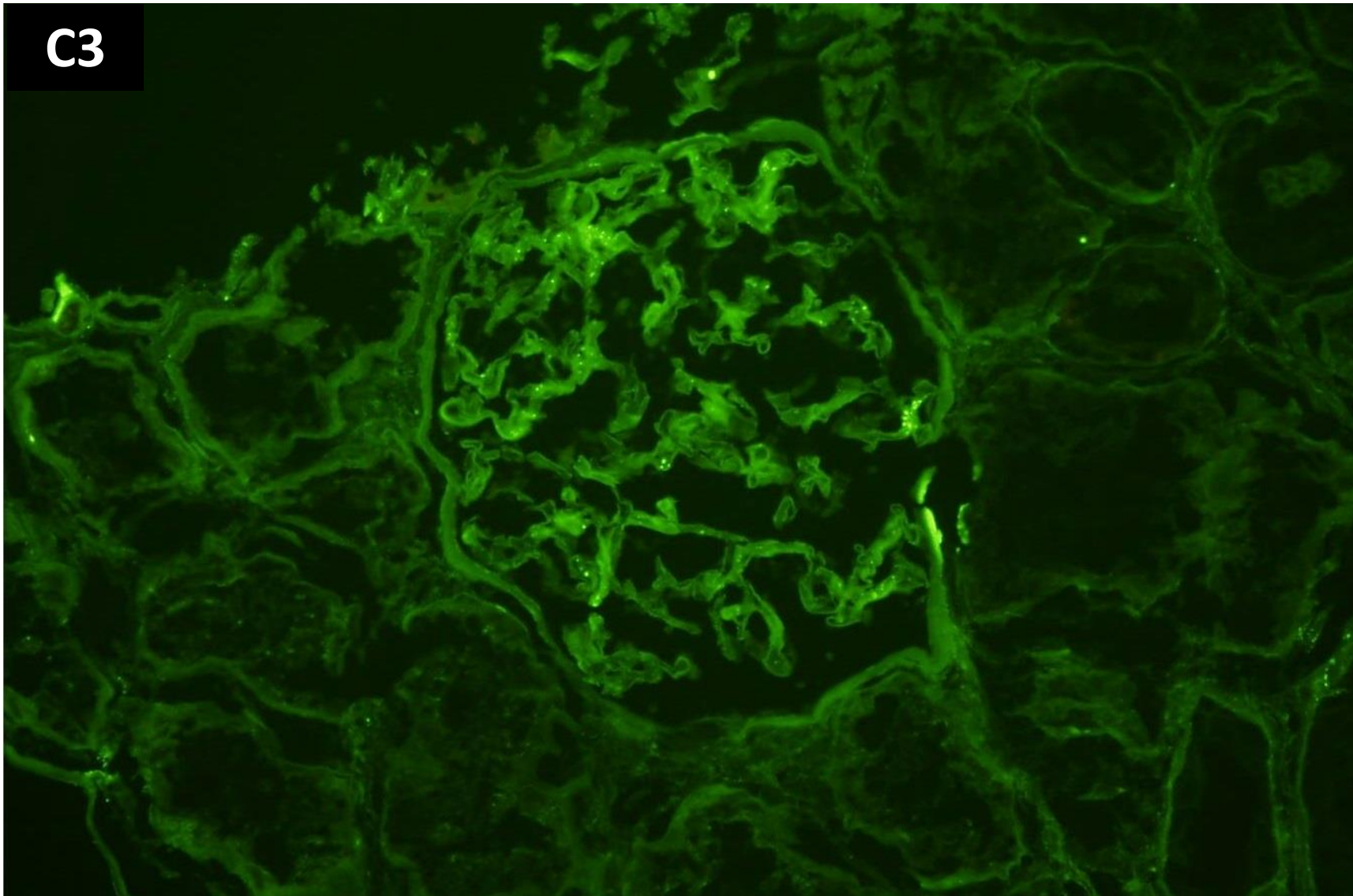


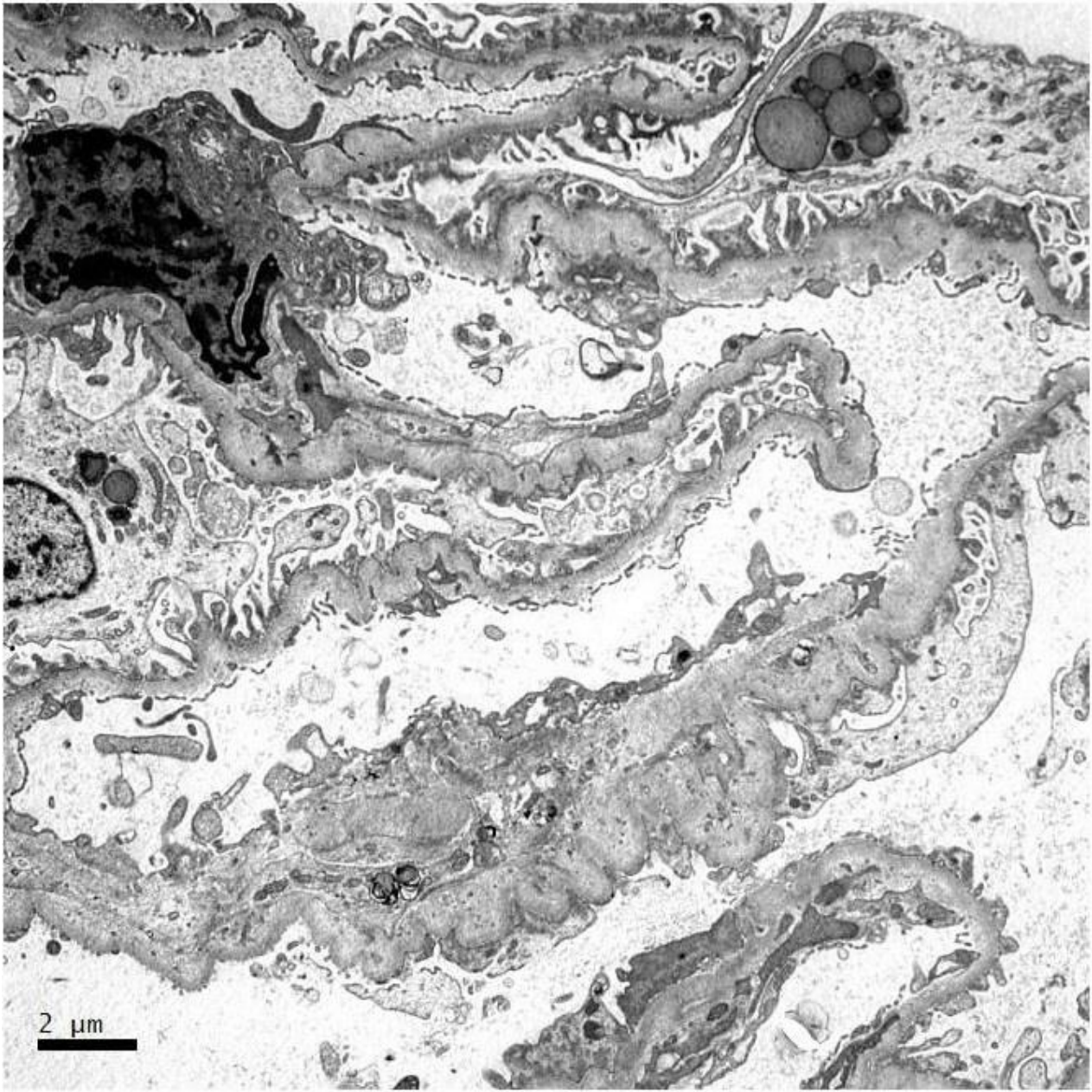
50 µm

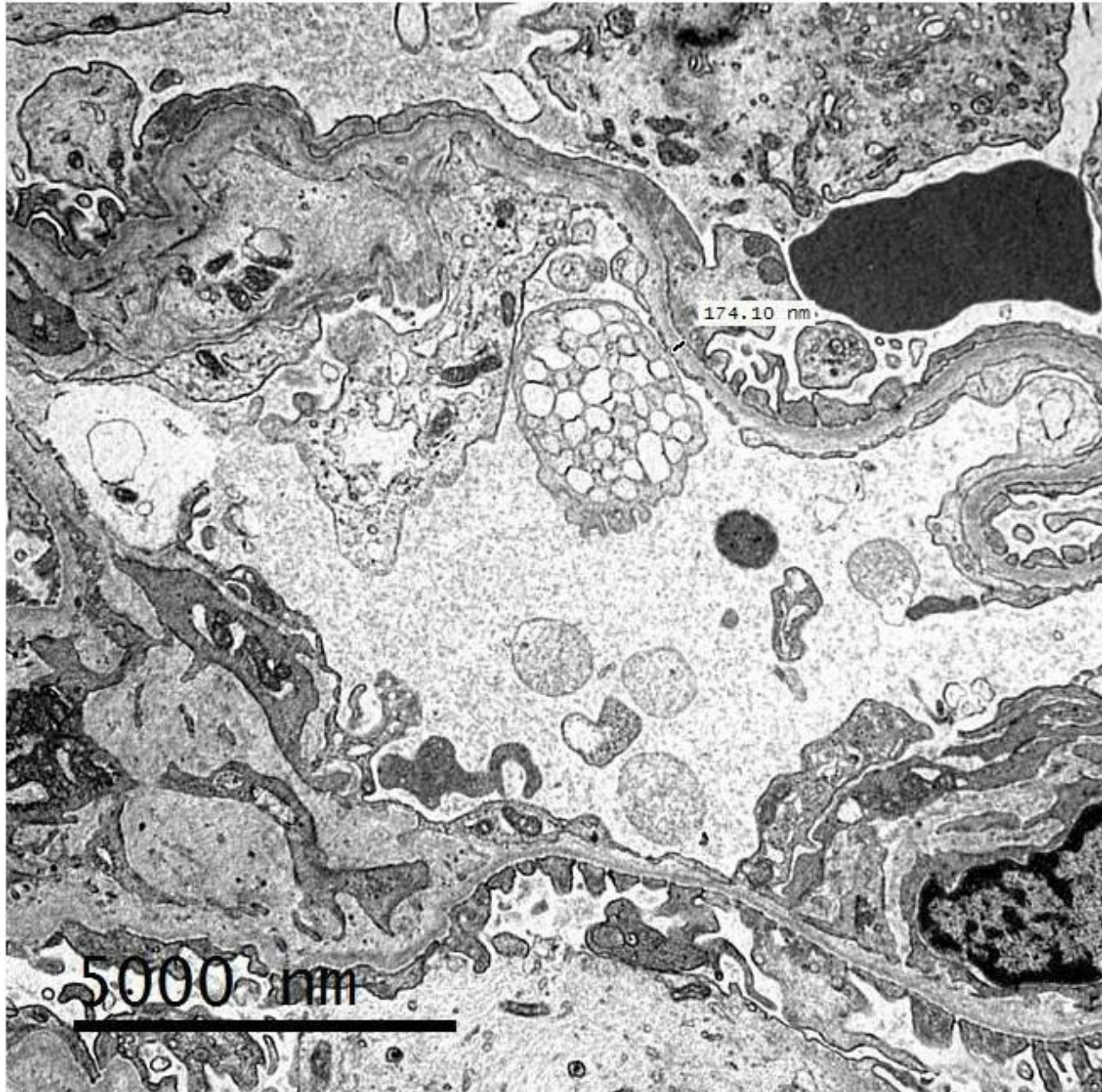
IgG



C3











**RENAL BIOPSY
CLINICOPATHOLOGICAL
WORKSHOP 2018**




SingHealth **DukeNUS**
ACADEMIC MEDICAL CENTRE
PATHOLOGY

 **Division of Pathology**
Singapore General Hospital

 **Department of Renal Medicine**
Singapore General Hospital


SingHealth **DukeNUS**
ACADEMIC MEDICAL CENTRE
MEDICINE