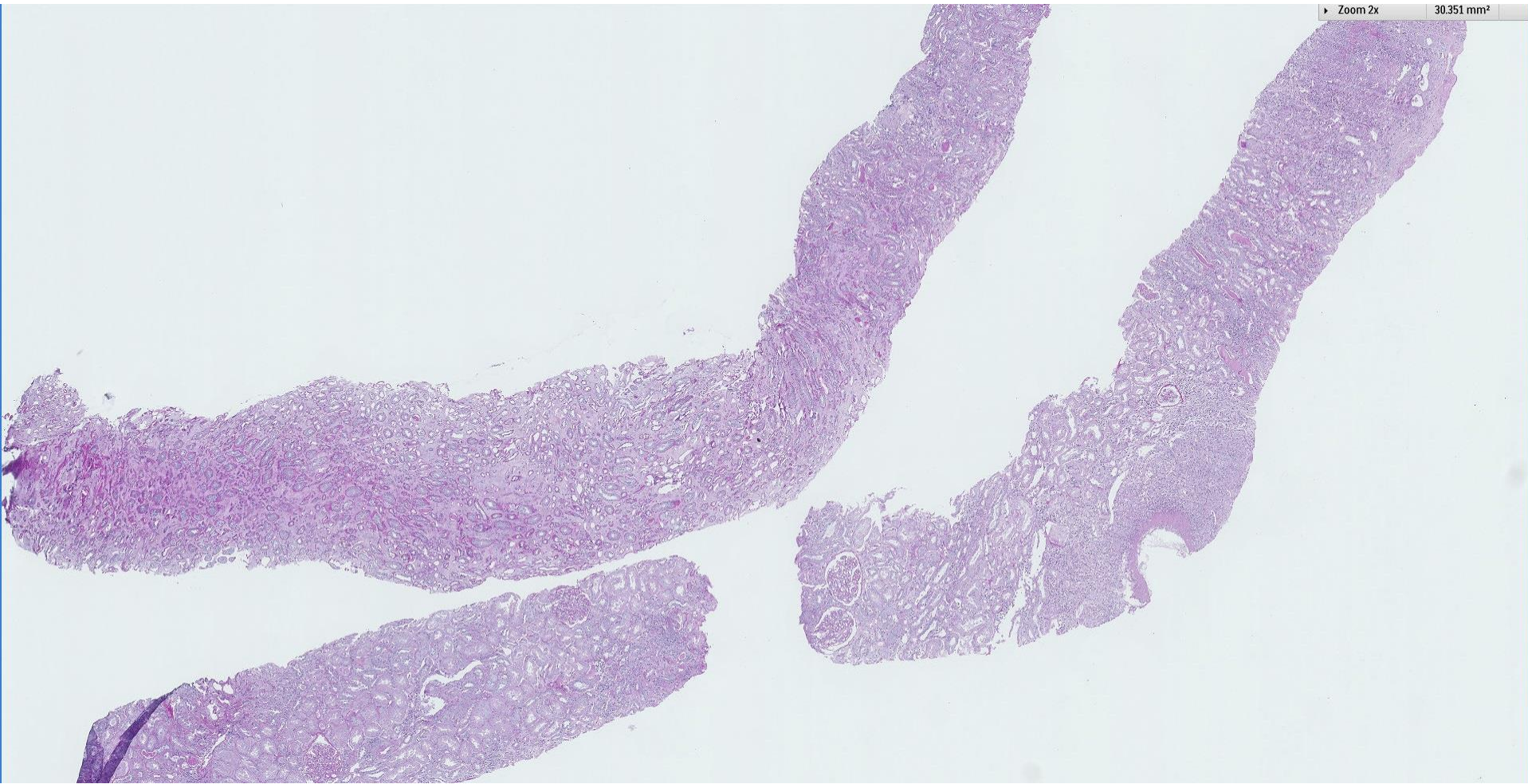
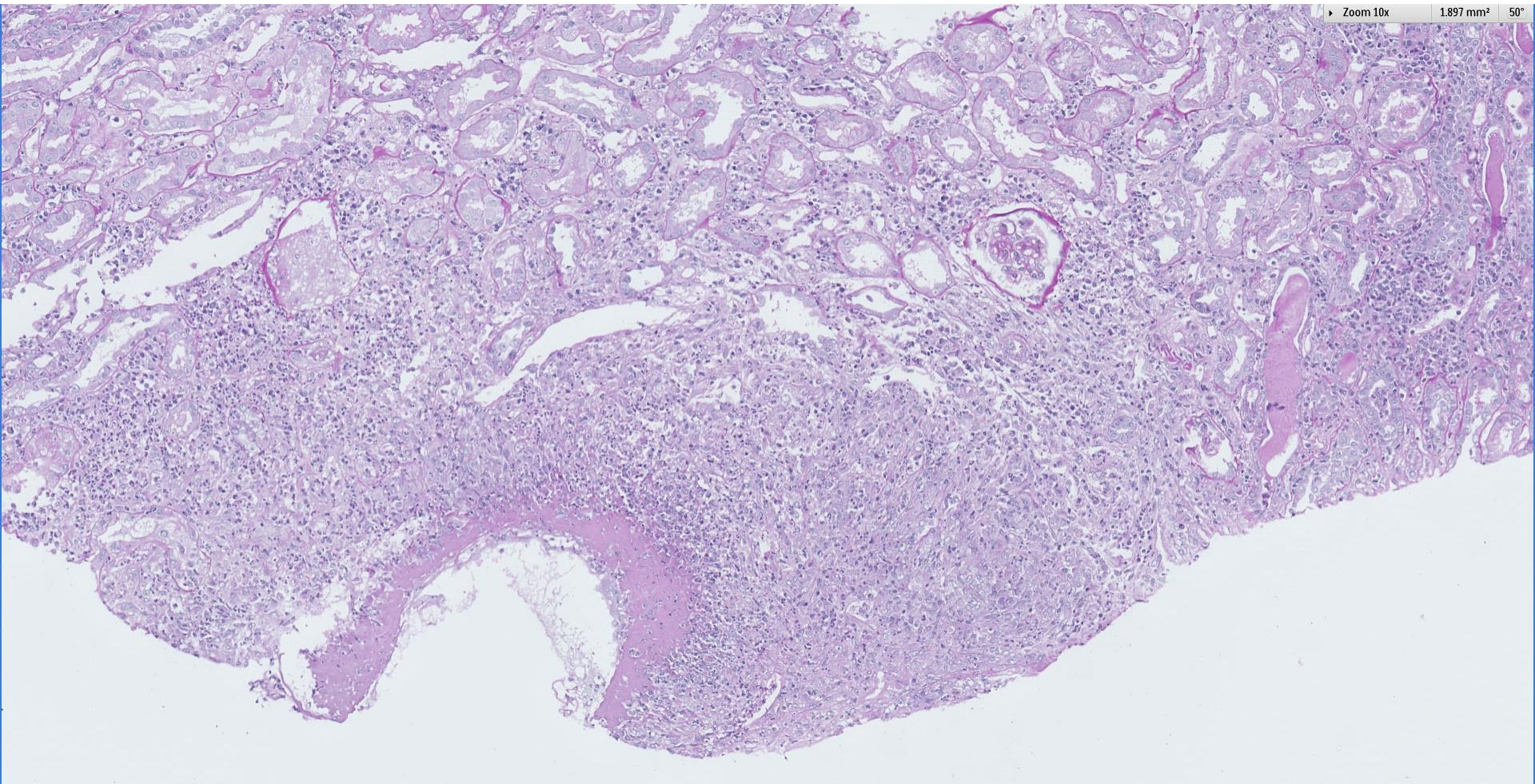


## *Case 53*

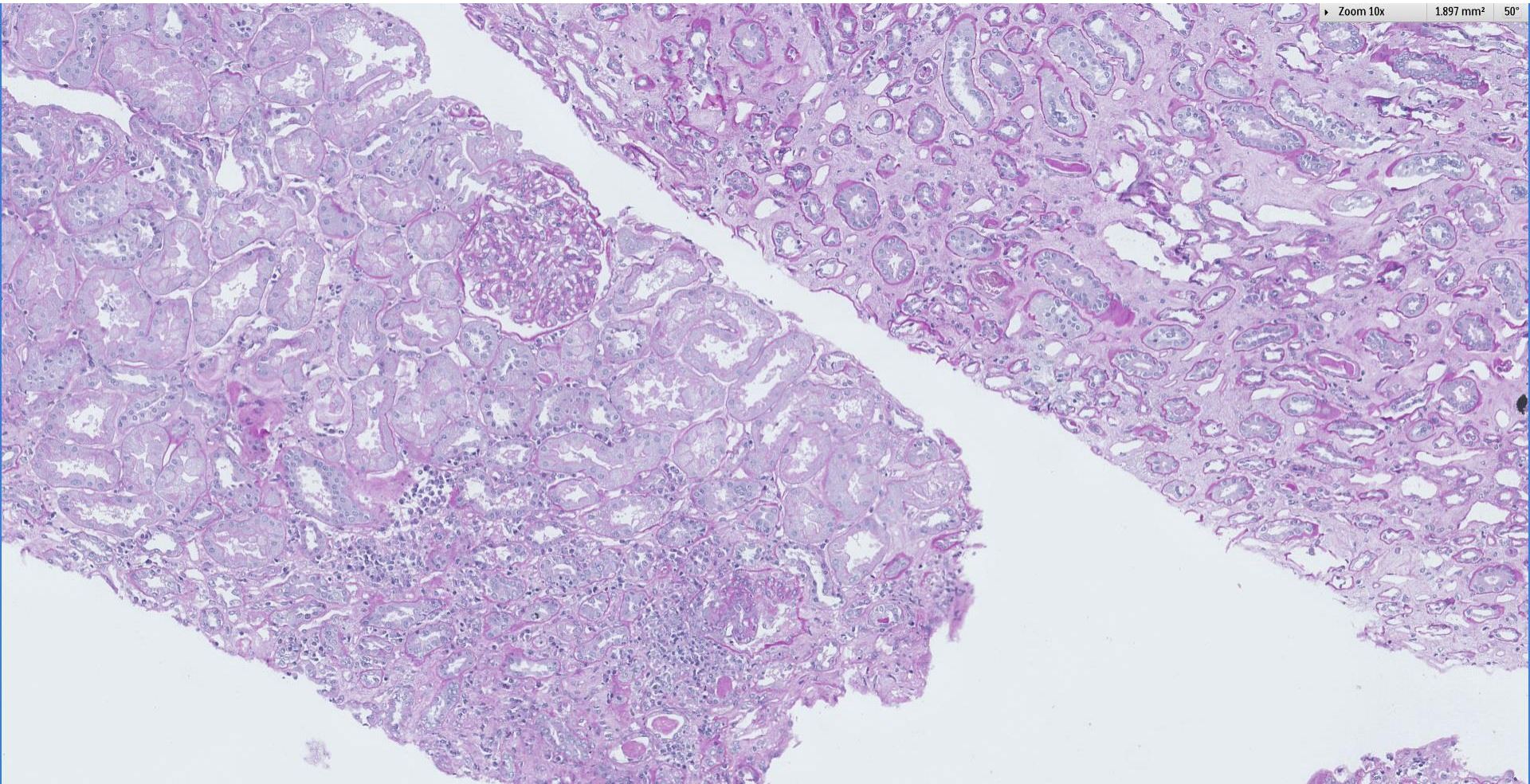
69 year old Chinese lady presented with interstitial lung disease and AKI. Also had mononeuritis multiplex. Anti-MPO was 37.4.



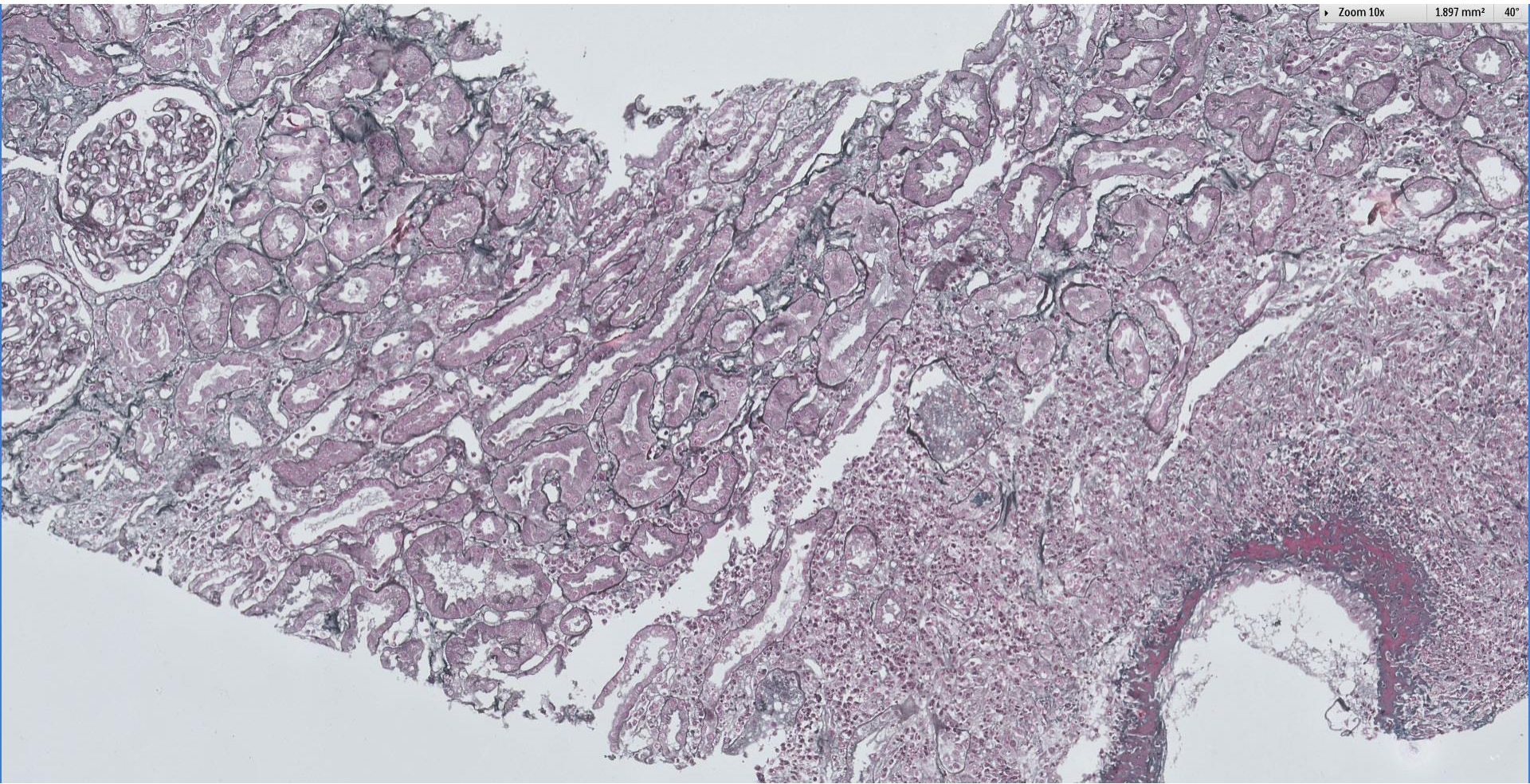






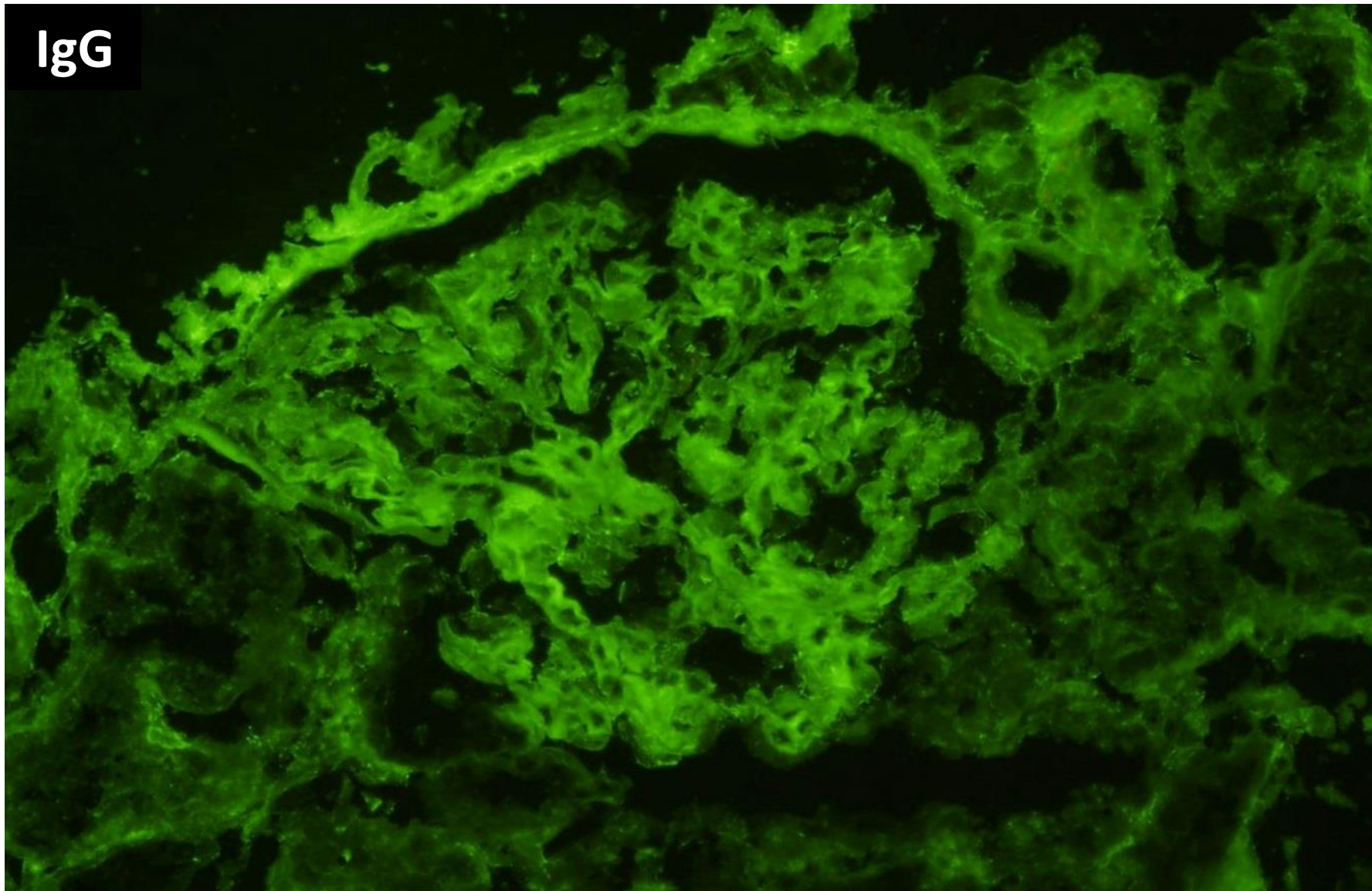




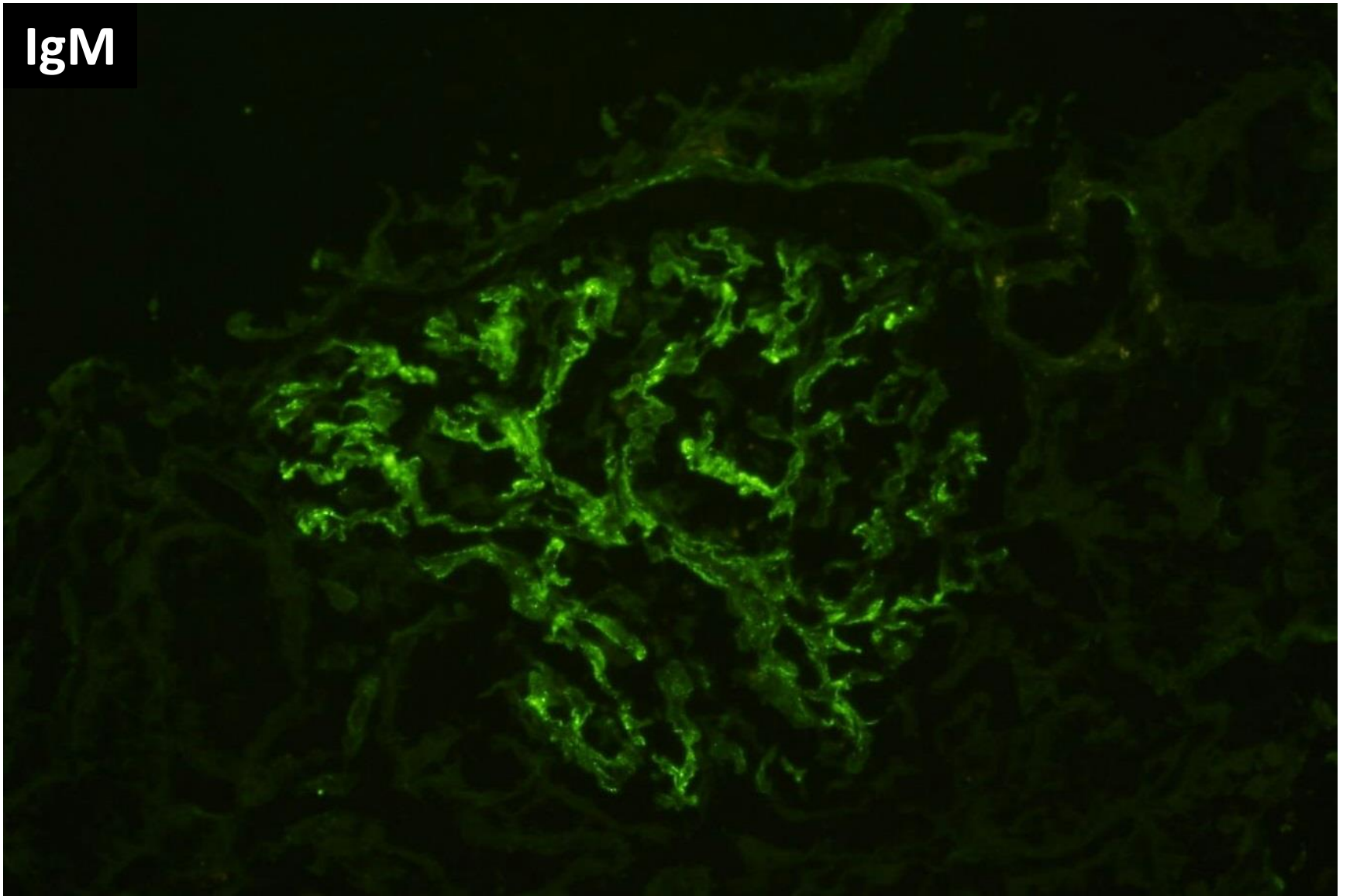




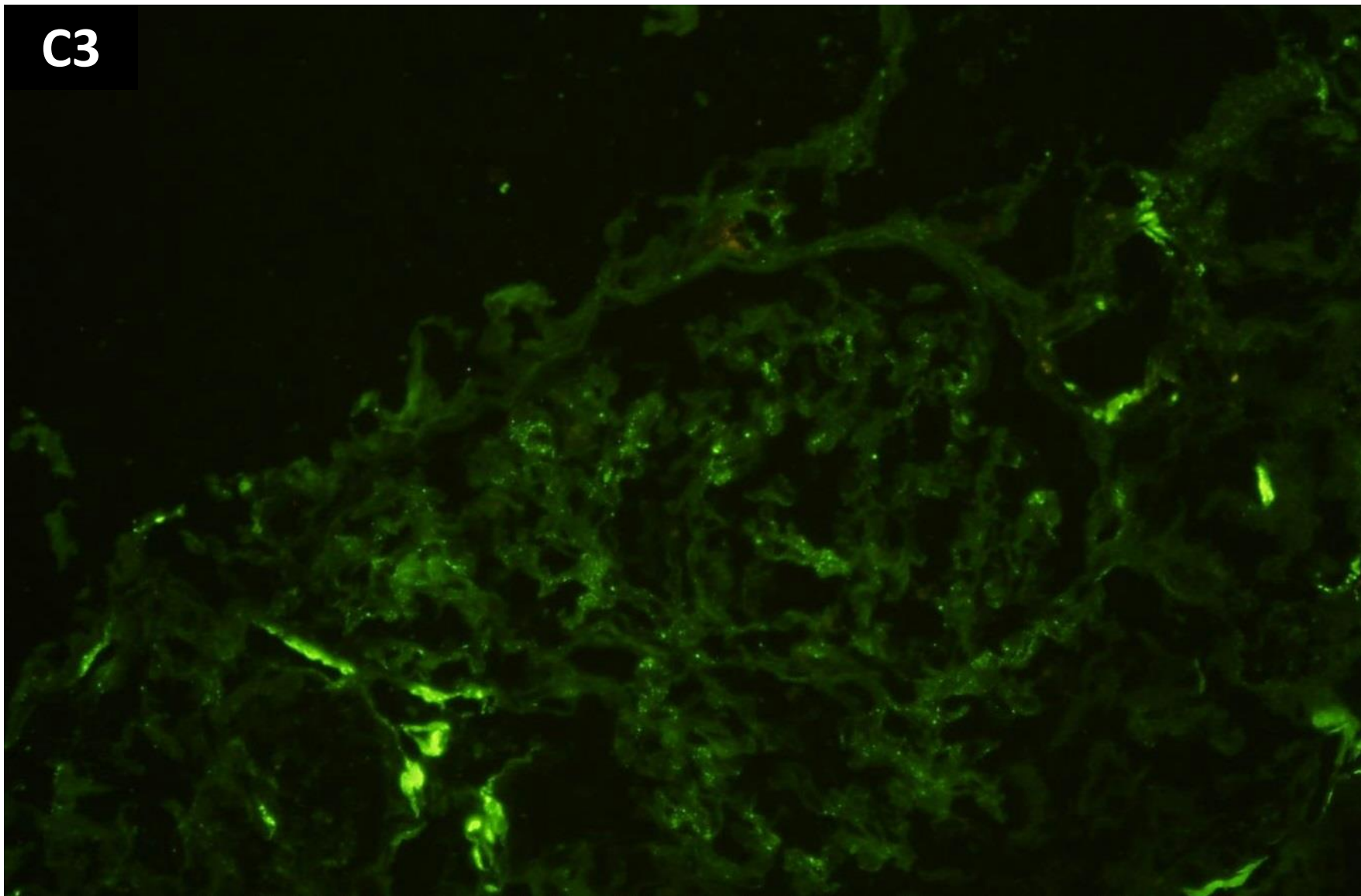
IgG



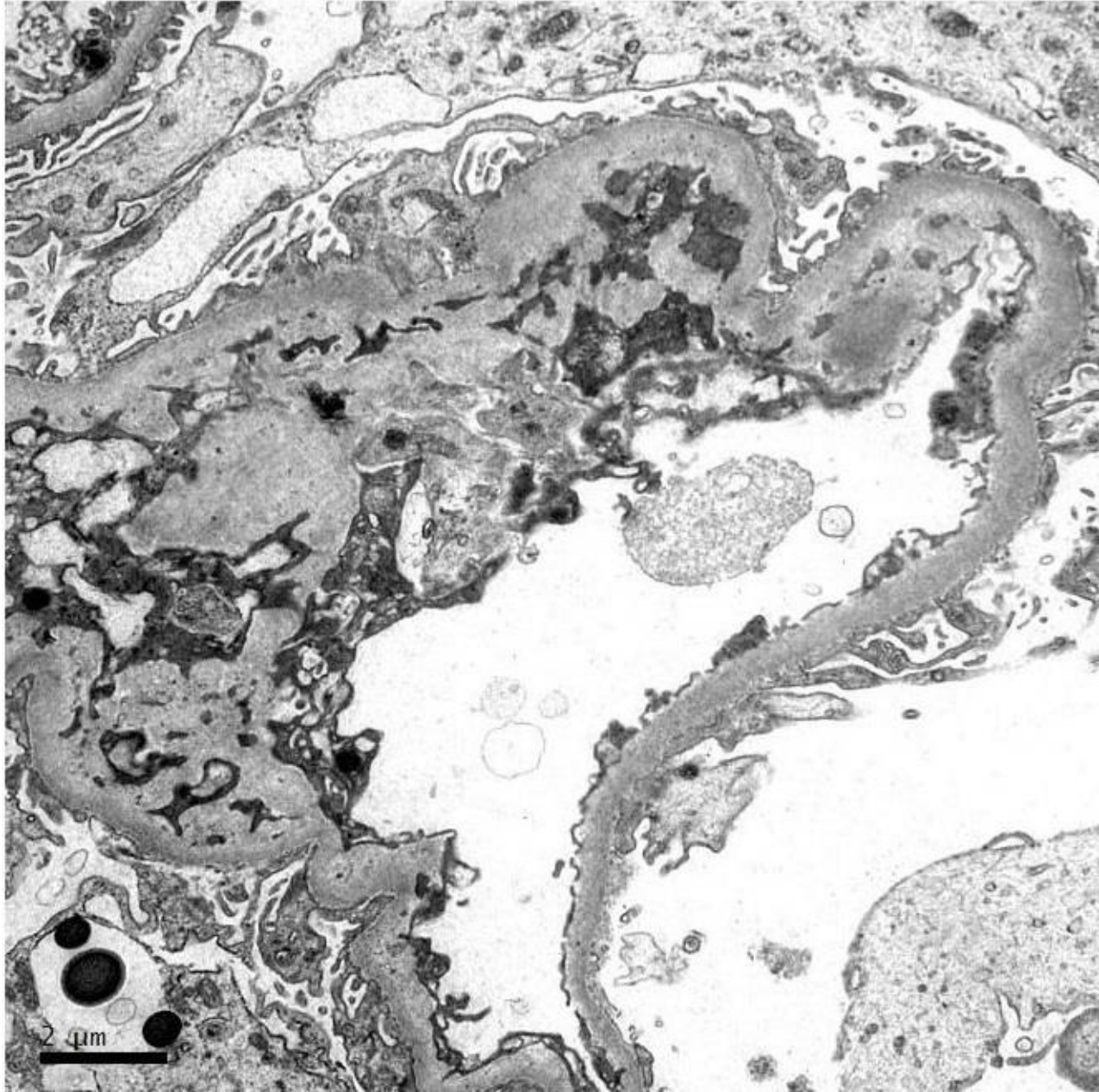
IgM

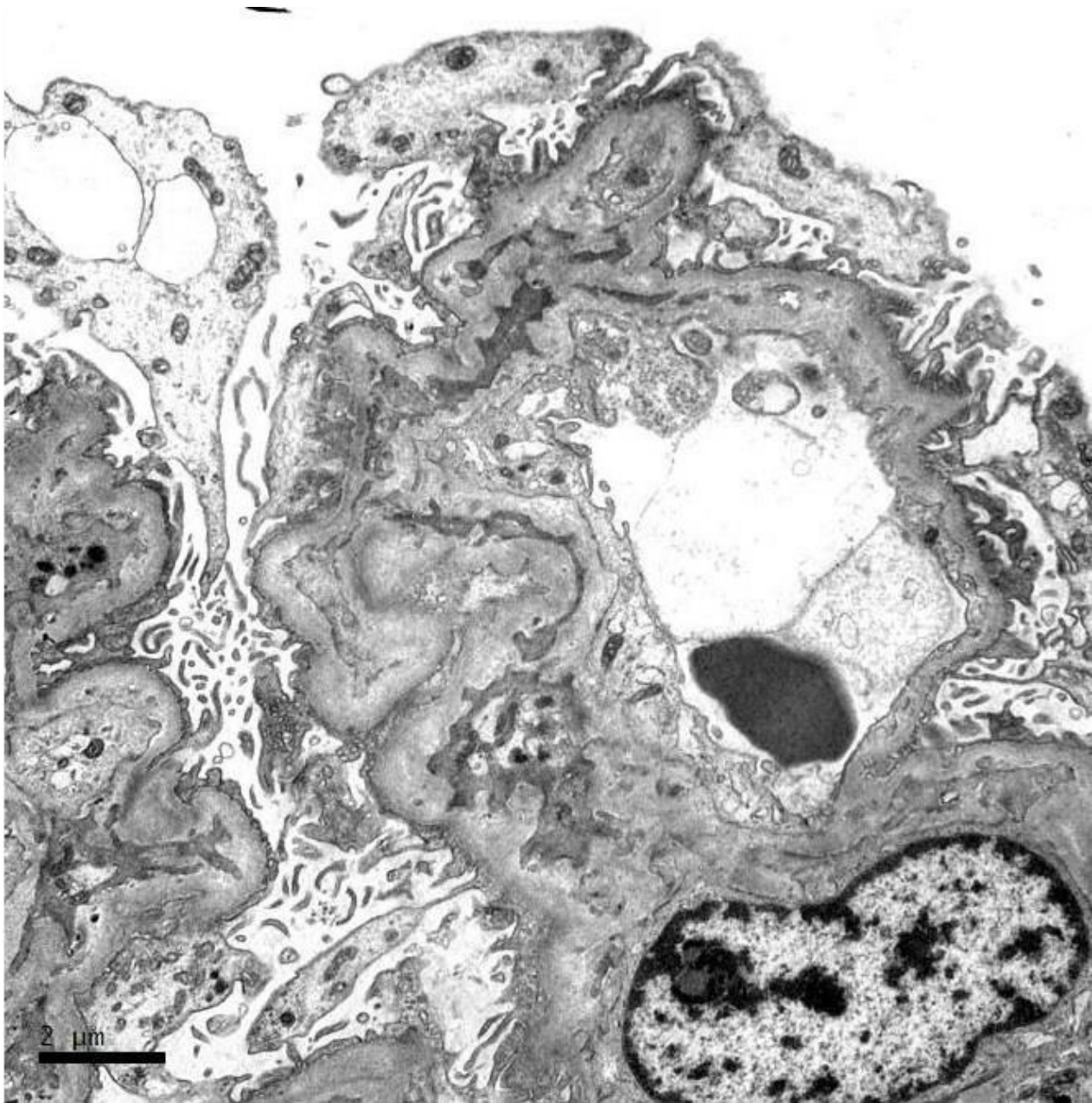


C3

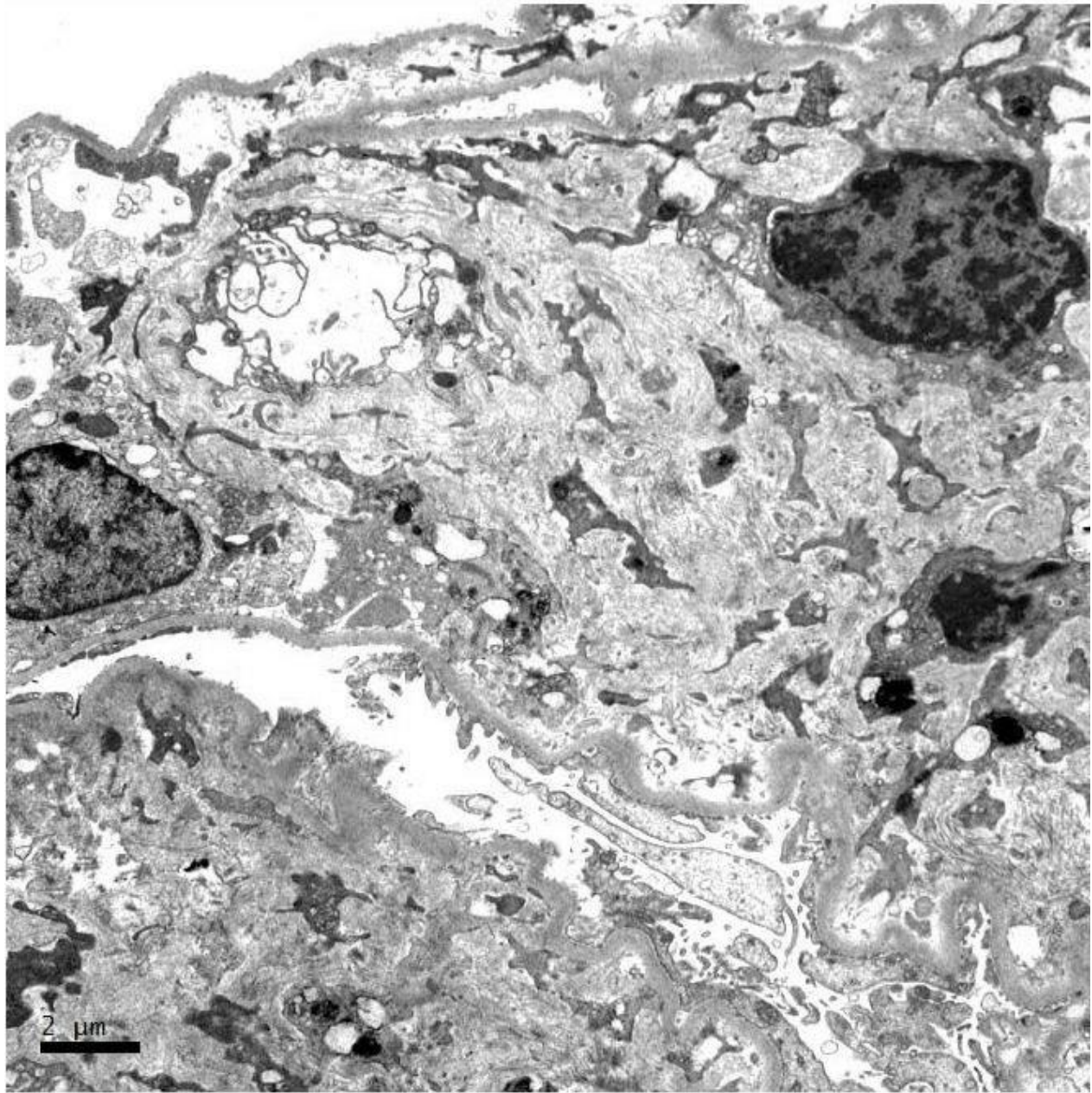


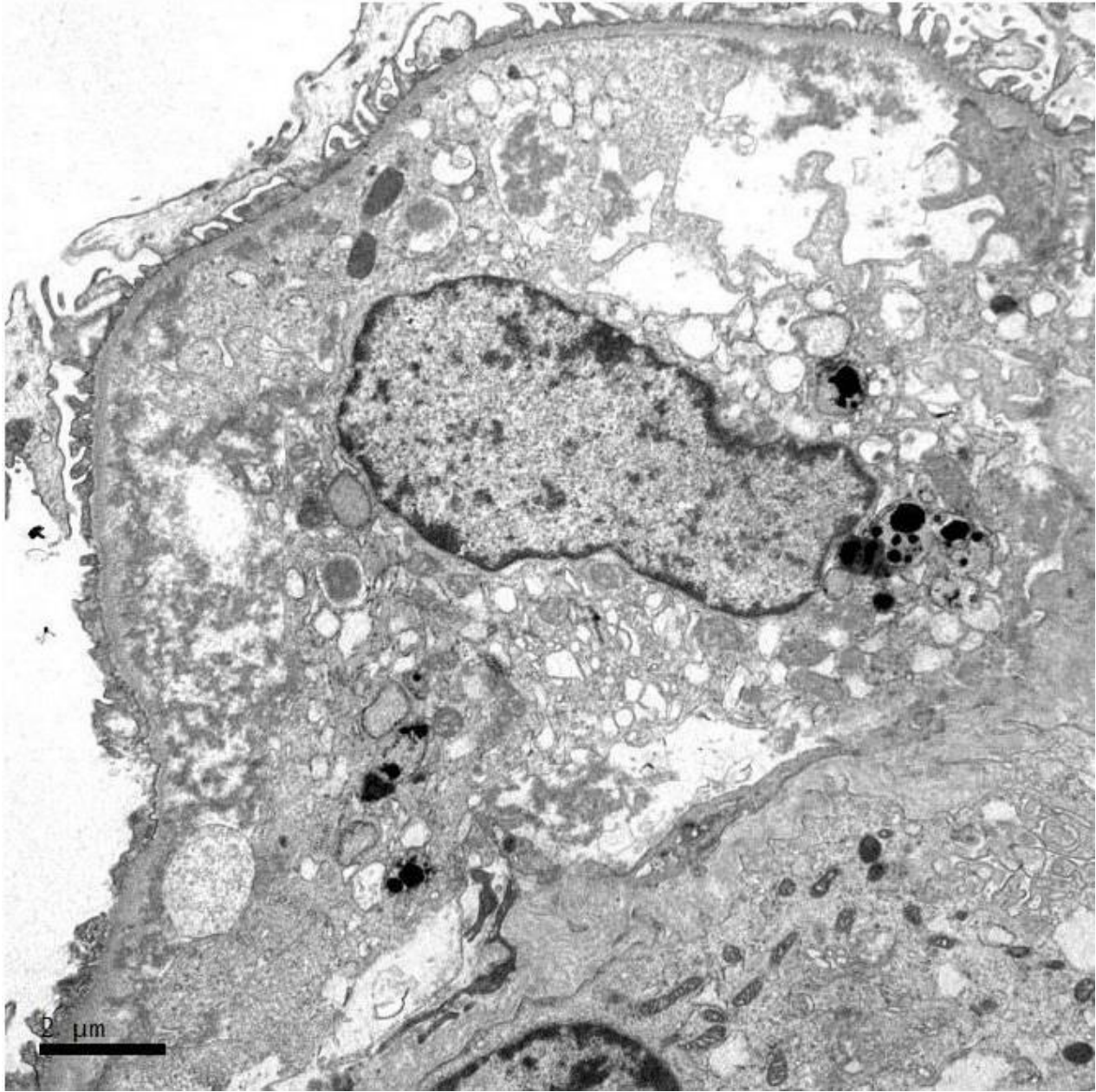




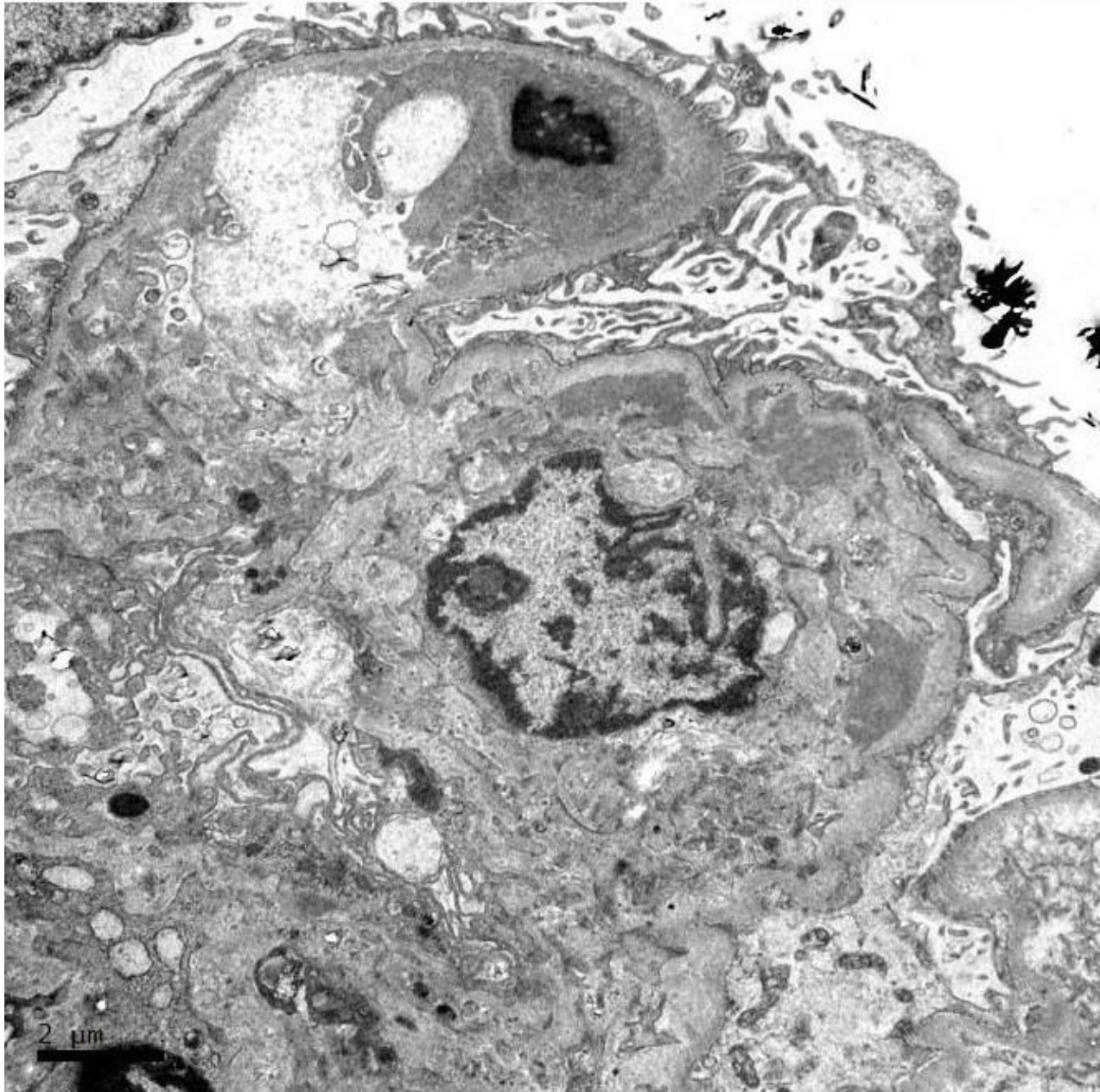
















**RENAL BIOPSY  
CLINICOPATHOLOGICAL  
WORKSHOP 2018**



**PATHOLOGY**



Division of Pathology  
Singapore General Hospital



Department of Renal Medicine  
Singapore General Hospital



**MEDICINE**