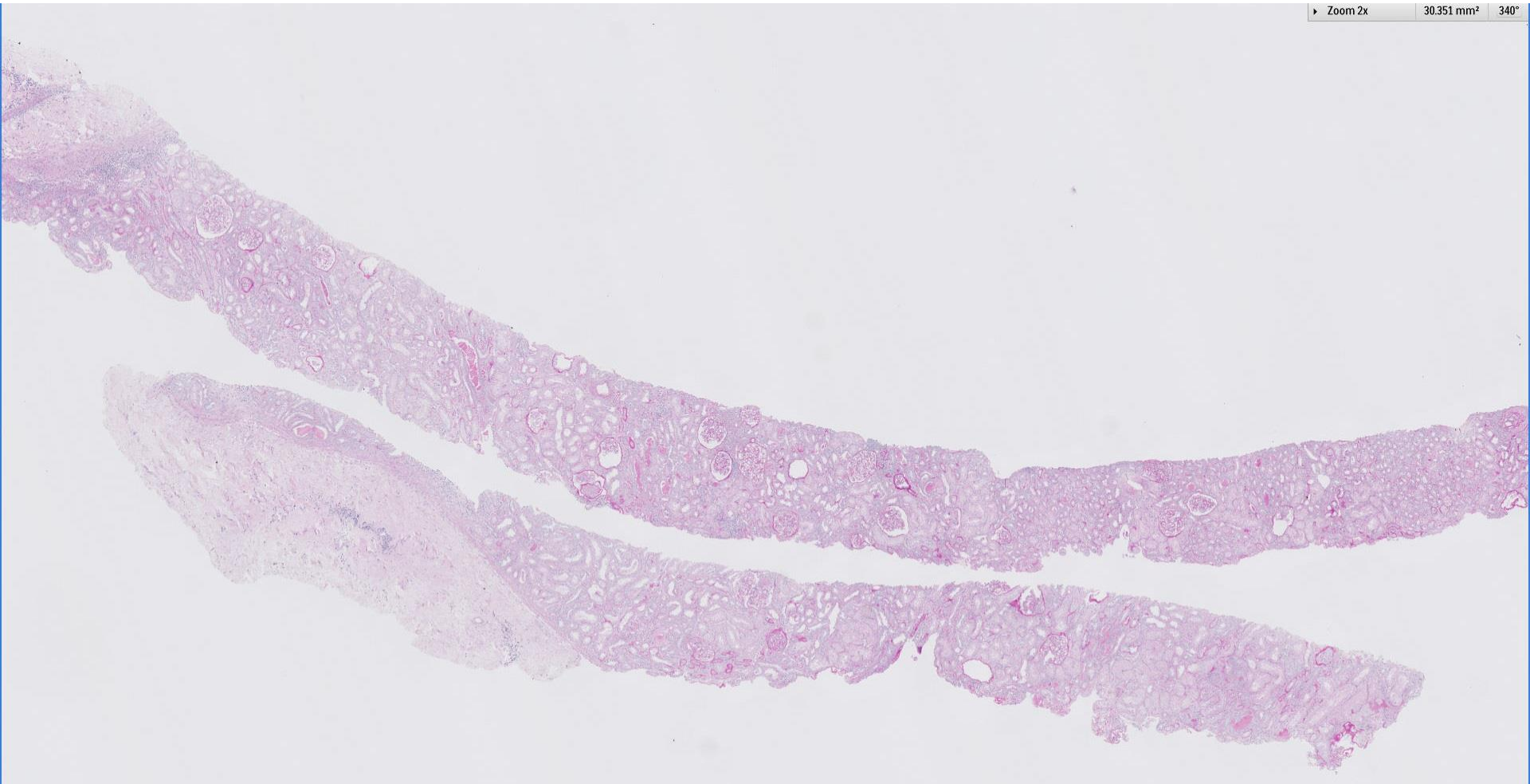
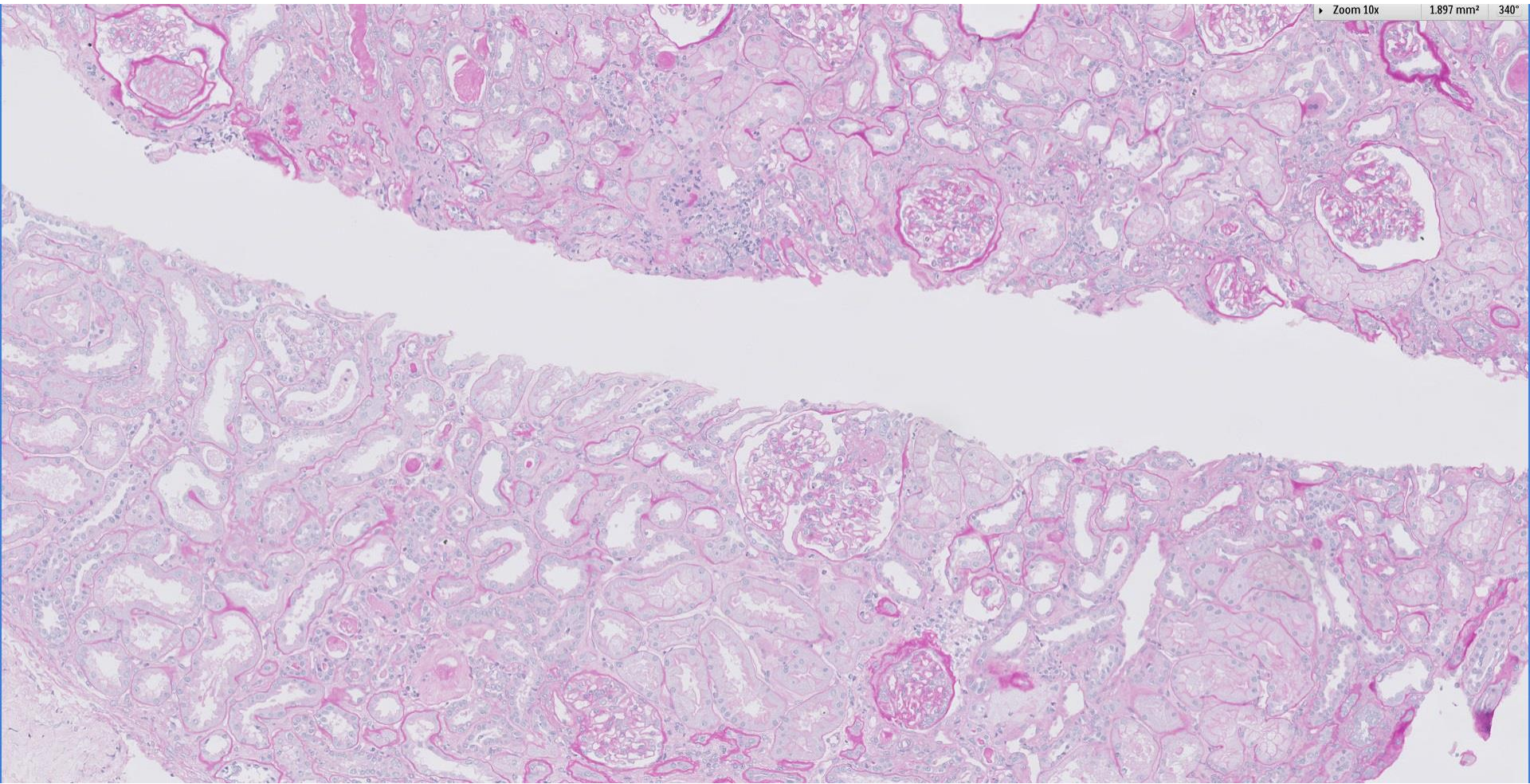
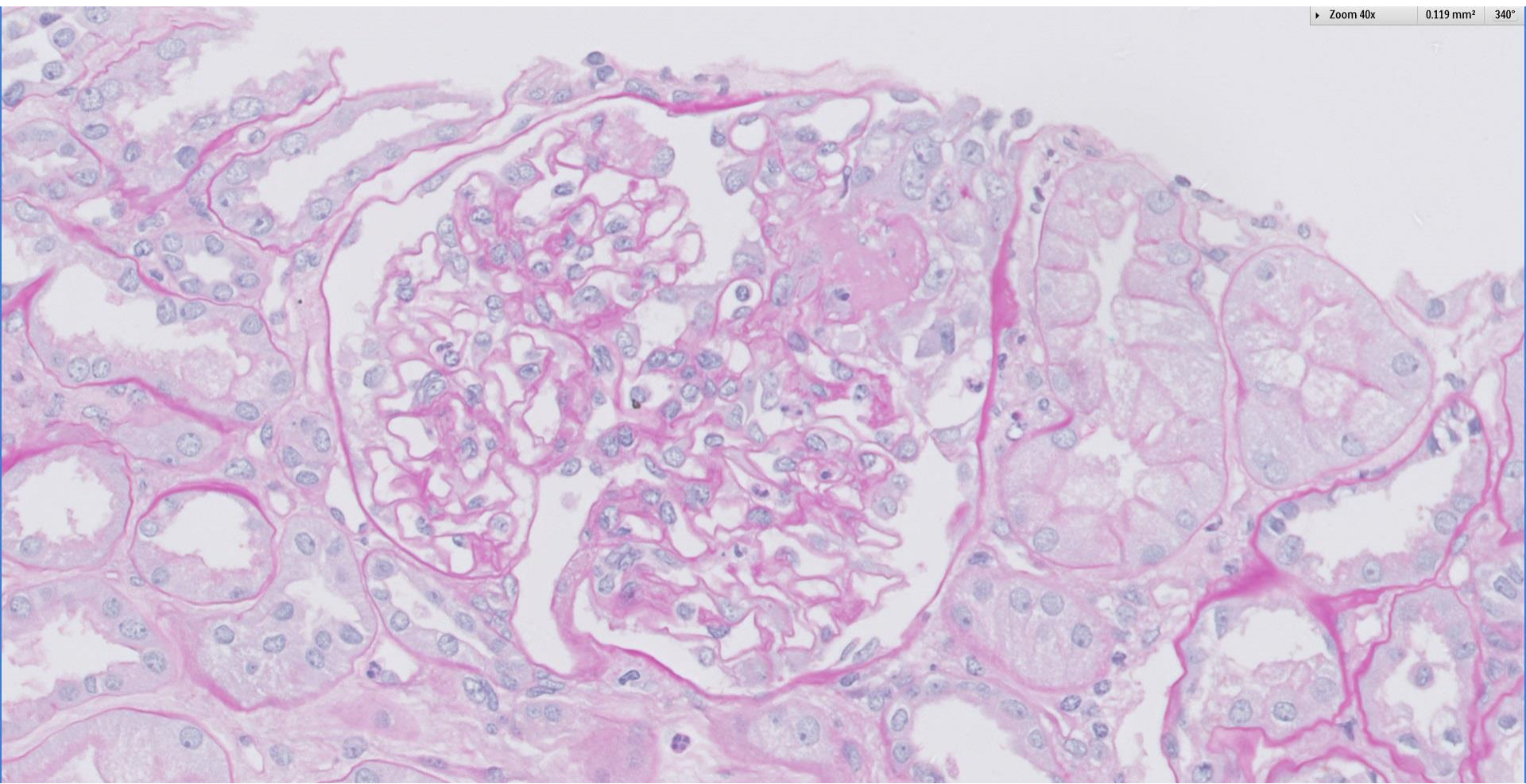


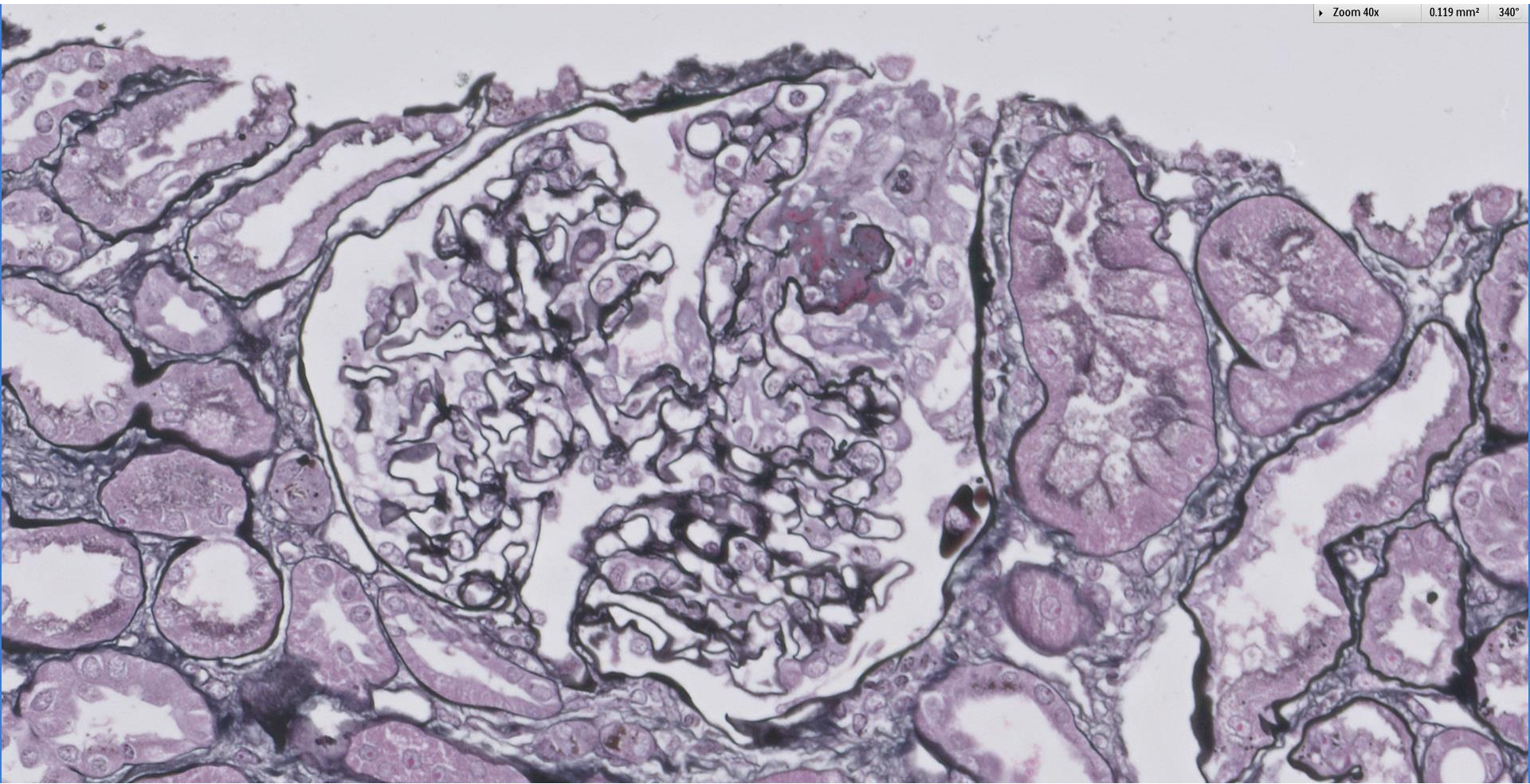
Case 52

54 year old Chinese lady presented with cutaneous vasculitis. Renal function was preserved with subnephrotic proteinuria and active haematuria. Anti-MPO was >100.

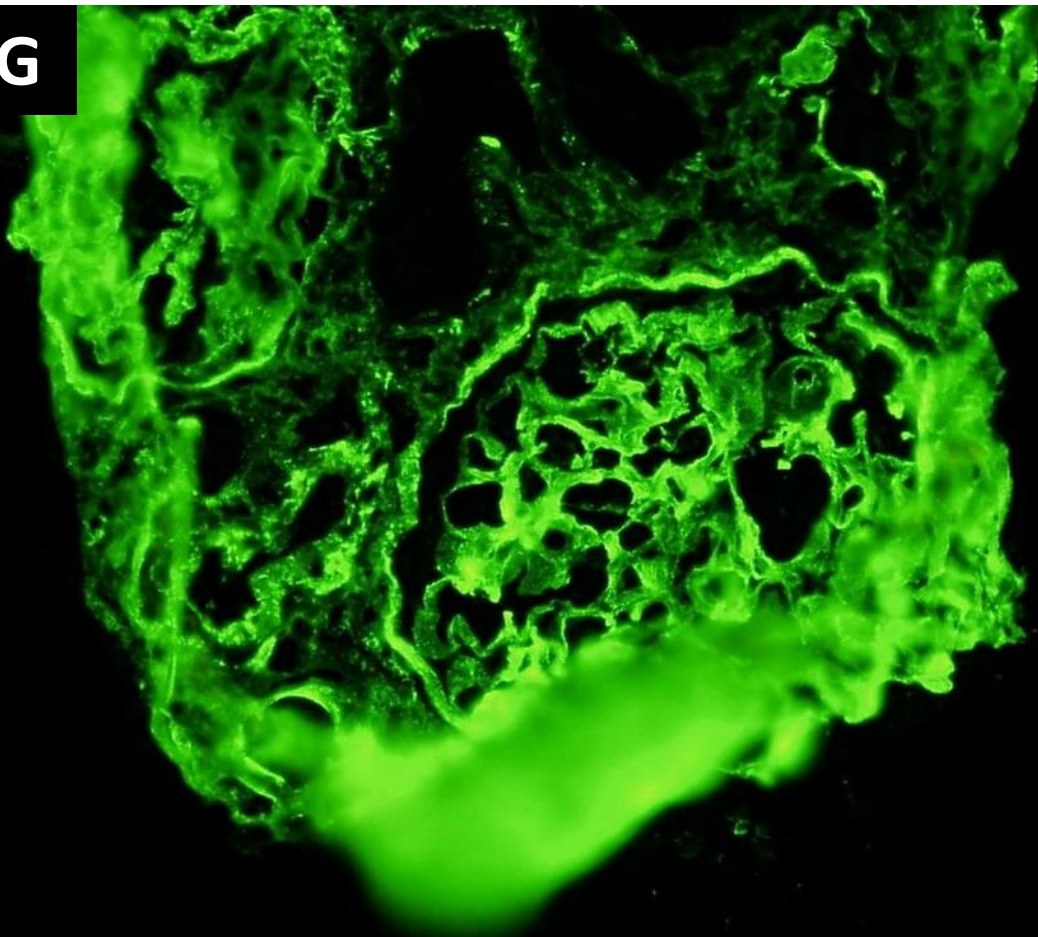




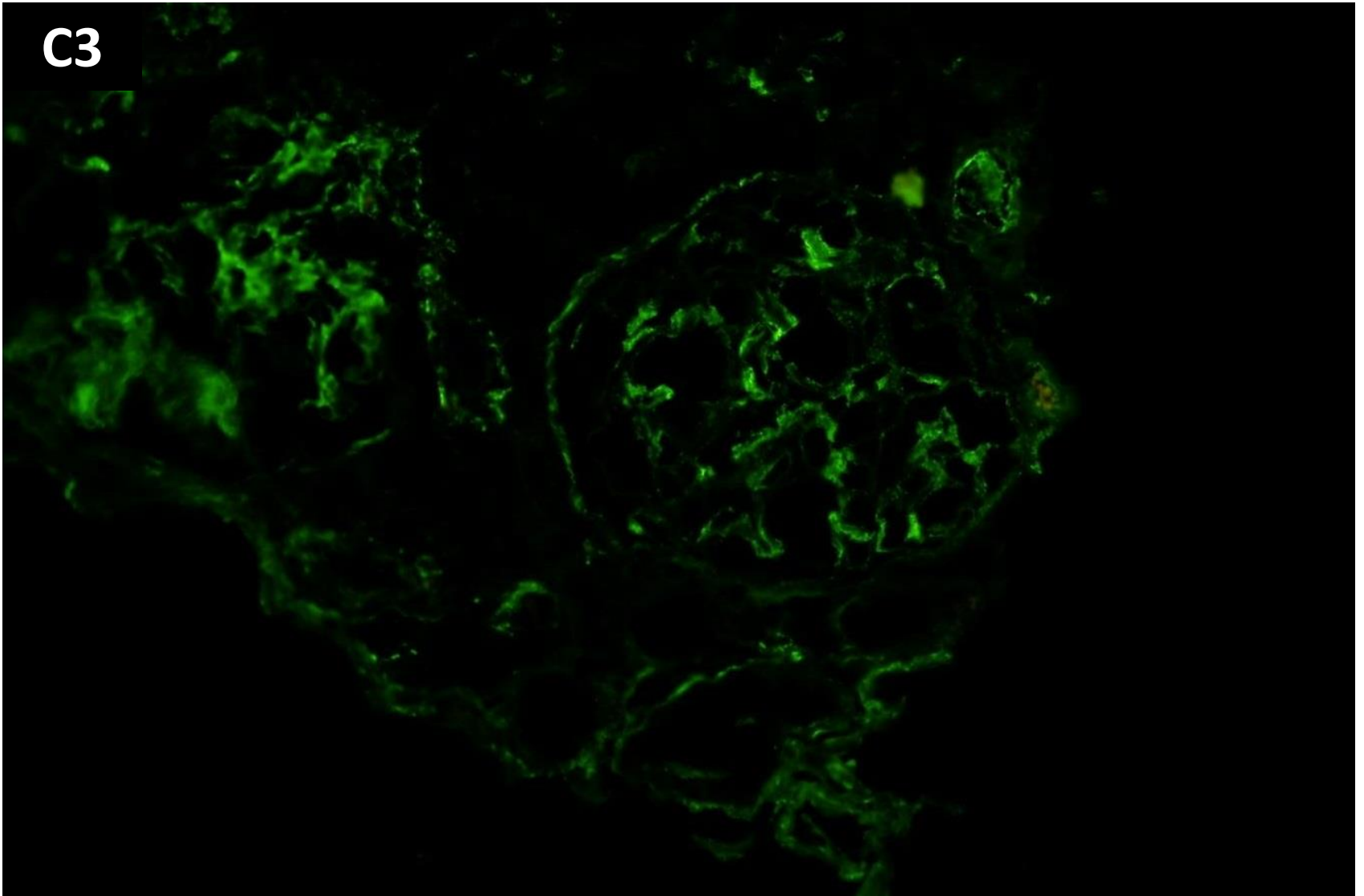




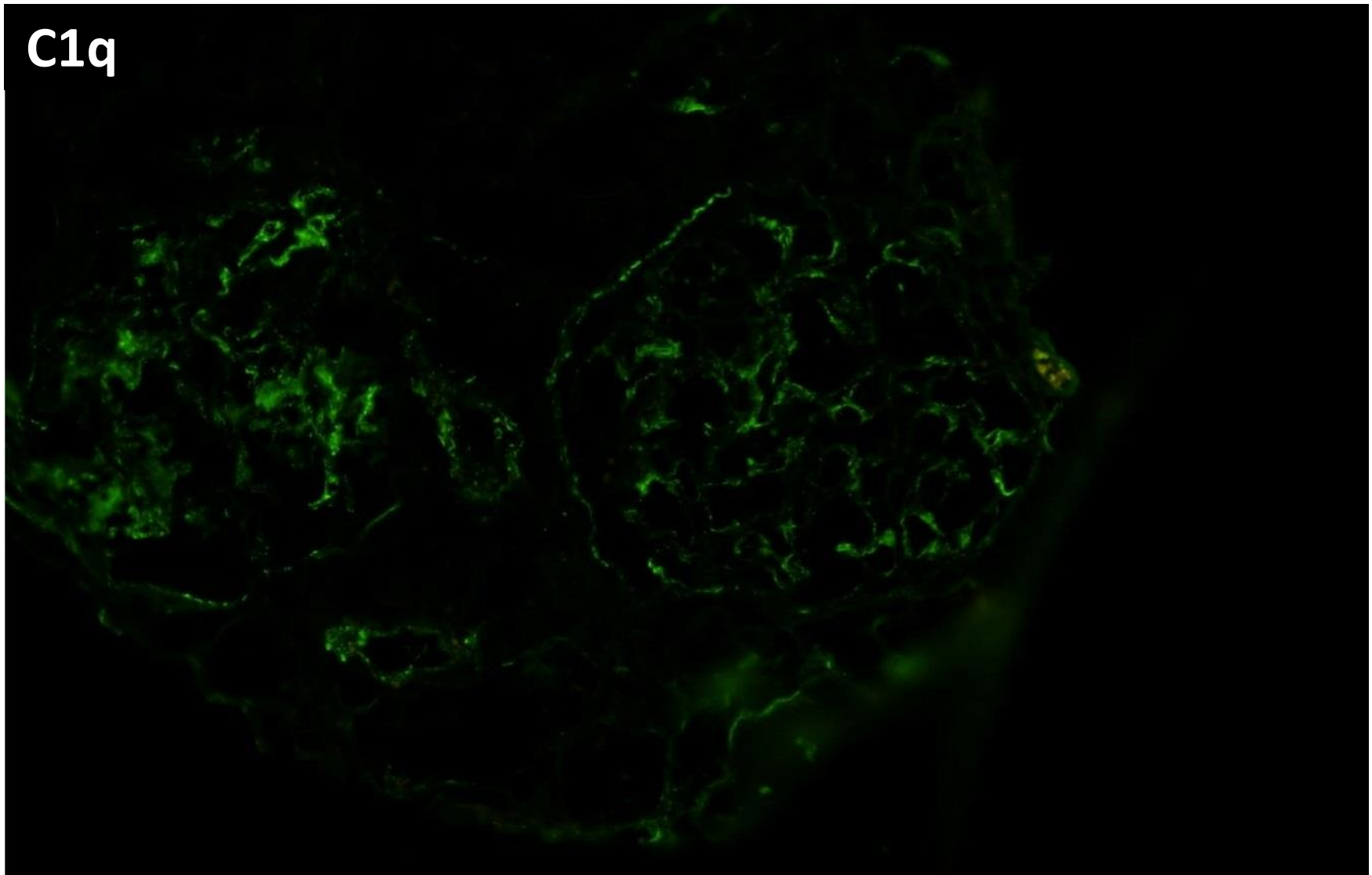
IgG



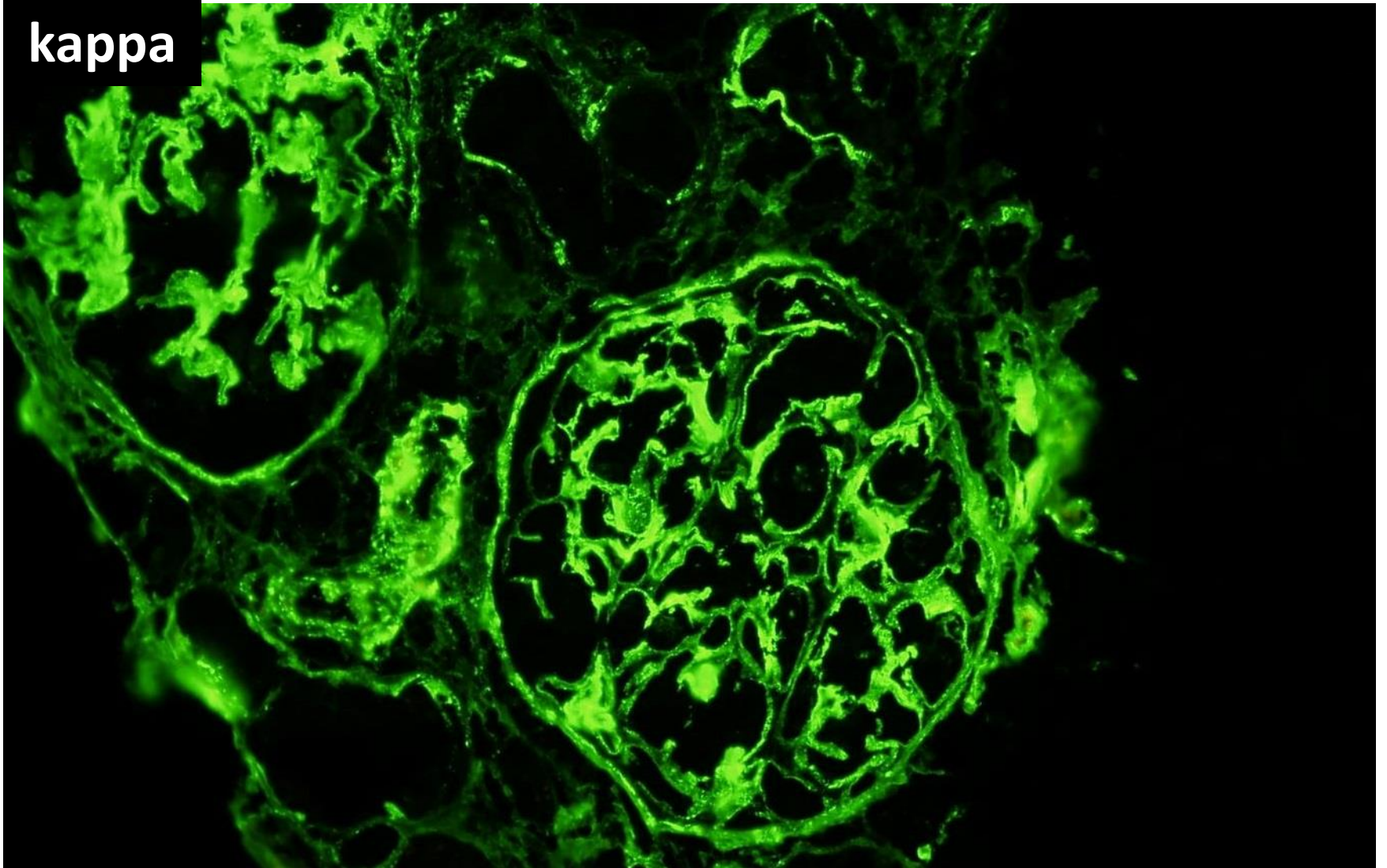
C3



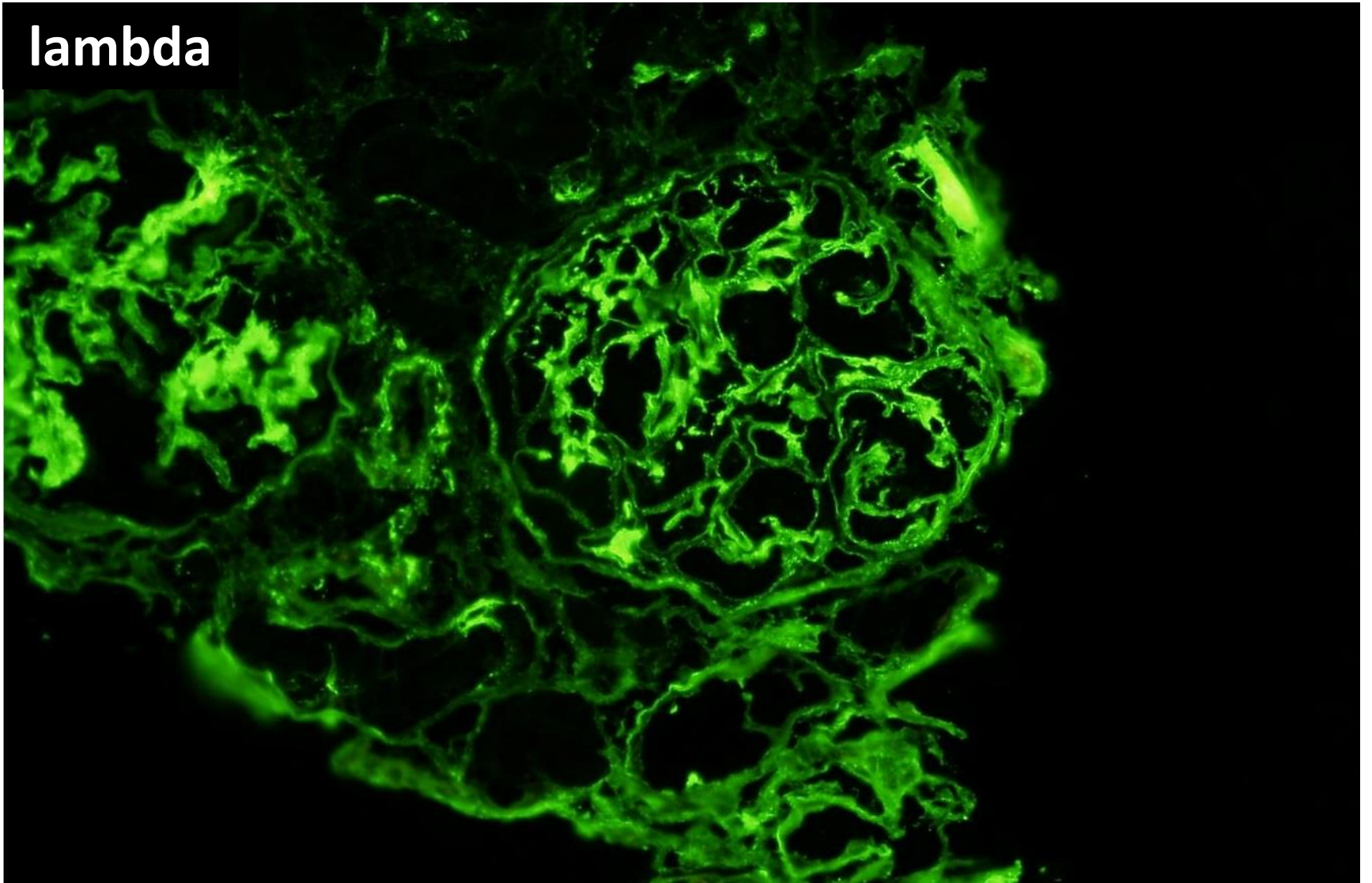
C1q

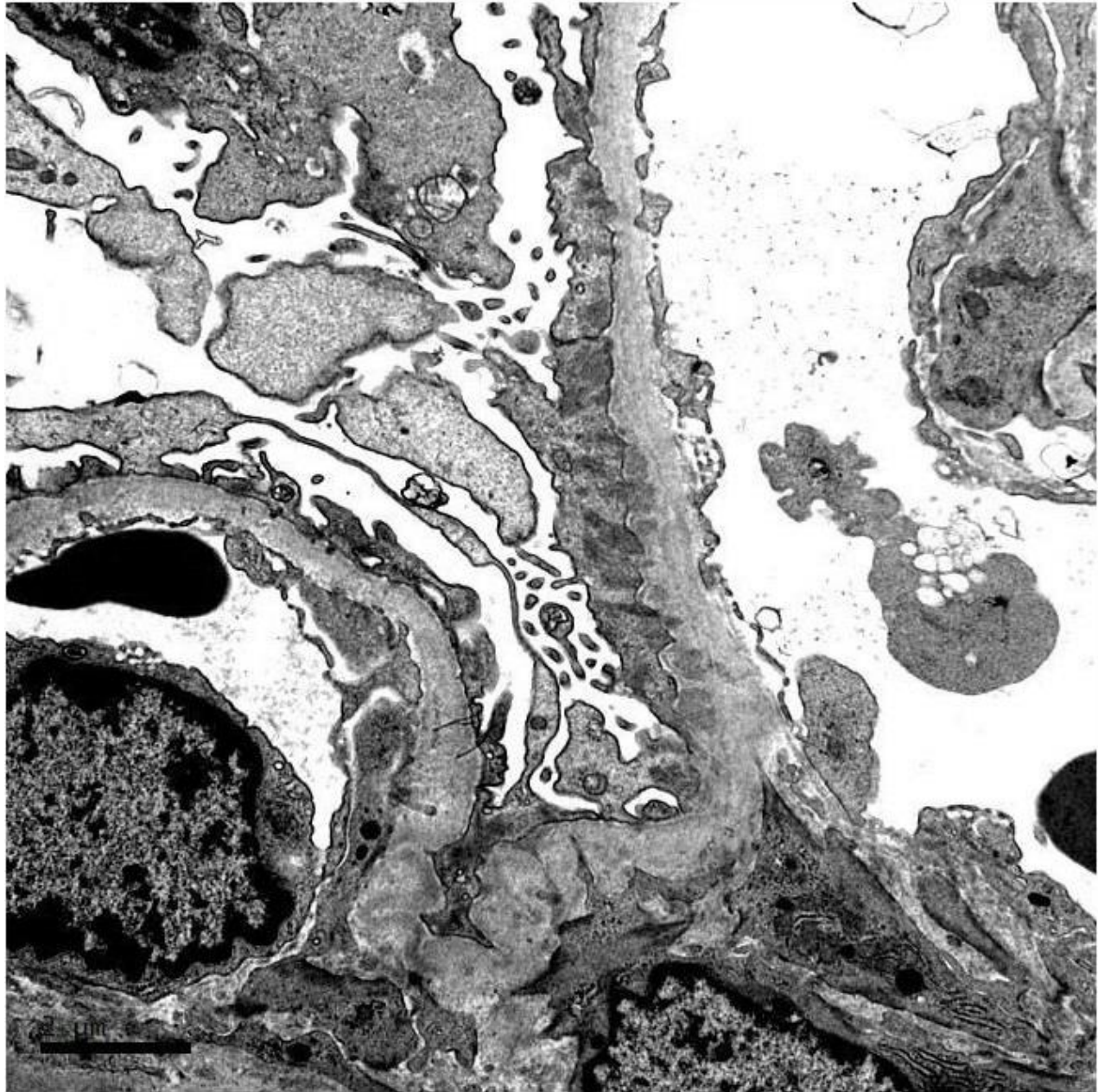


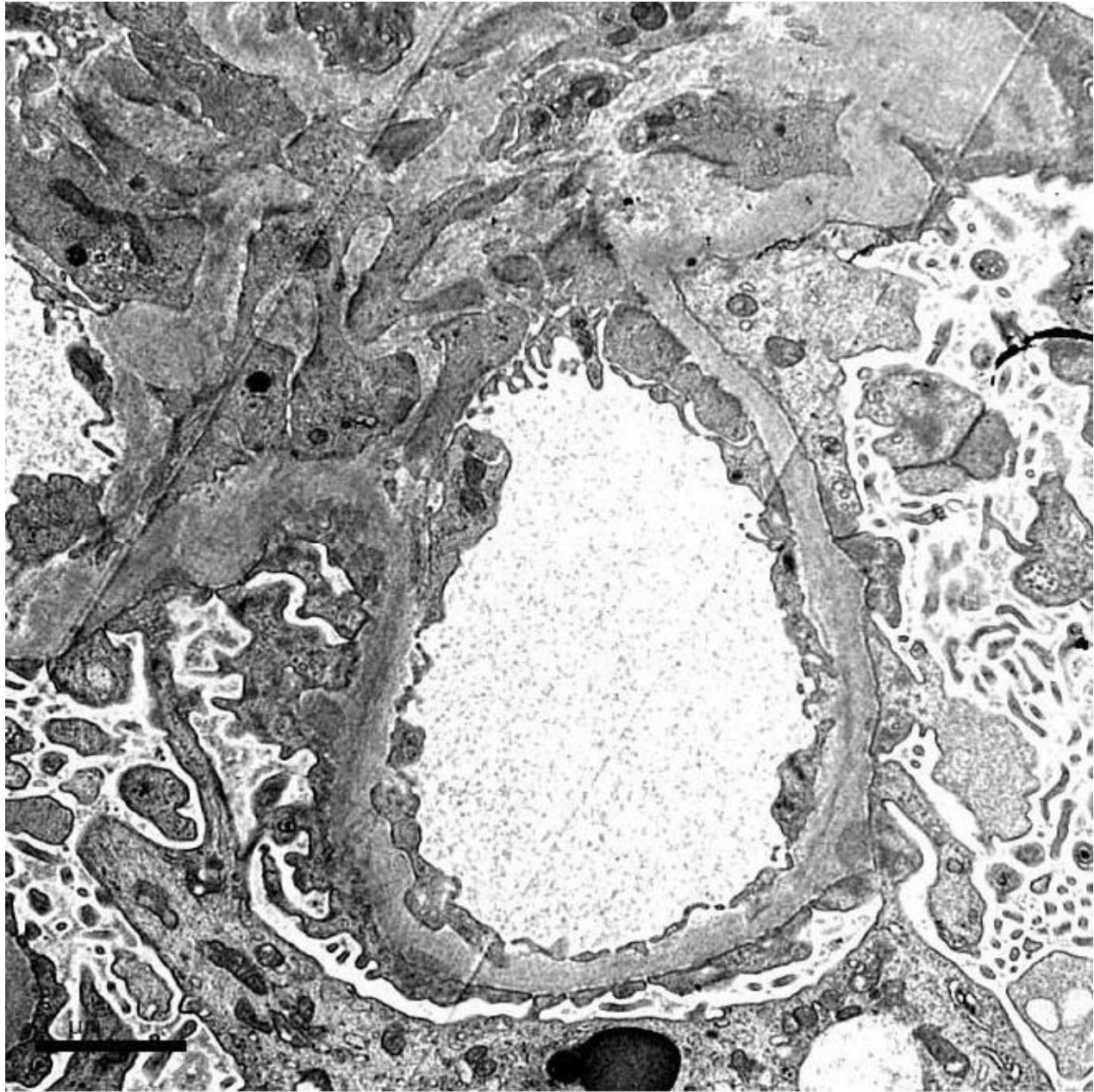
kappa

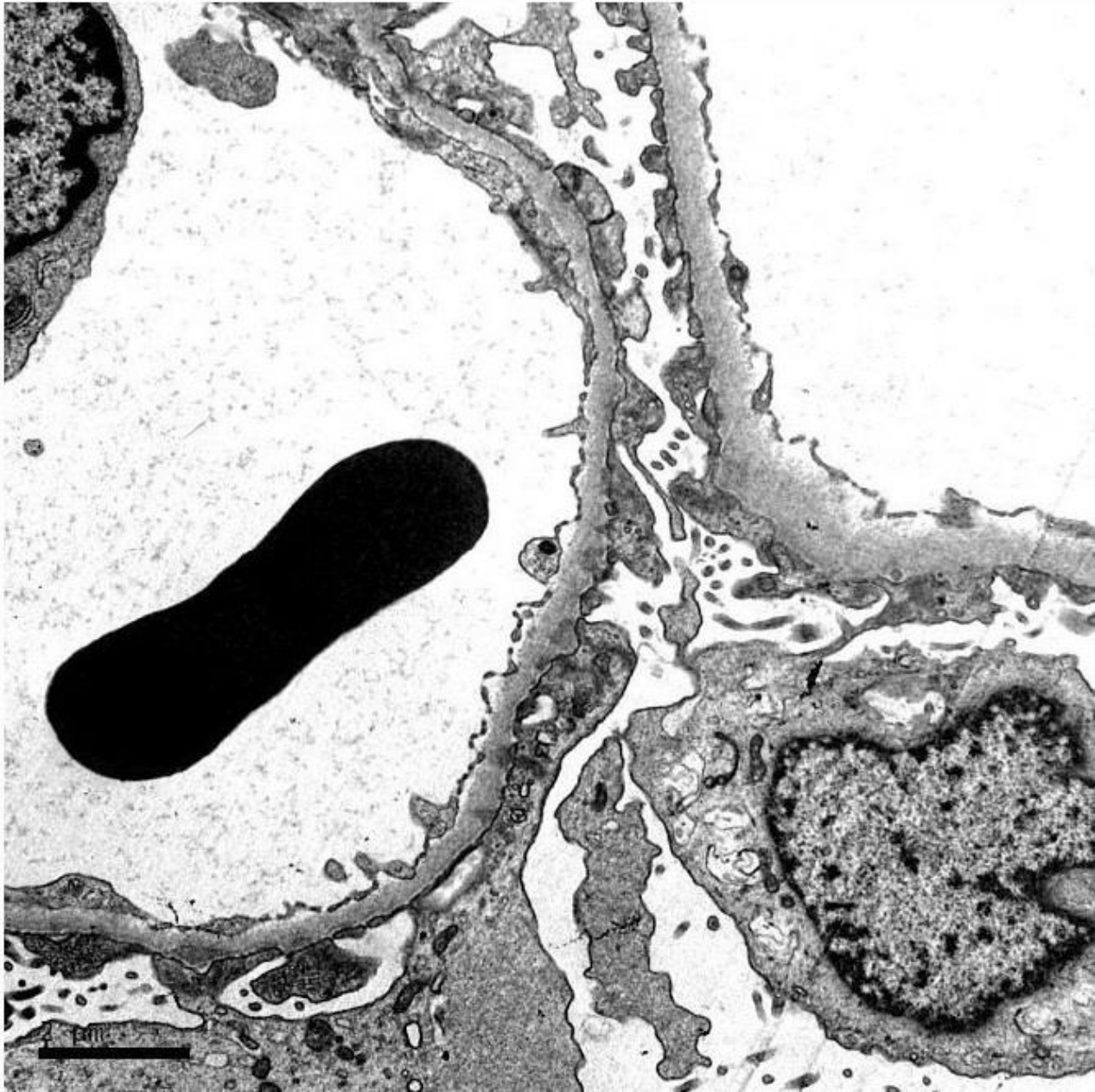


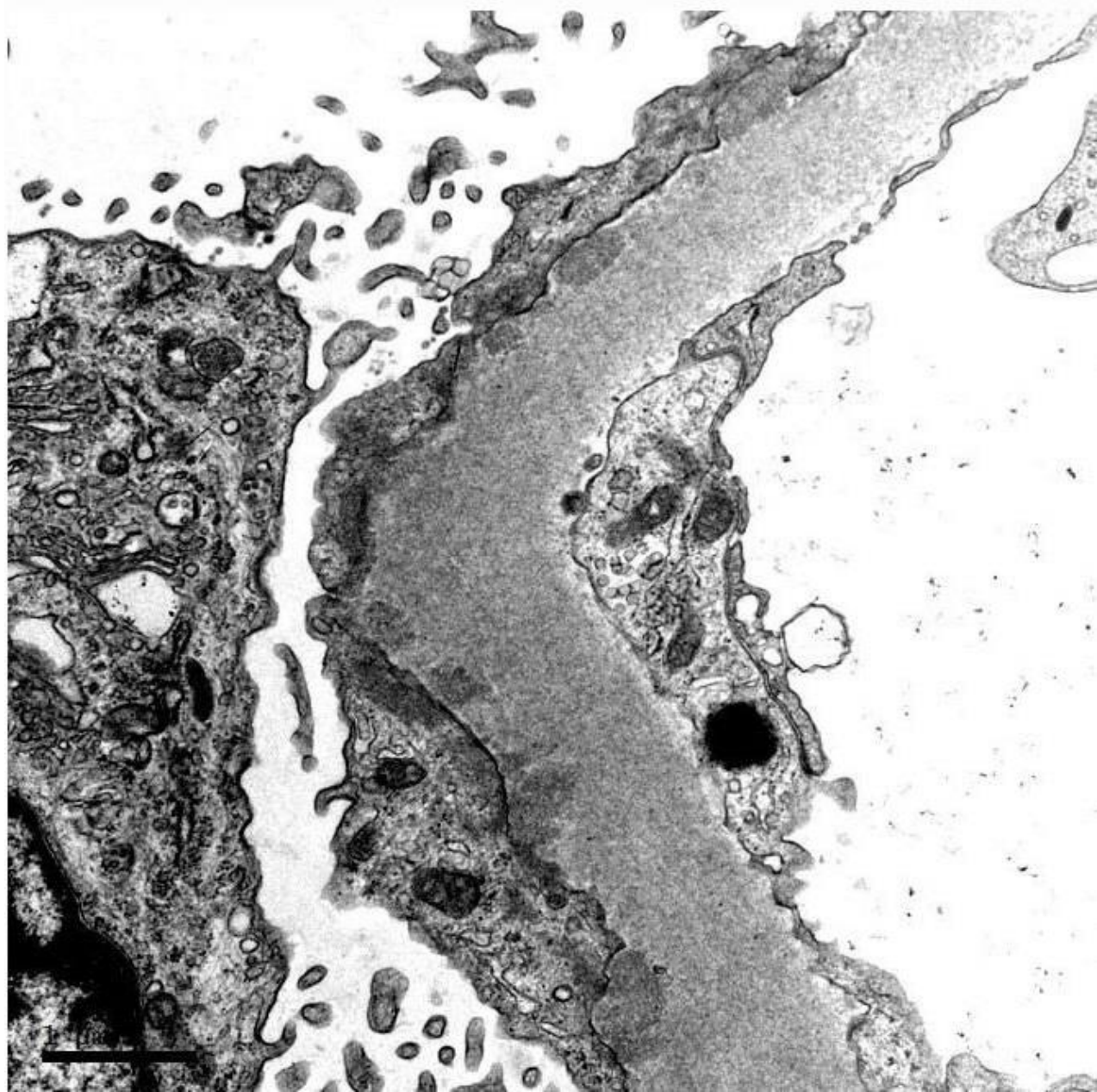
lambda

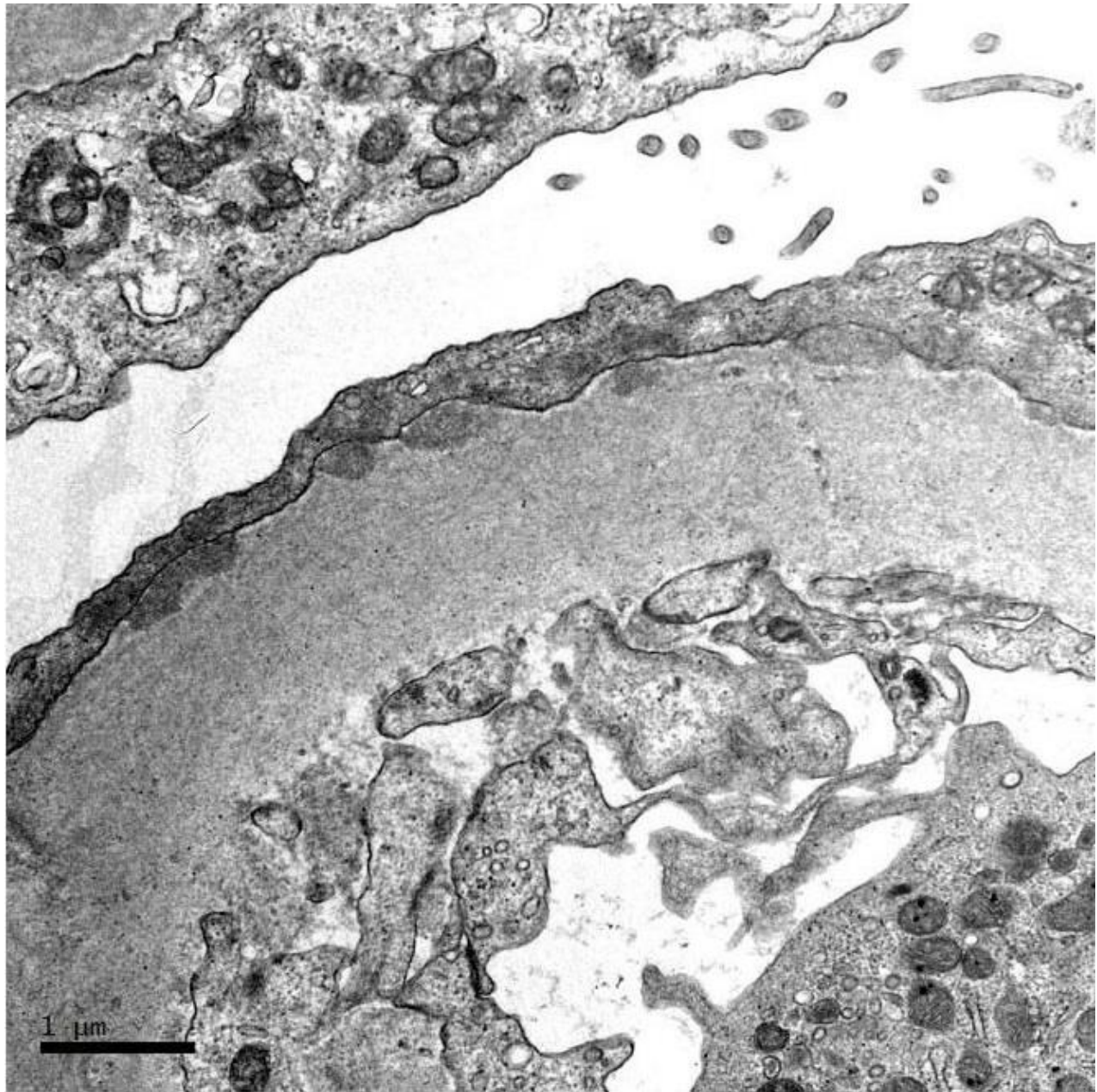


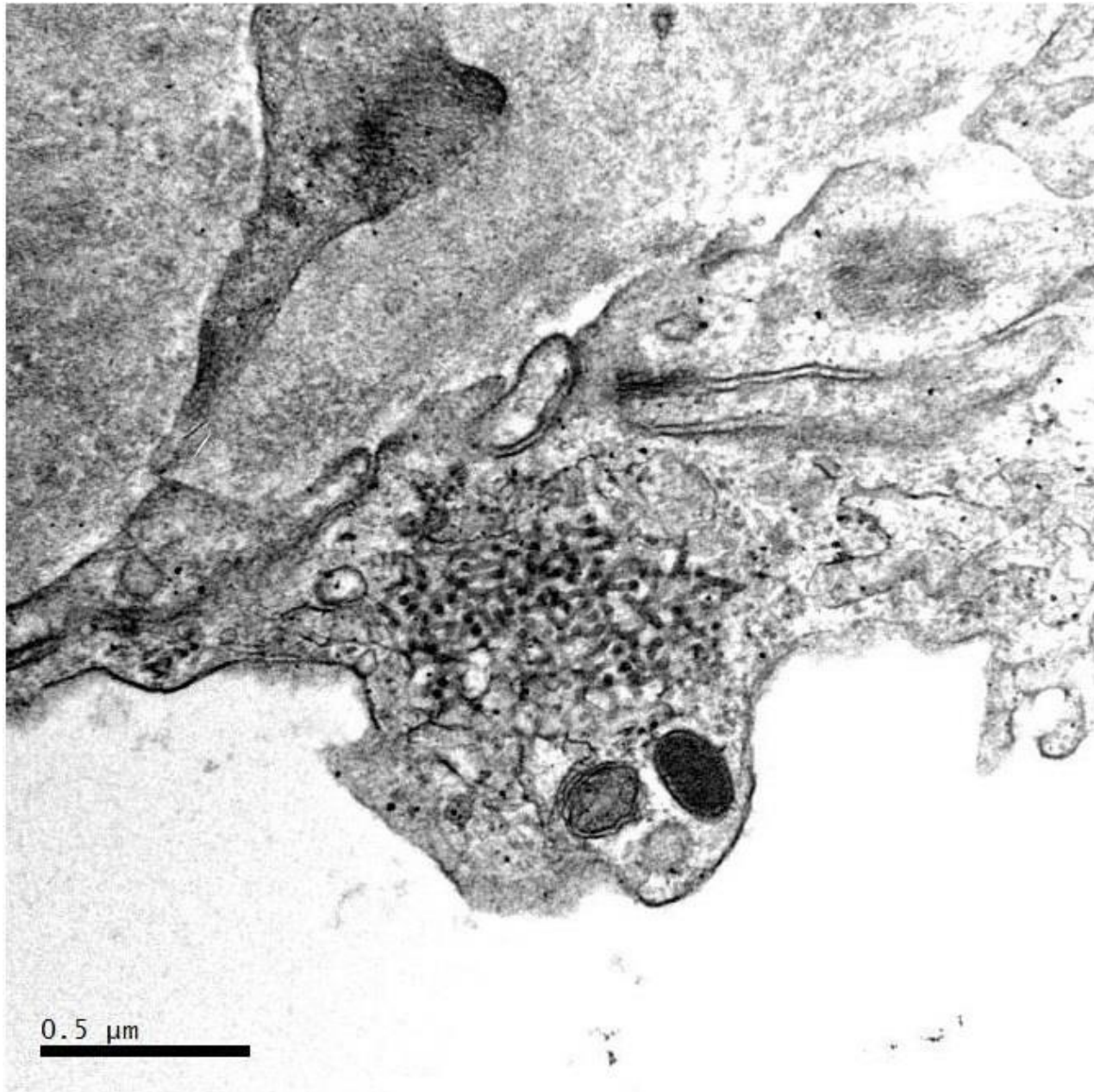














RENAL BIOPSY CLINICOPATHOLOGICAL WORKSHOP 2018



PATHOLOGY



Division of Pathology
Singapore General Hospital



Department of Renal Medicine
Singapore General Hospital



MEDICINE