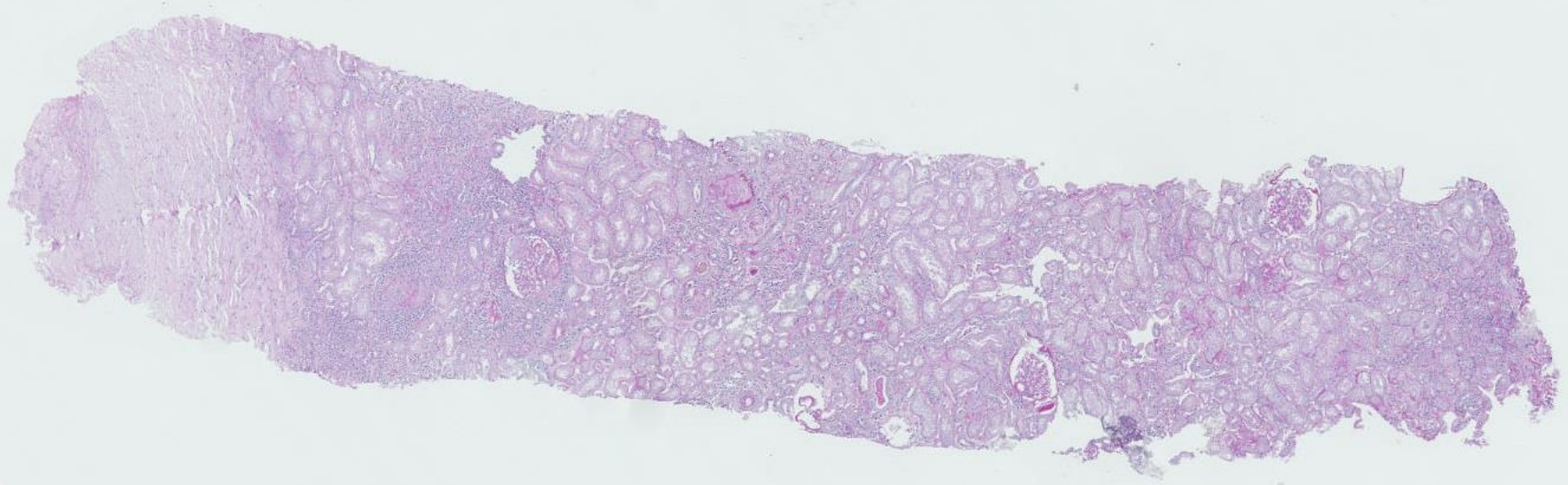
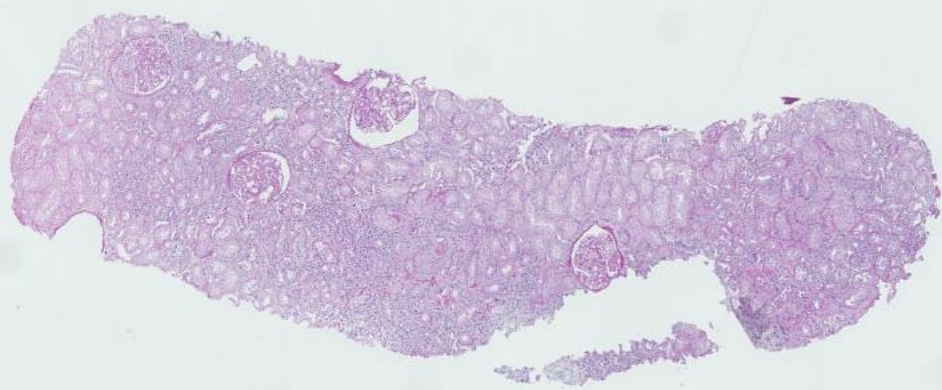
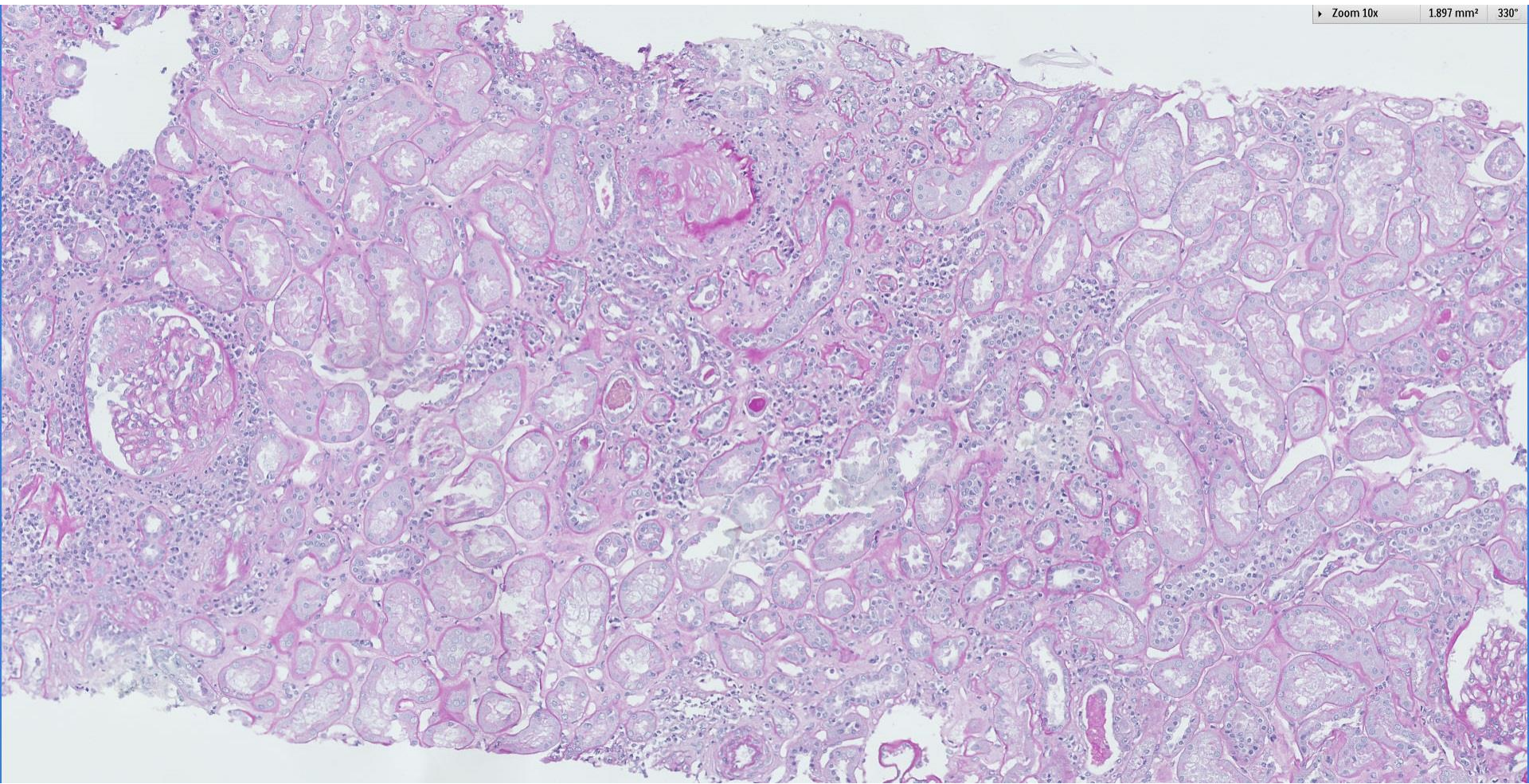
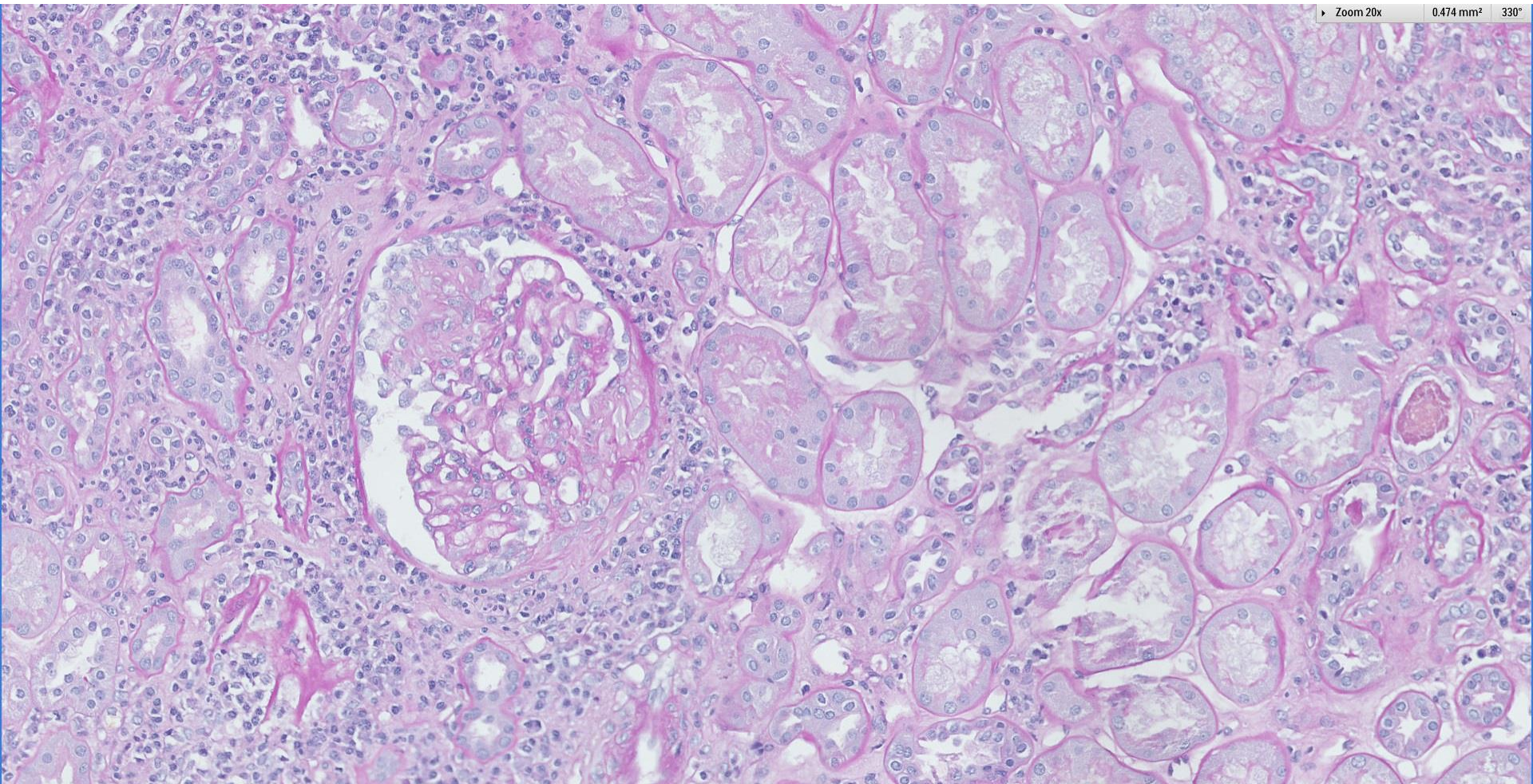


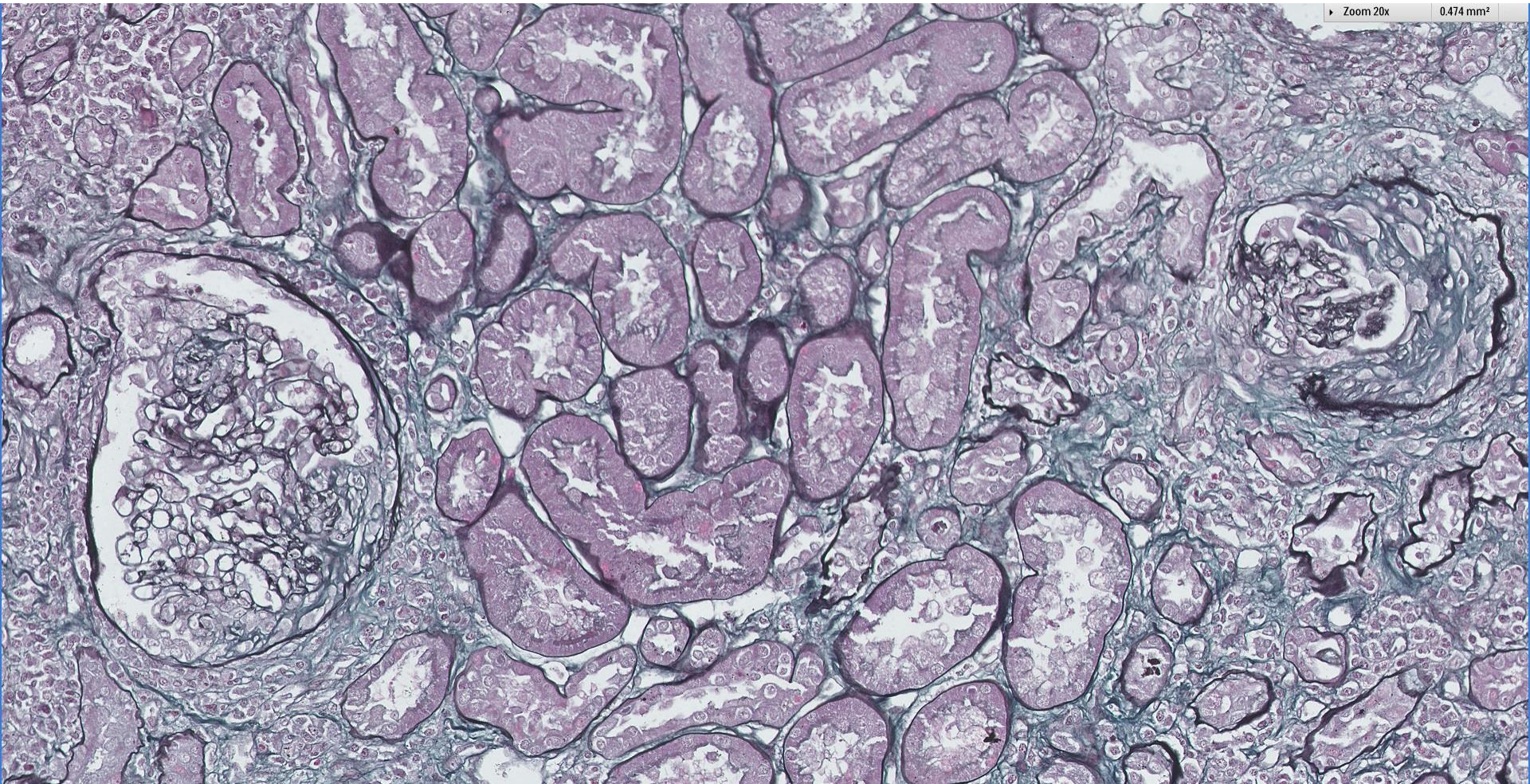
Case 51

52 year old Chinese gentleman with diabetes presented with the nephrotic-nephritic syndrome. Anti-MPO was positive.

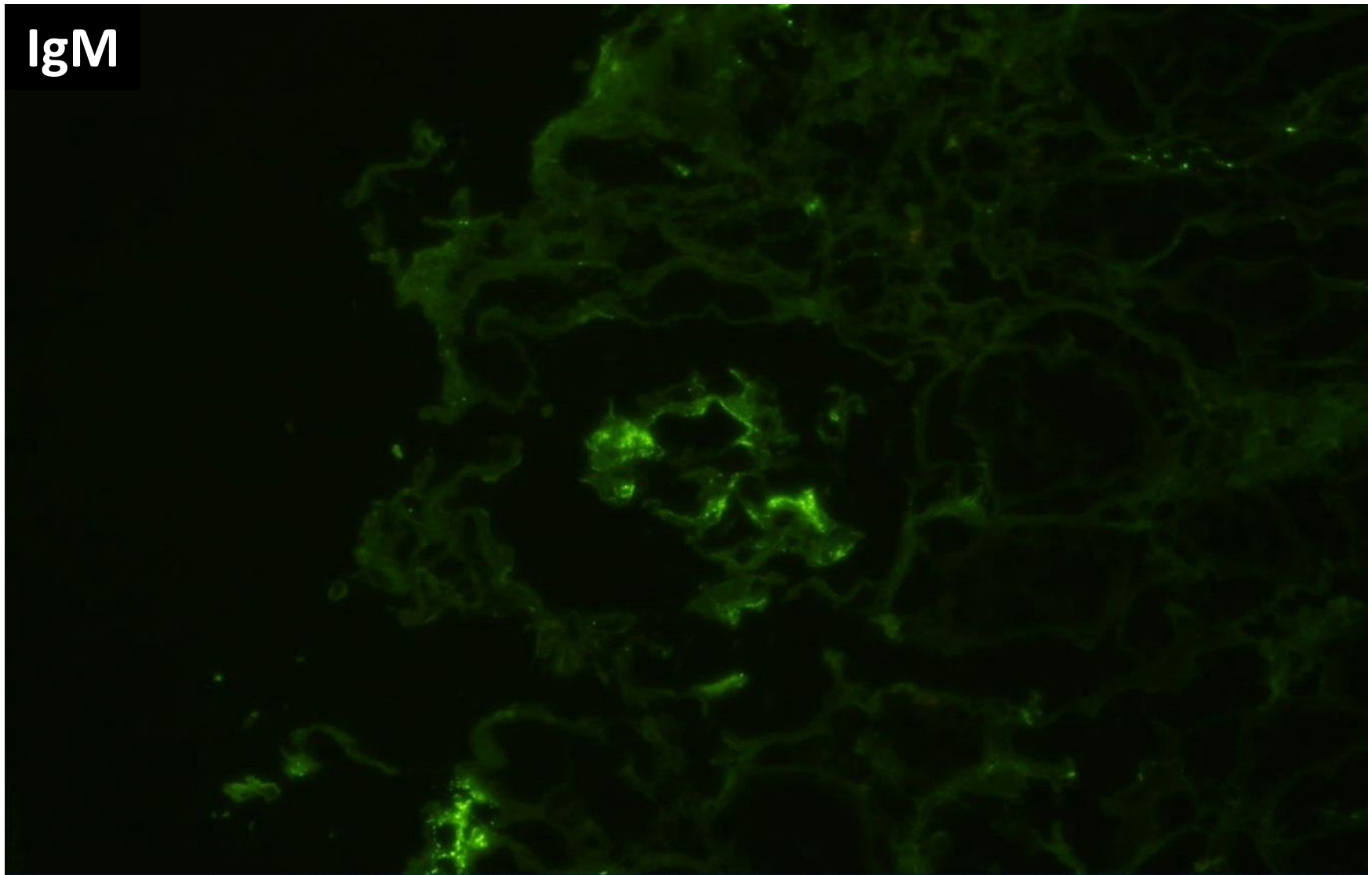




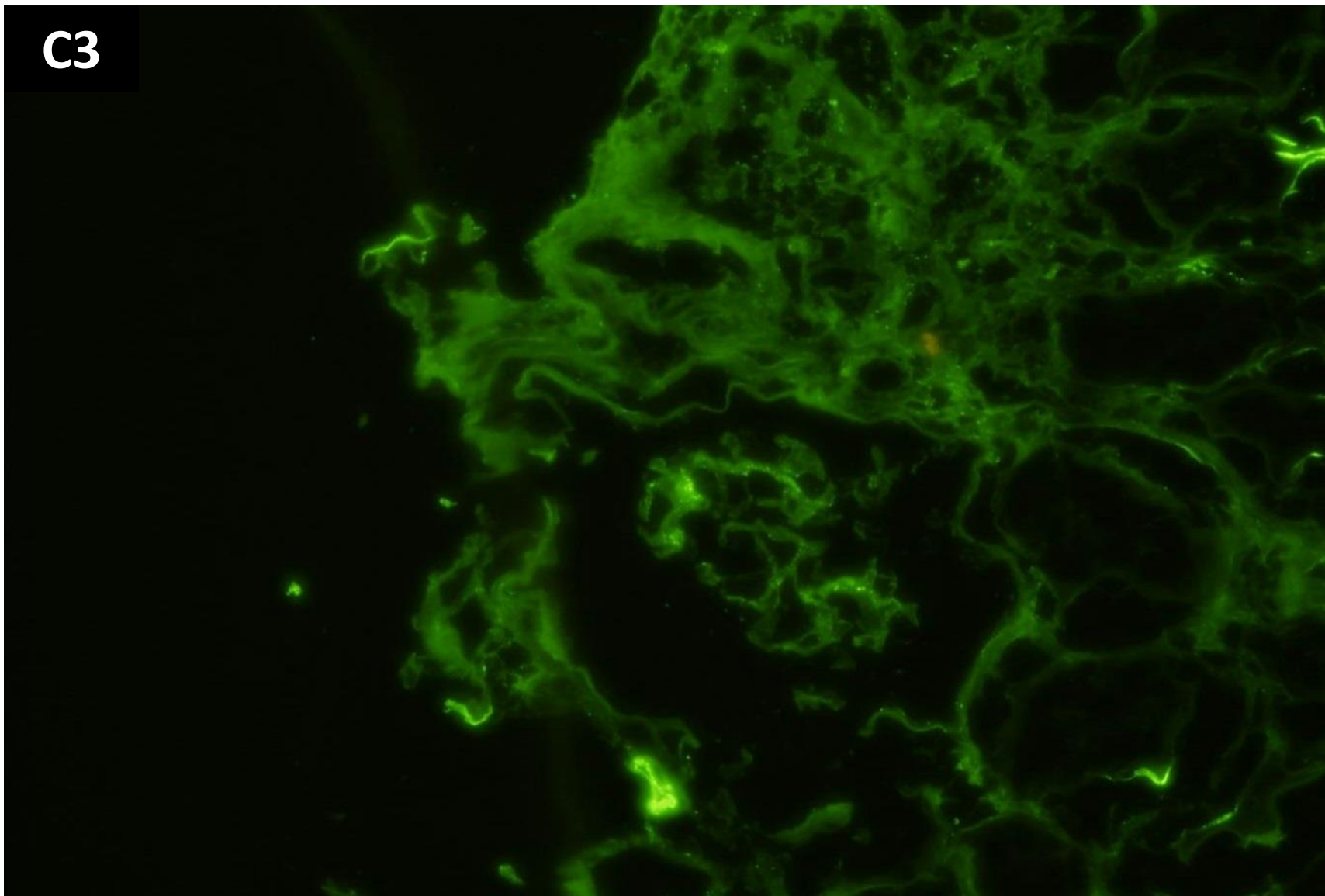




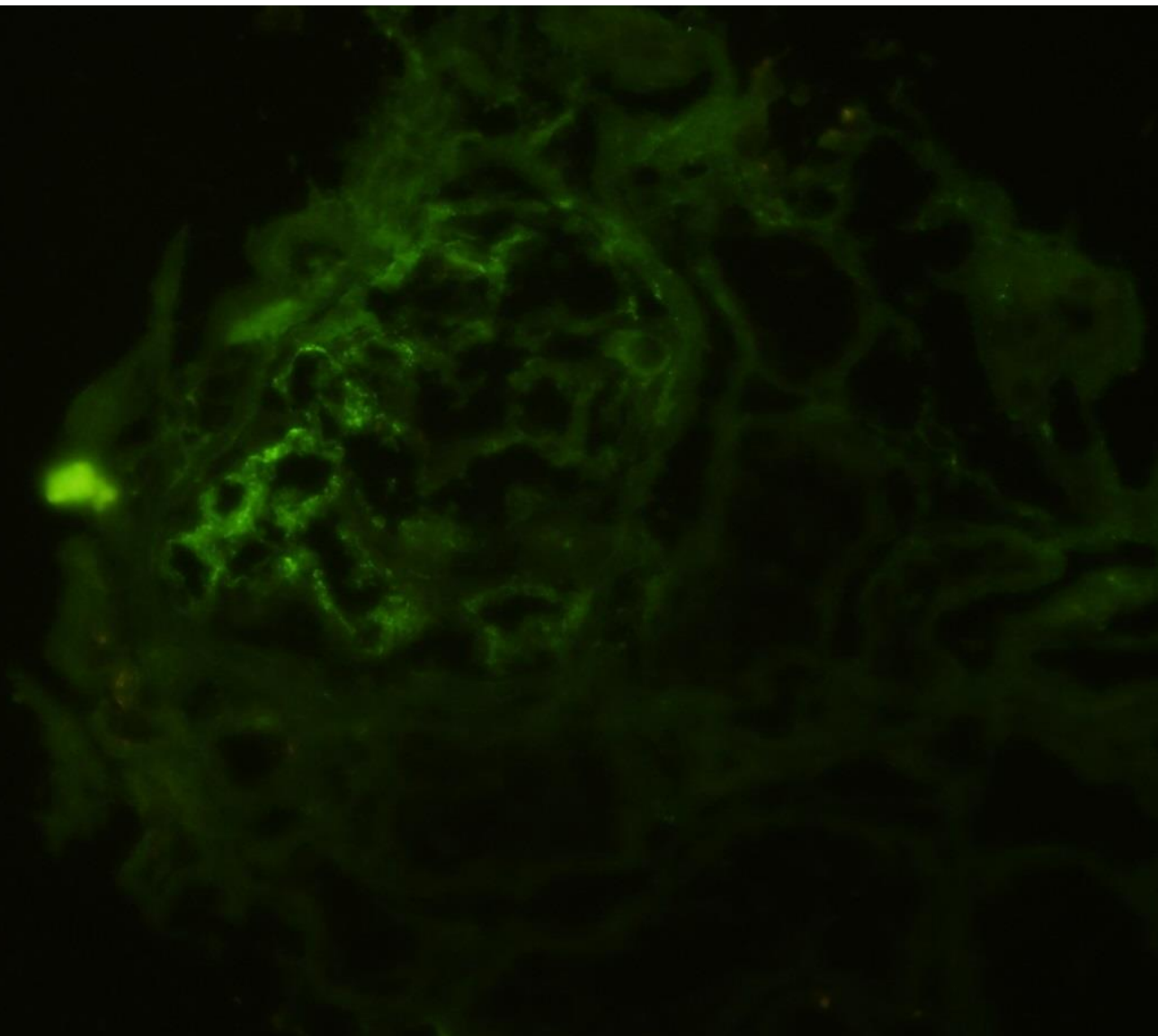
IgM

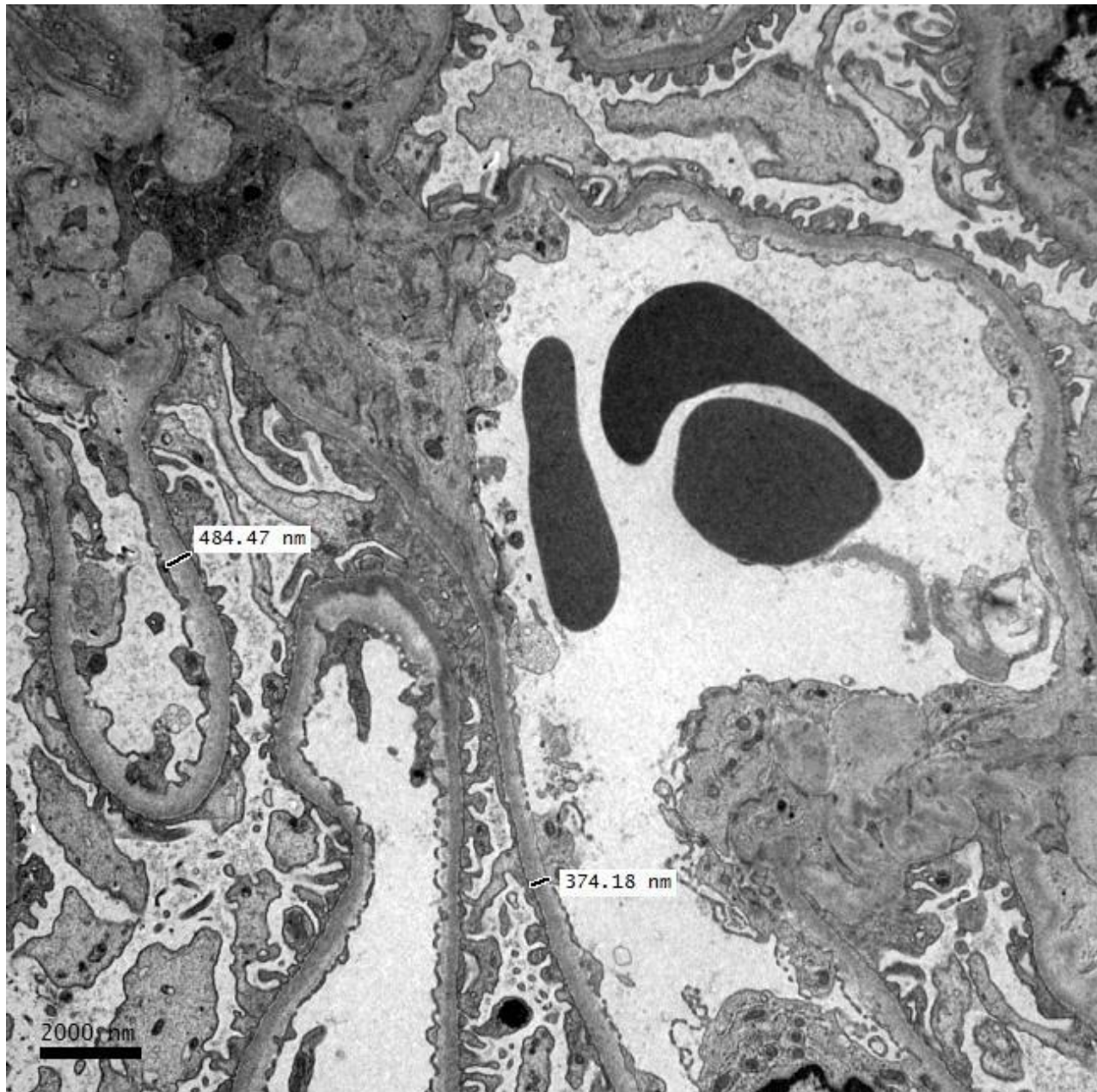


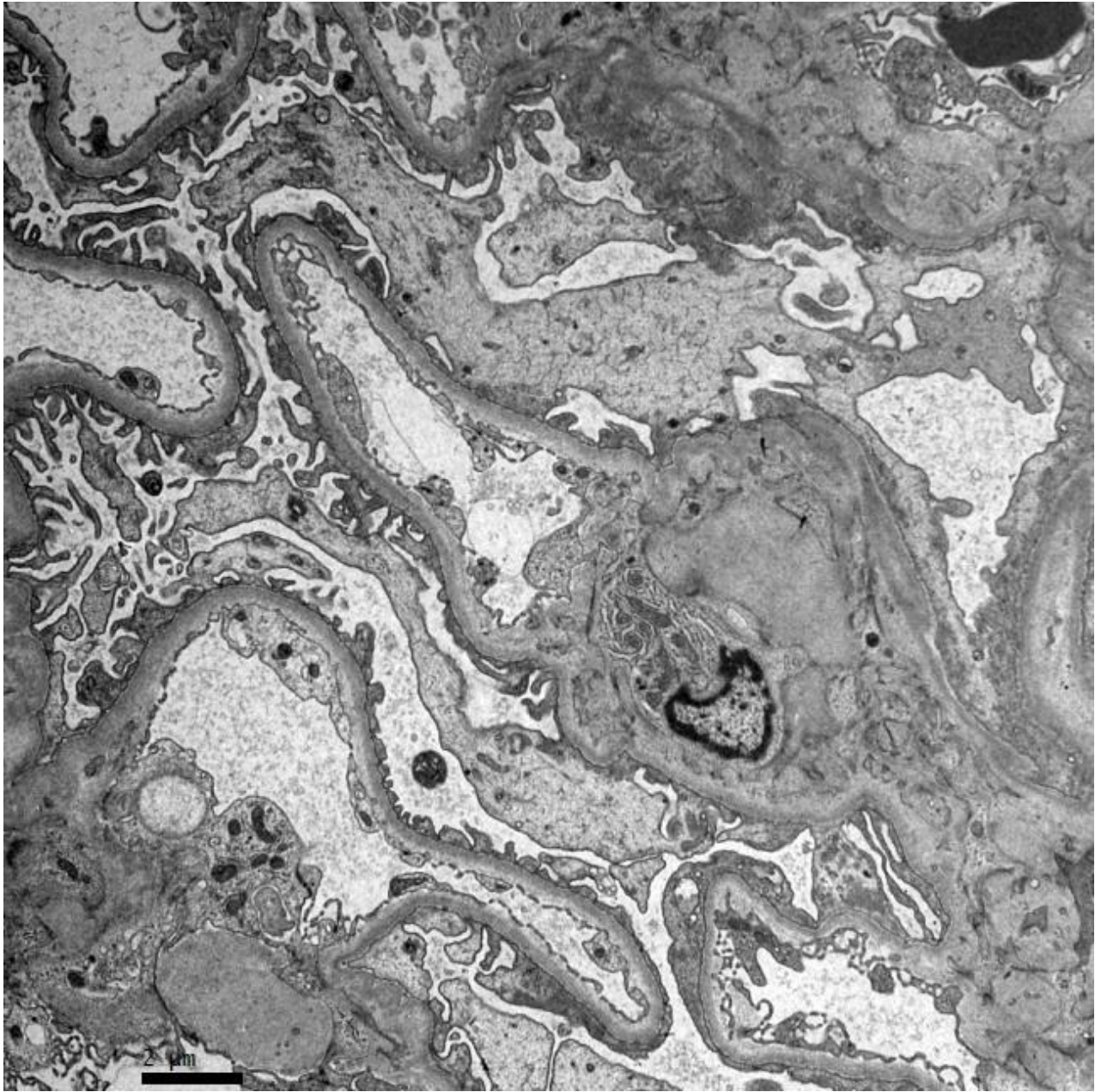
C3



C1q









RENAL BIOPSY CLINICOPATHOLOGICAL WORKSHOP 2018



PATHOLOGY



Division of Pathology
Singapore General Hospital



Department of Renal Medicine
Singapore General Hospital



MEDICINE