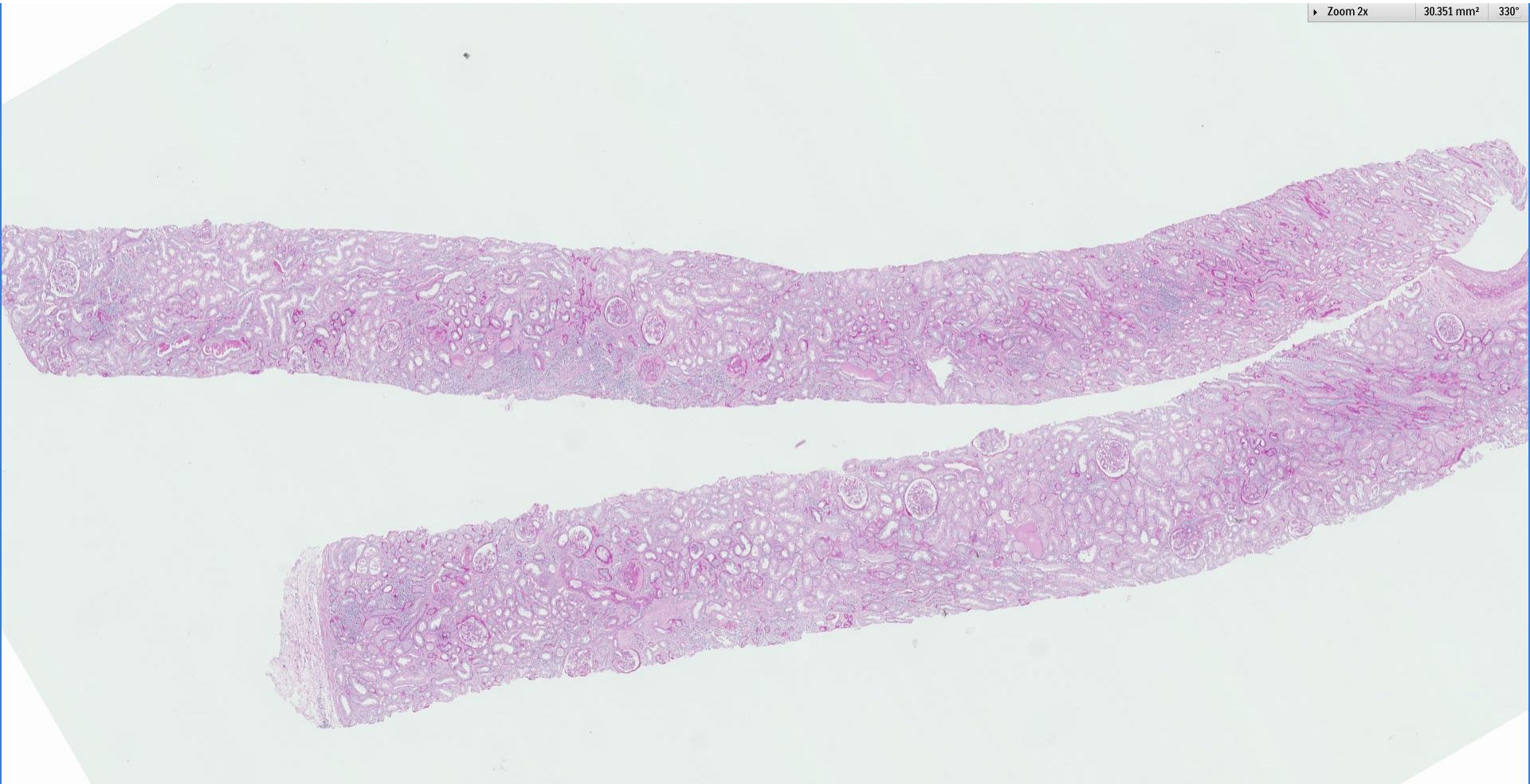
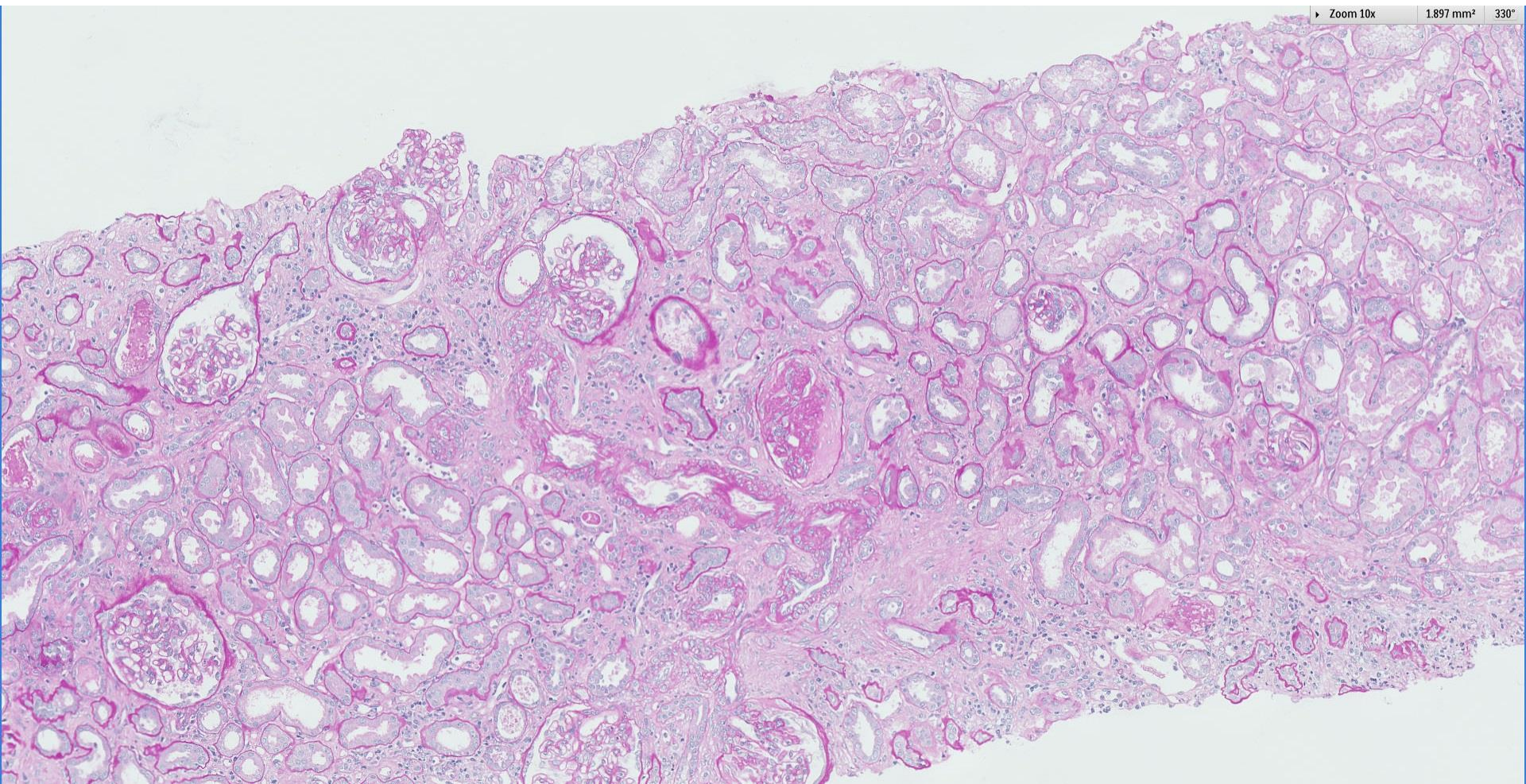
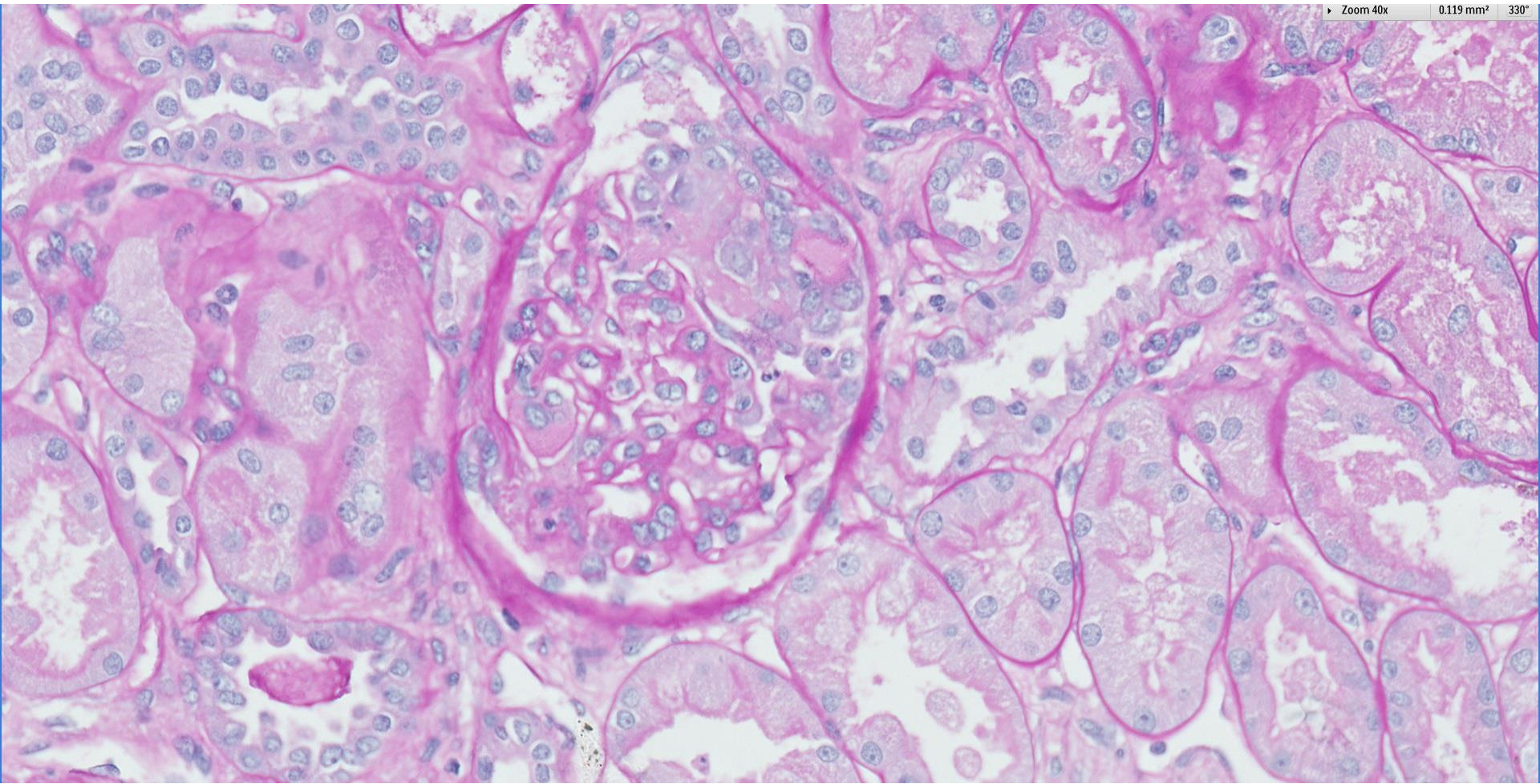


## *Case 50*

48 year old Chinese gentleman with long standing hypertension for more than 10 years, previously well controlled. Presented with hypertensive urgency and AKI. Anti-MPO was positive.

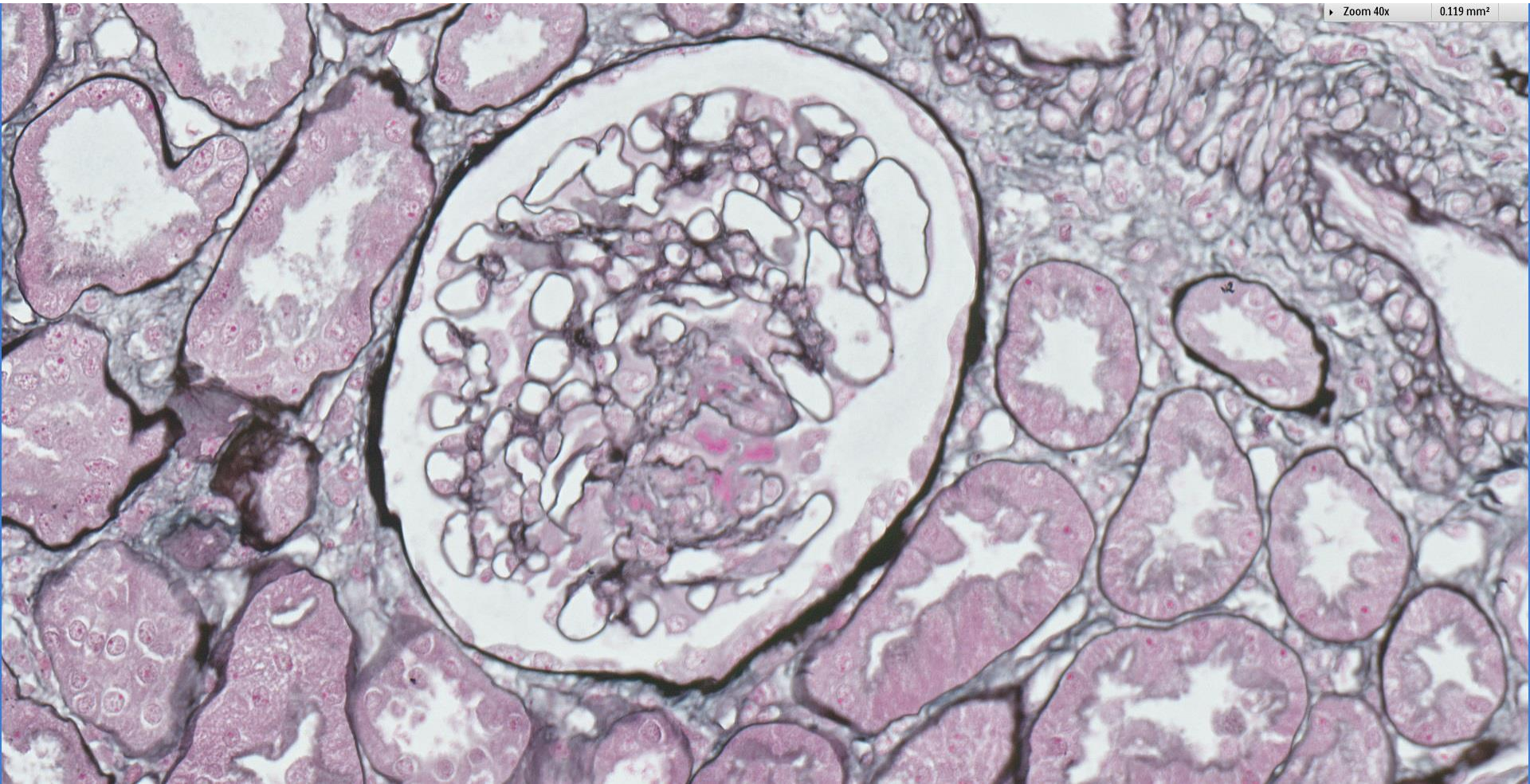




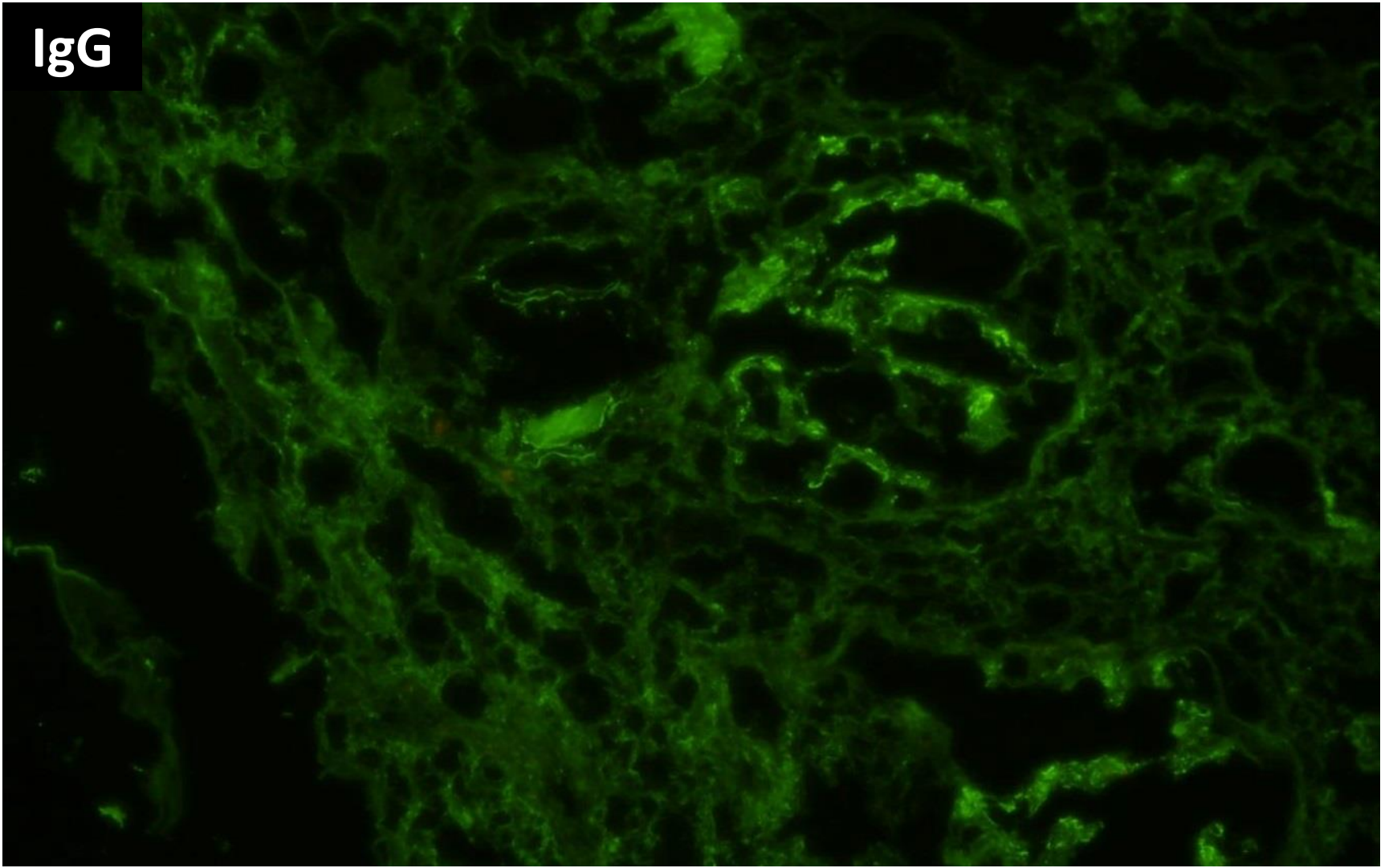


Zoom 40x

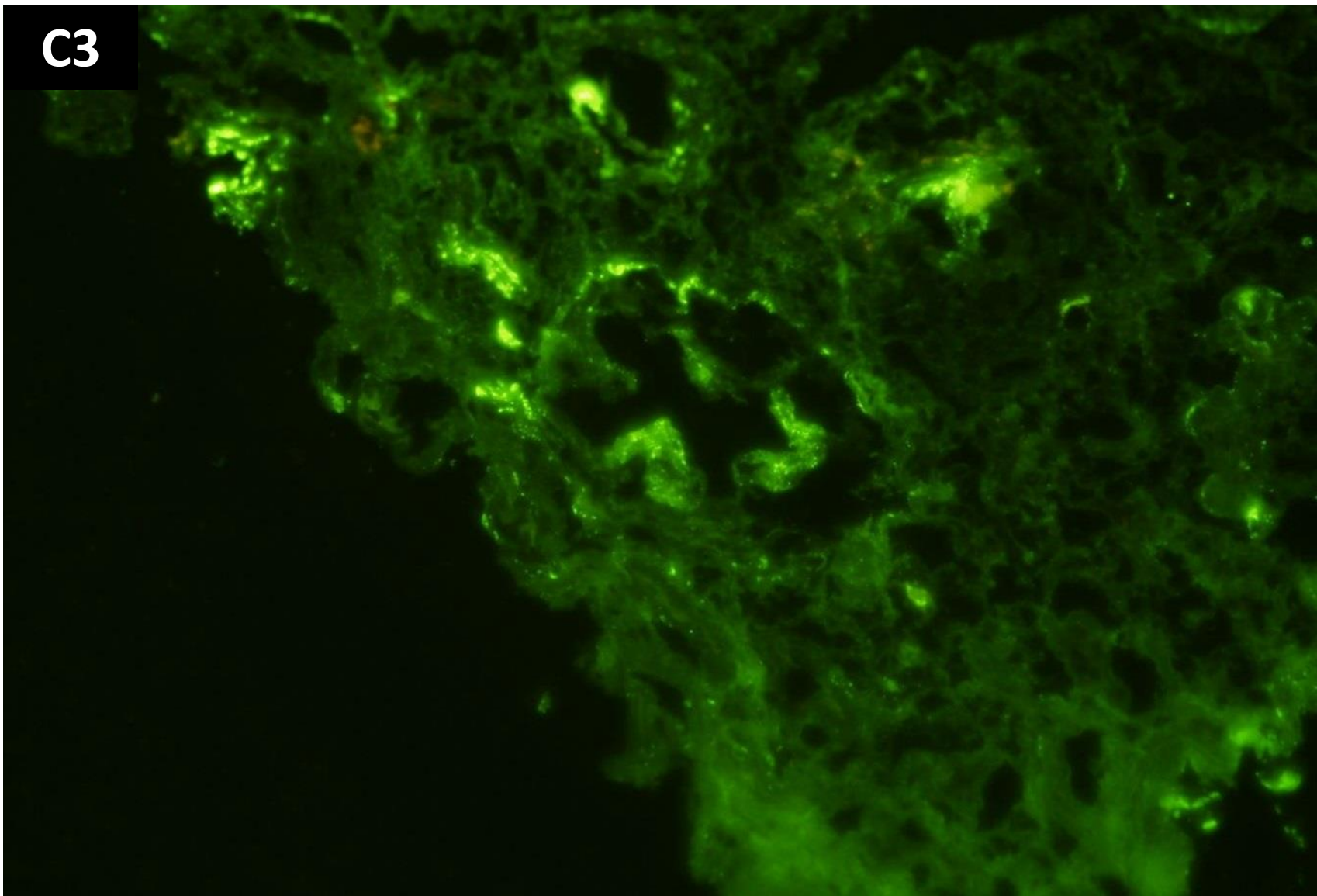
0.119 mm<sup>2</sup>

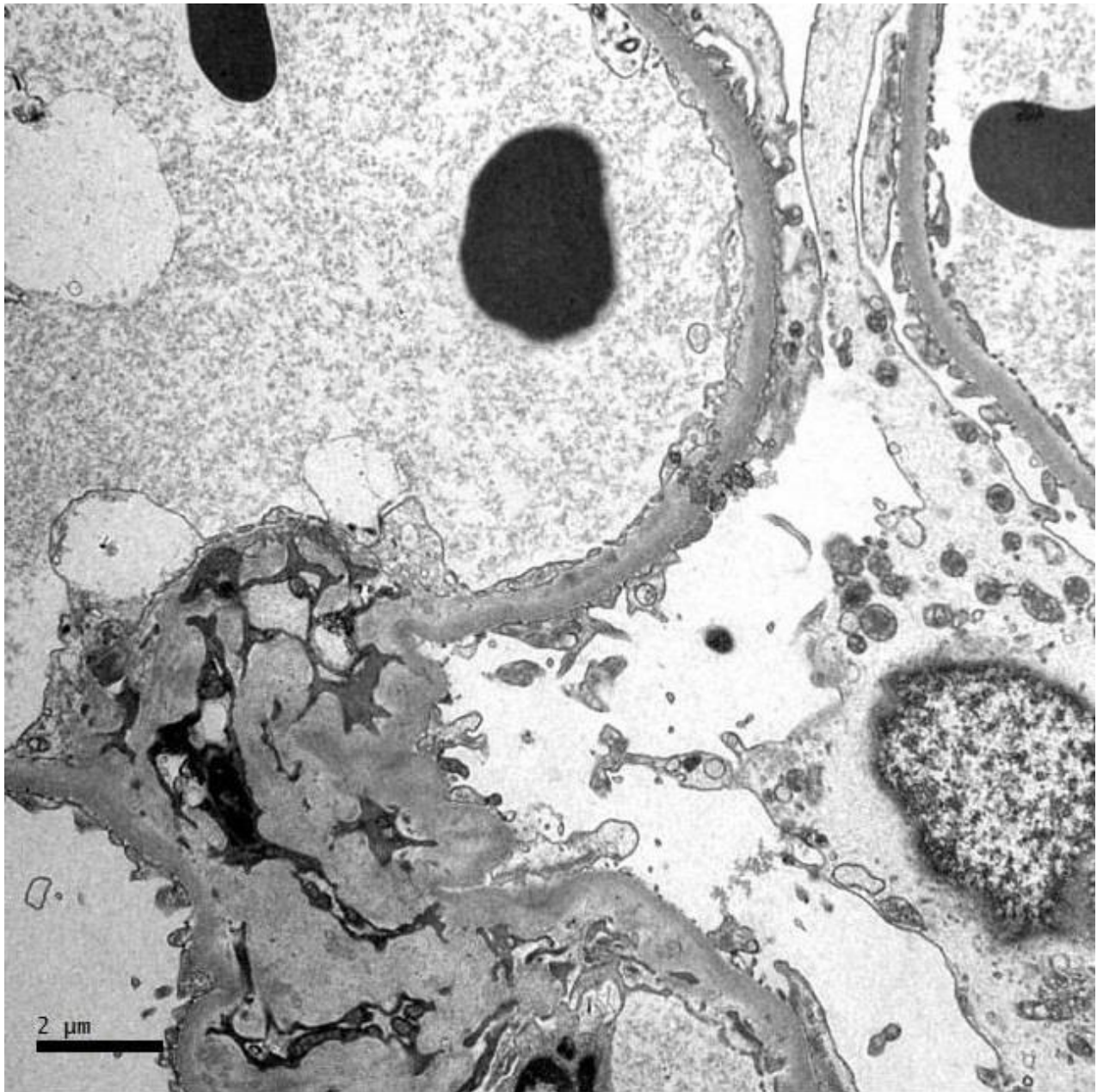


IgG

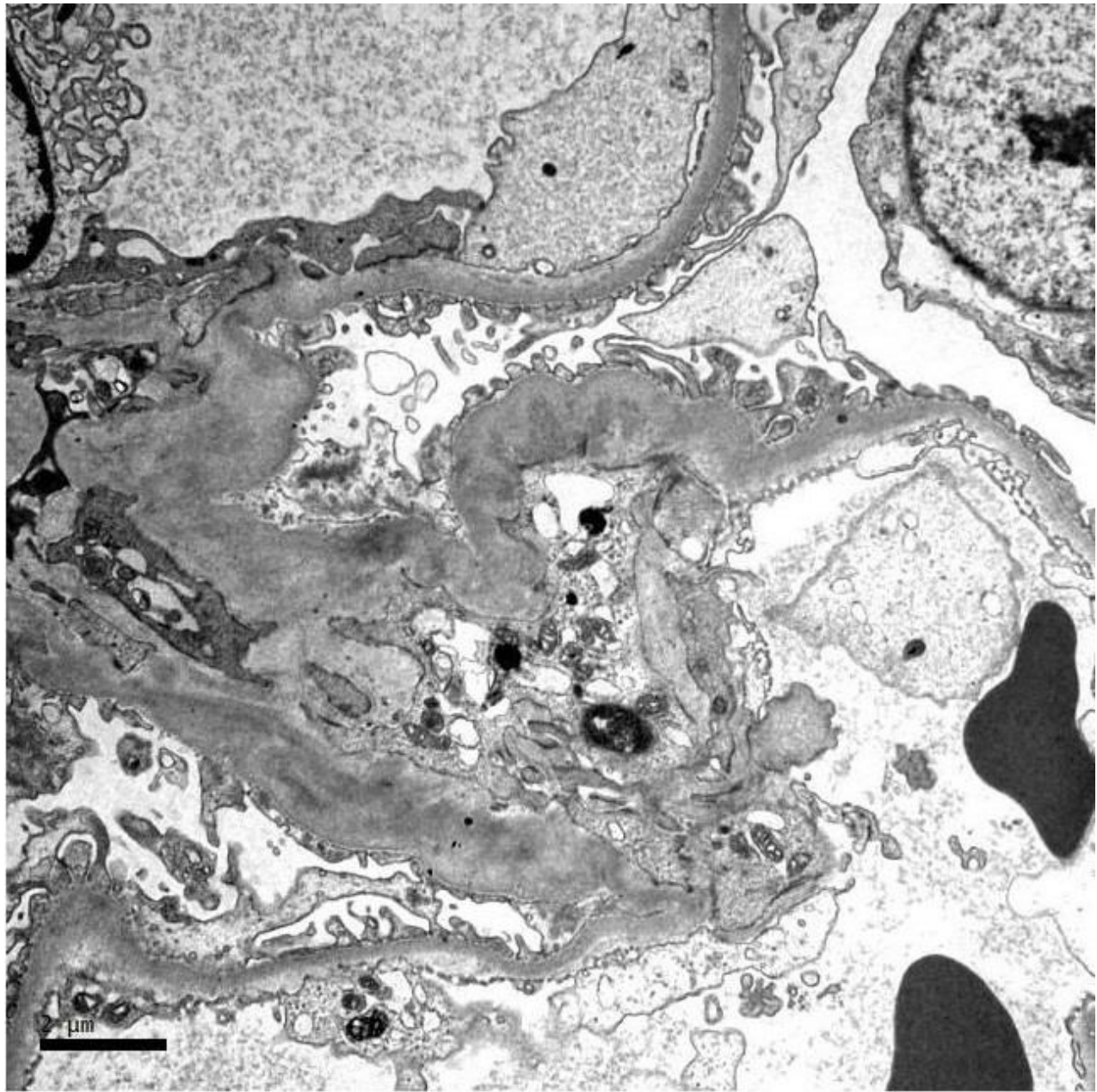


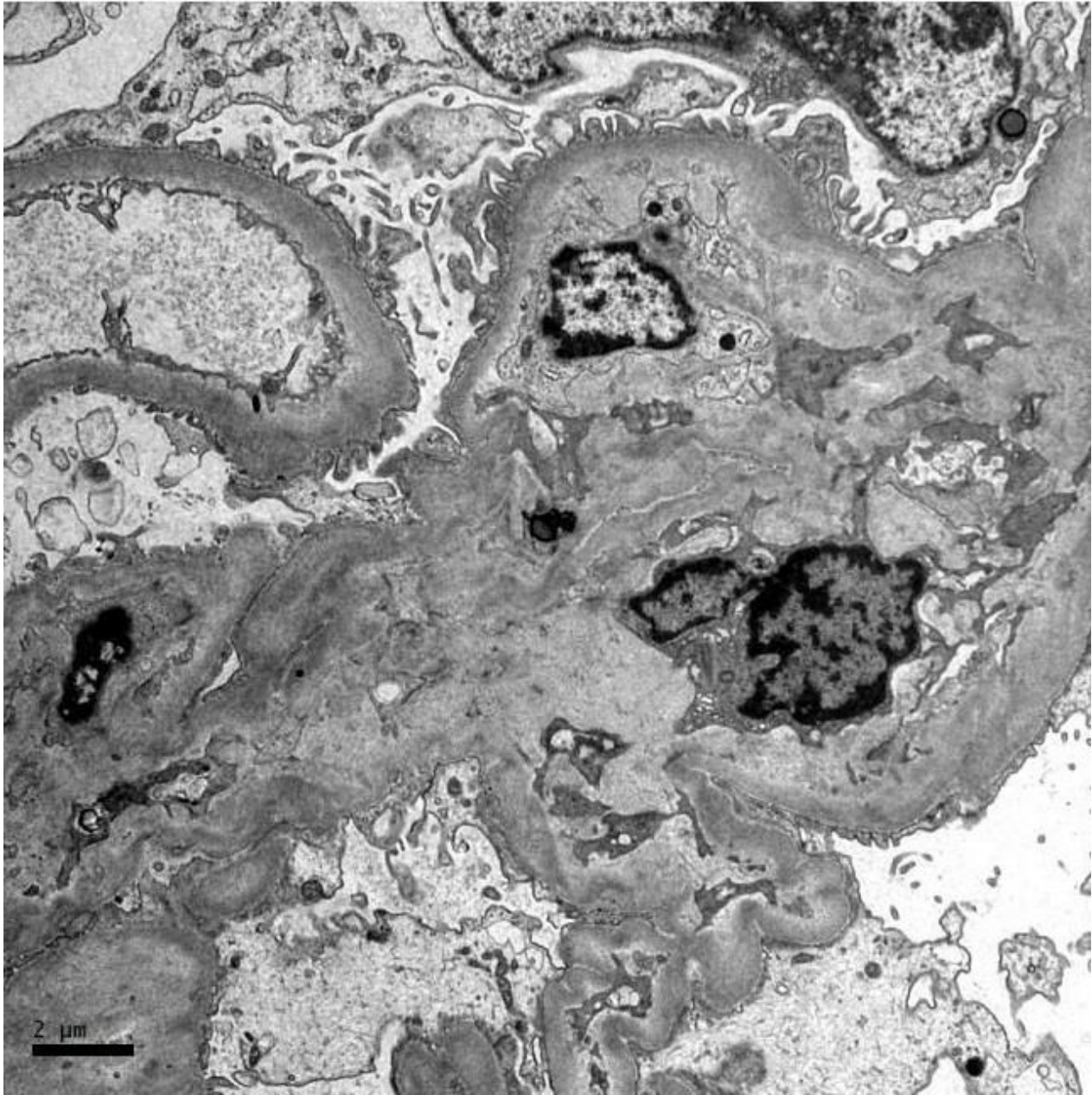
C3

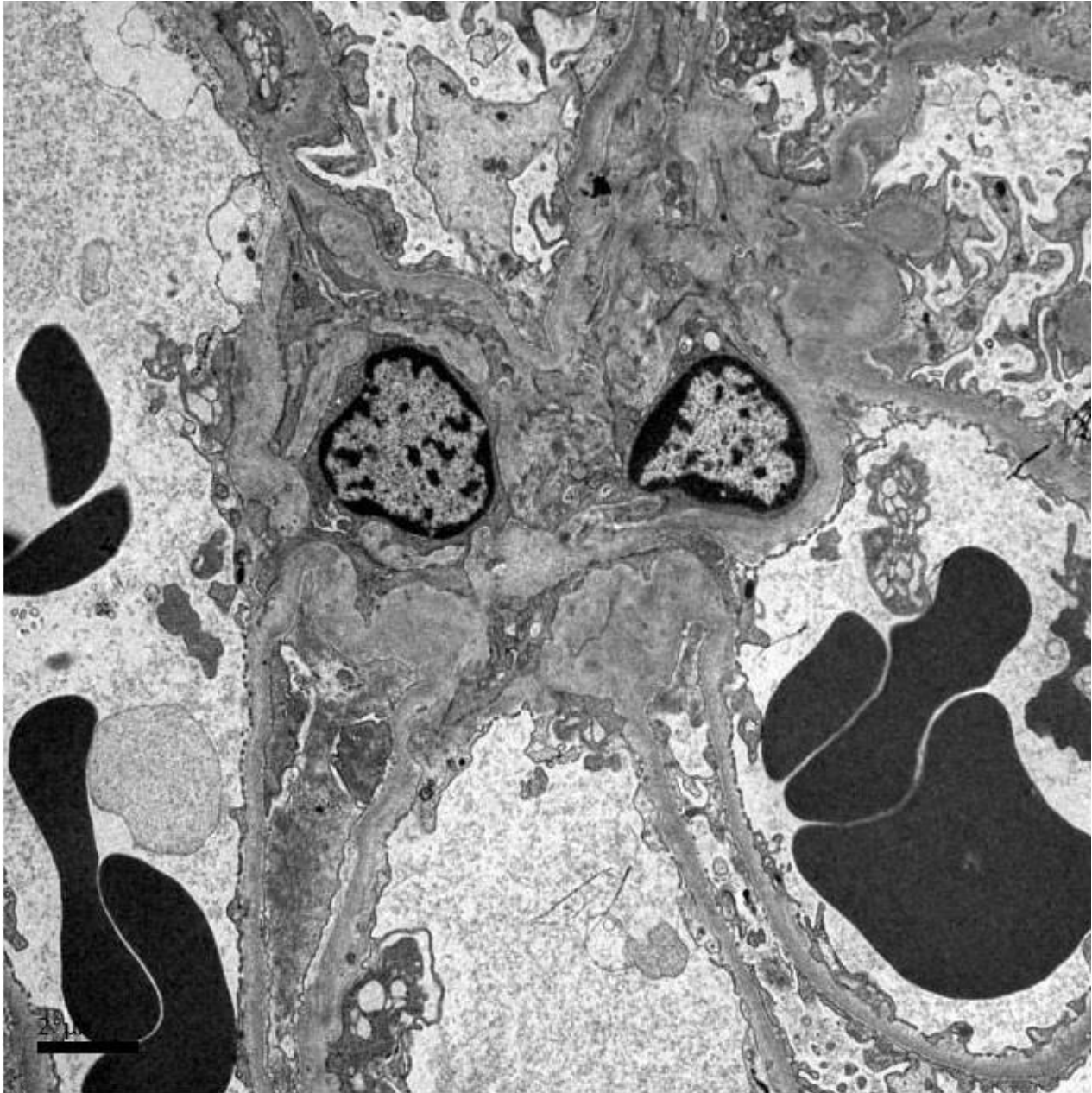


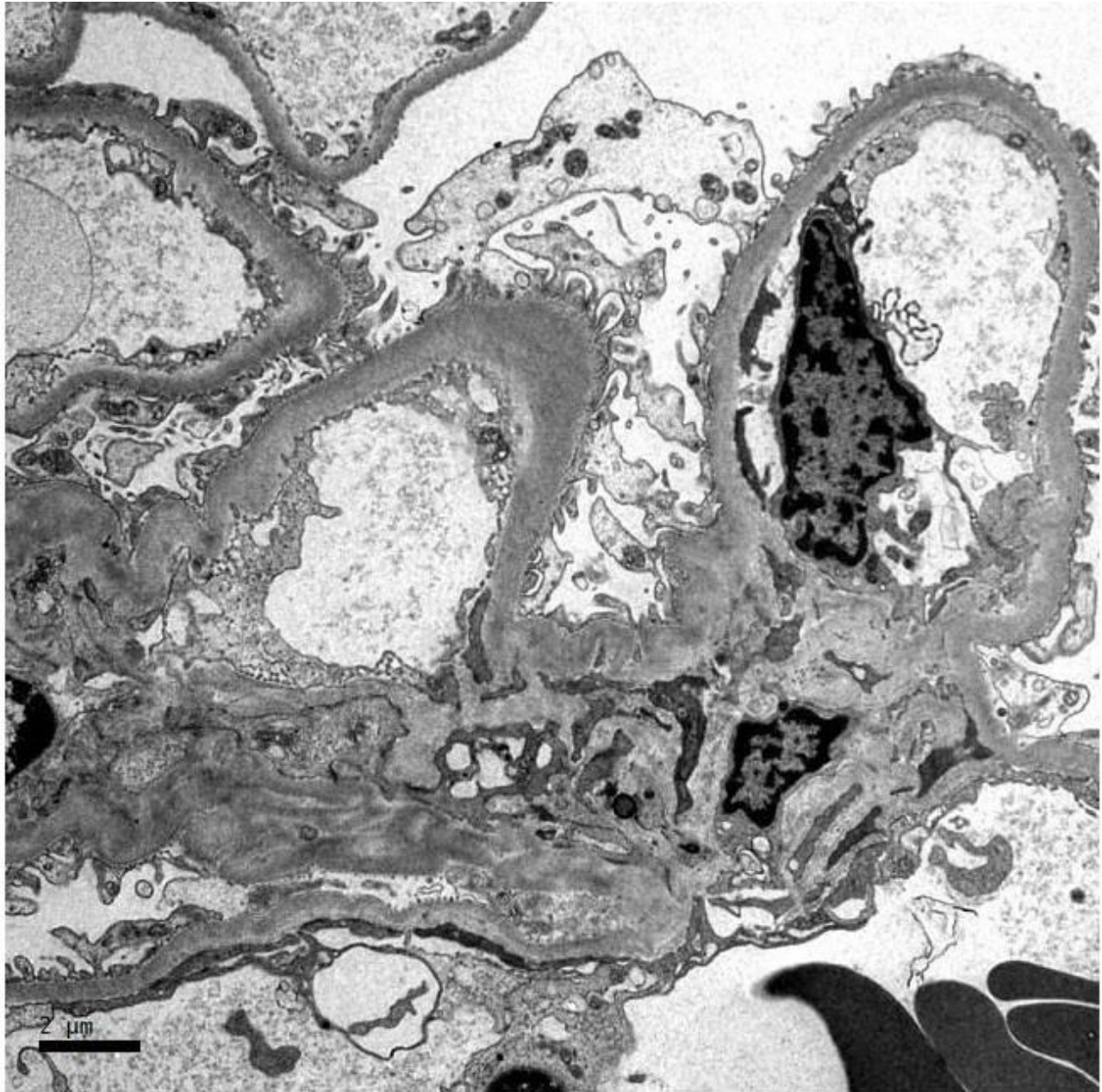














# RENAL BIOPSY CLINICOPATHOLOGICAL WORKSHOP 2018



**PATHOLOGY**



Division of Pathology  
Singapore General Hospital



Department of Renal Medicine  
Singapore General Hospital



**MEDICINE**