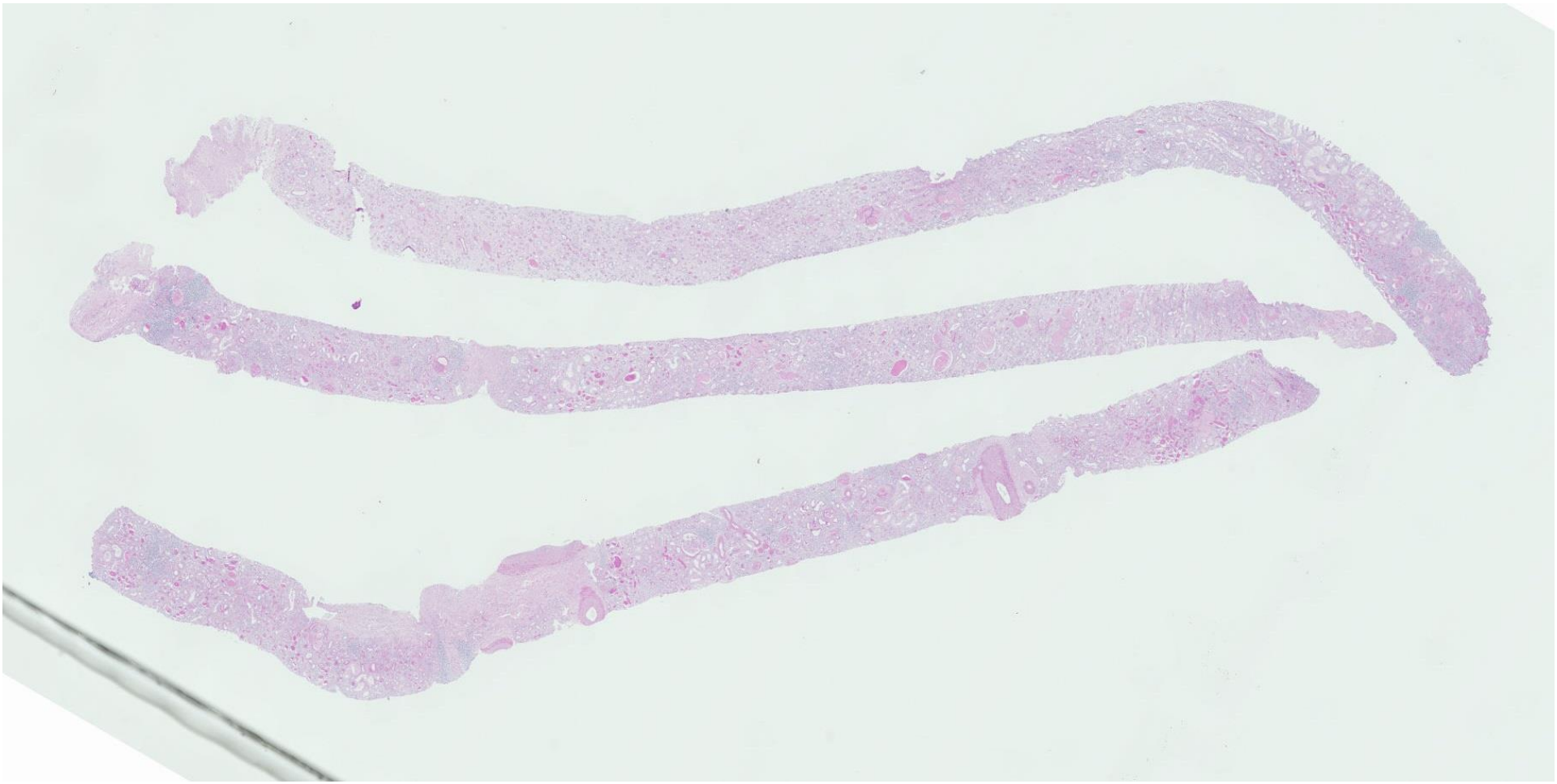
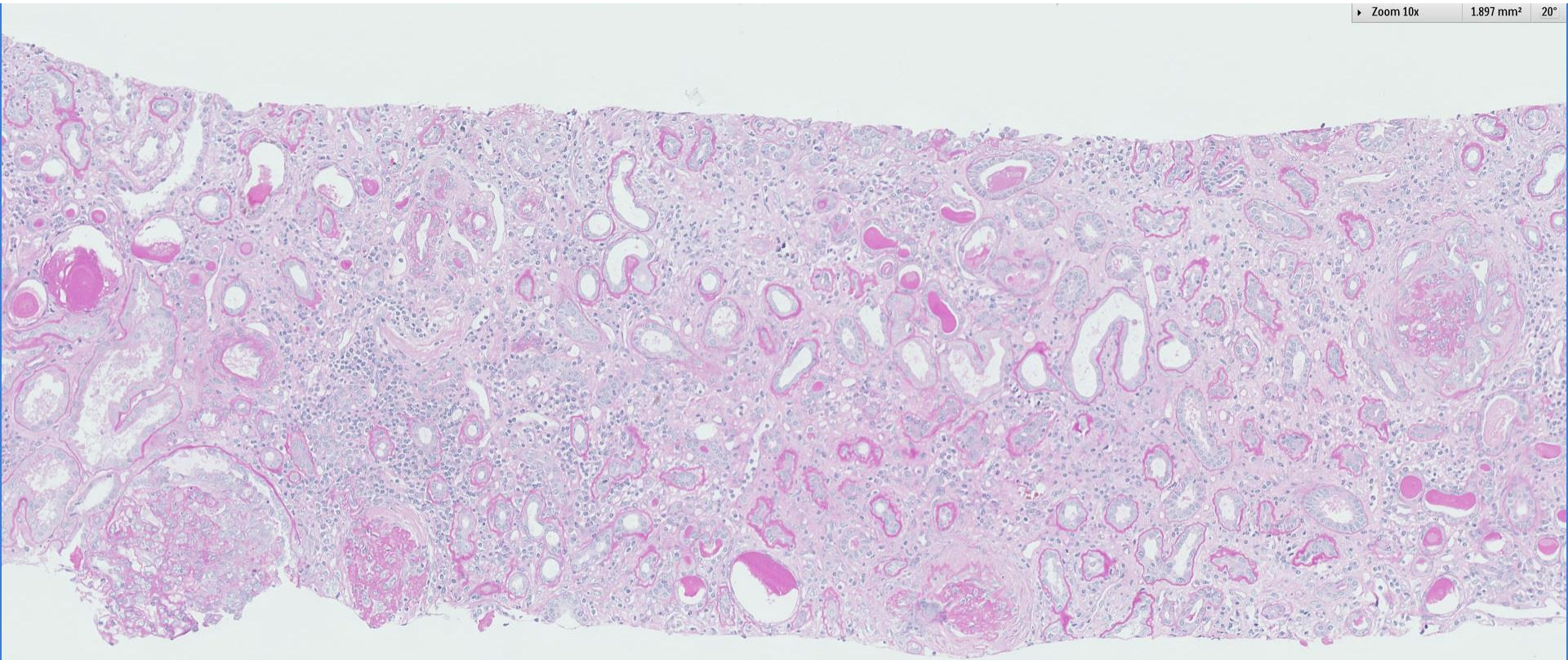
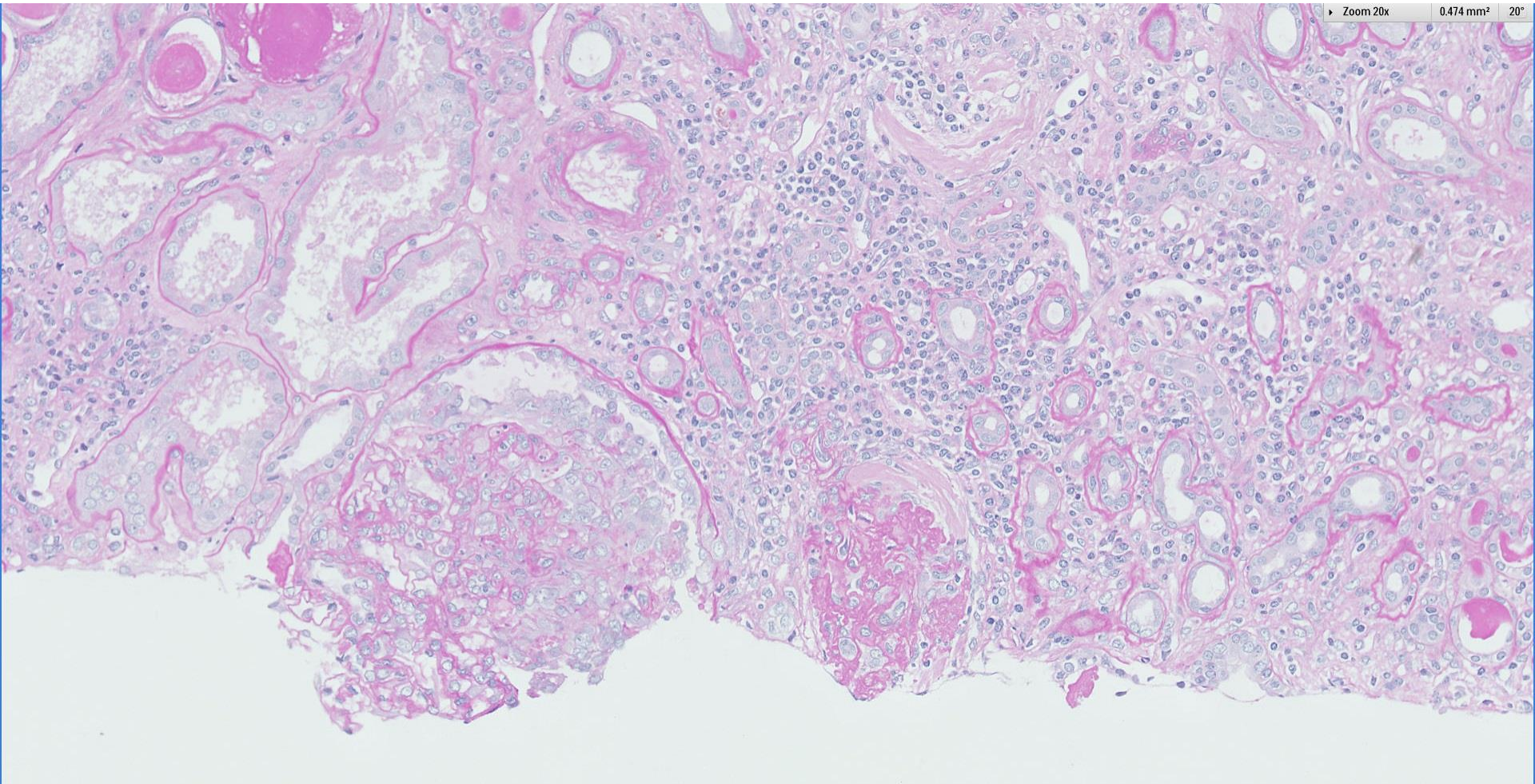


Case 49

52 year old Chinese gentleman with hypertension. Presented with nephrotic-nephritic syndrome. Anti-MPO was positive.

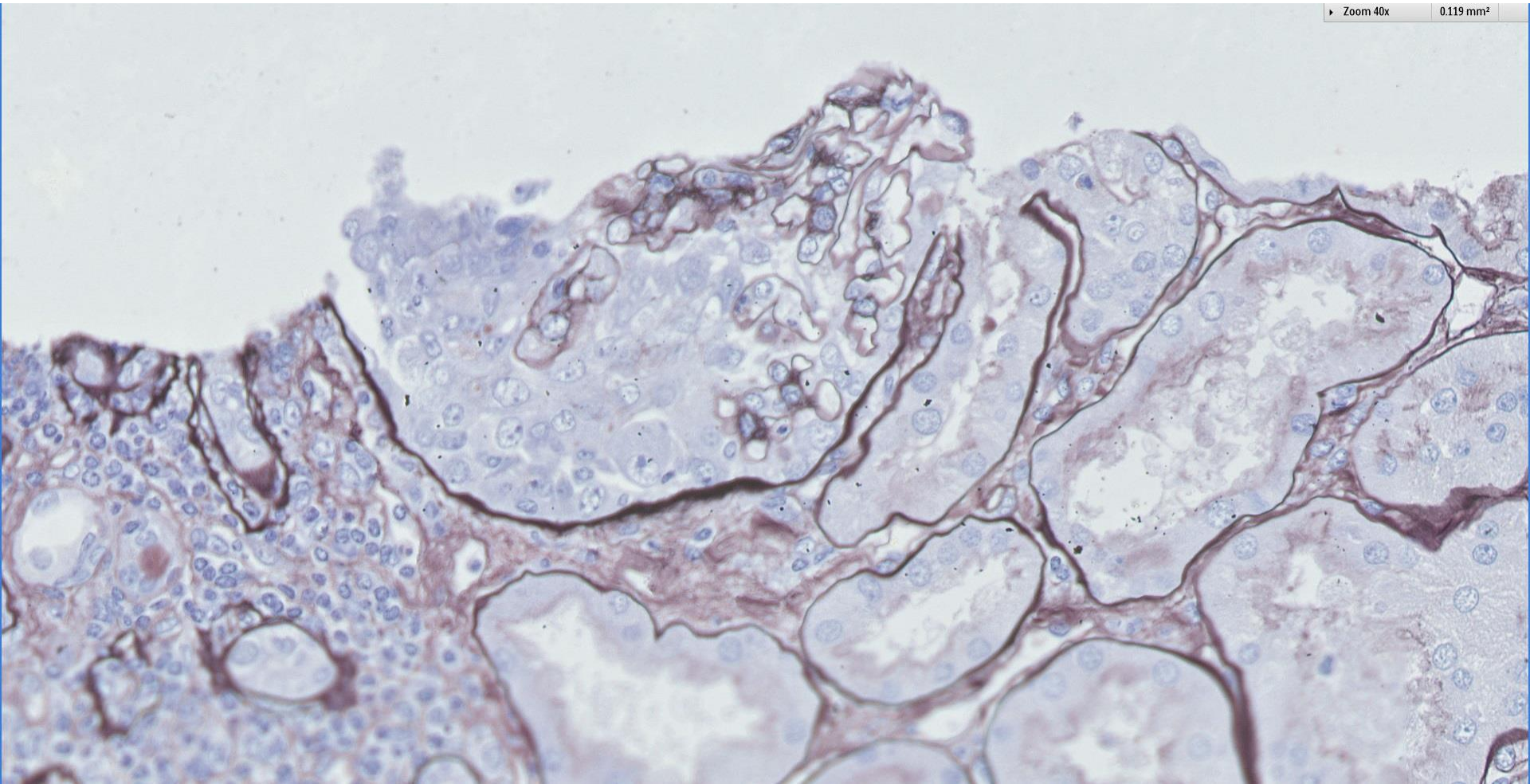




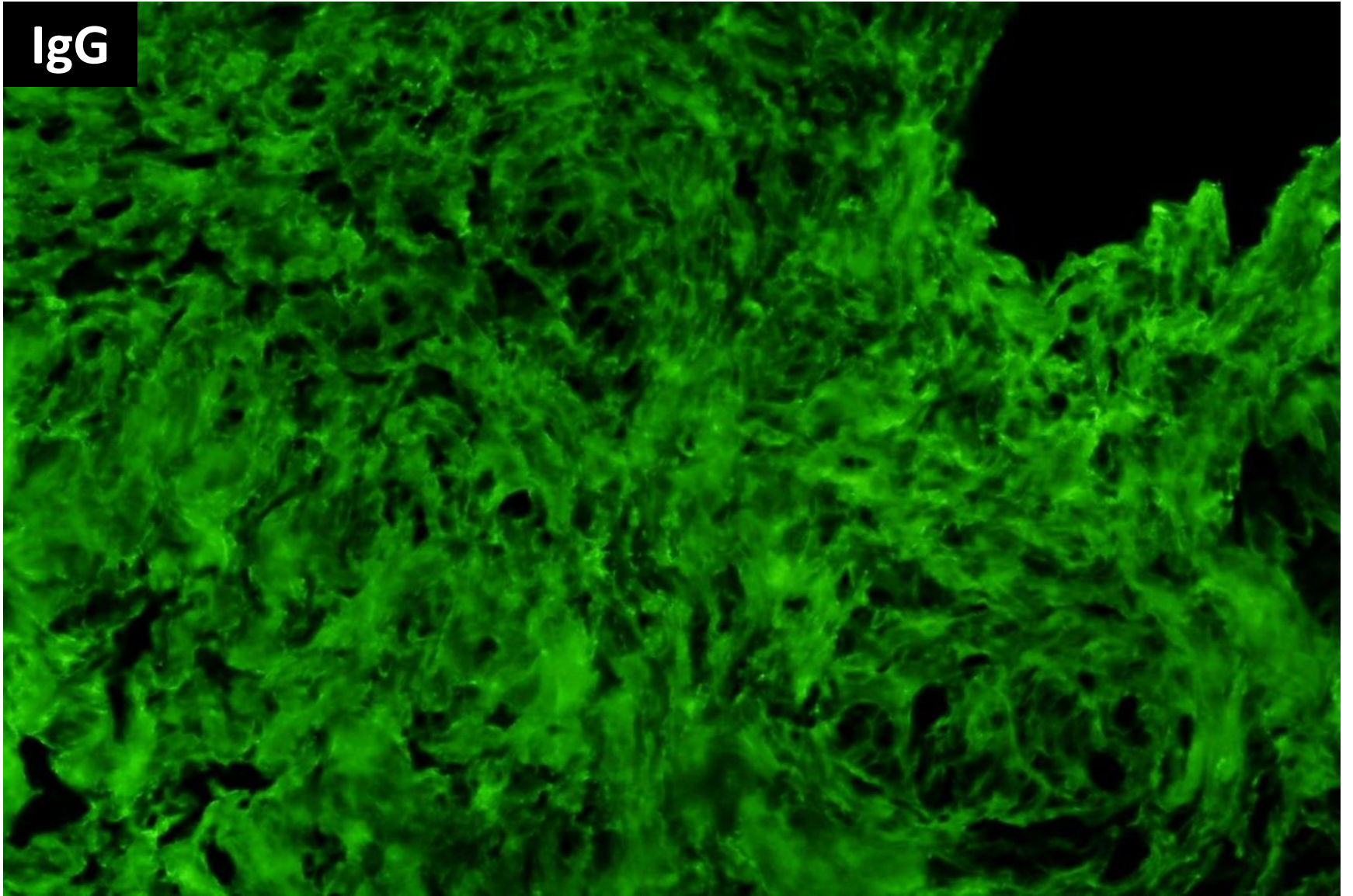


Zoom 40x

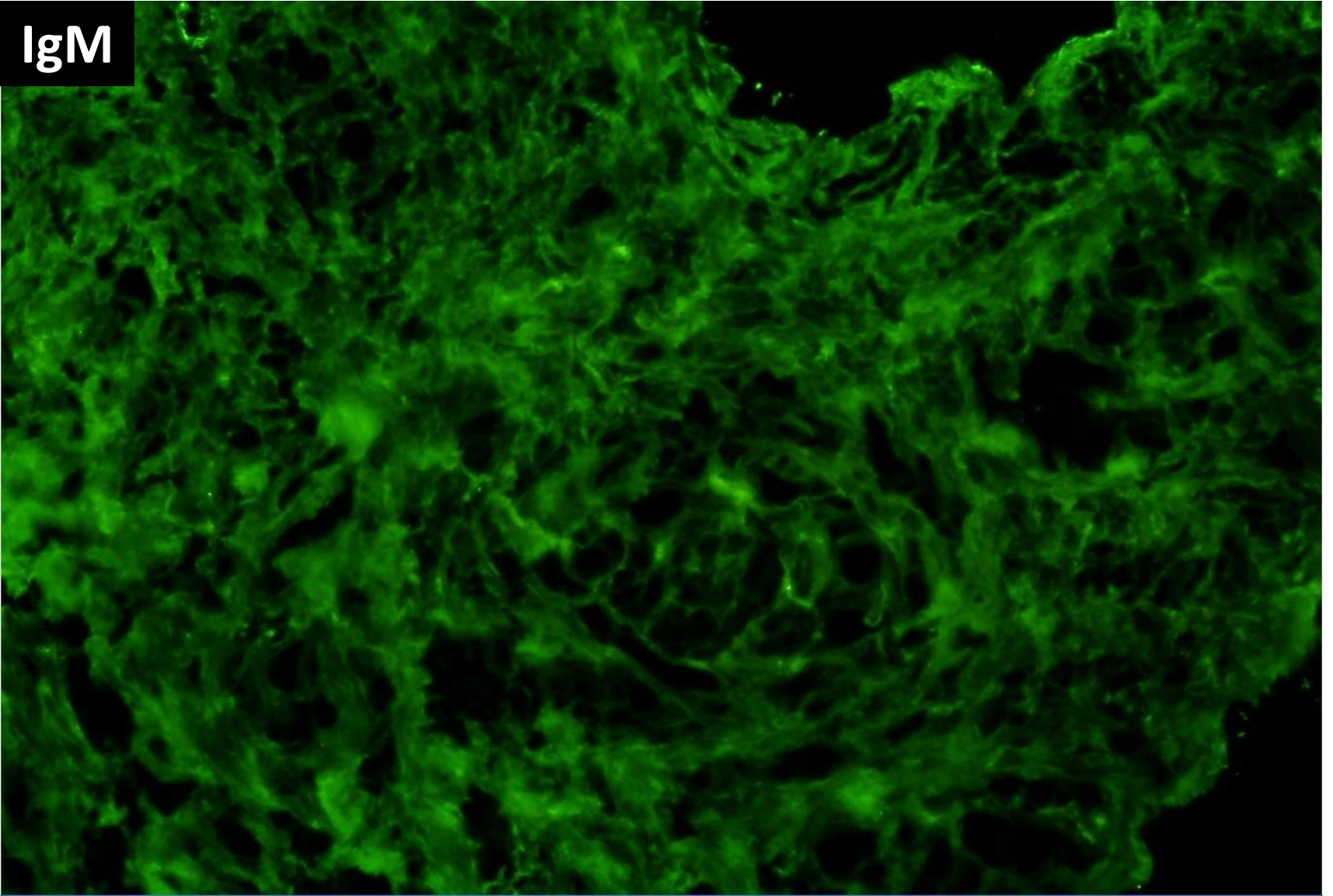
0.119 mm²



IgG



IgM



Tissue received for electron microscopy showed no
glomeruli.
Ultrastructural studies were not performed.



**RENAL BIOPSY
CLINICOPATHOLOGICAL
WORKSHOP 2018**



PATHOLOGY



Division of Pathology
Singapore General Hospital



Department of Renal Medicine
Singapore General Hospital



MEDICINE