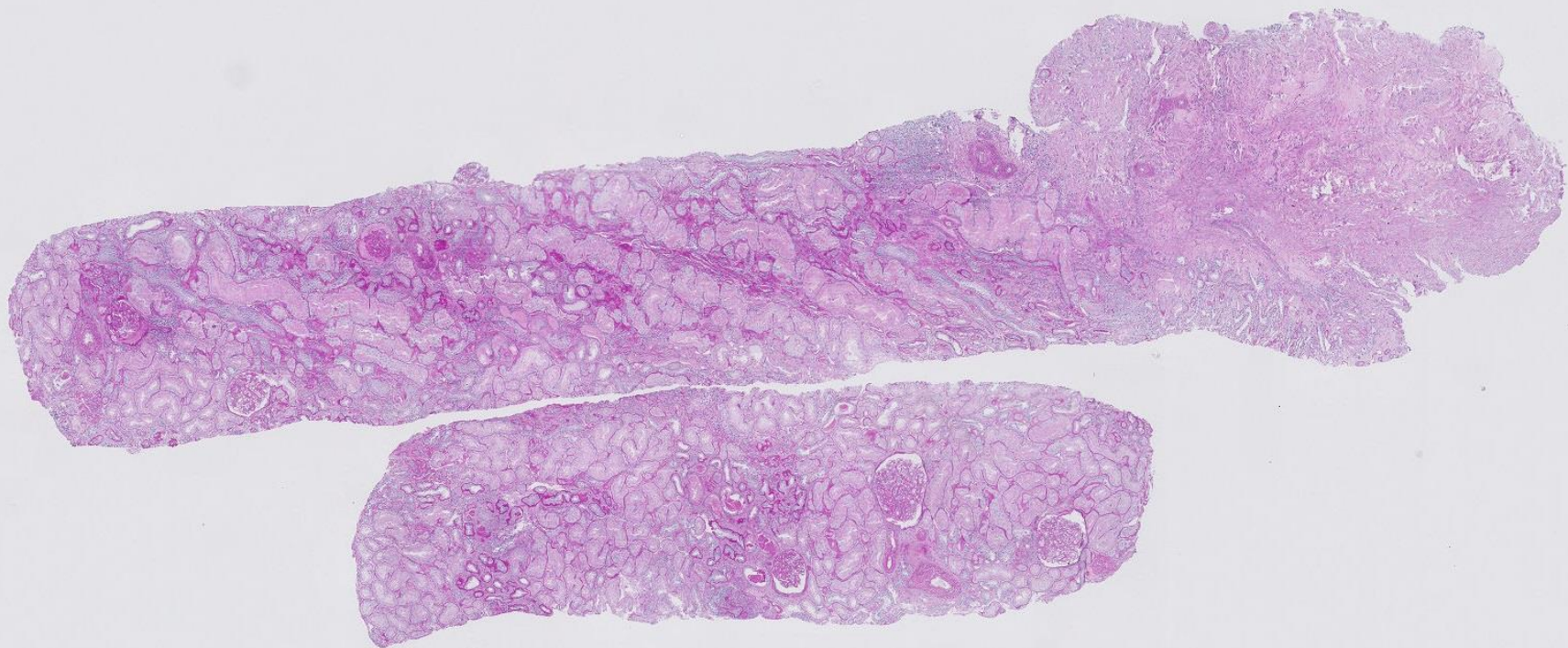


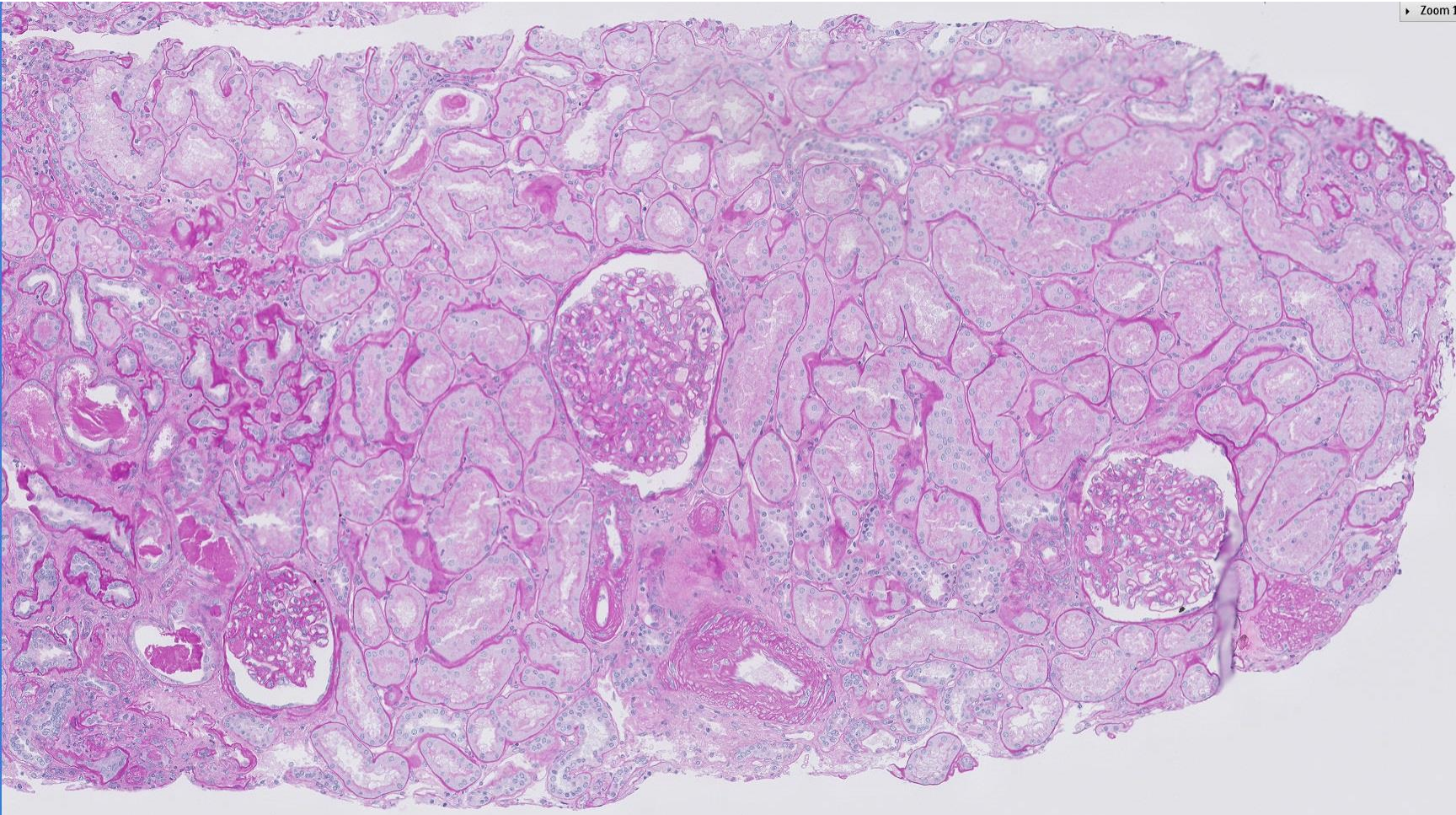
Case 45

33 year old female with lower limb rash, gross haematuria
and acute kidney injury.



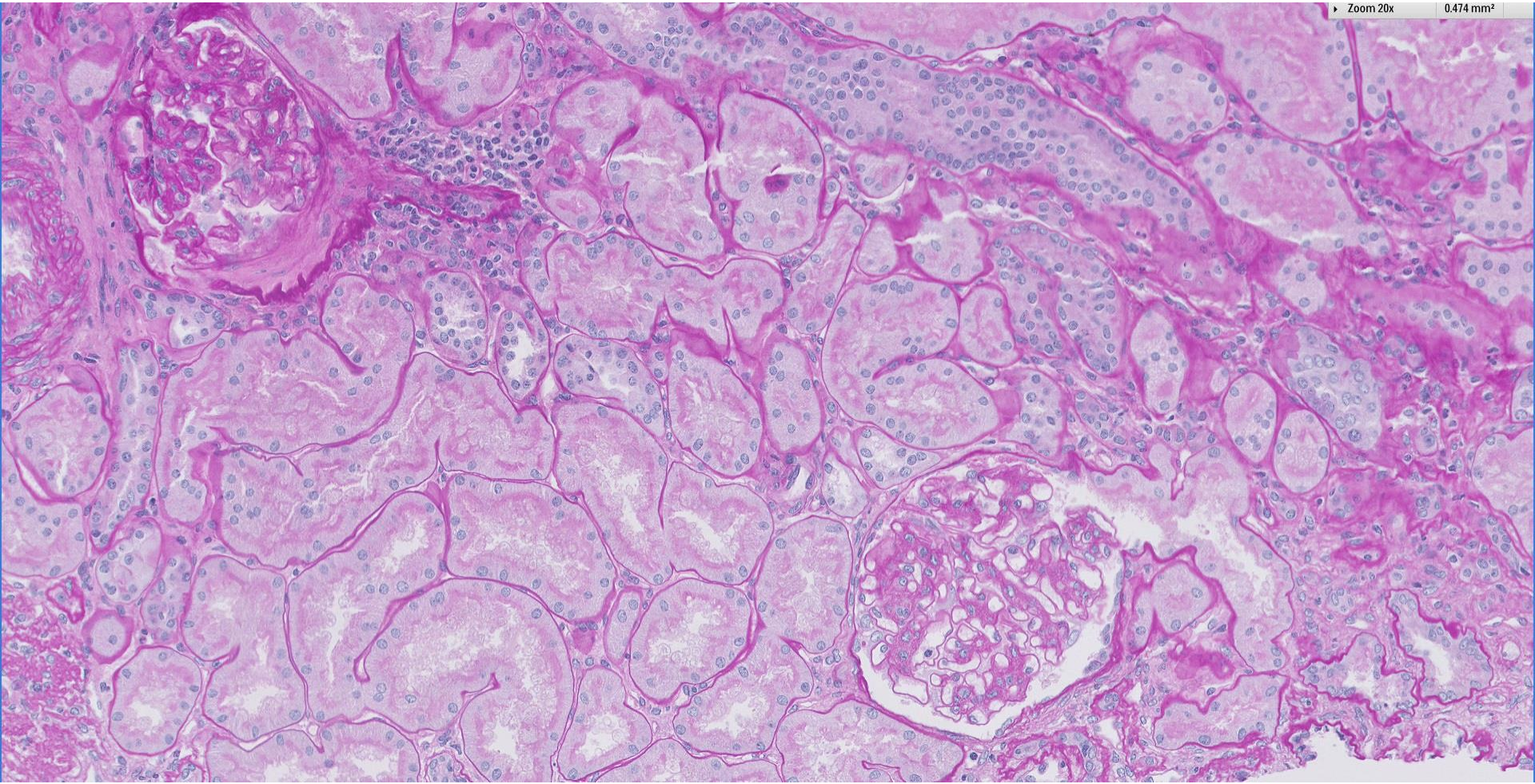
Zoom 10x

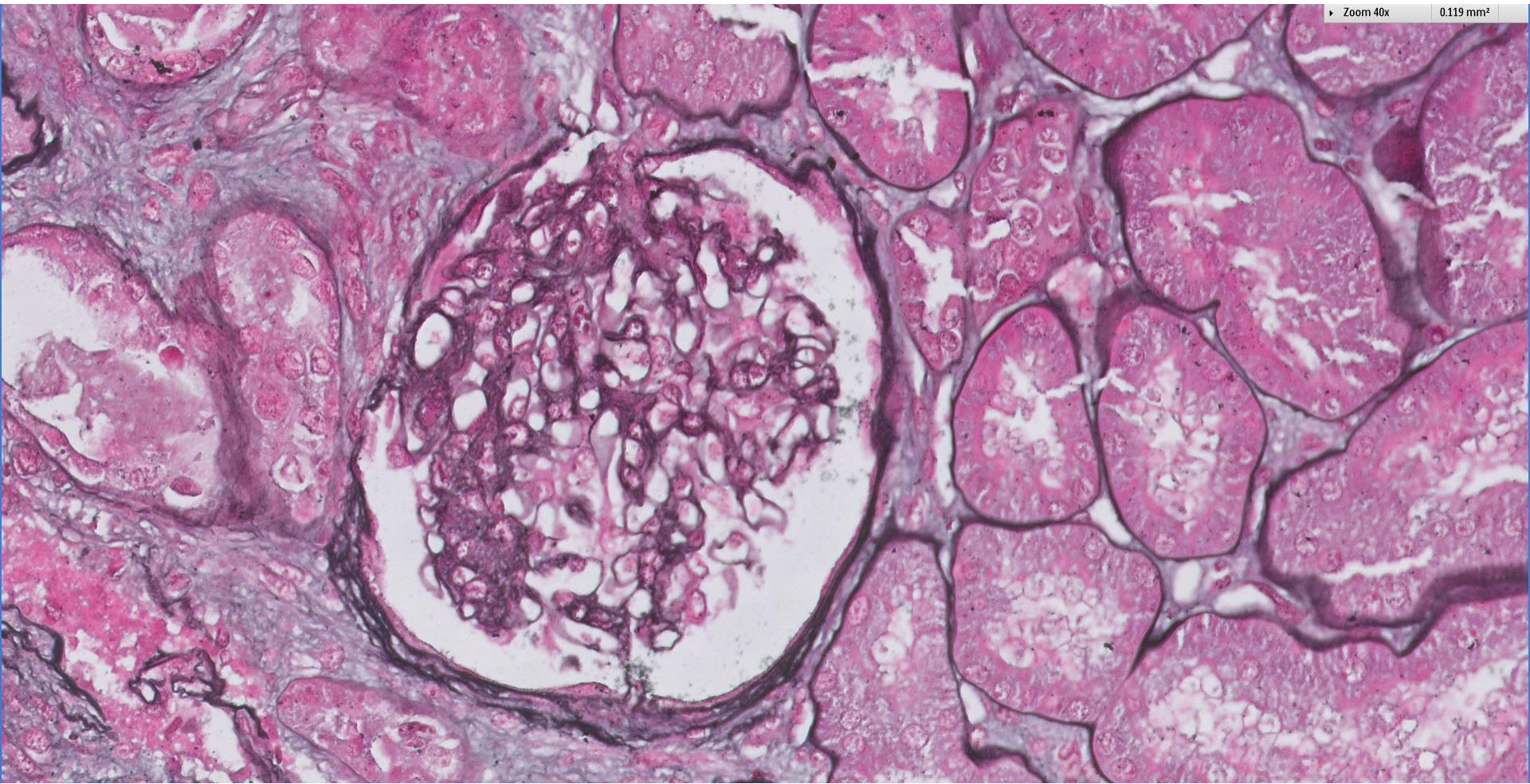
1.897 mm²



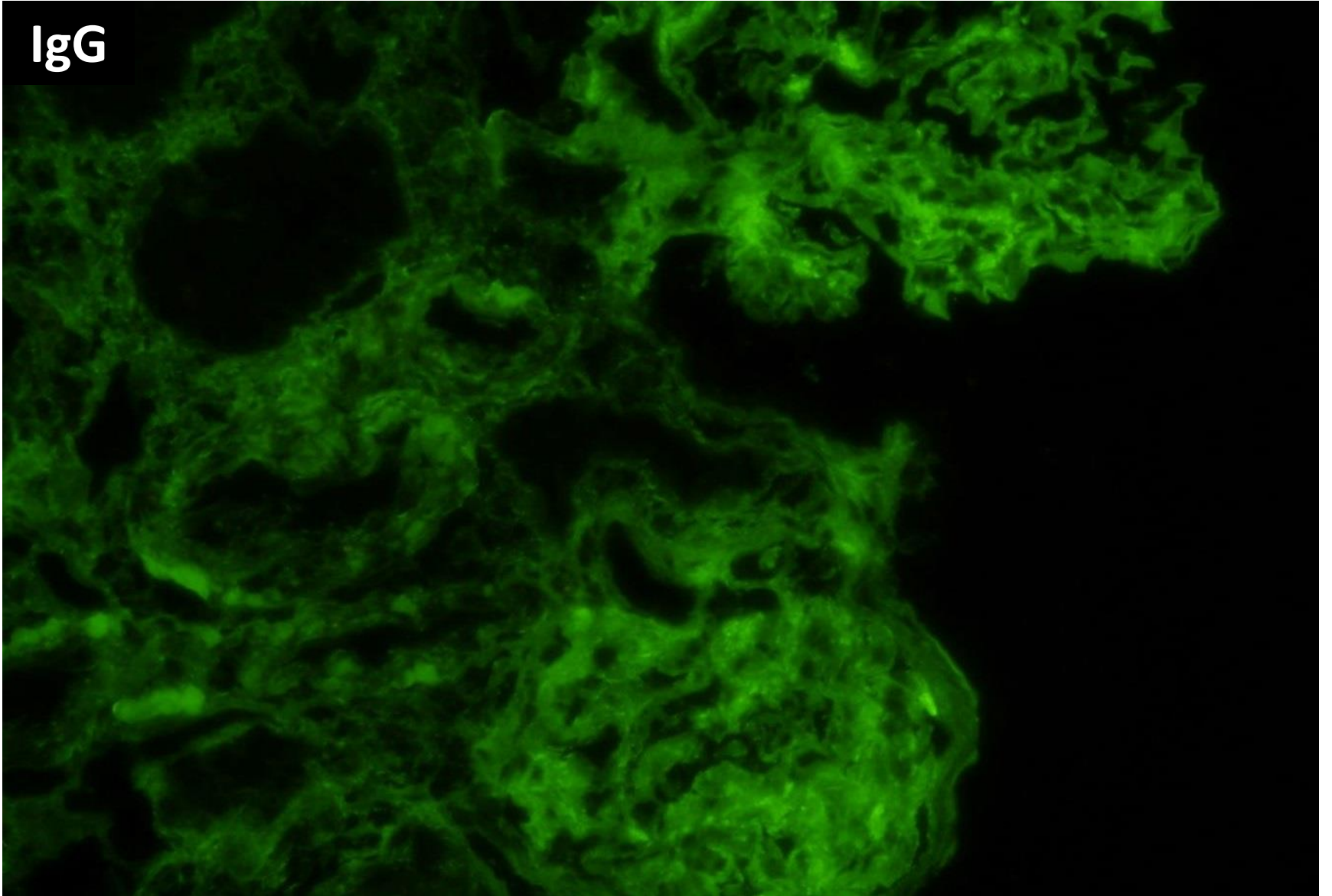
Zoom 20x

0.474 mm²

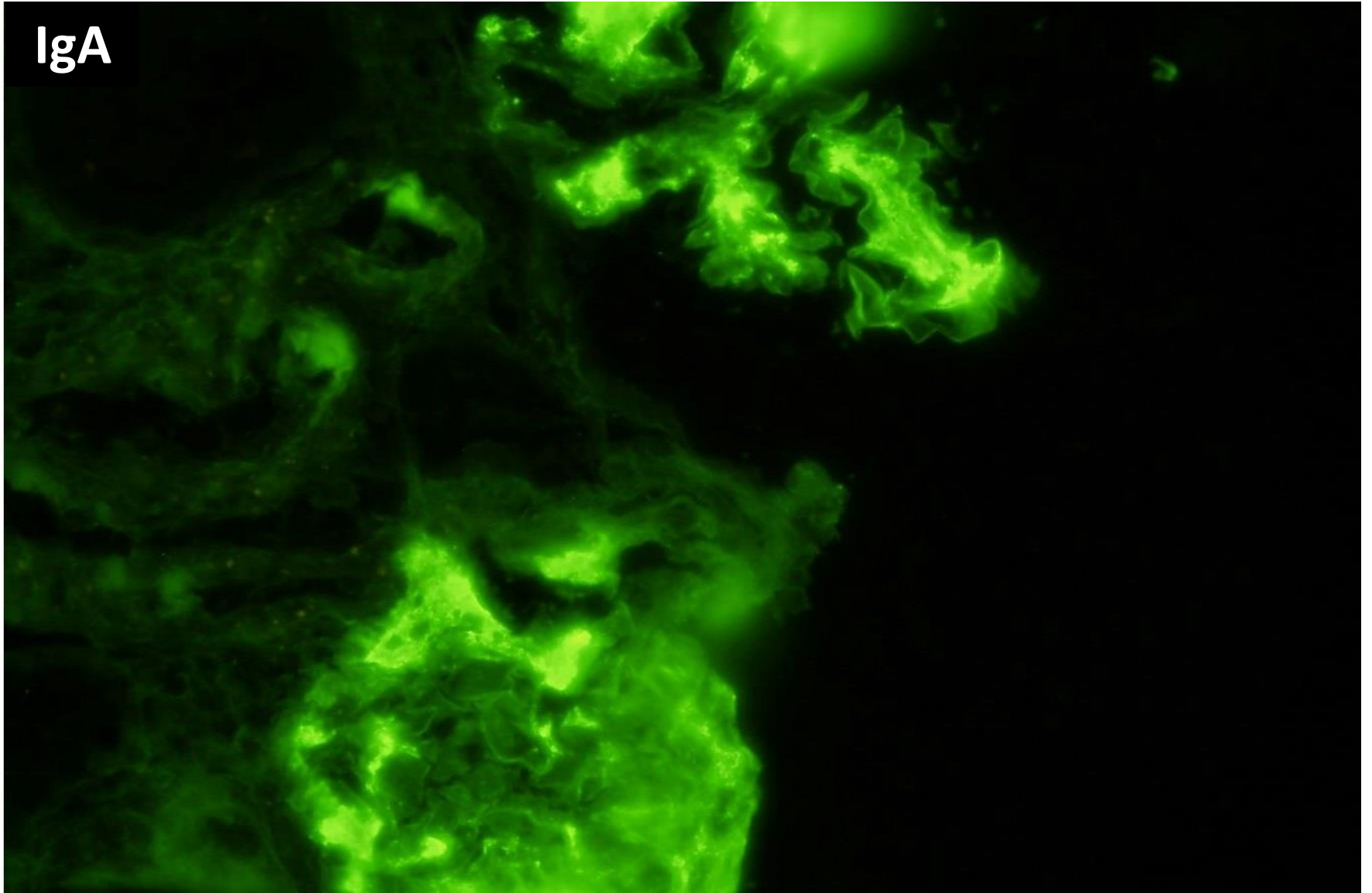




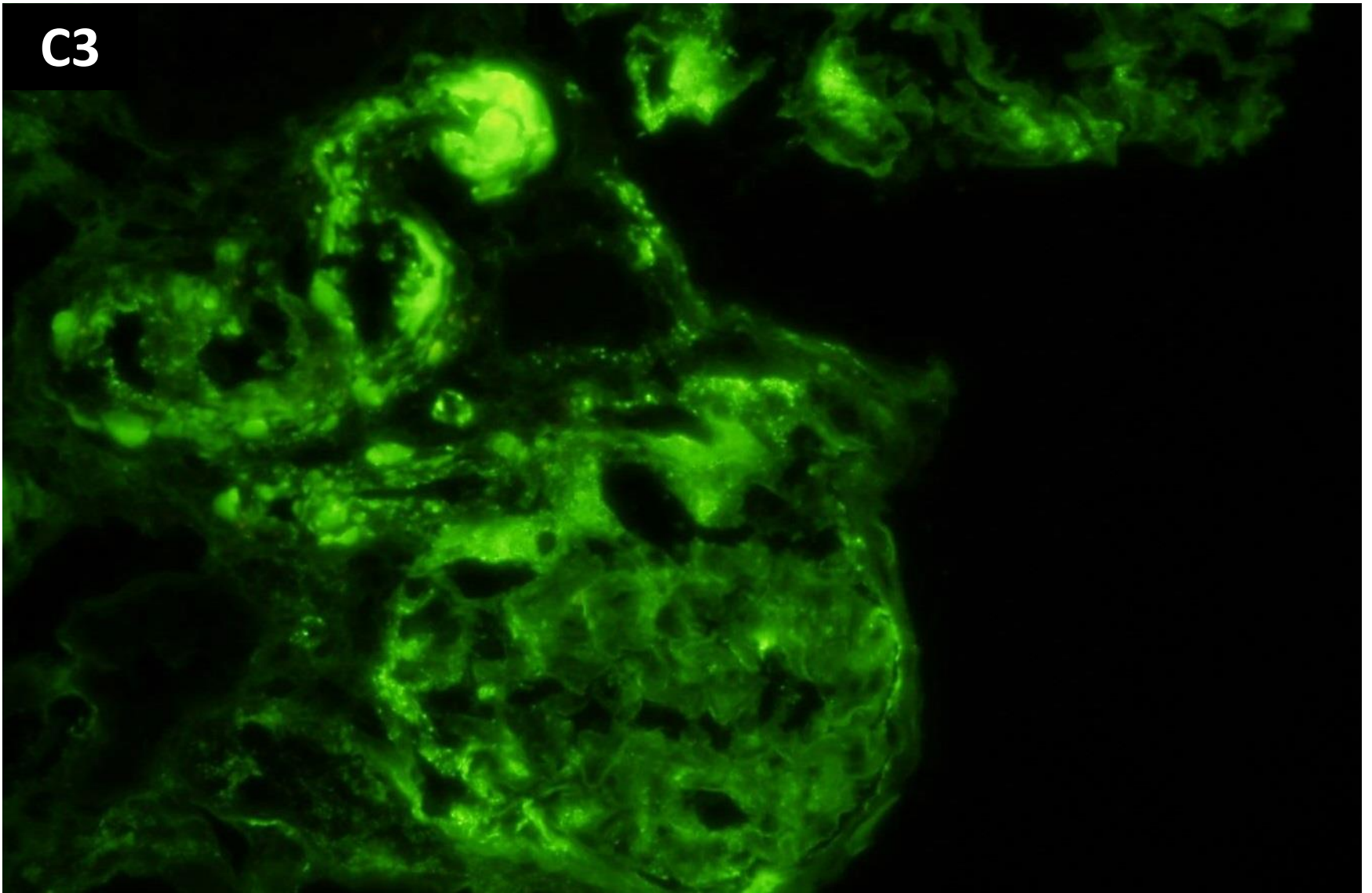
IgG



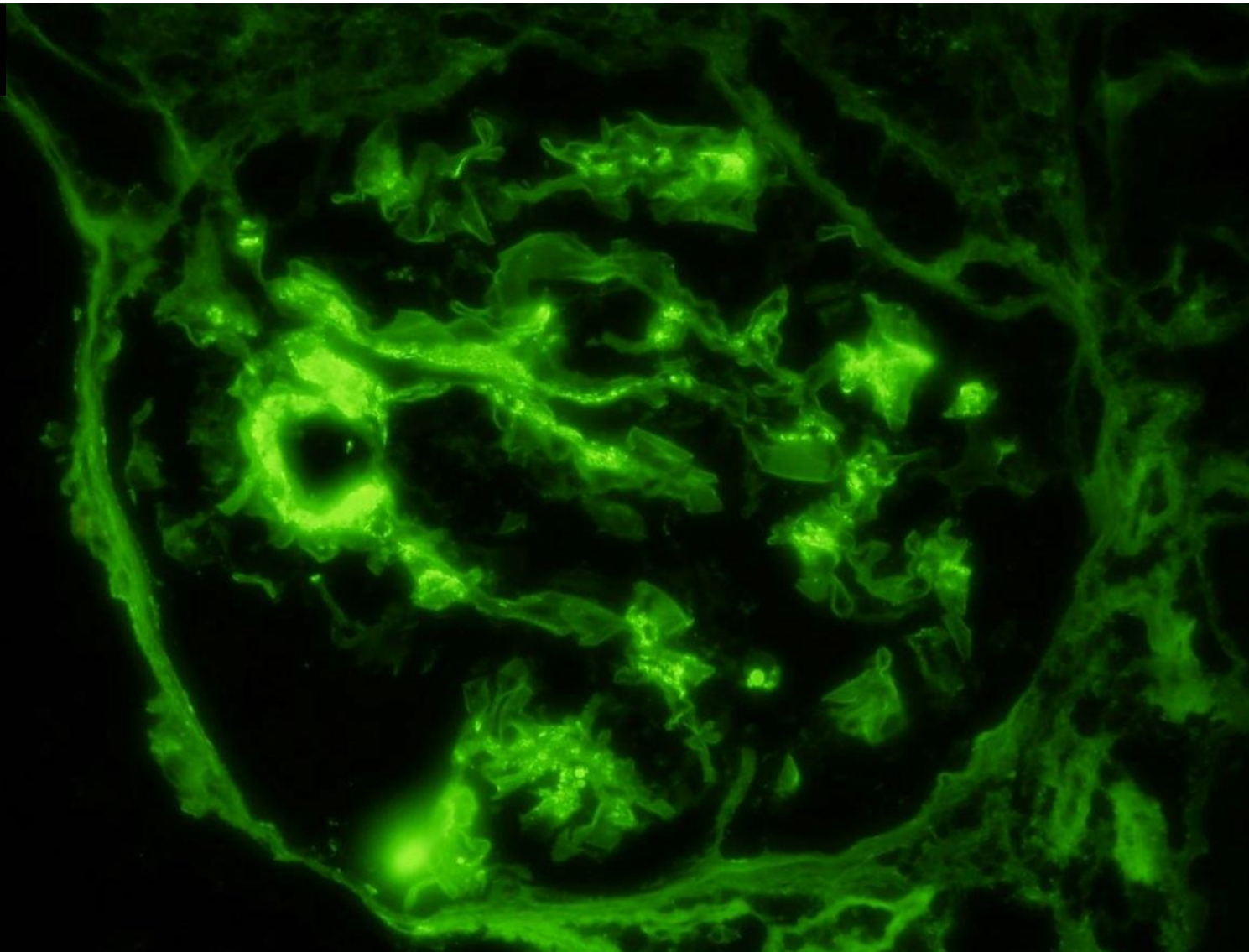
IgA



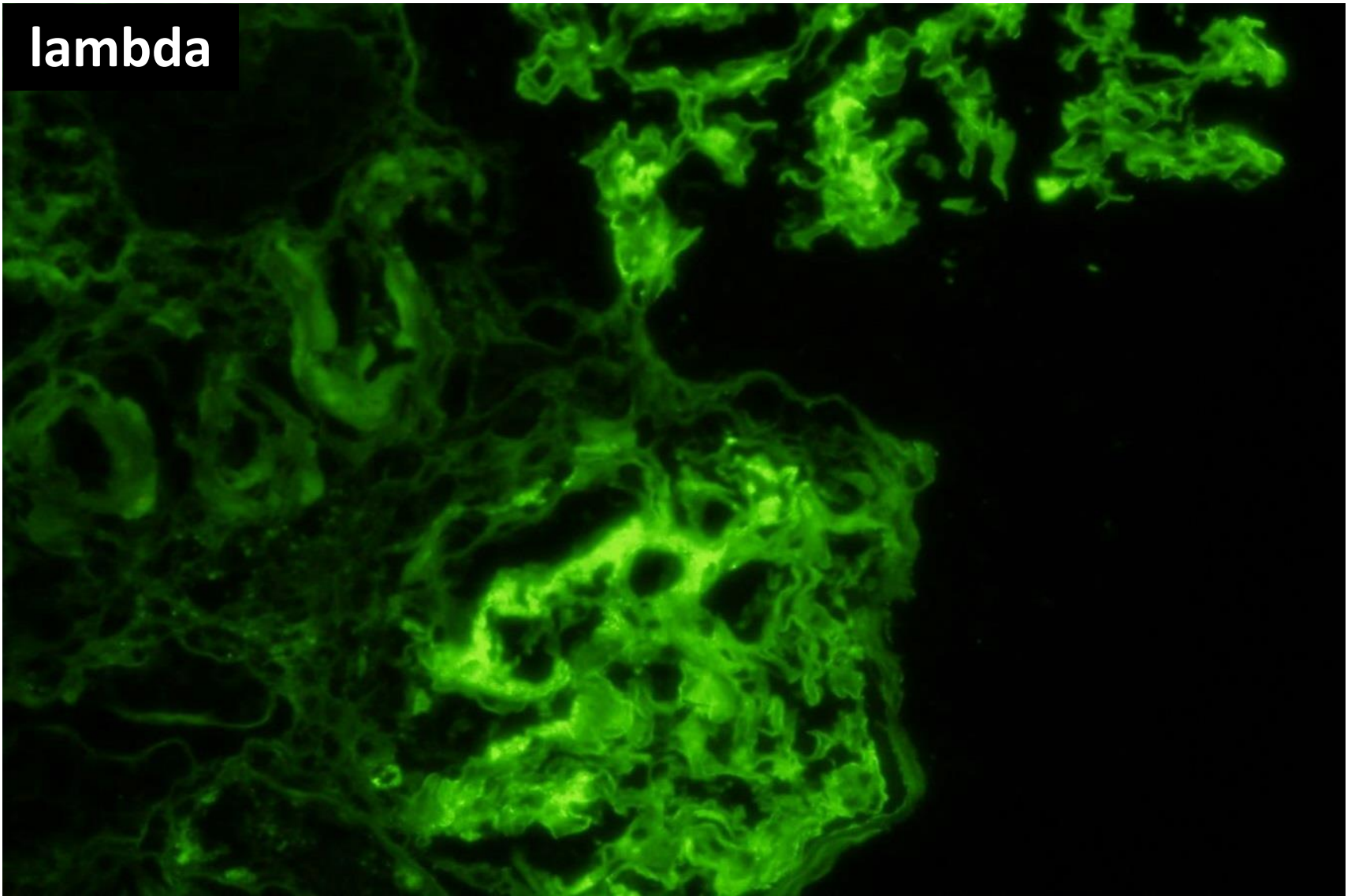
C3

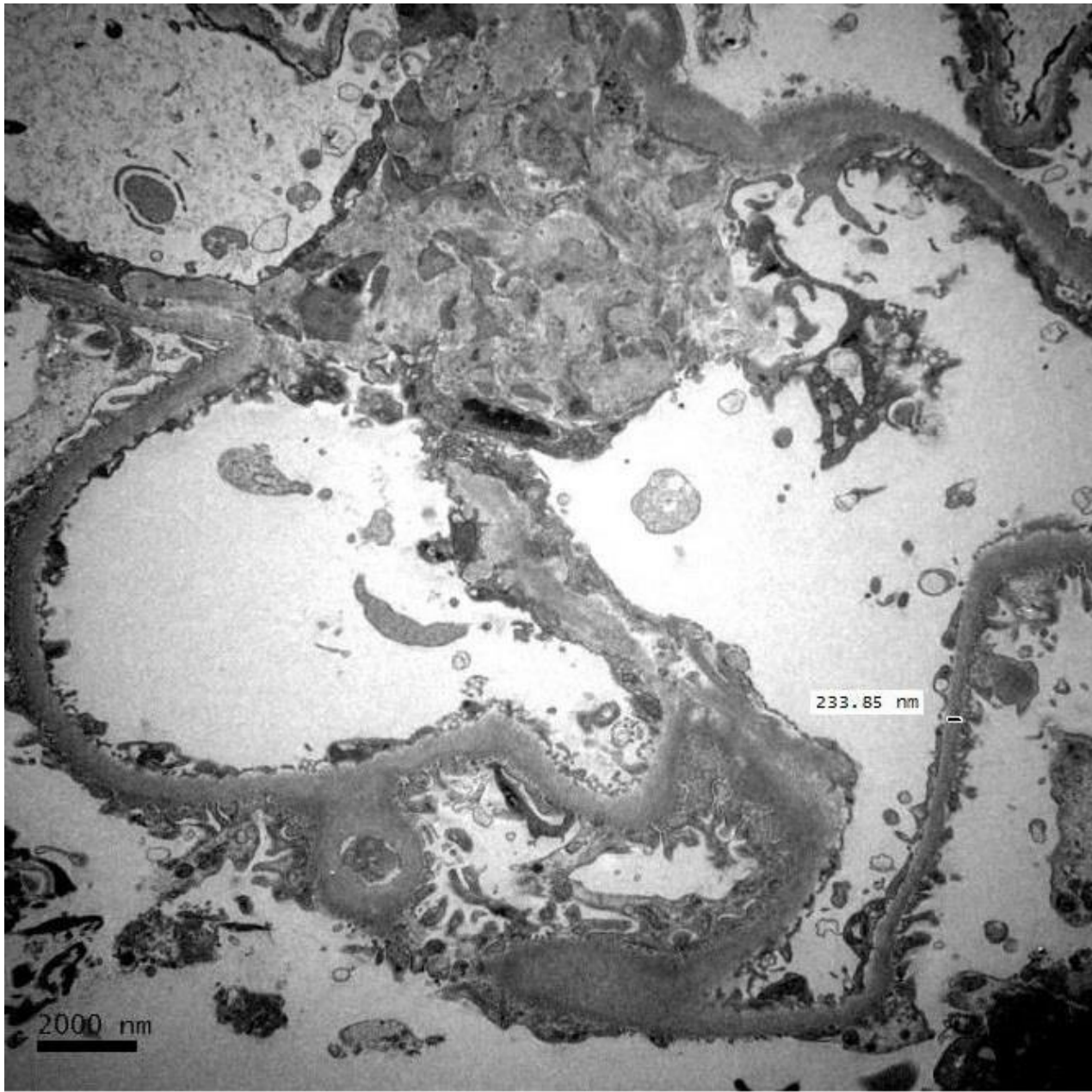


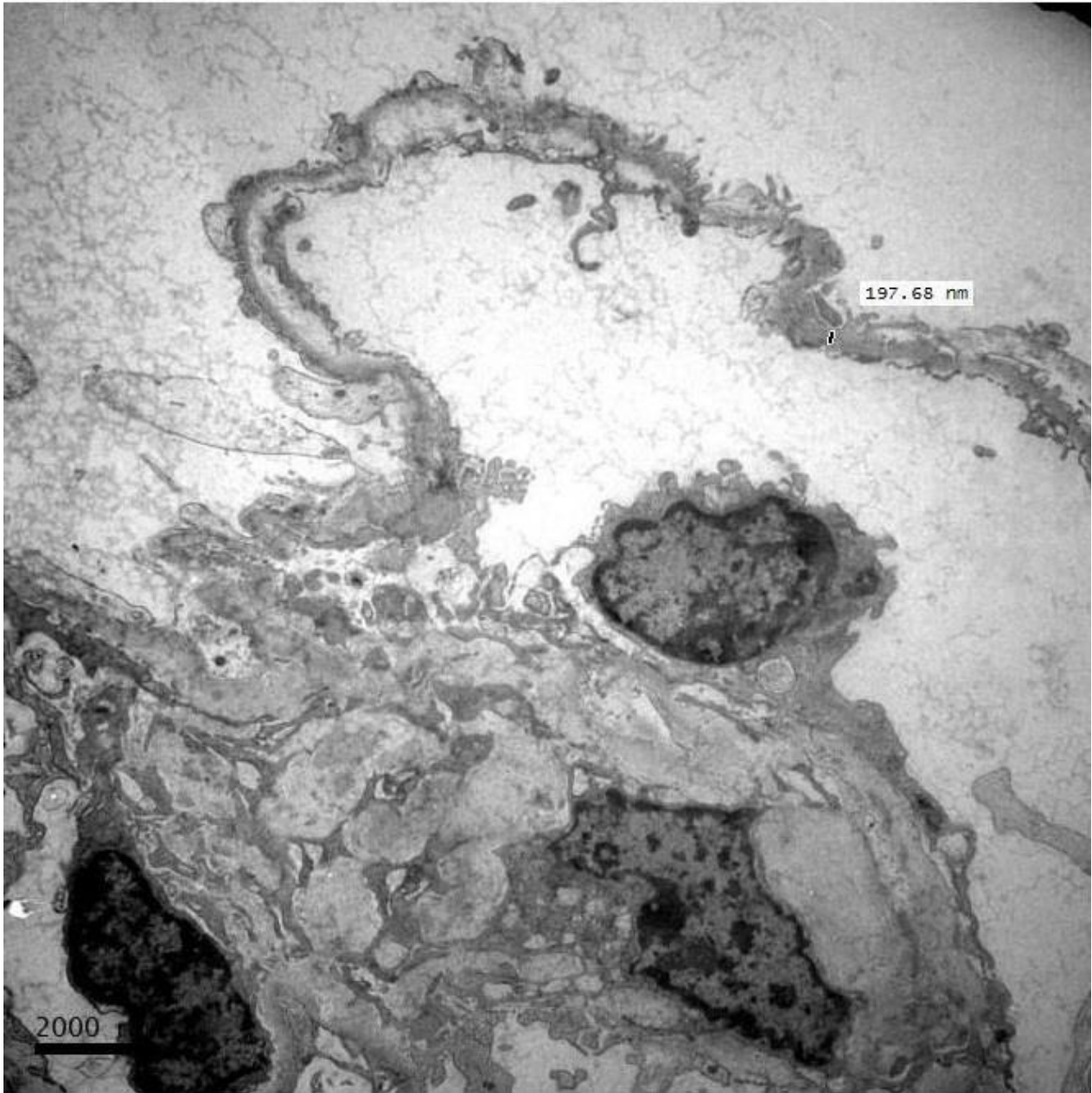
kappa

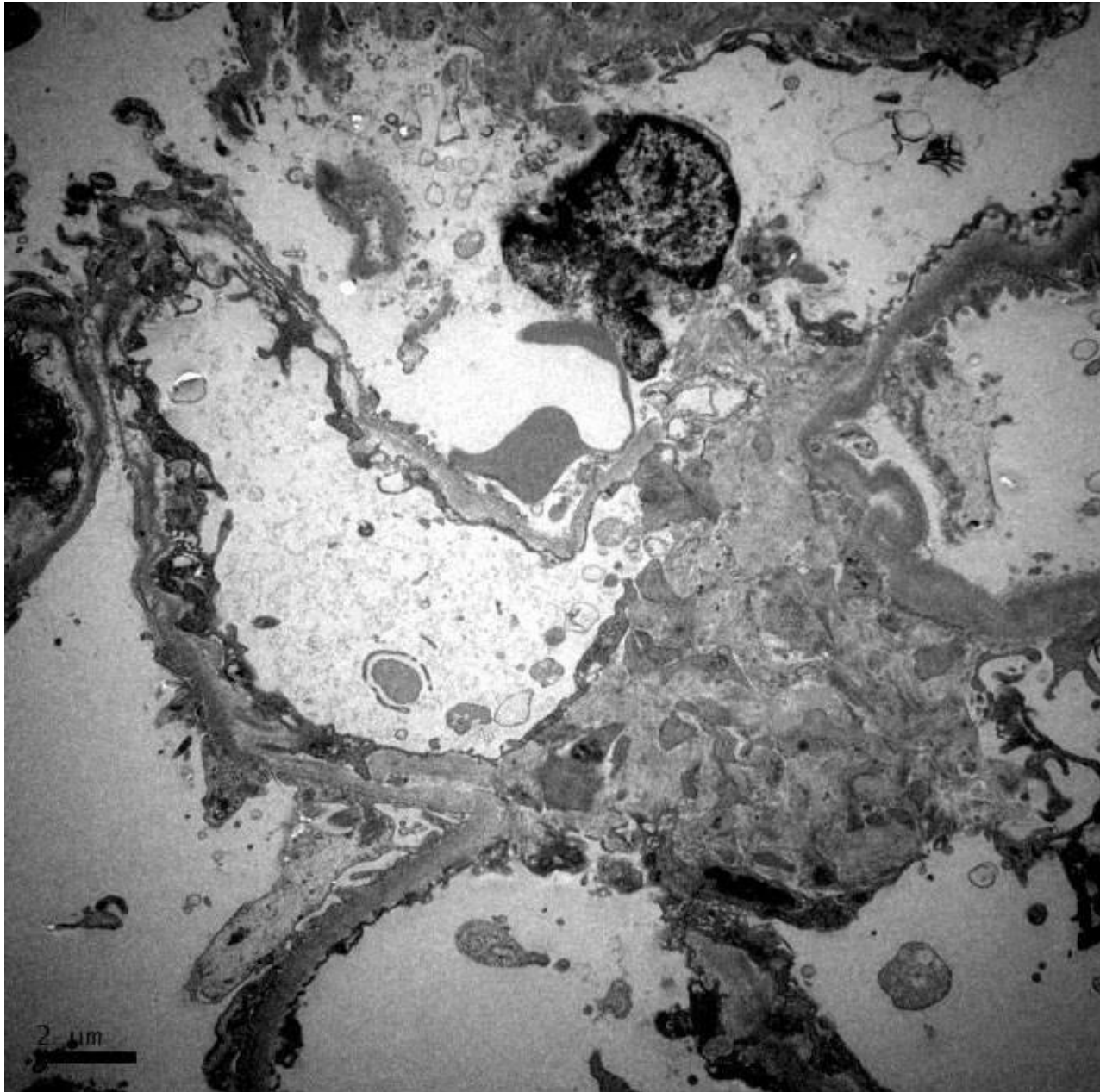


lambda











RENAL BIOPSY CLINICOPATHOLOGICAL WORKSHOP 2018



PATHOLOGY



Division of Pathology
Singapore General Hospital



Department of Renal Medicine
Singapore General Hospital



MEDICINE