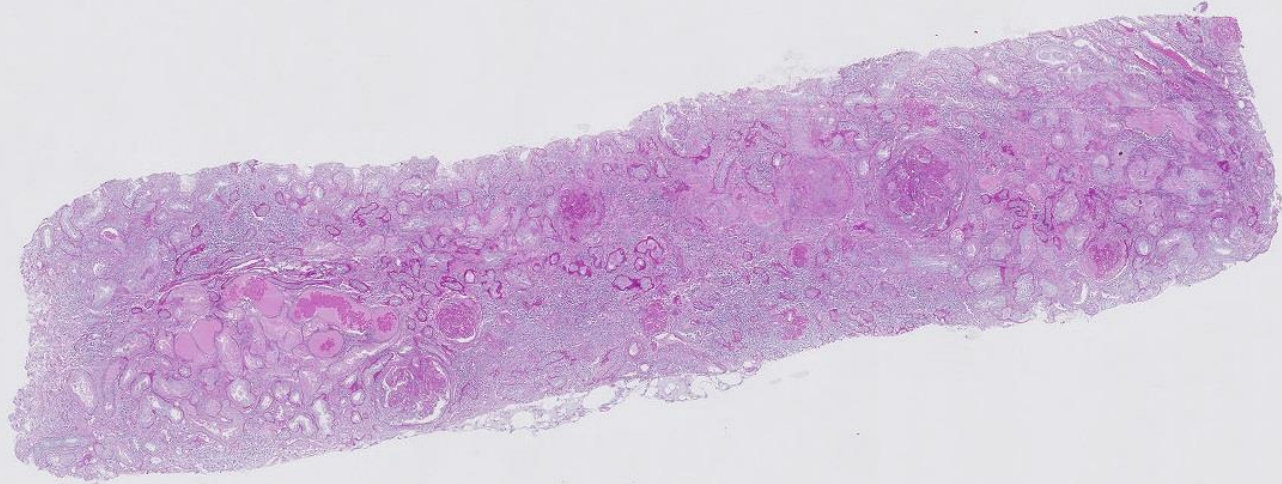
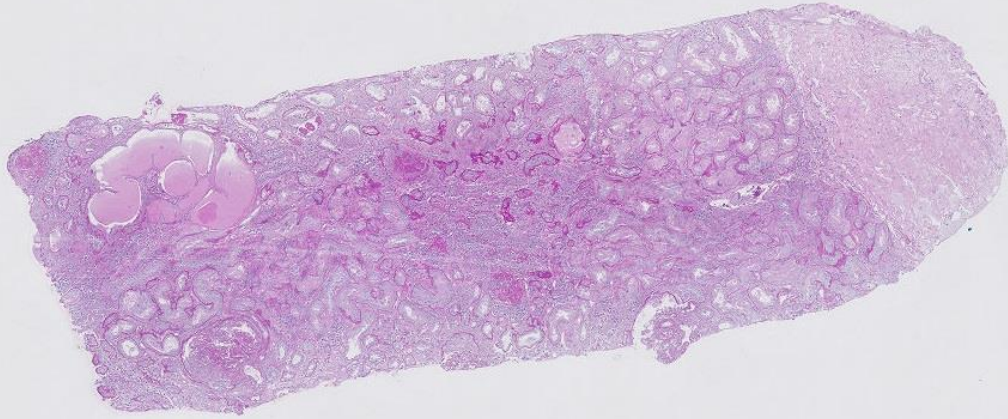
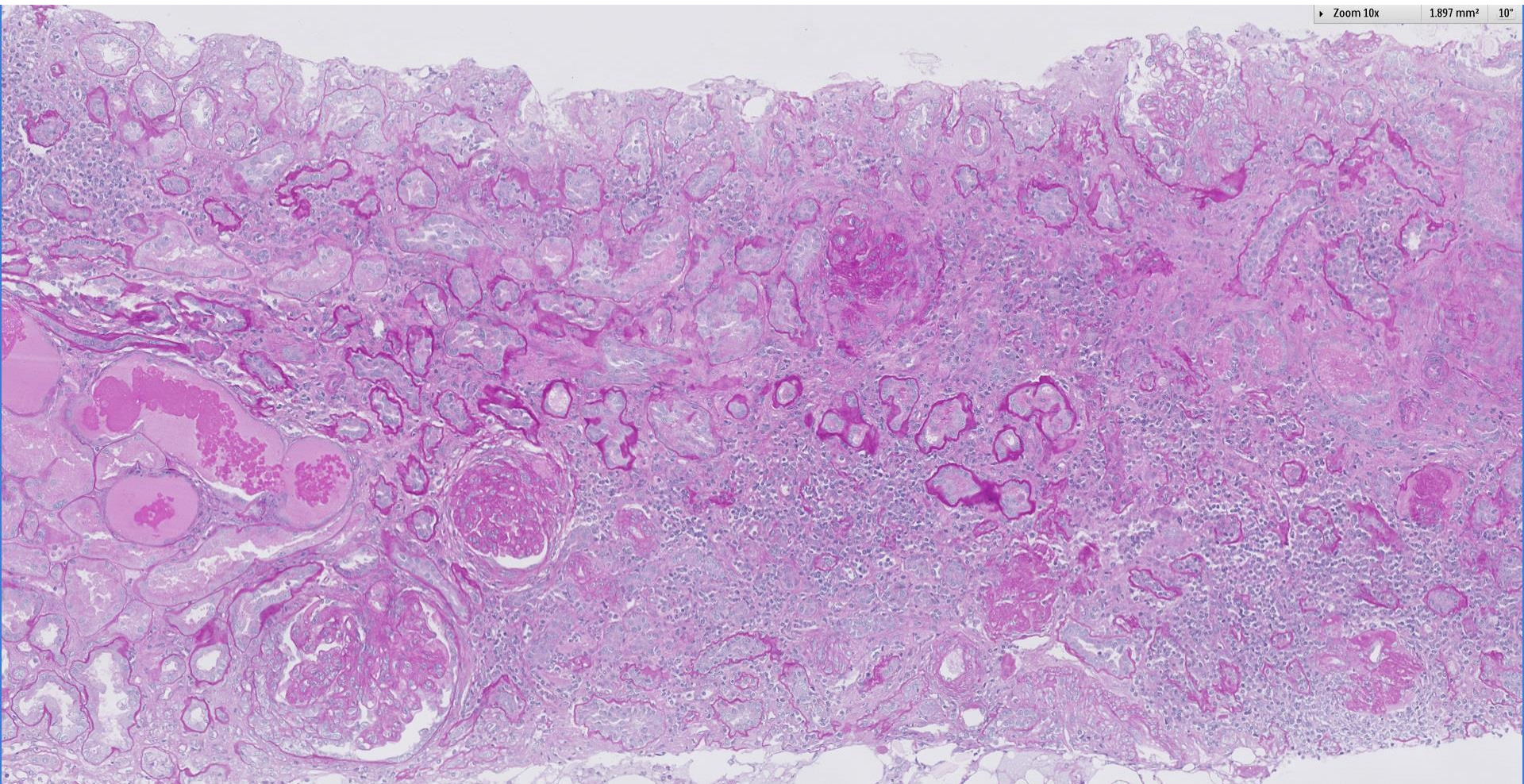
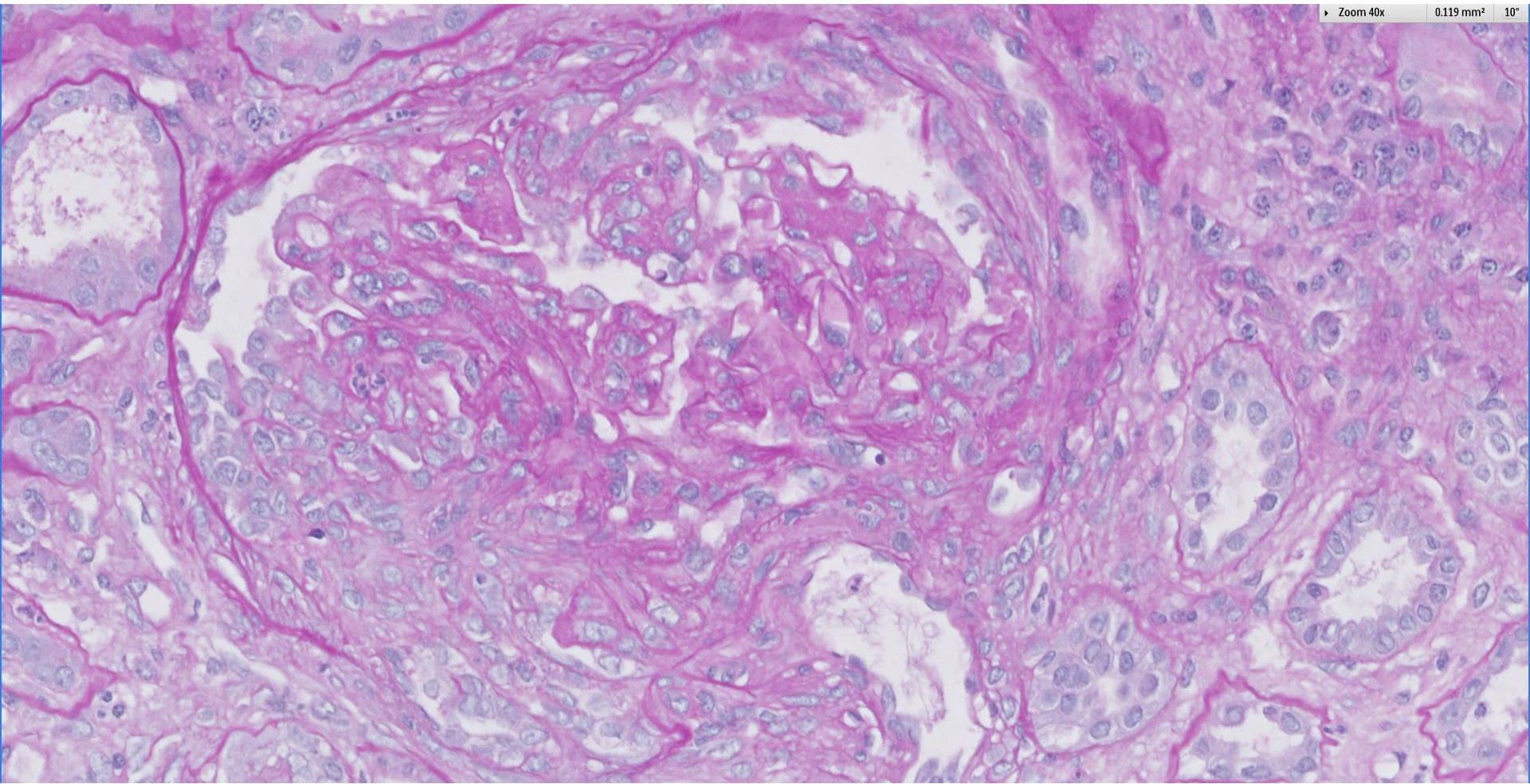


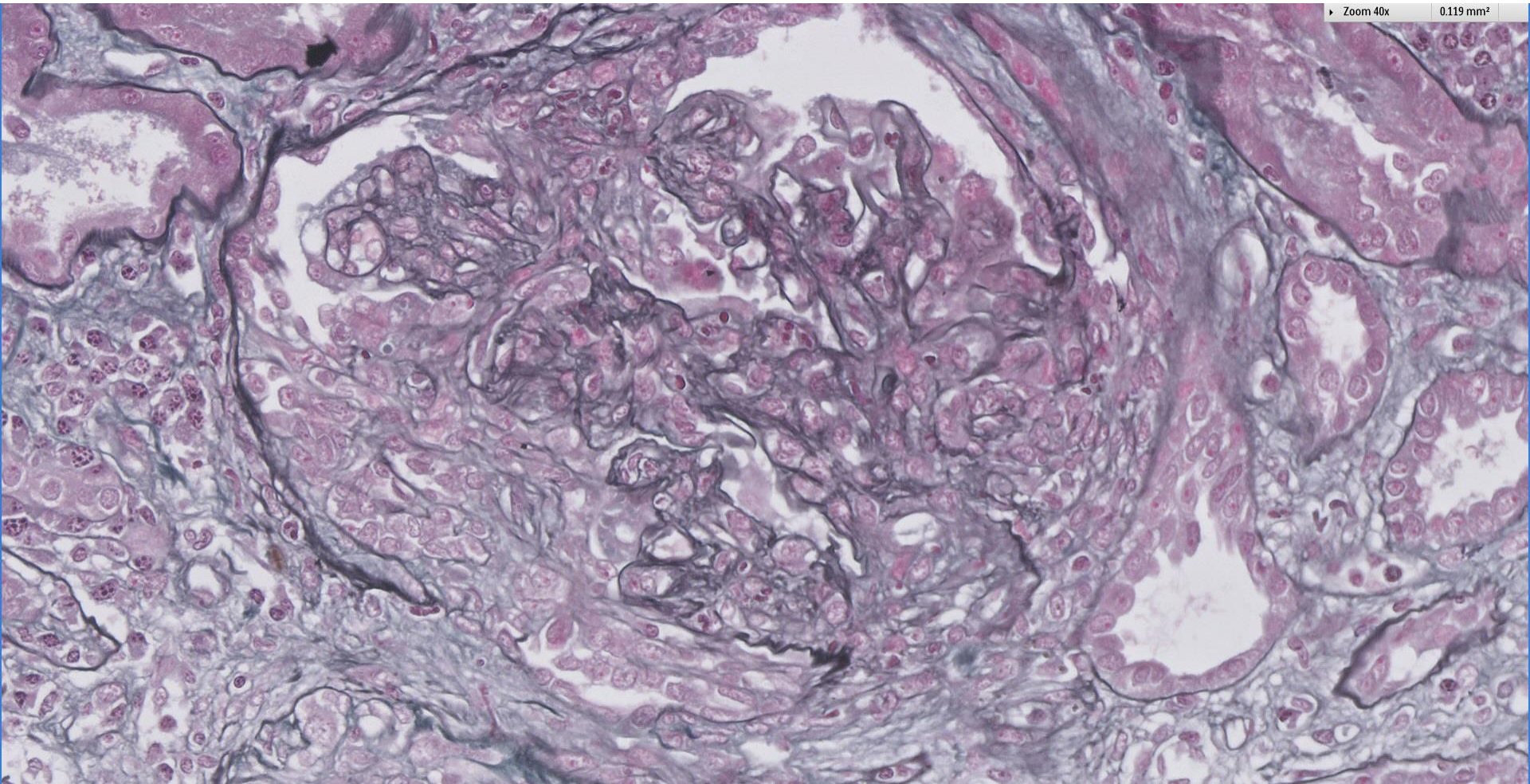
Case 42

46 year old male with recent fever and coryza 3 weeks ago now presents with acute kidney injury. Urine red blood cells 172 per hpf, UPCR 10 g/g, C3 low, C4 normal. ANA, anti-dsDNA, ANCA-EIA negative. ASOT strongly positive >1/1600.

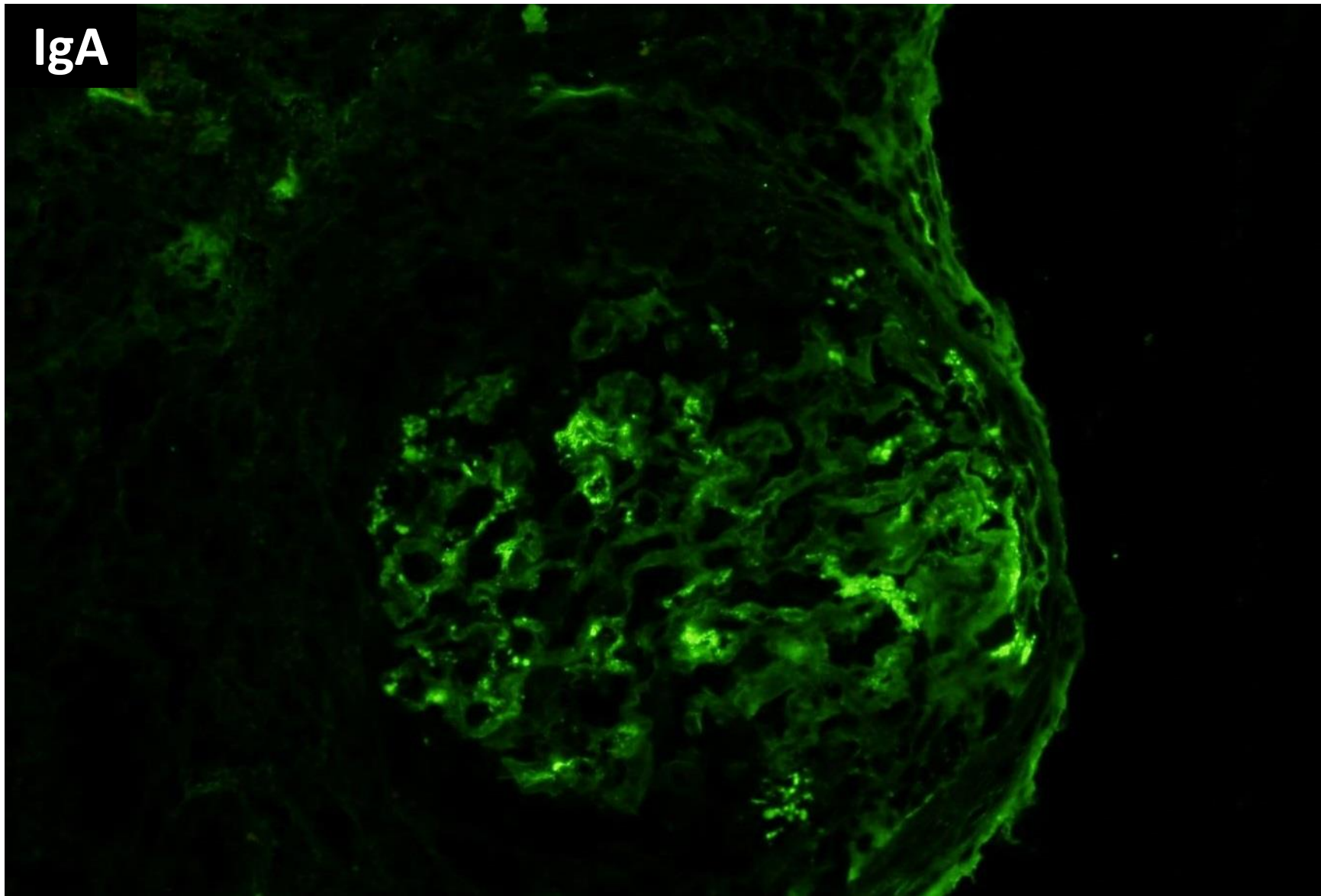




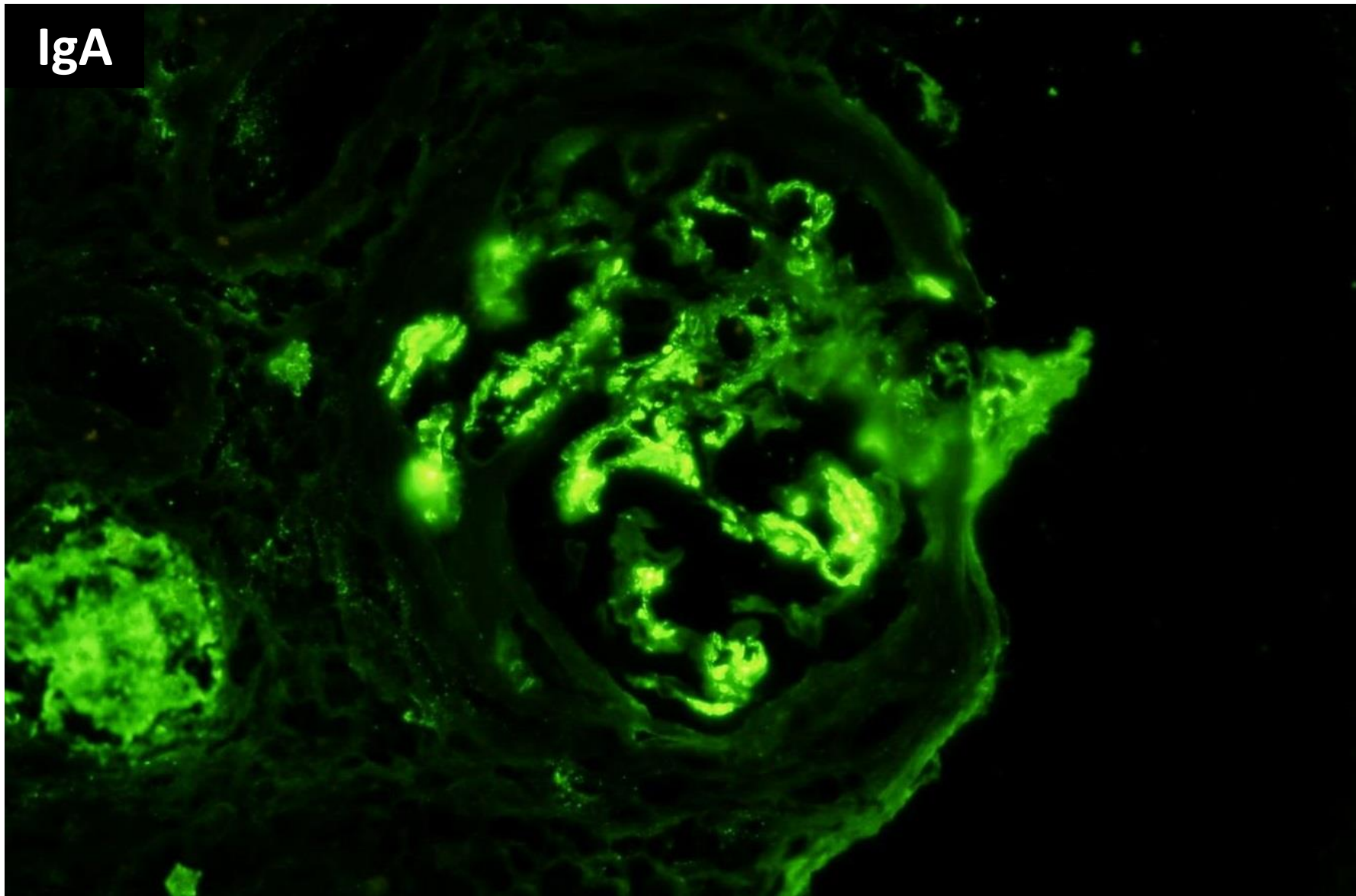




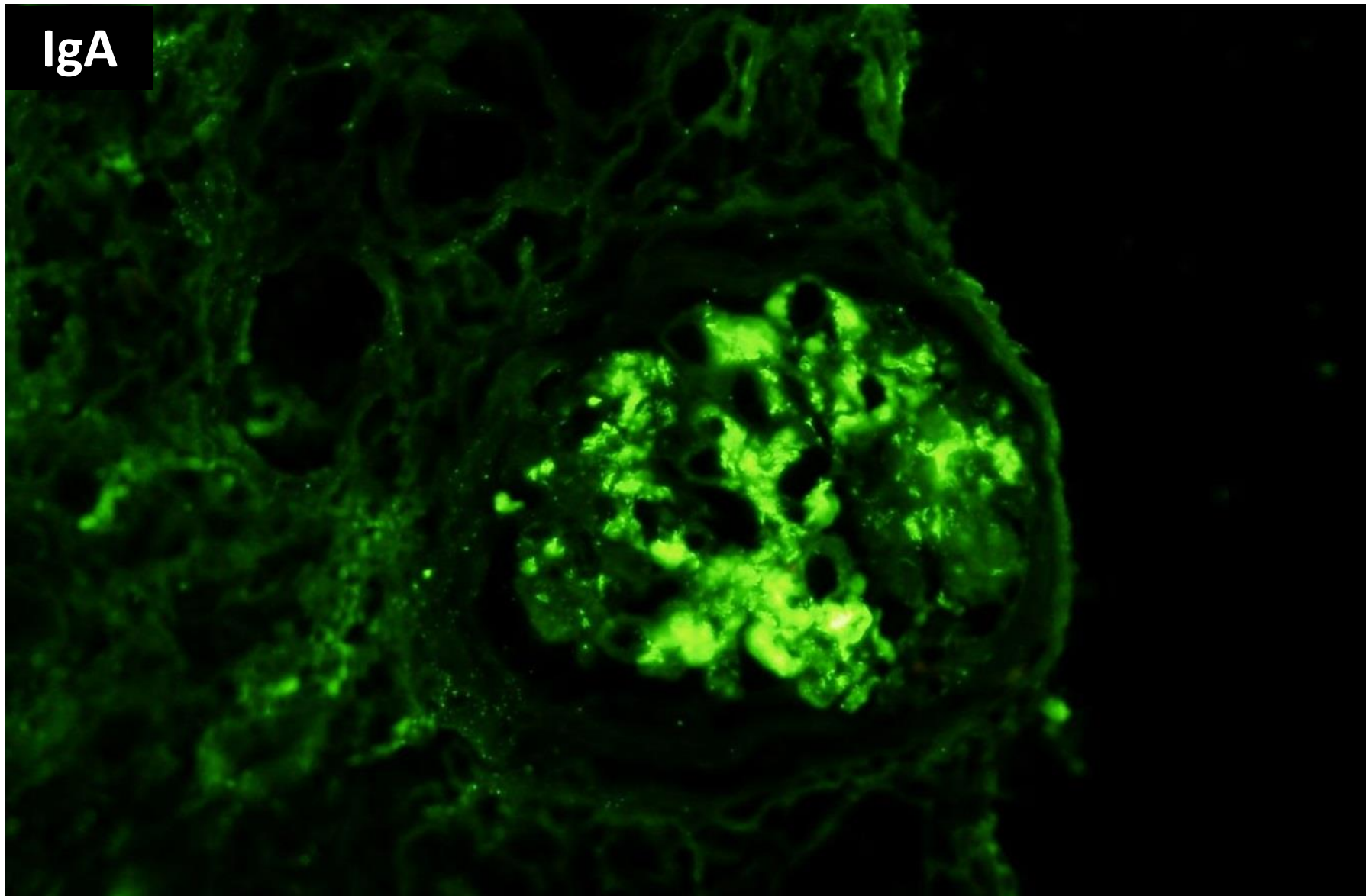
IgA



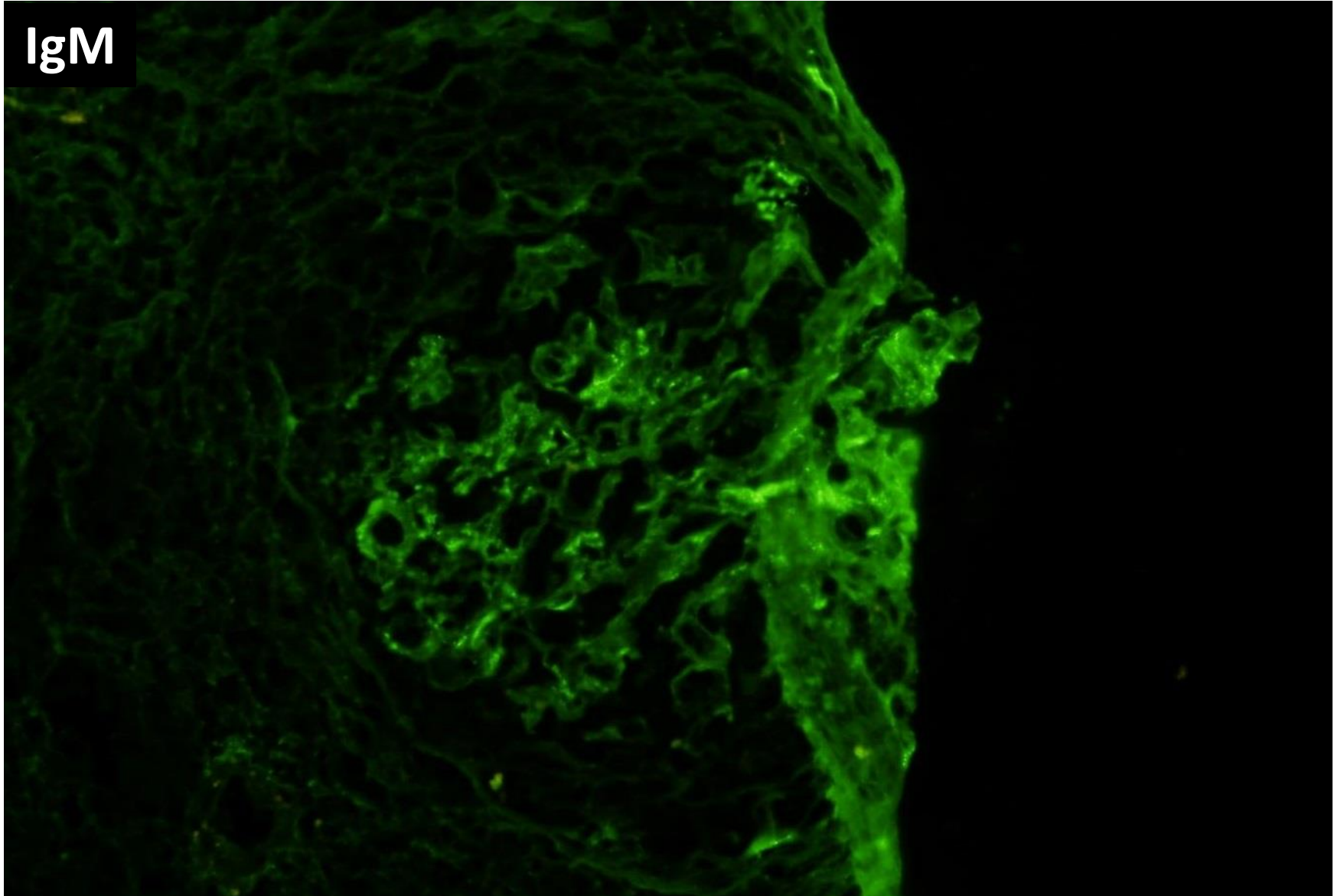
IgA



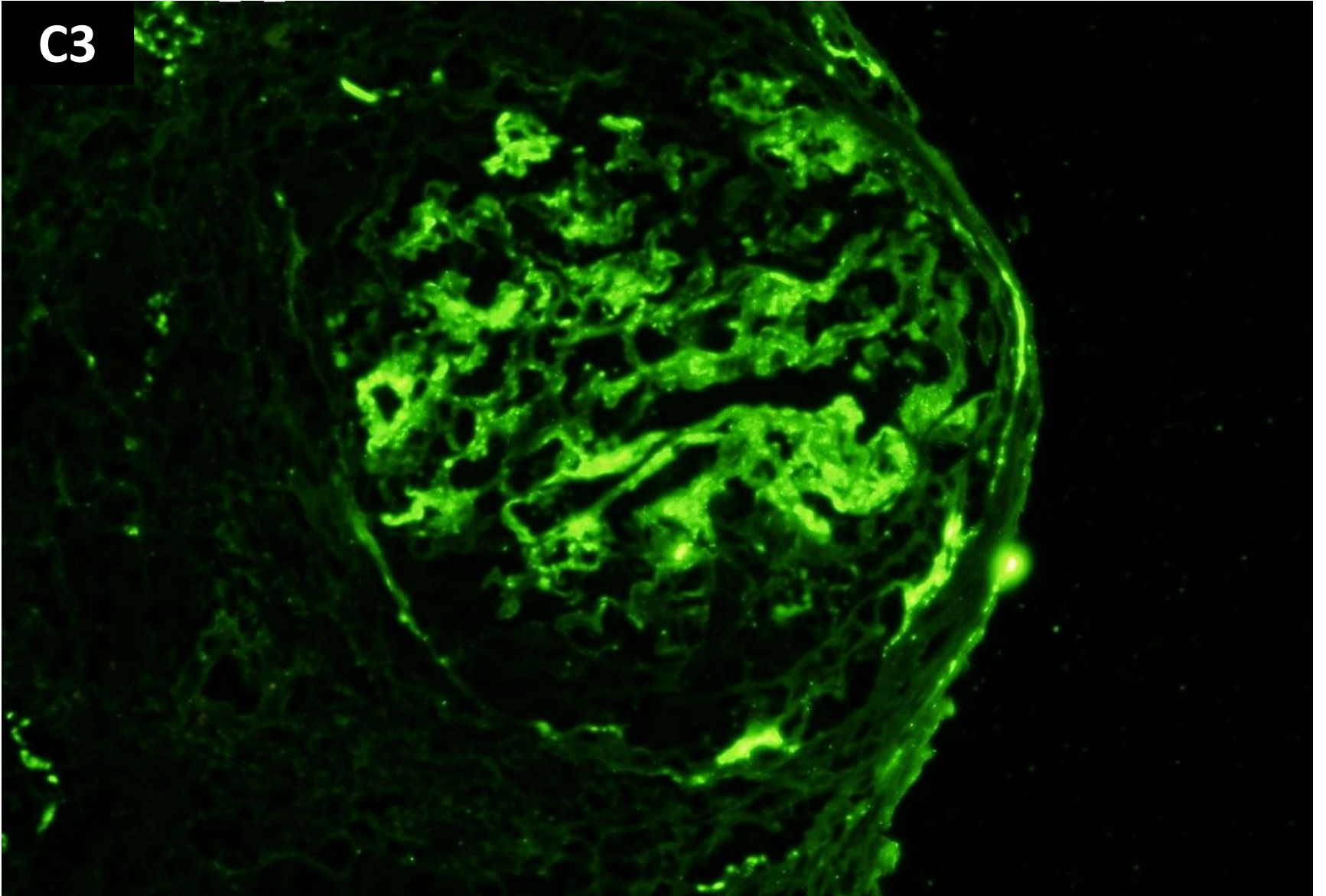
IgA

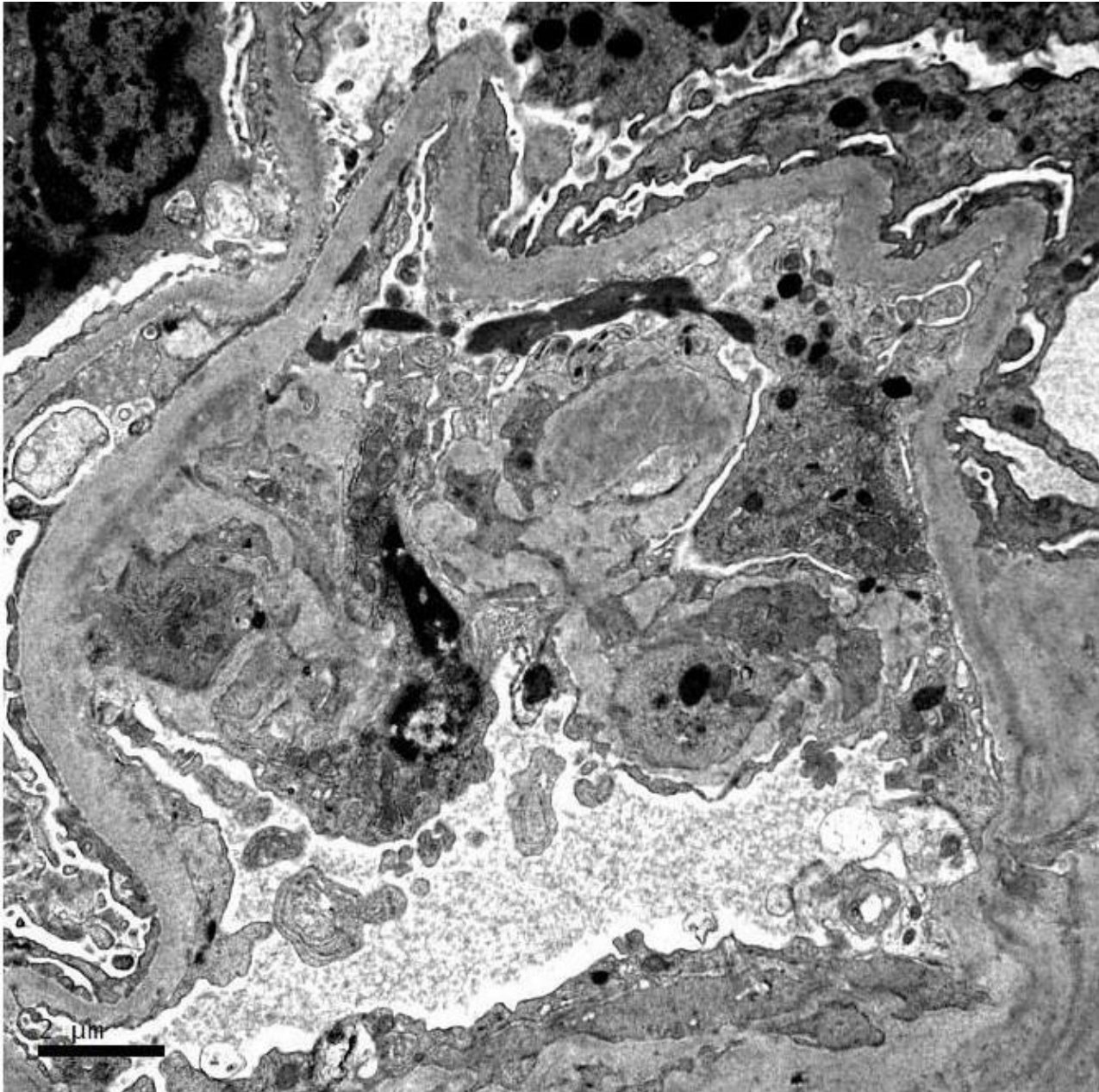


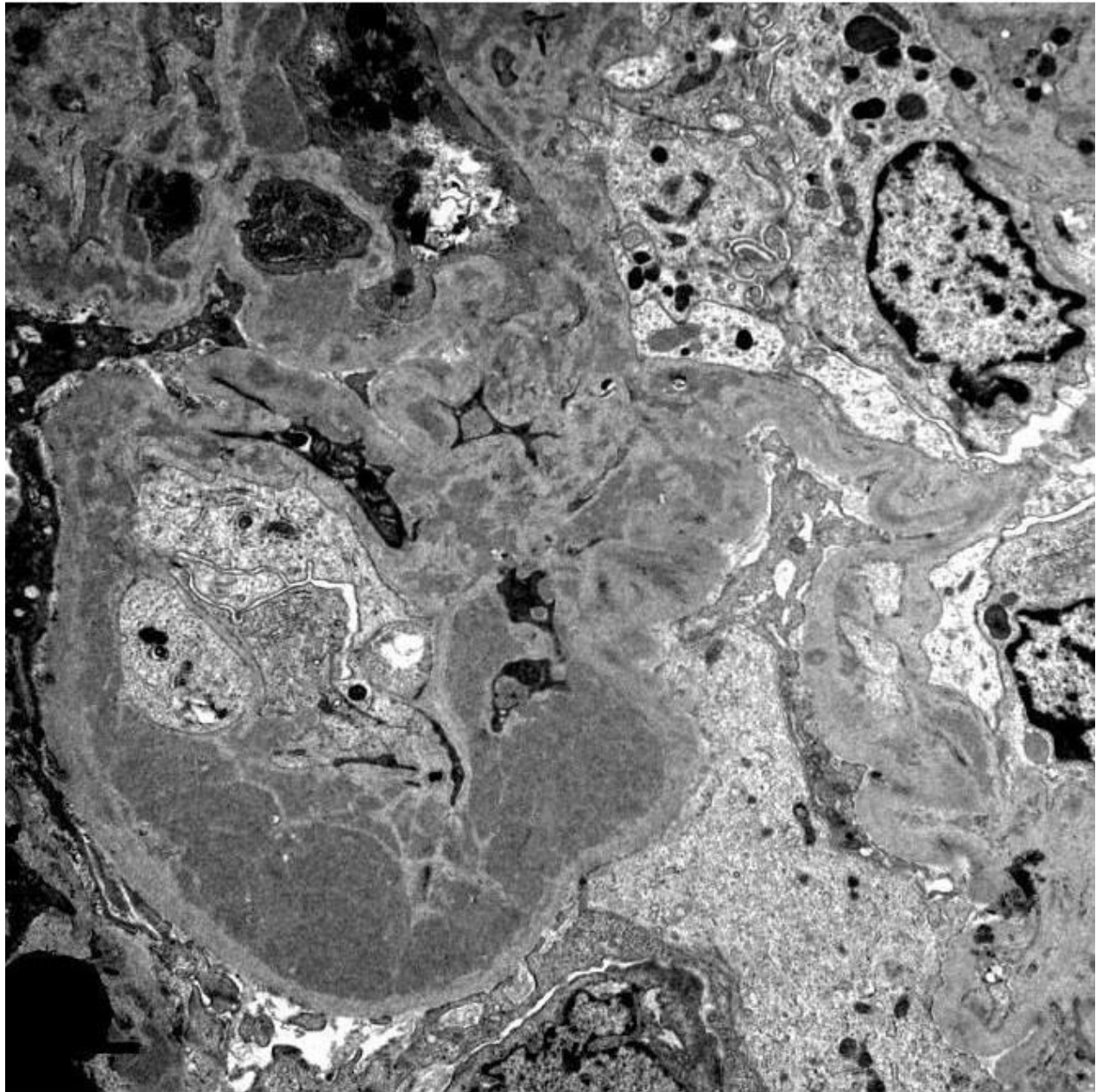
IgM

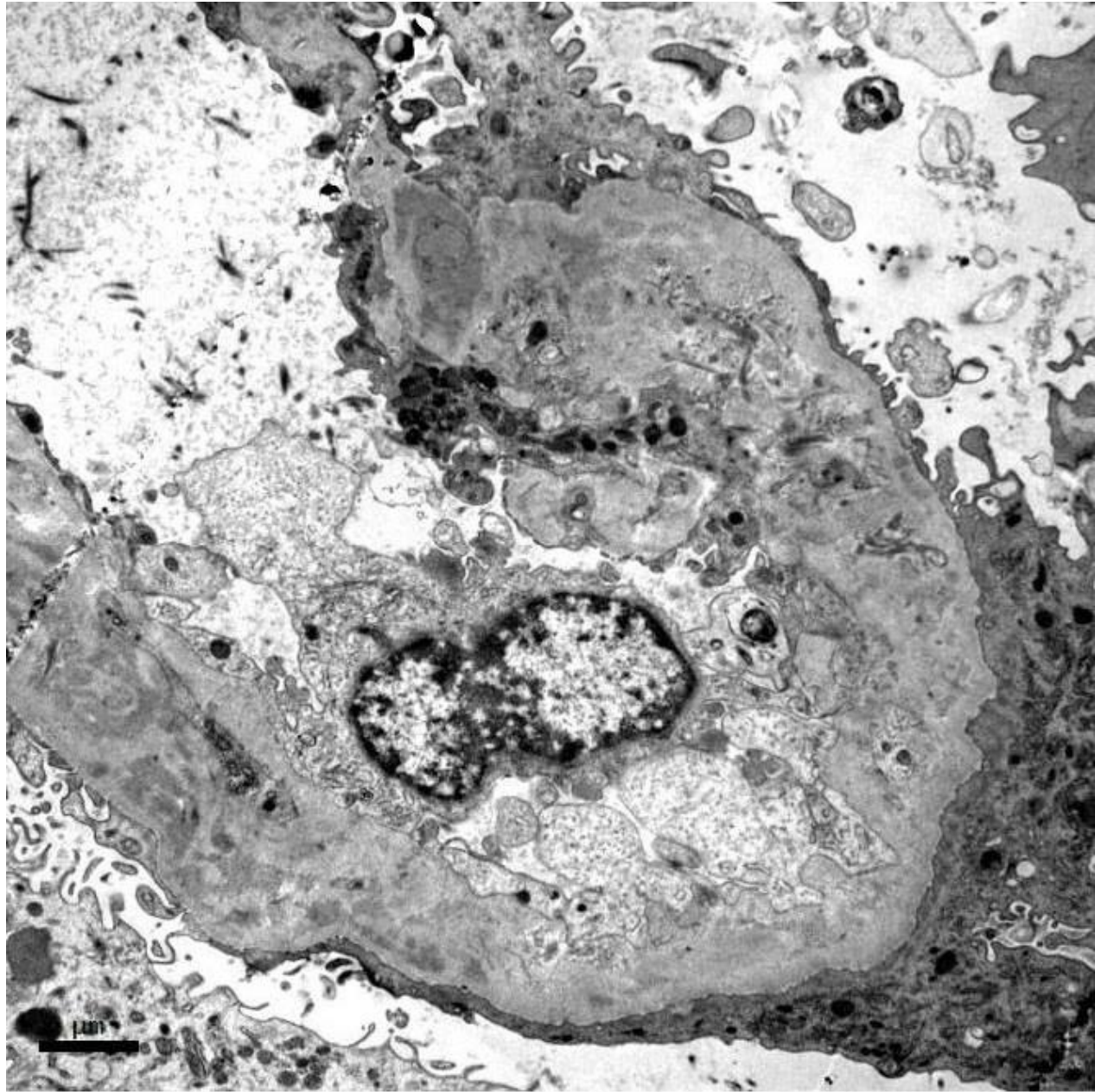


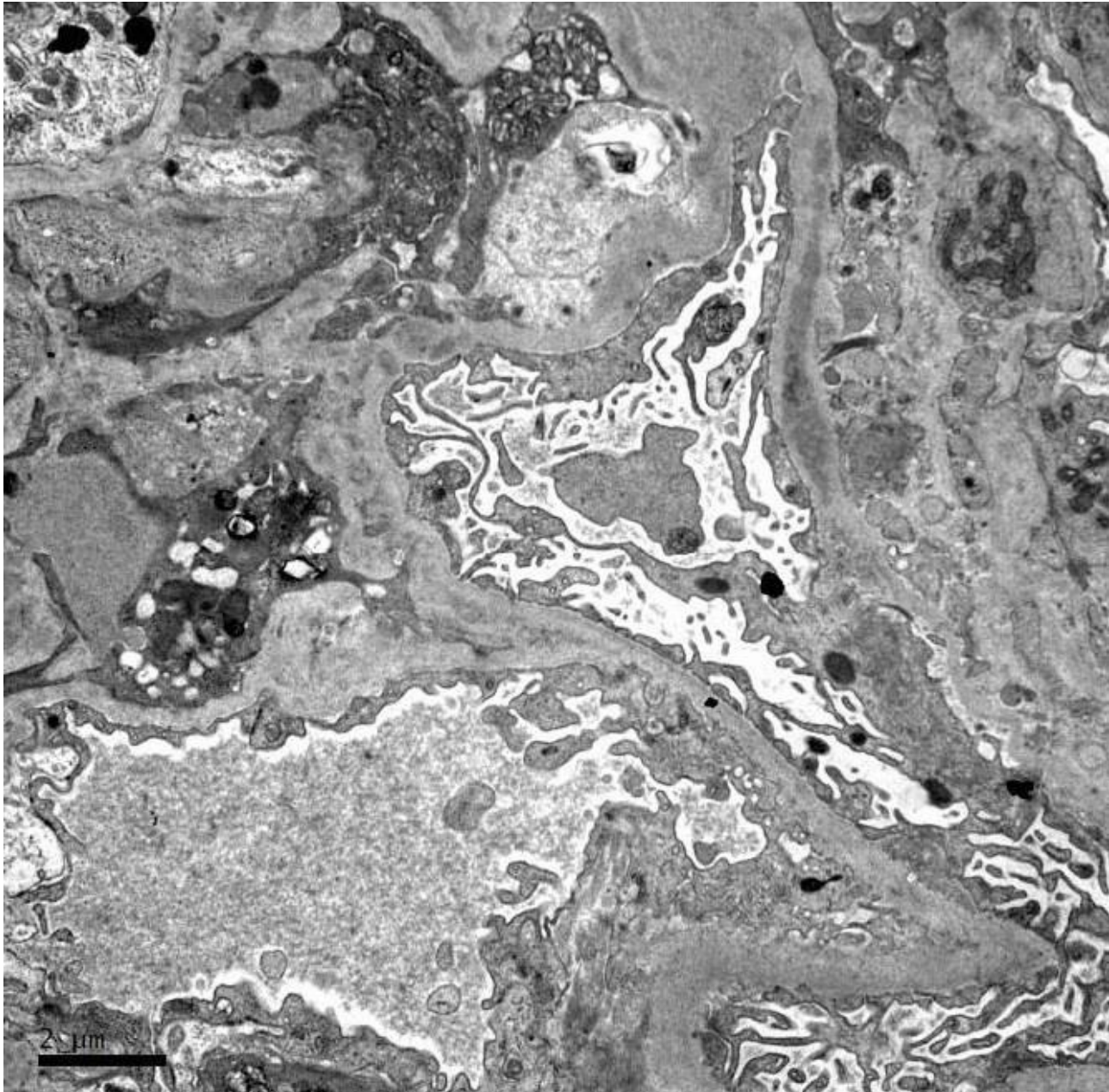
C3

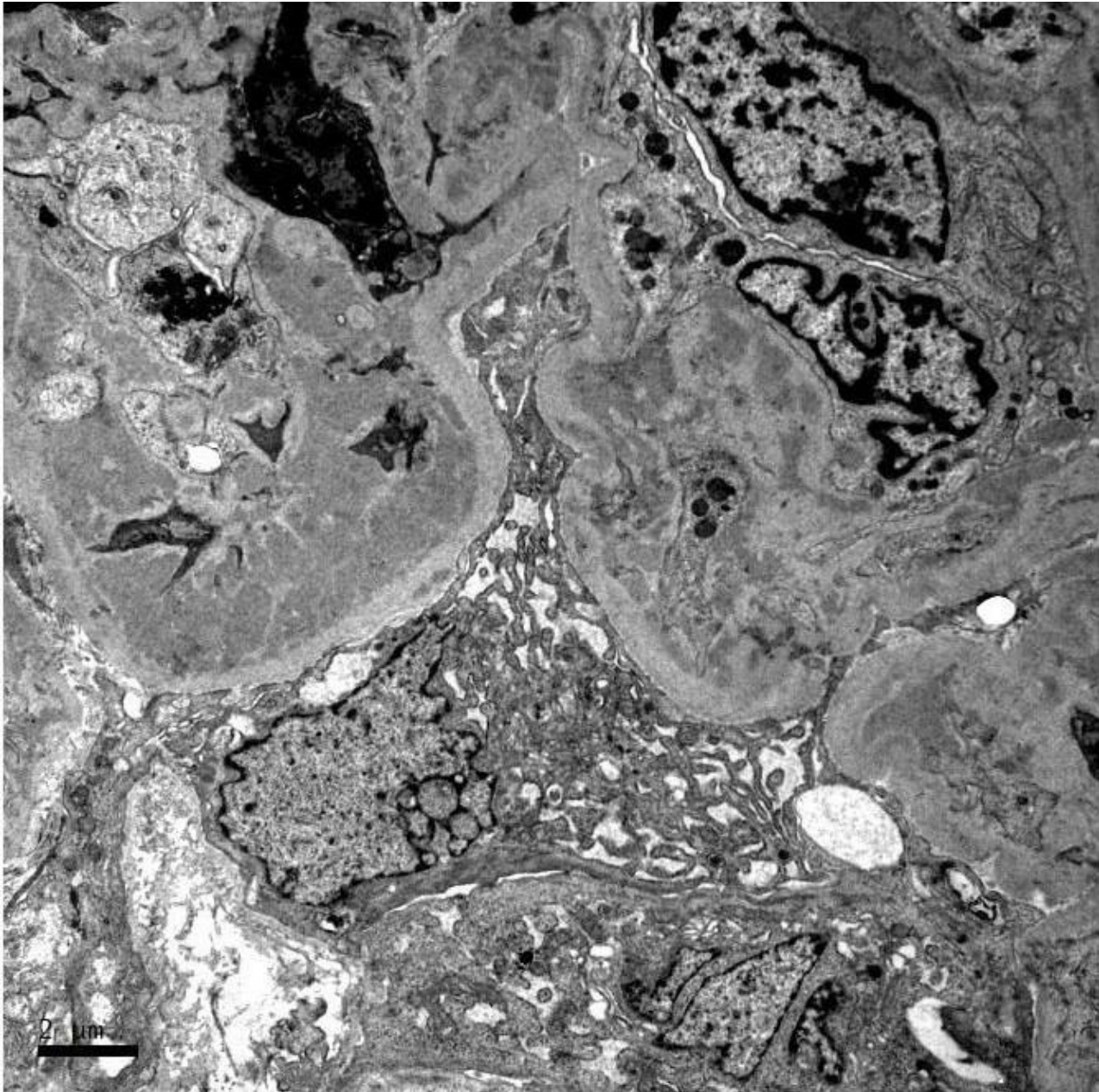


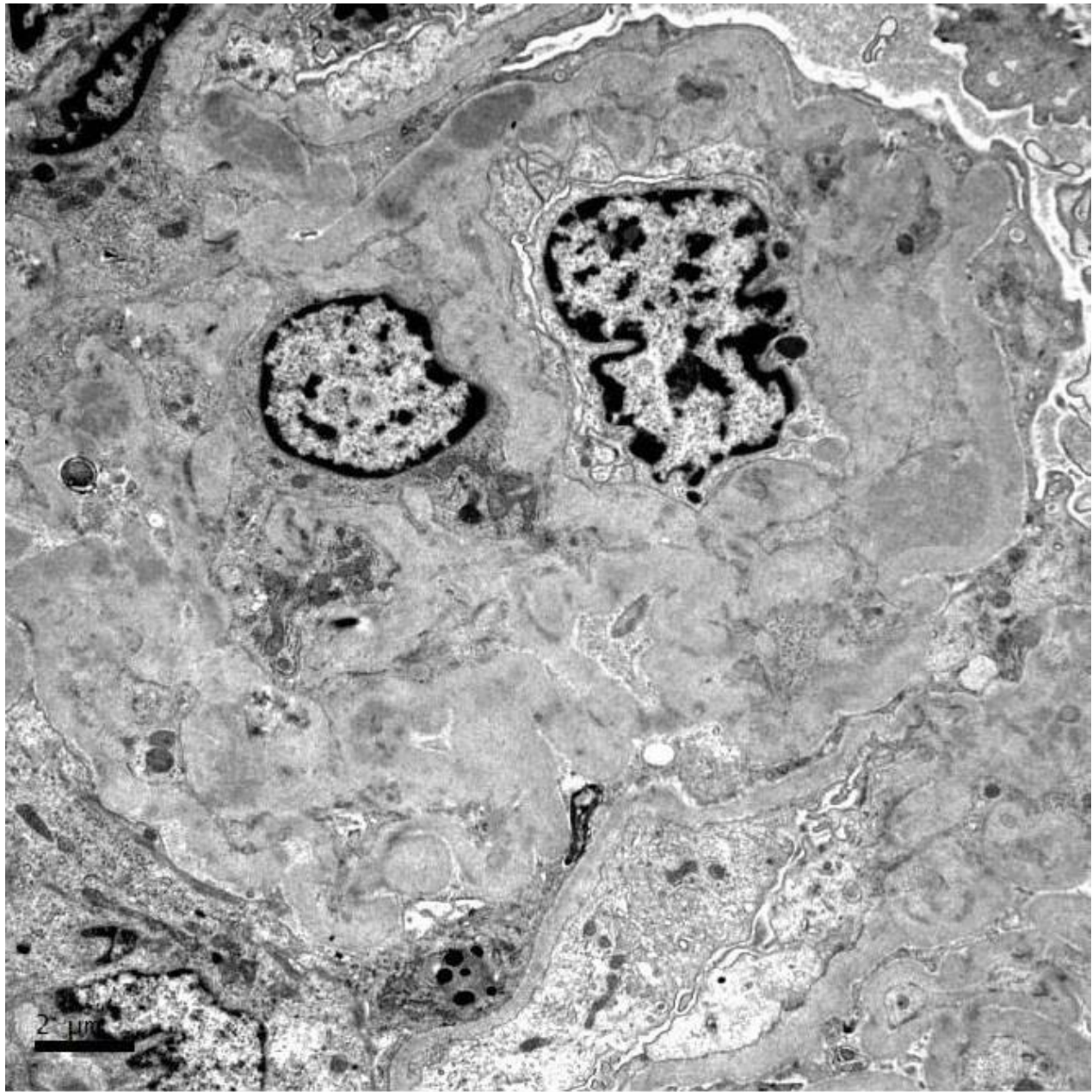














RENAL BIOPSY CLINICOPATHOLOGICAL WORKSHOP 2018



PATHOLOGY



Division of Pathology
Singapore General Hospital



Department of Renal Medicine
Singapore General Hospital



MEDICINE