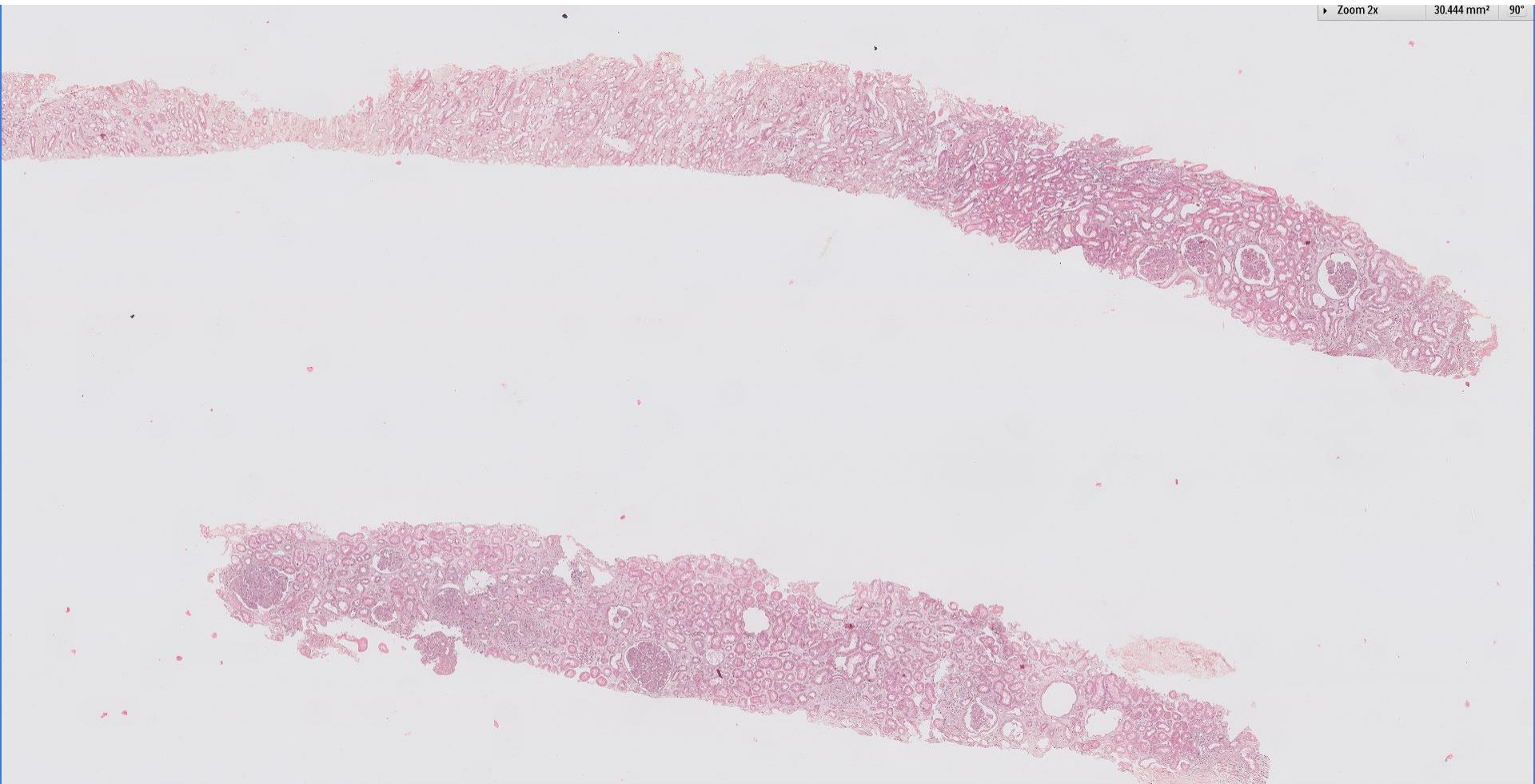
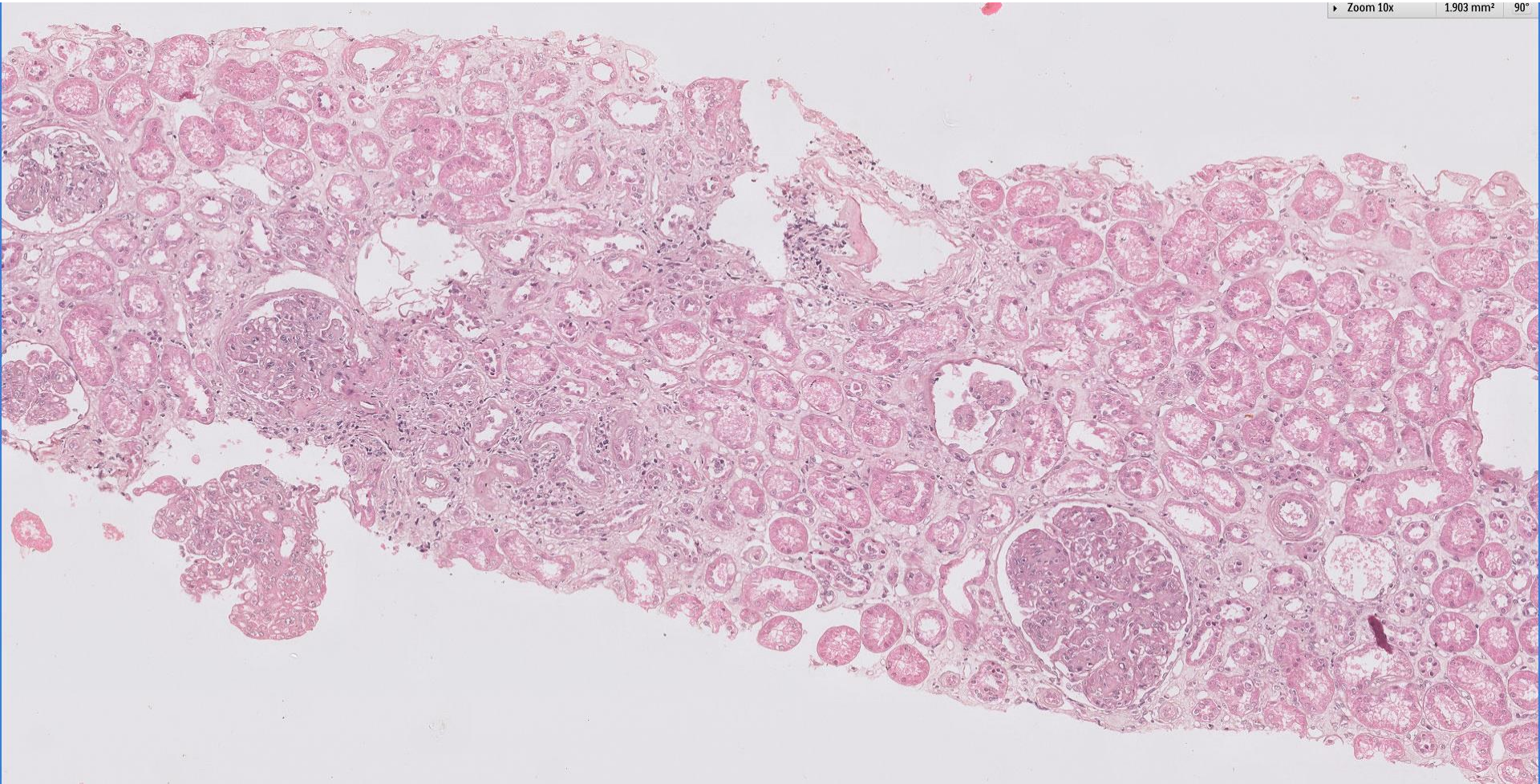
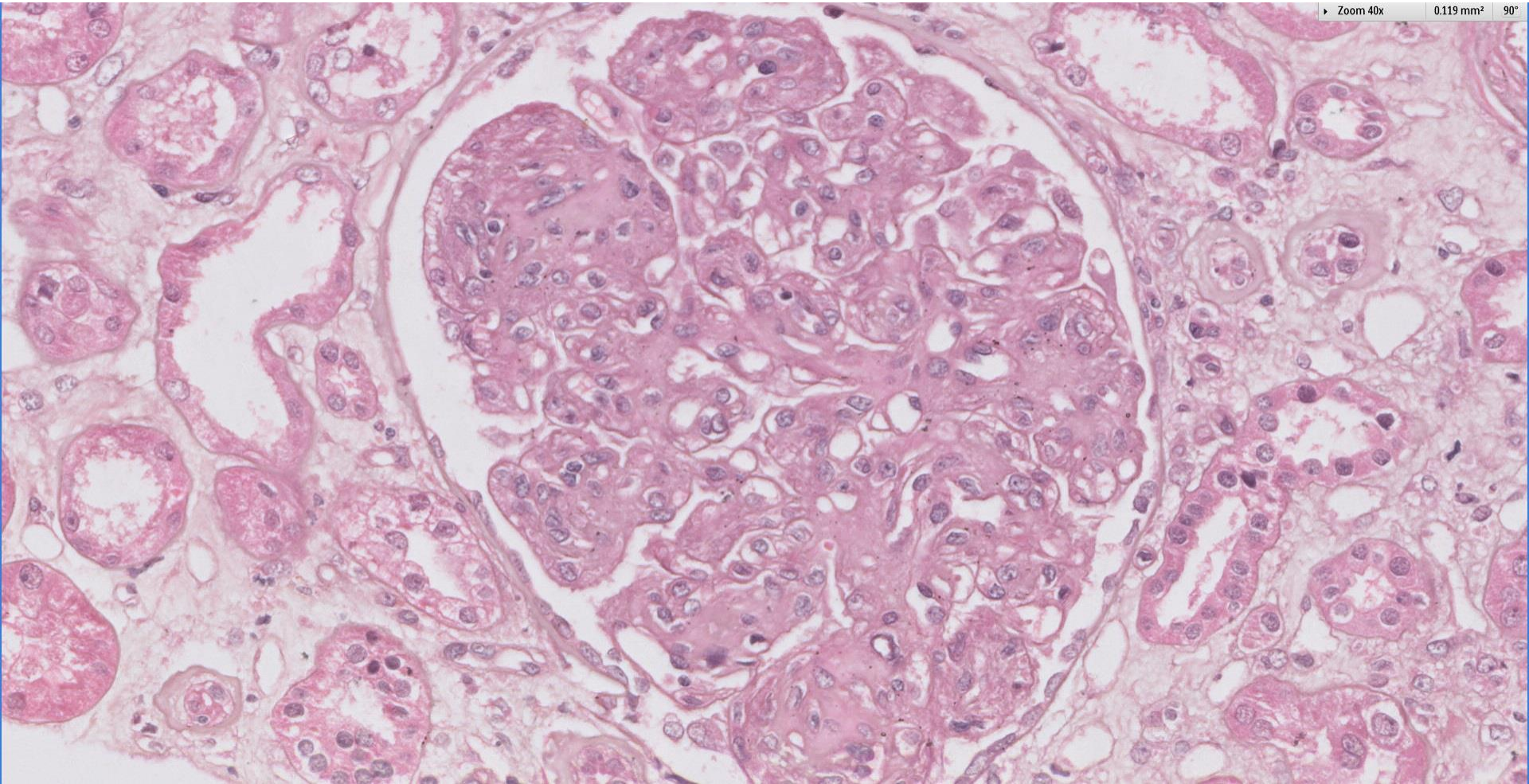


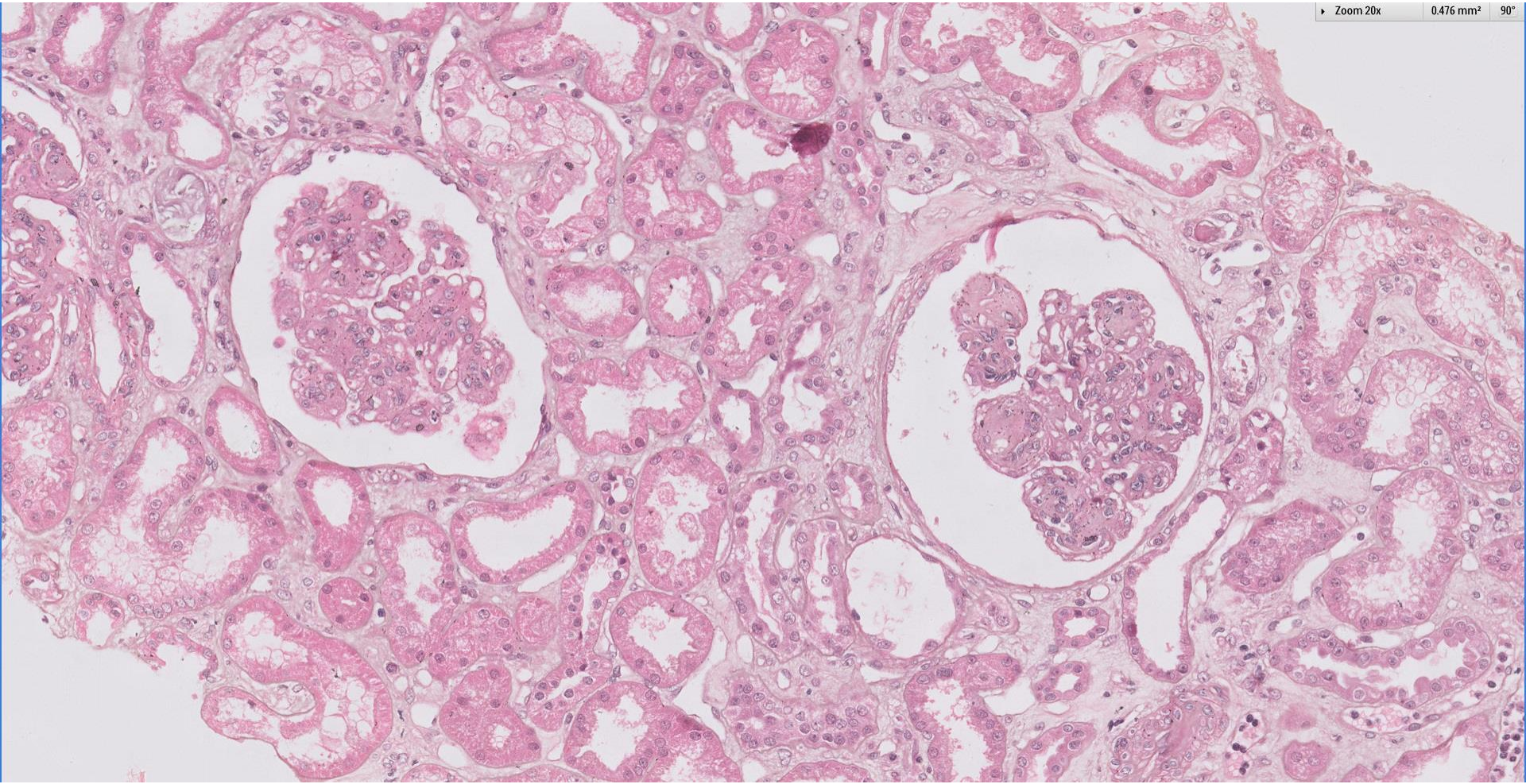
Case 28

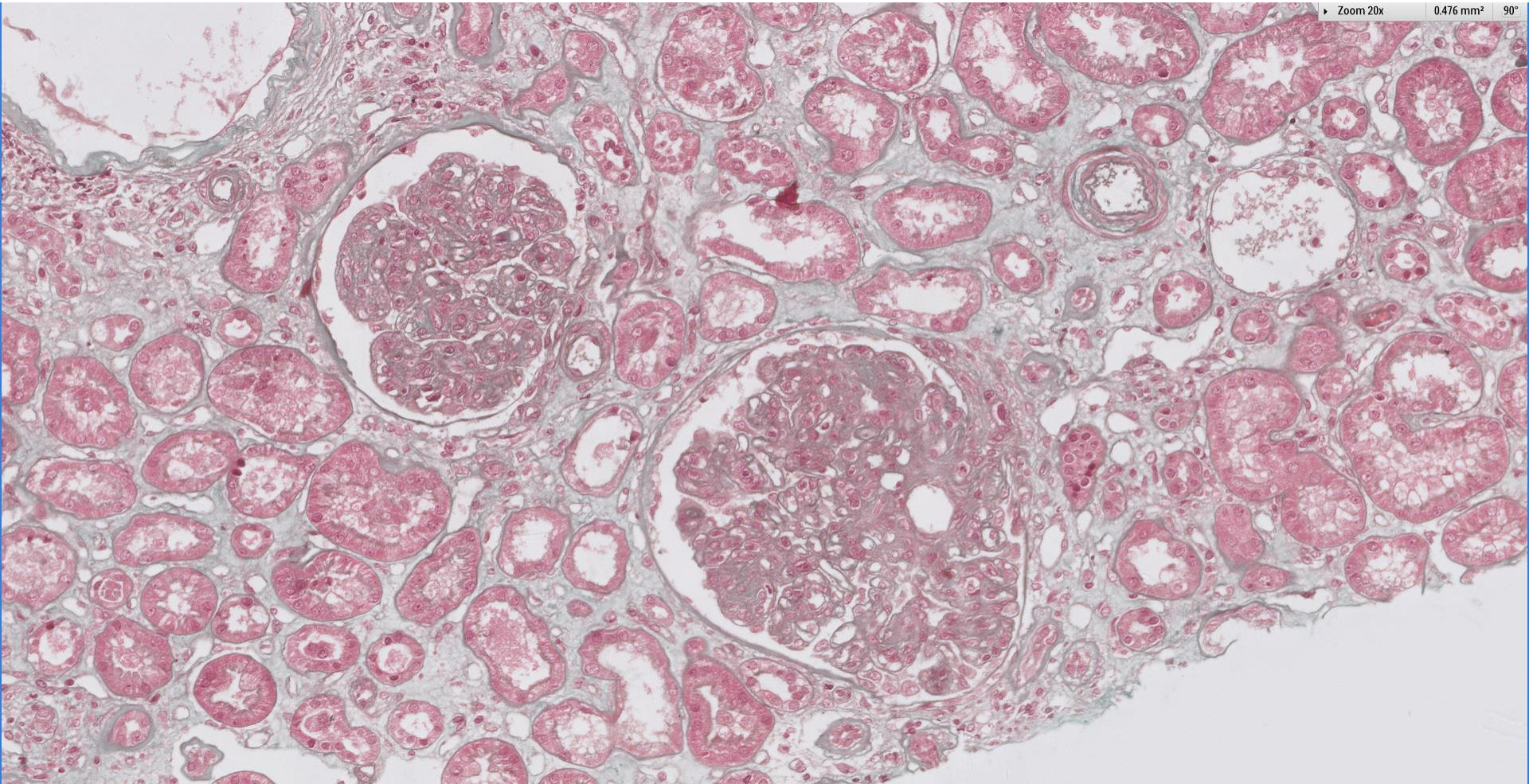
50 year old male with transaminitis and UPCR 2.5 g/g.

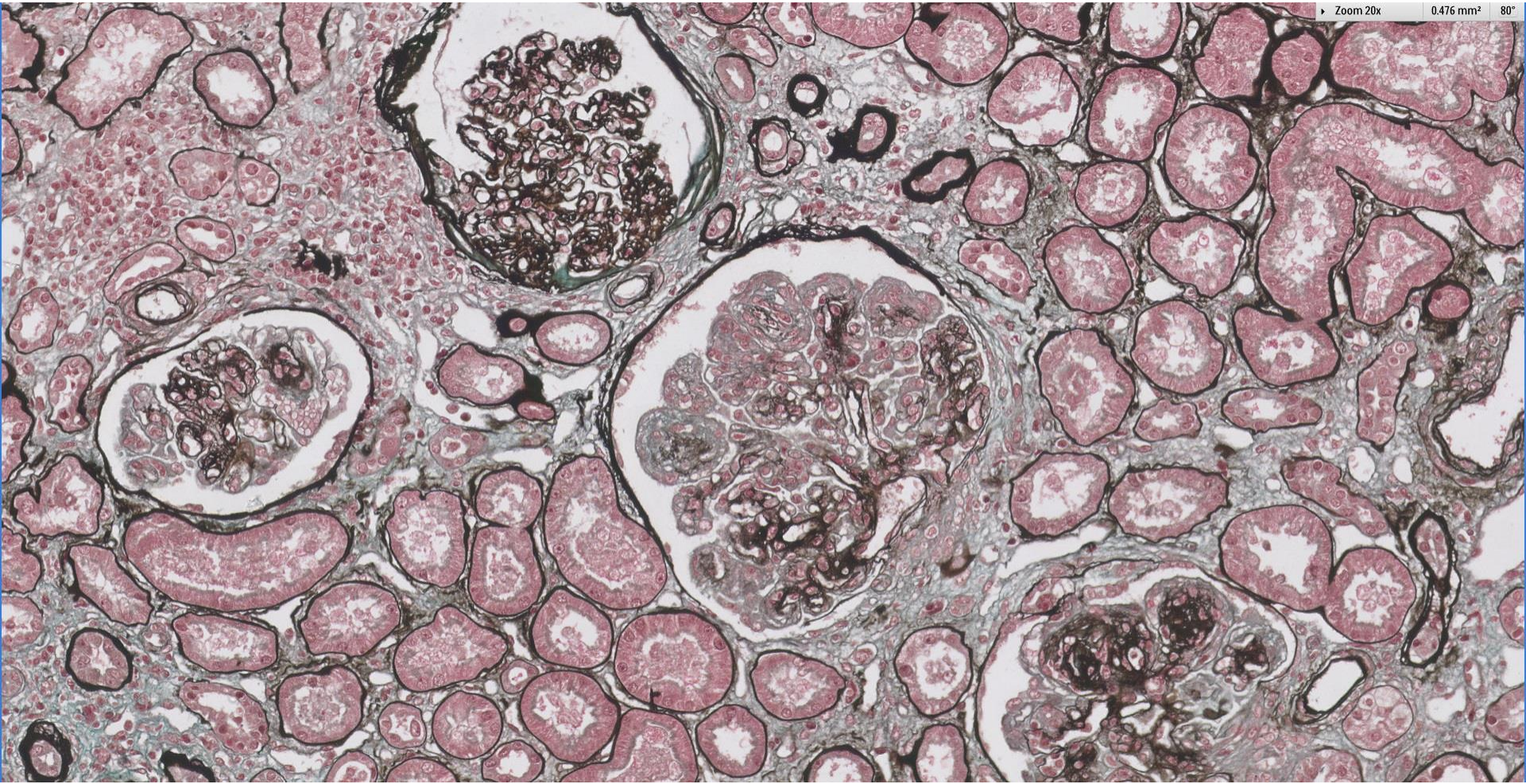




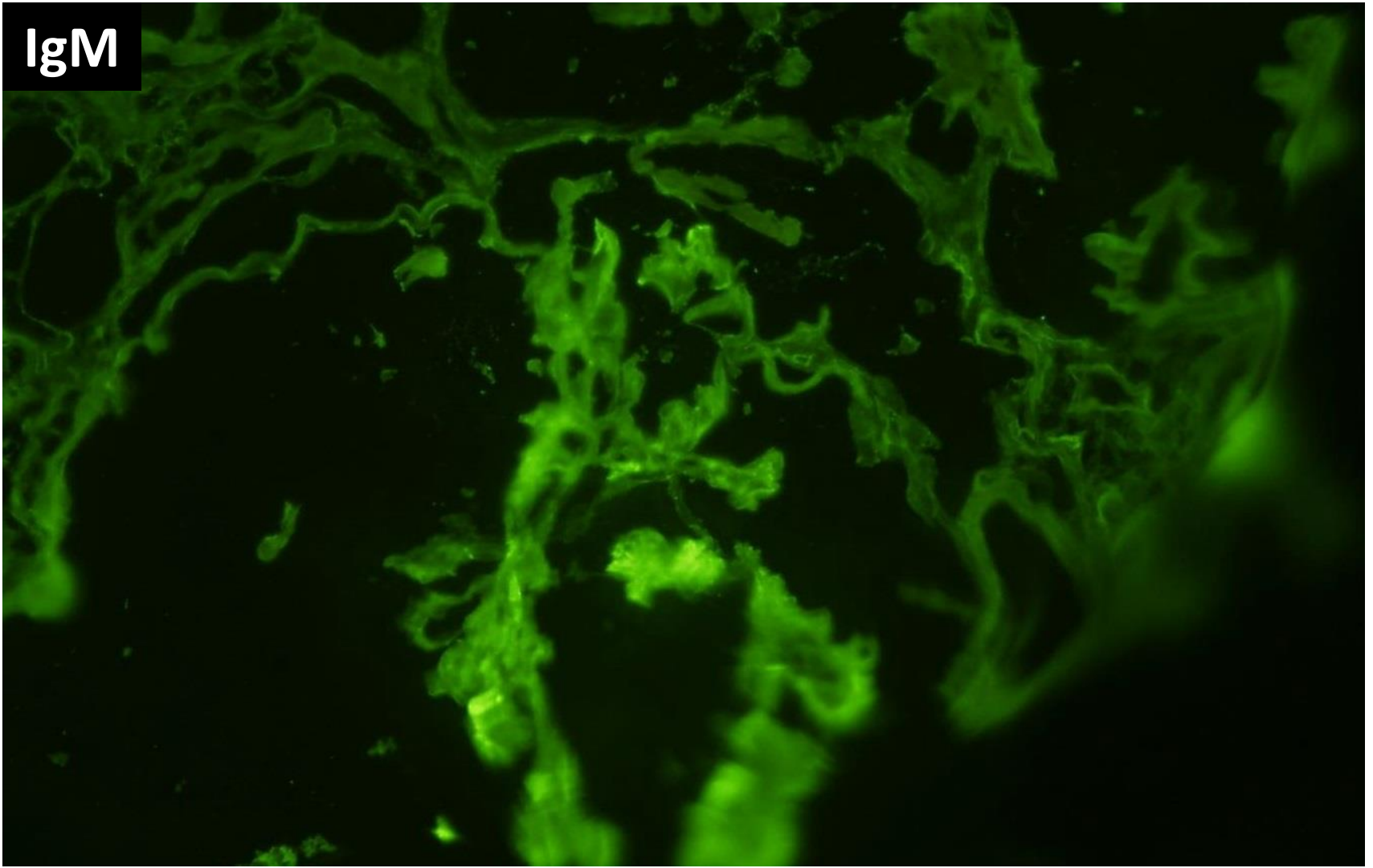




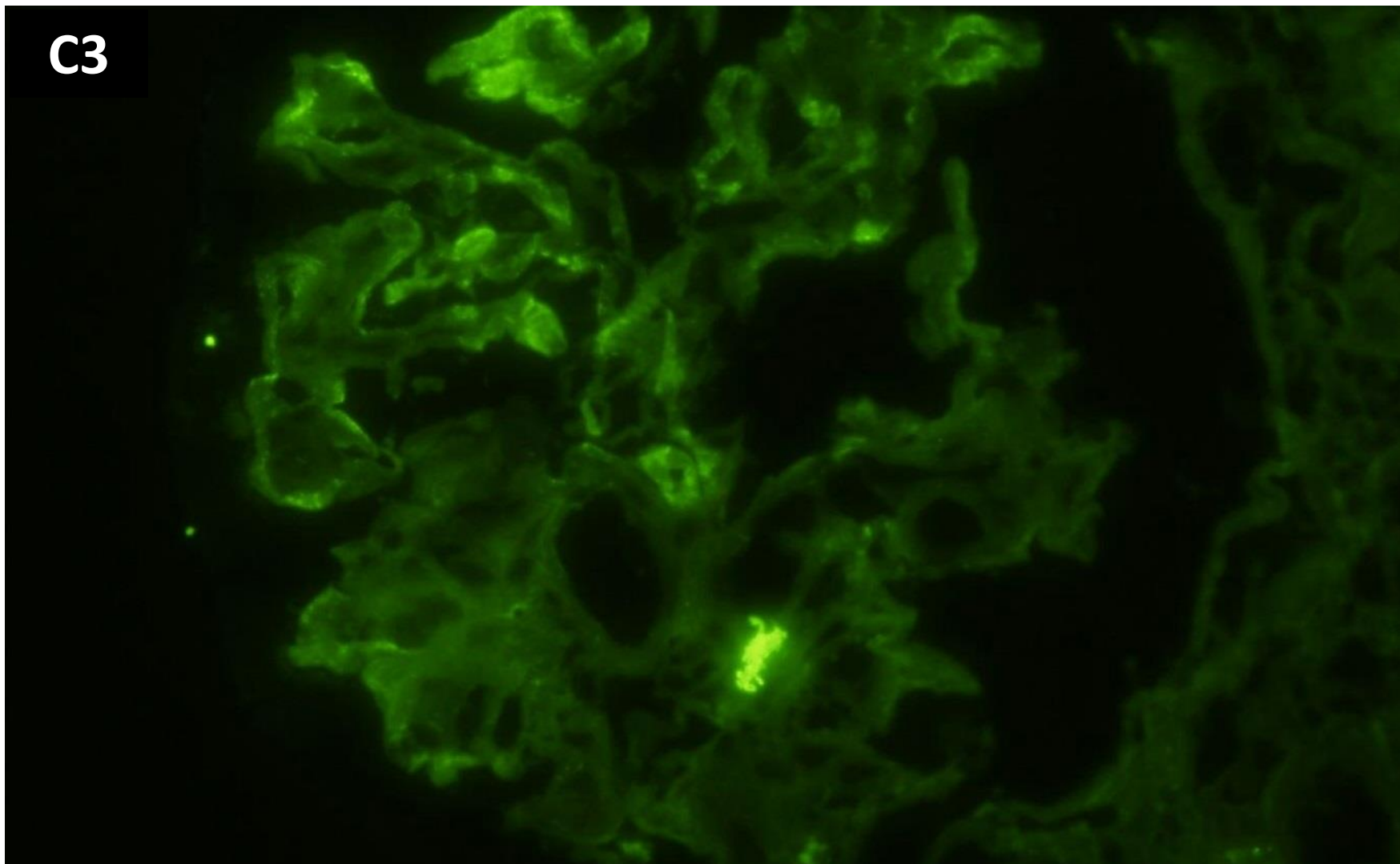




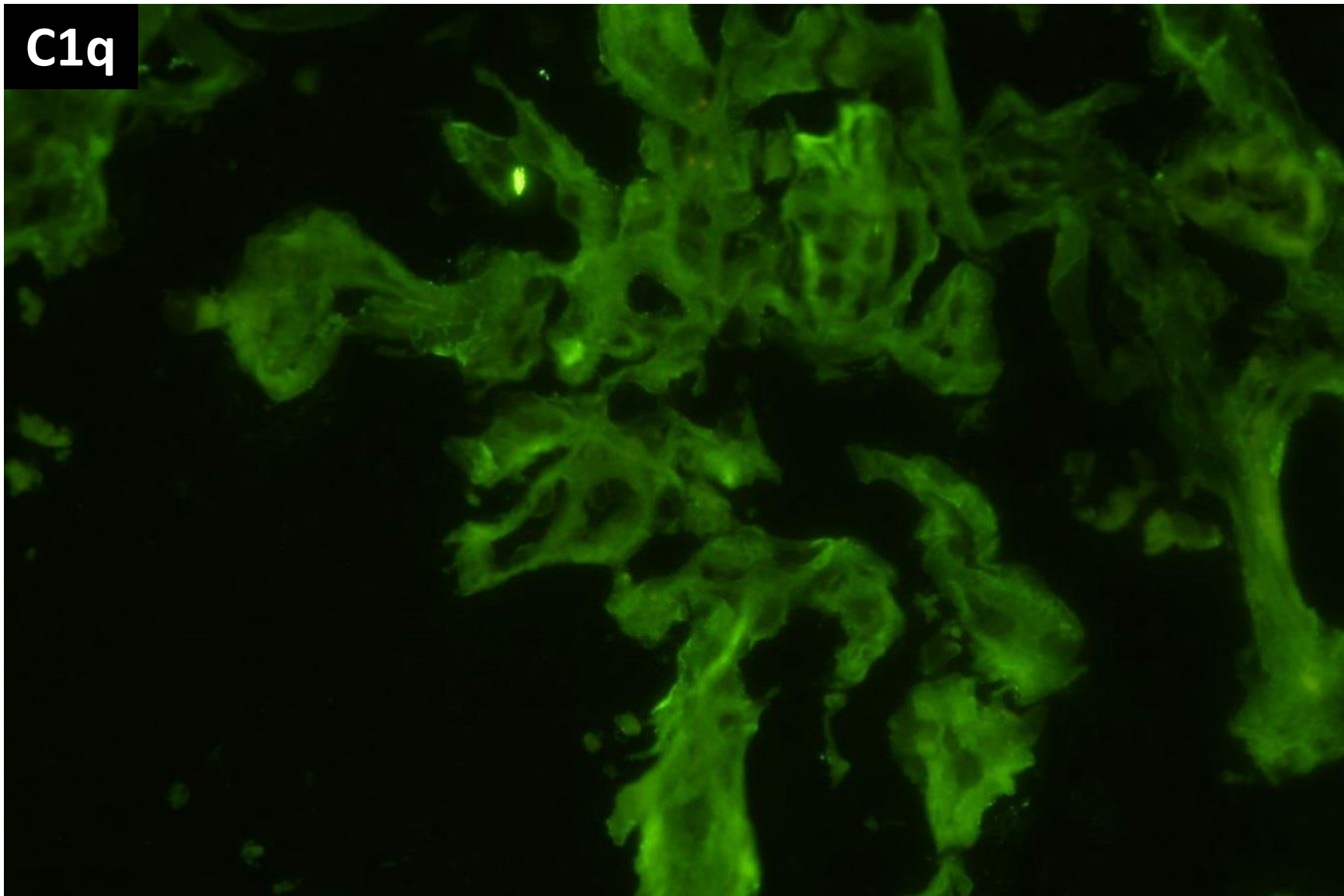
IgM

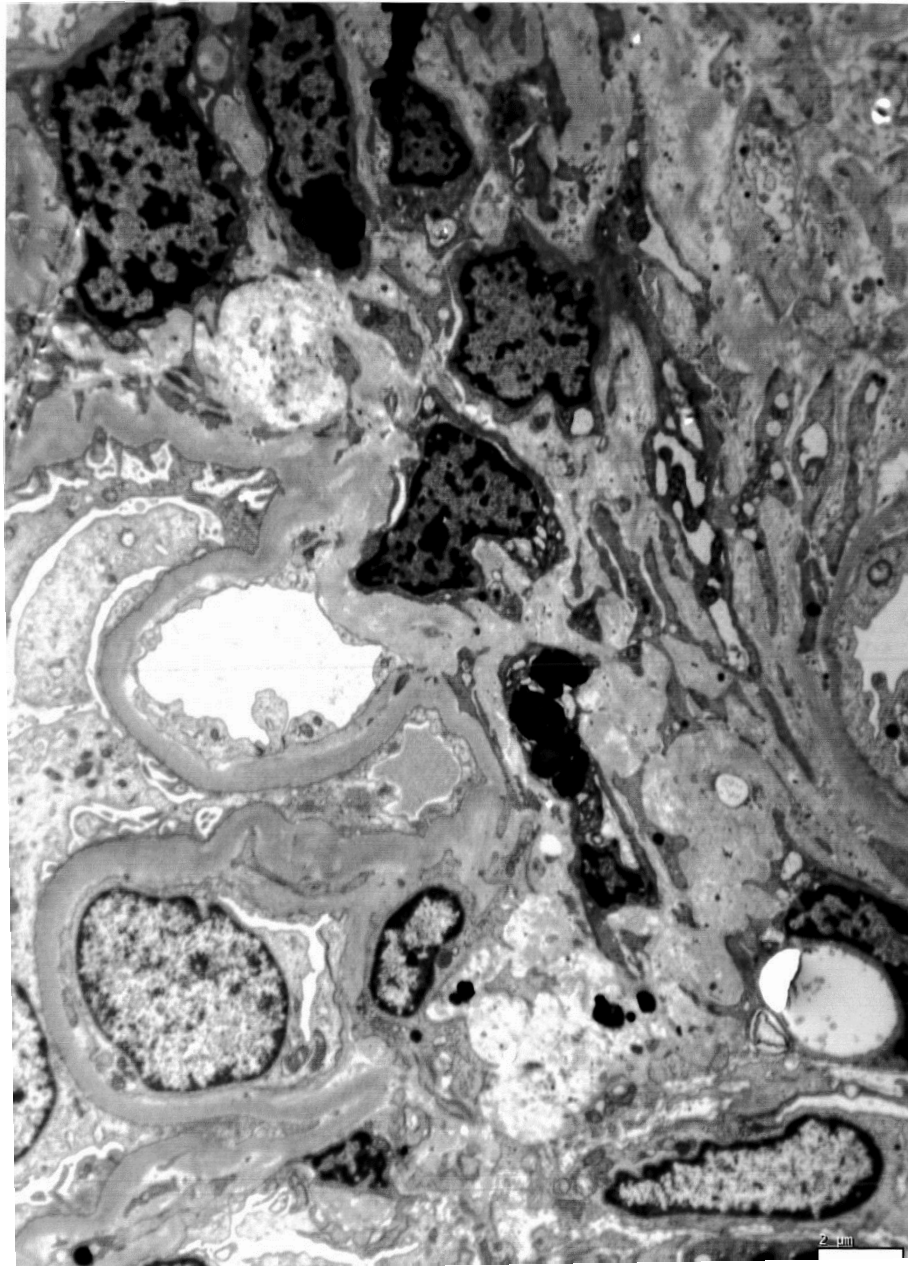


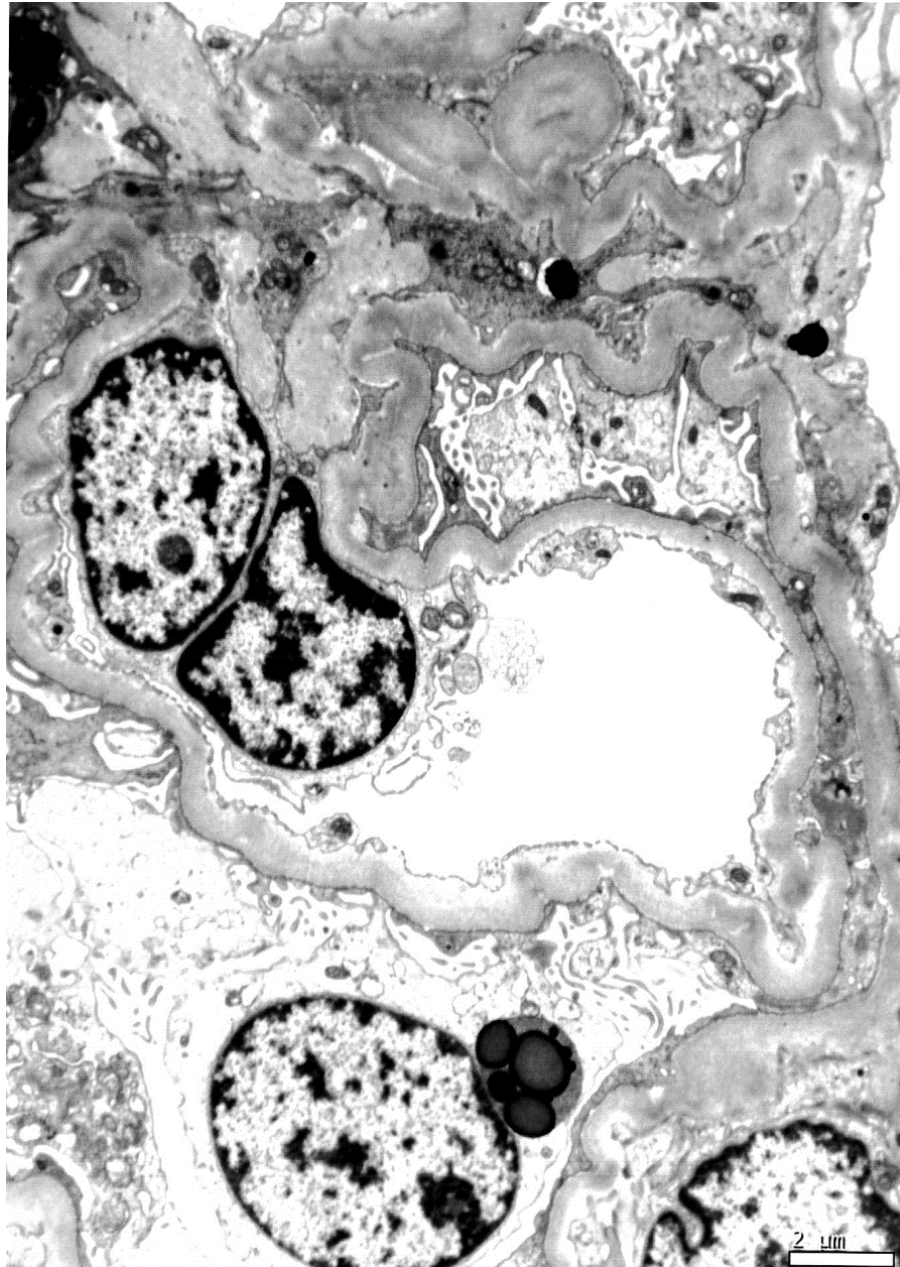
C3

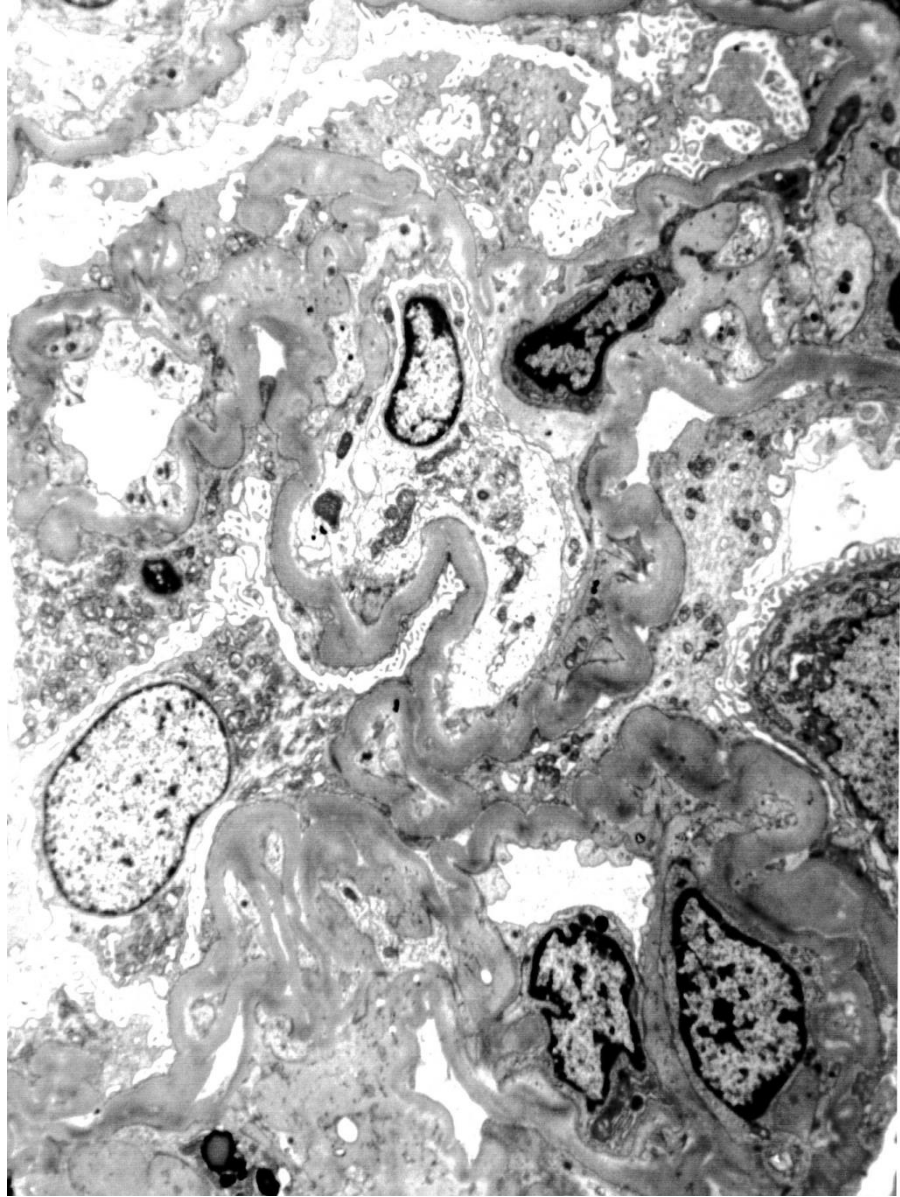


C1q











RENAL BIOPSY CLINICOPATHOLOGICAL WORKSHOP 2018



PATHOLOGY



Division of Pathology
Singapore General Hospital



Department of Renal Medicine
Singapore General Hospital



MEDICINE