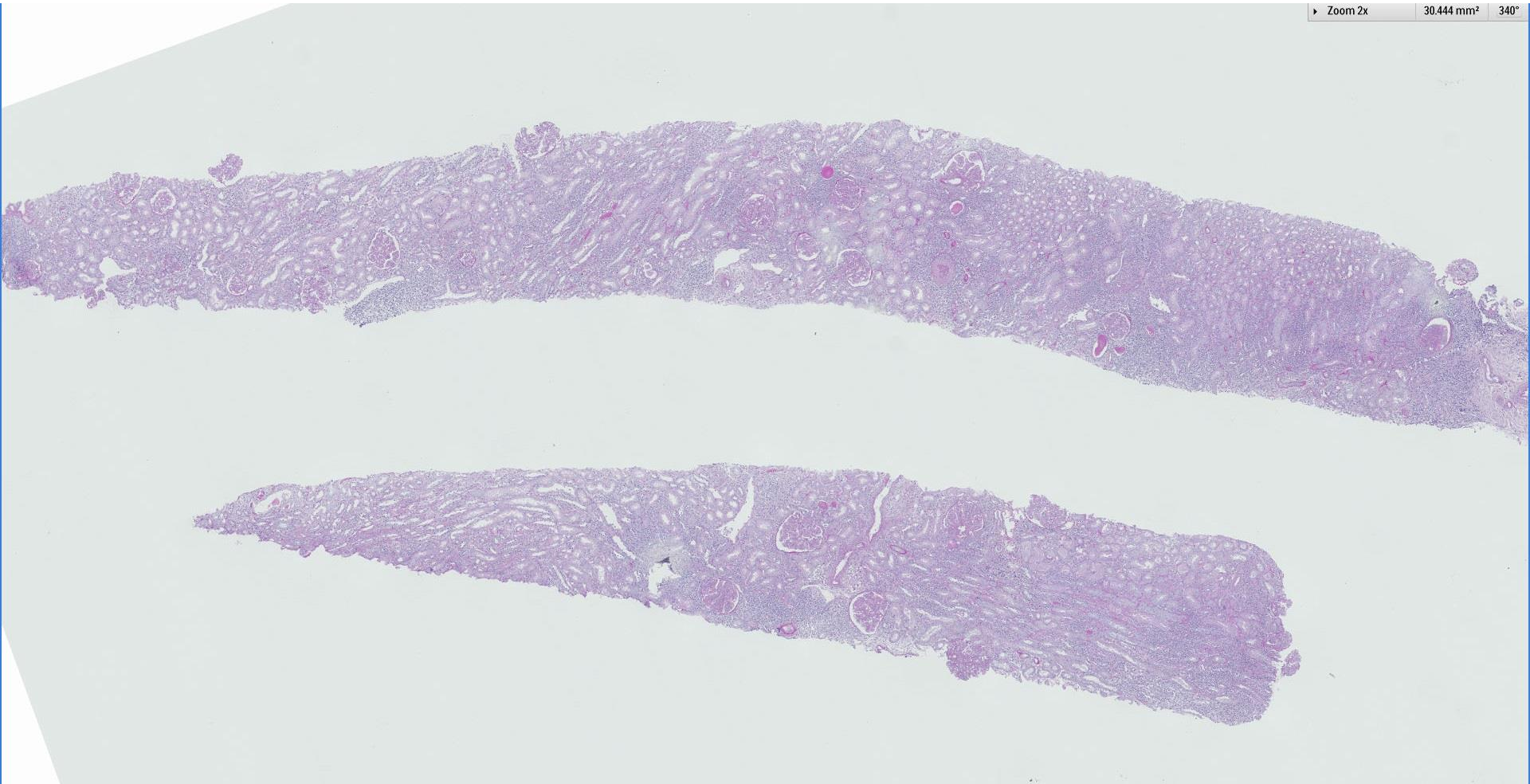
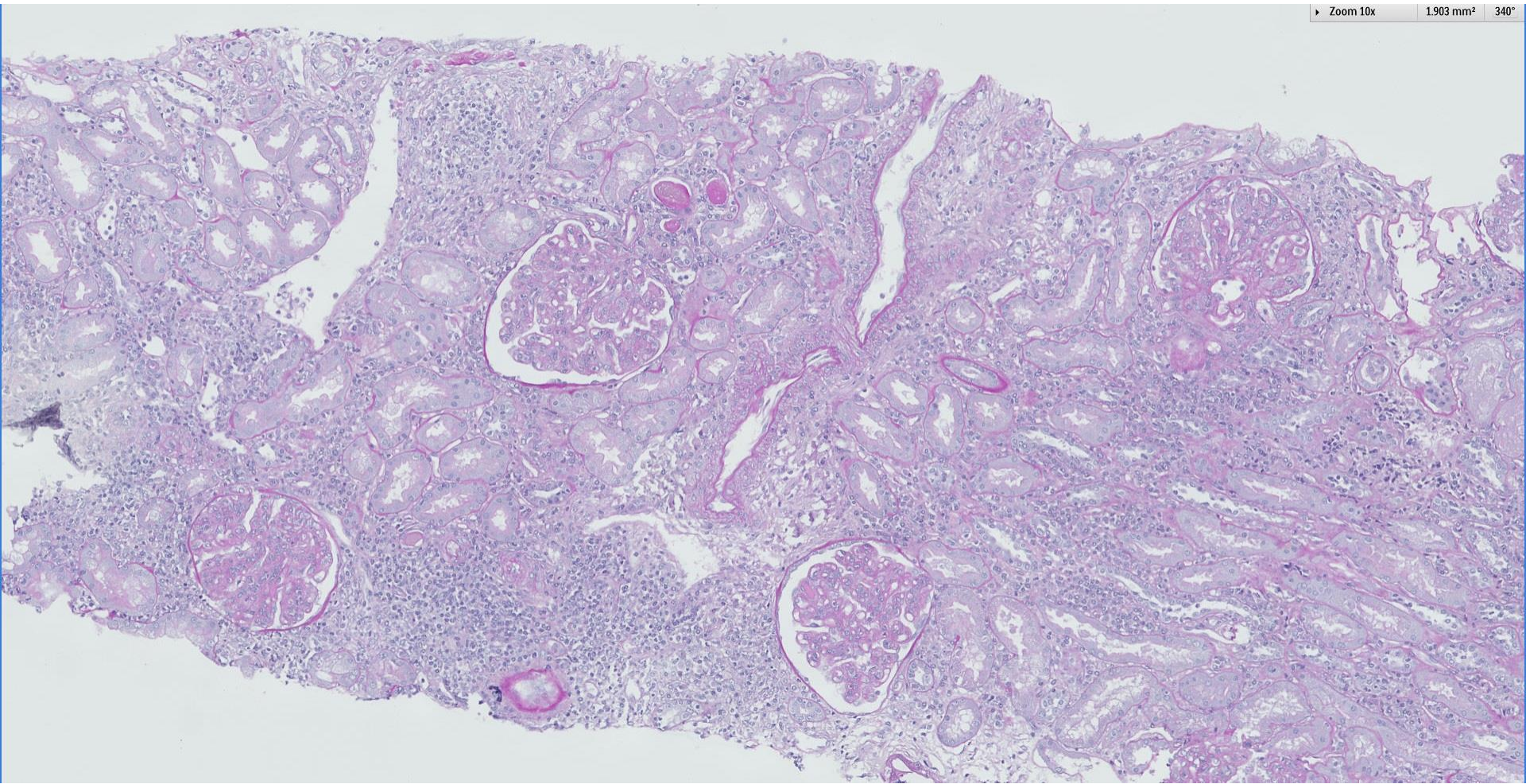


## Case 27

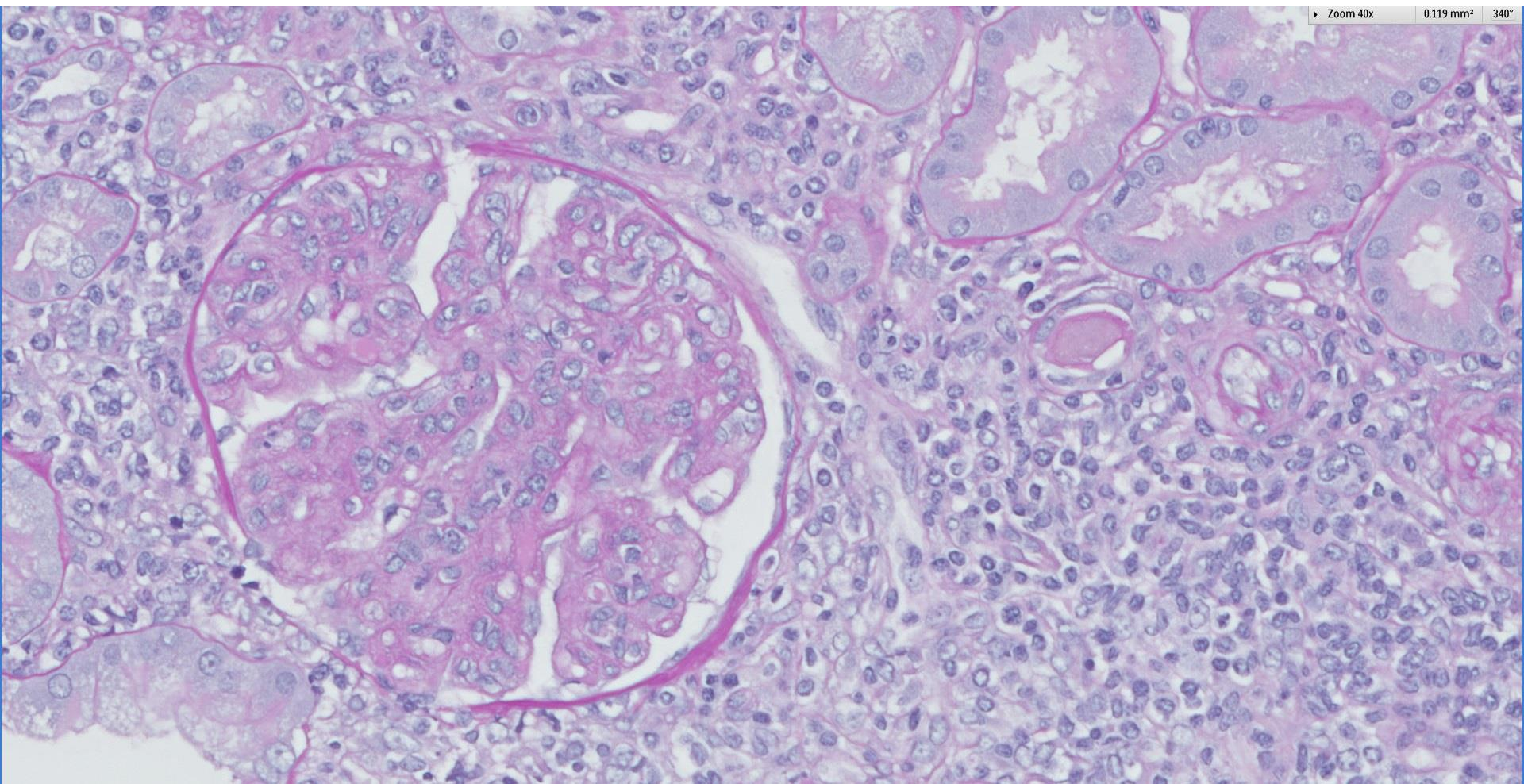
49 year old female hepatitis B carrier with leucocytoclastic vasculitis and Sjogren's syndrome, presents with microscopic haematuria and proteinuria (24h UTP 0.6g/day) and low serum complements.







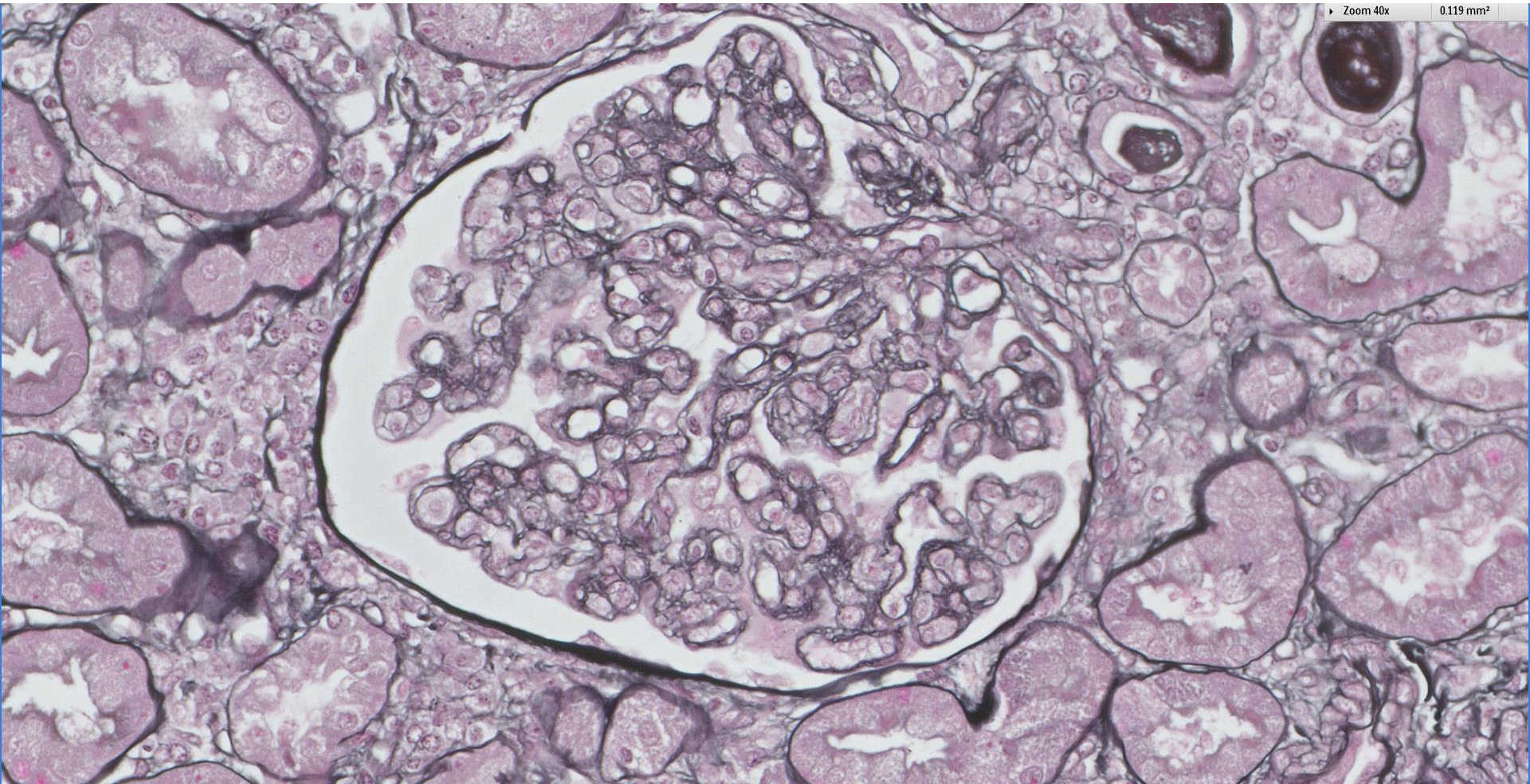






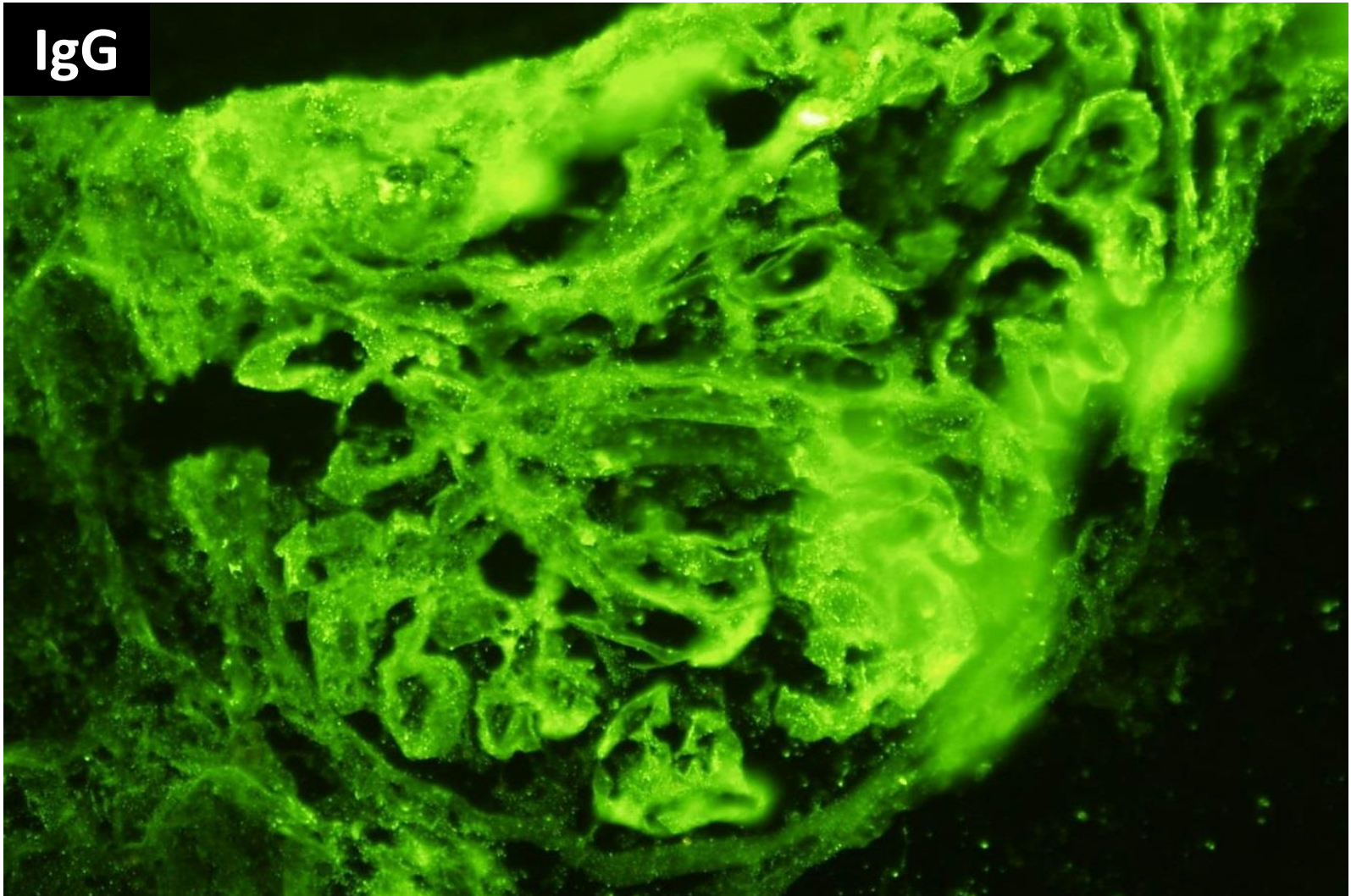
Zoom 40x

0.119 mm<sup>2</sup>

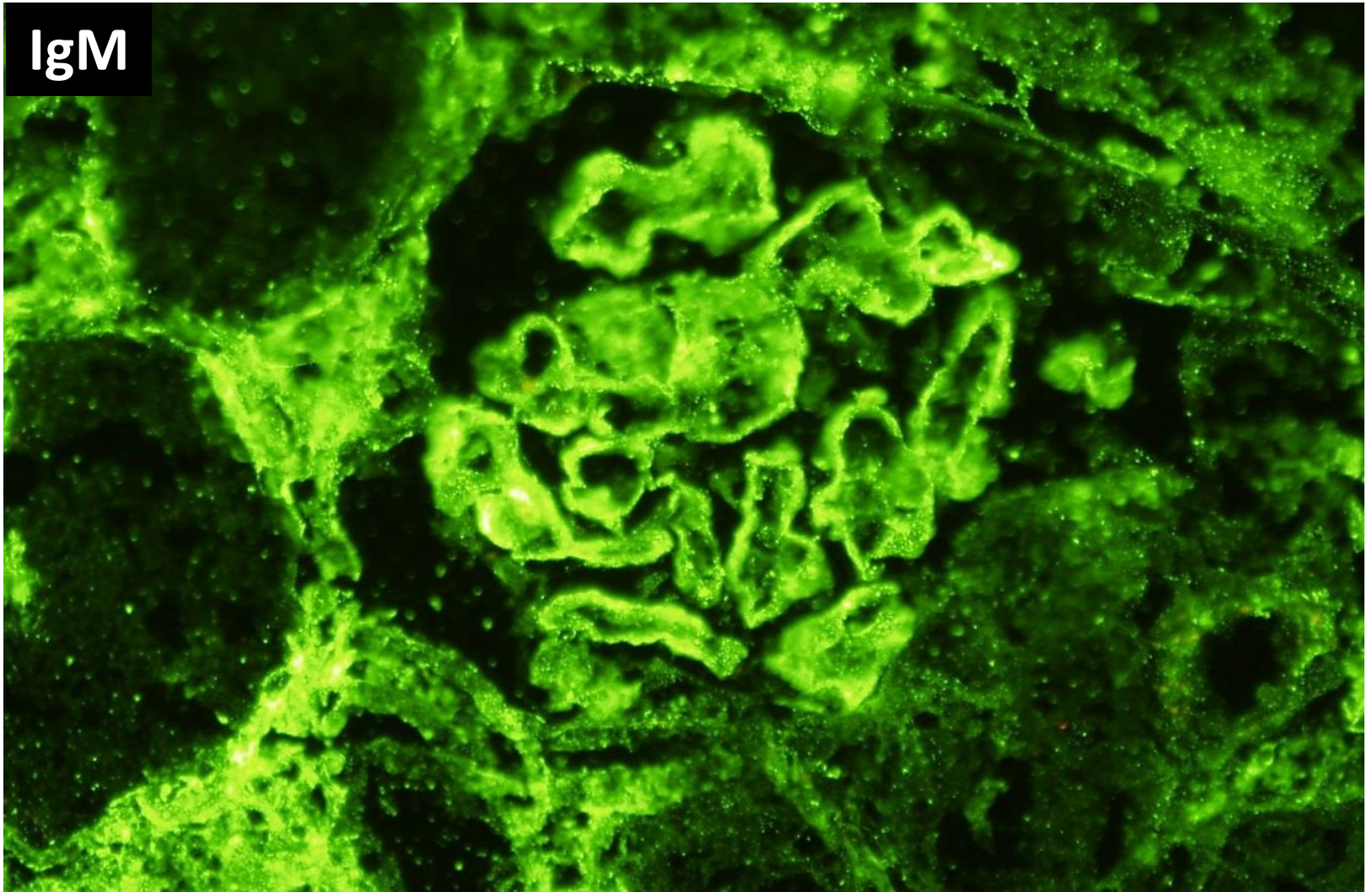




IgG

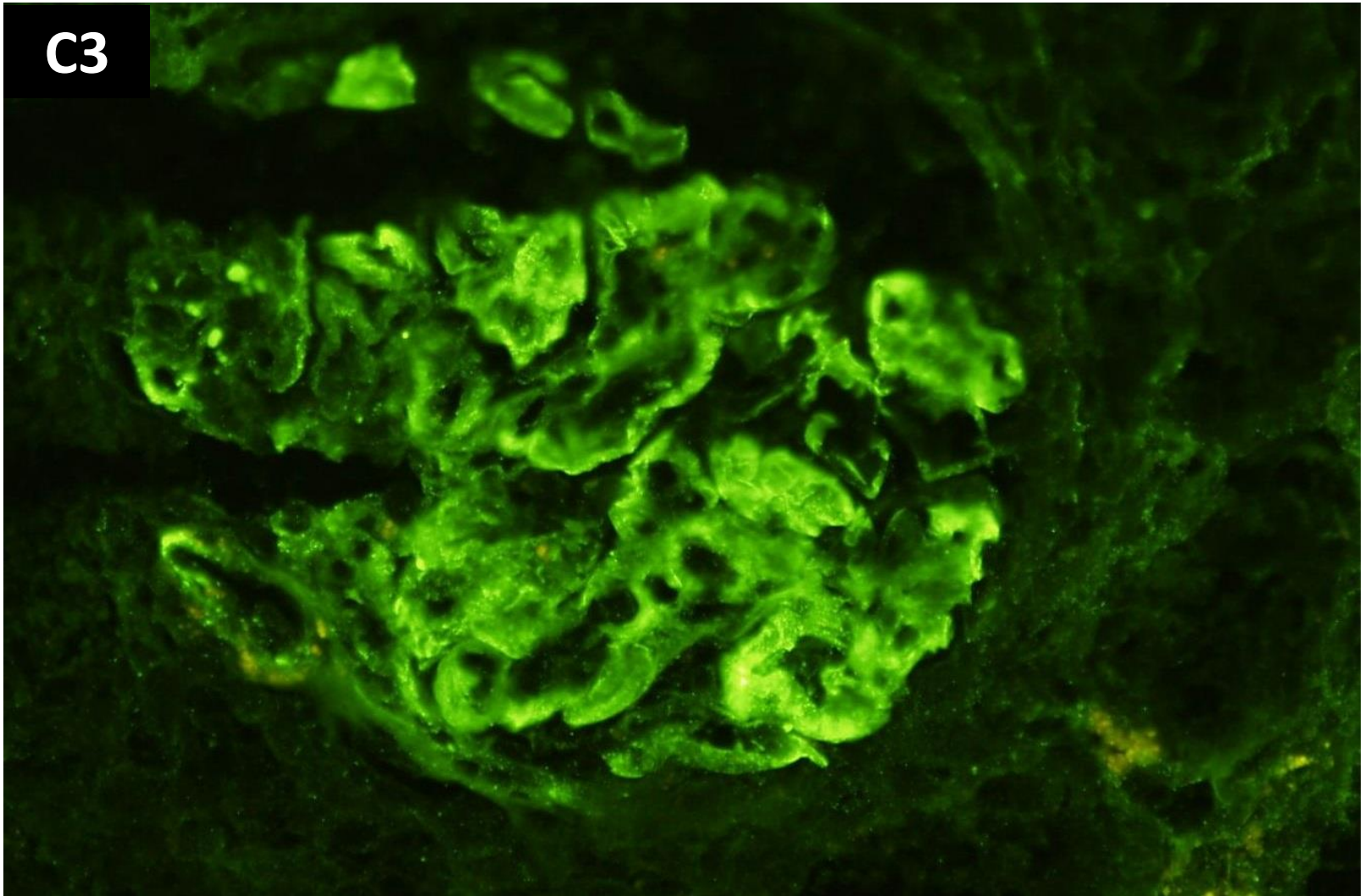


IgM



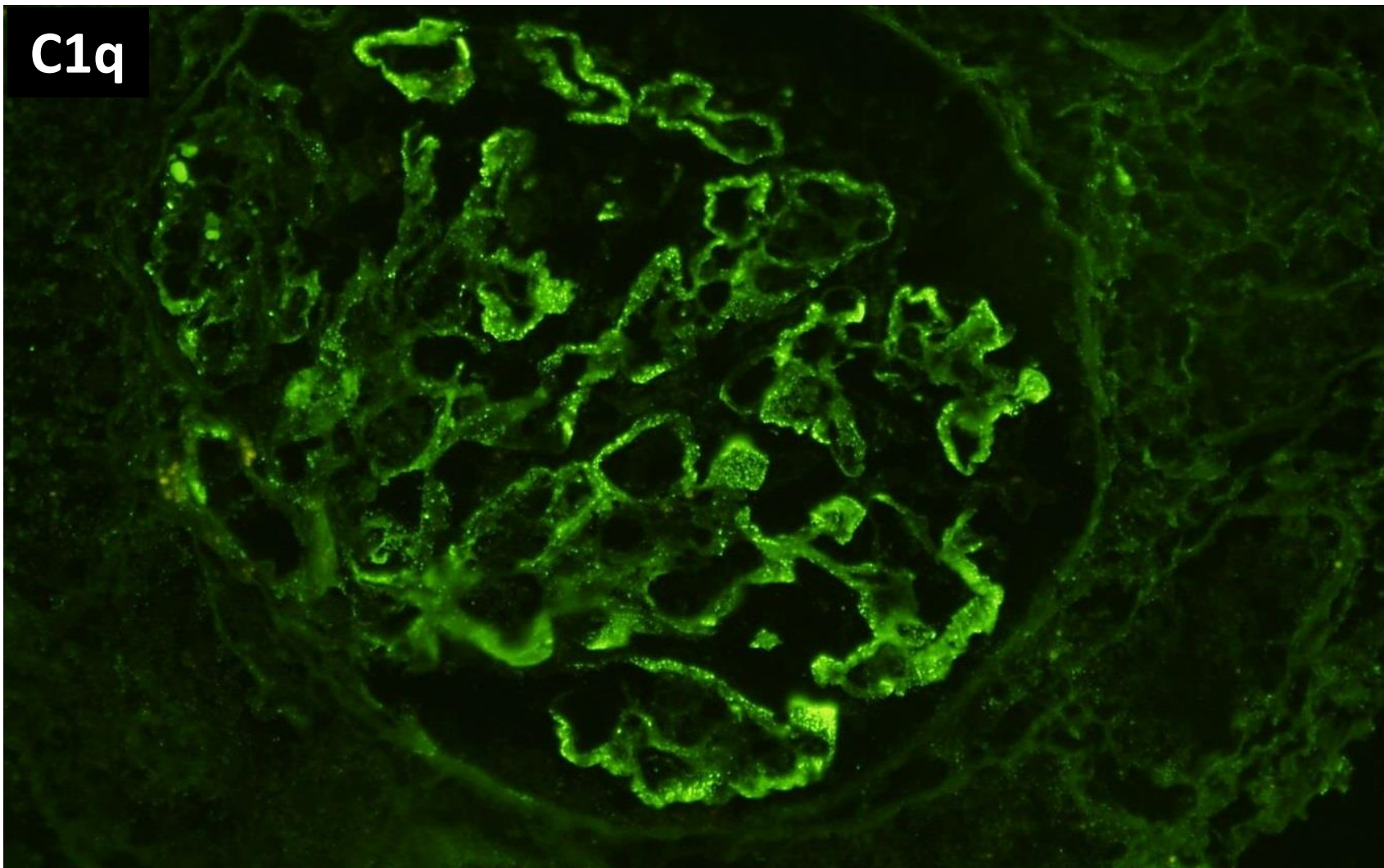


C3

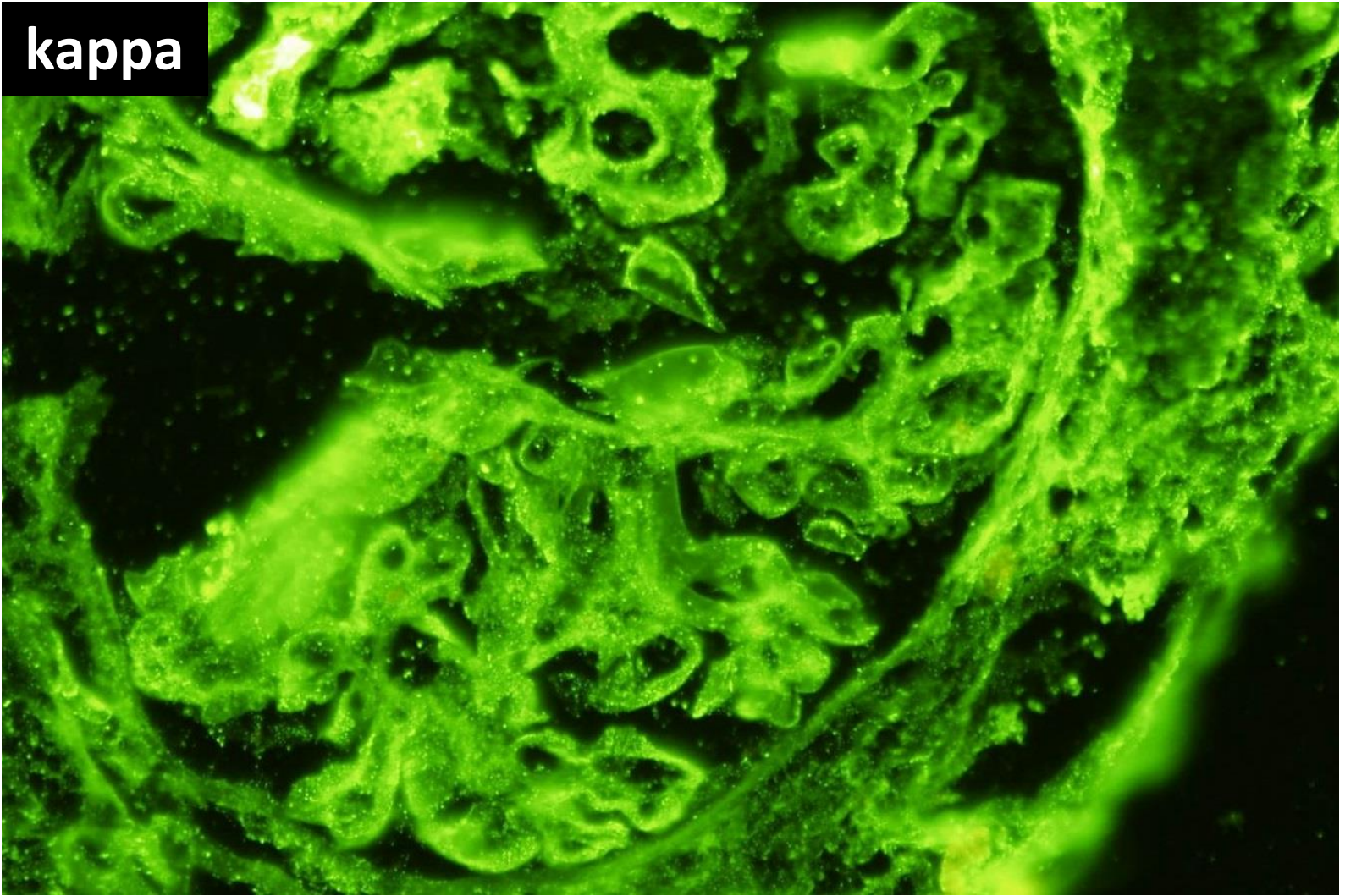




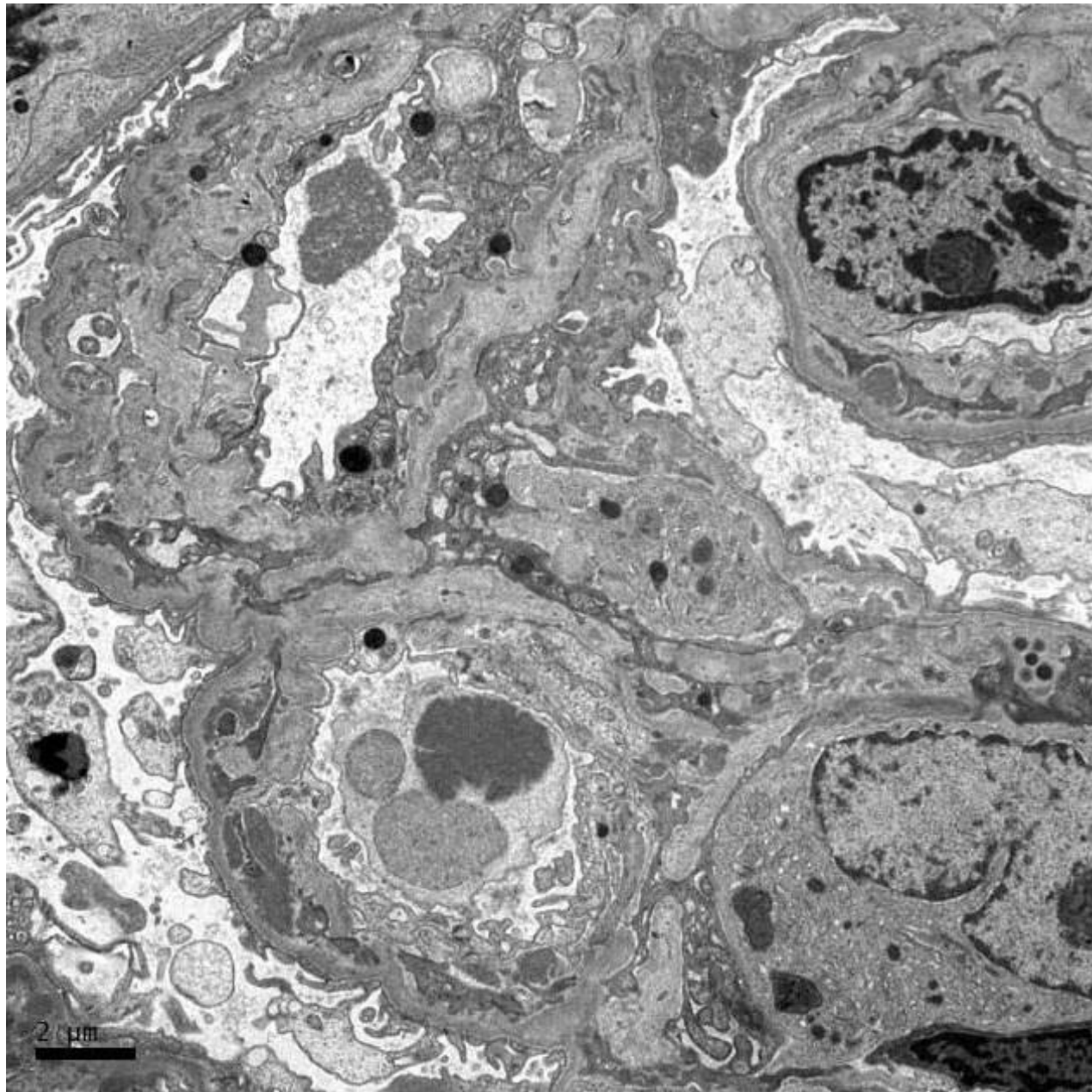
**C1q**

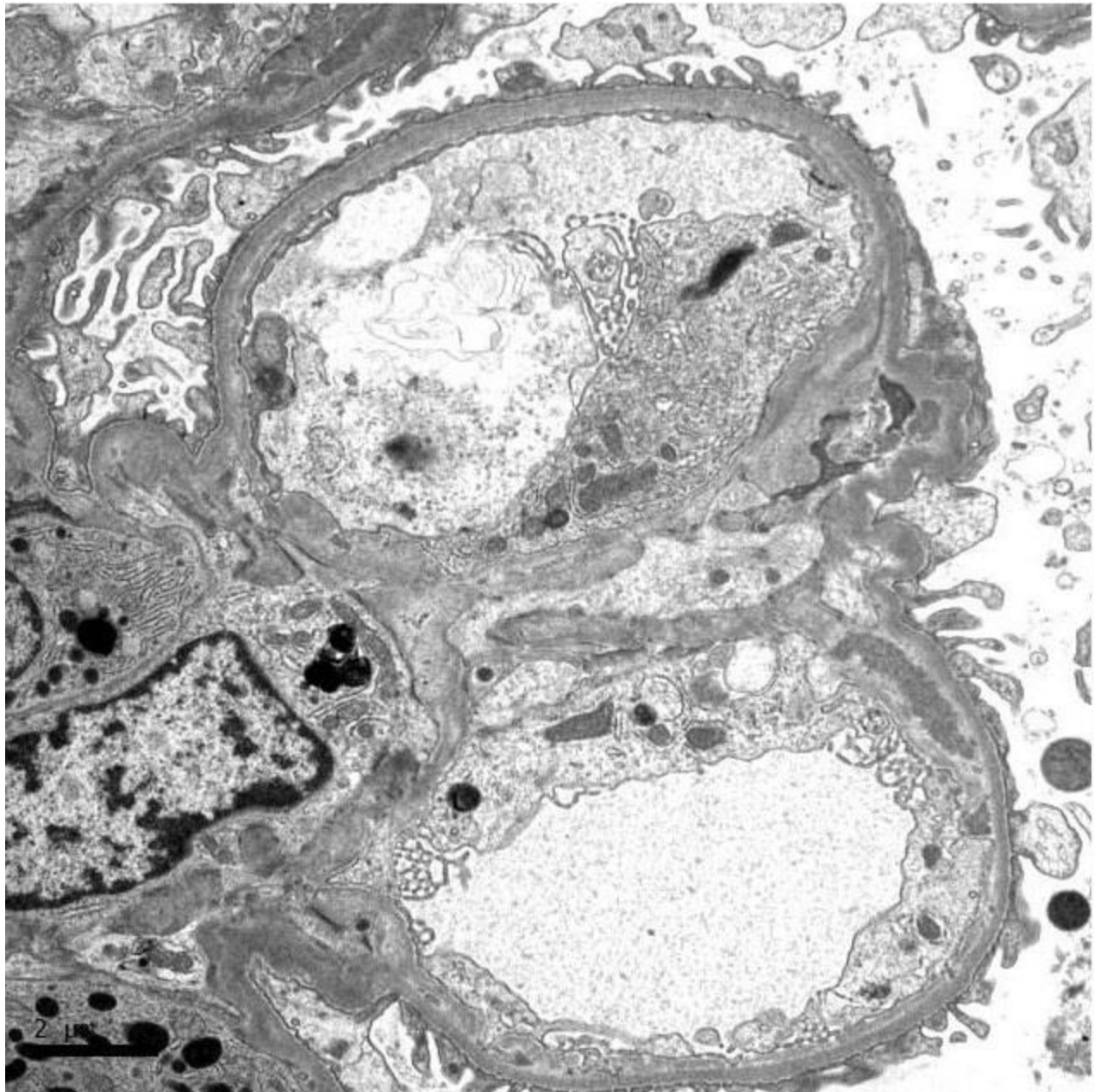


kappa

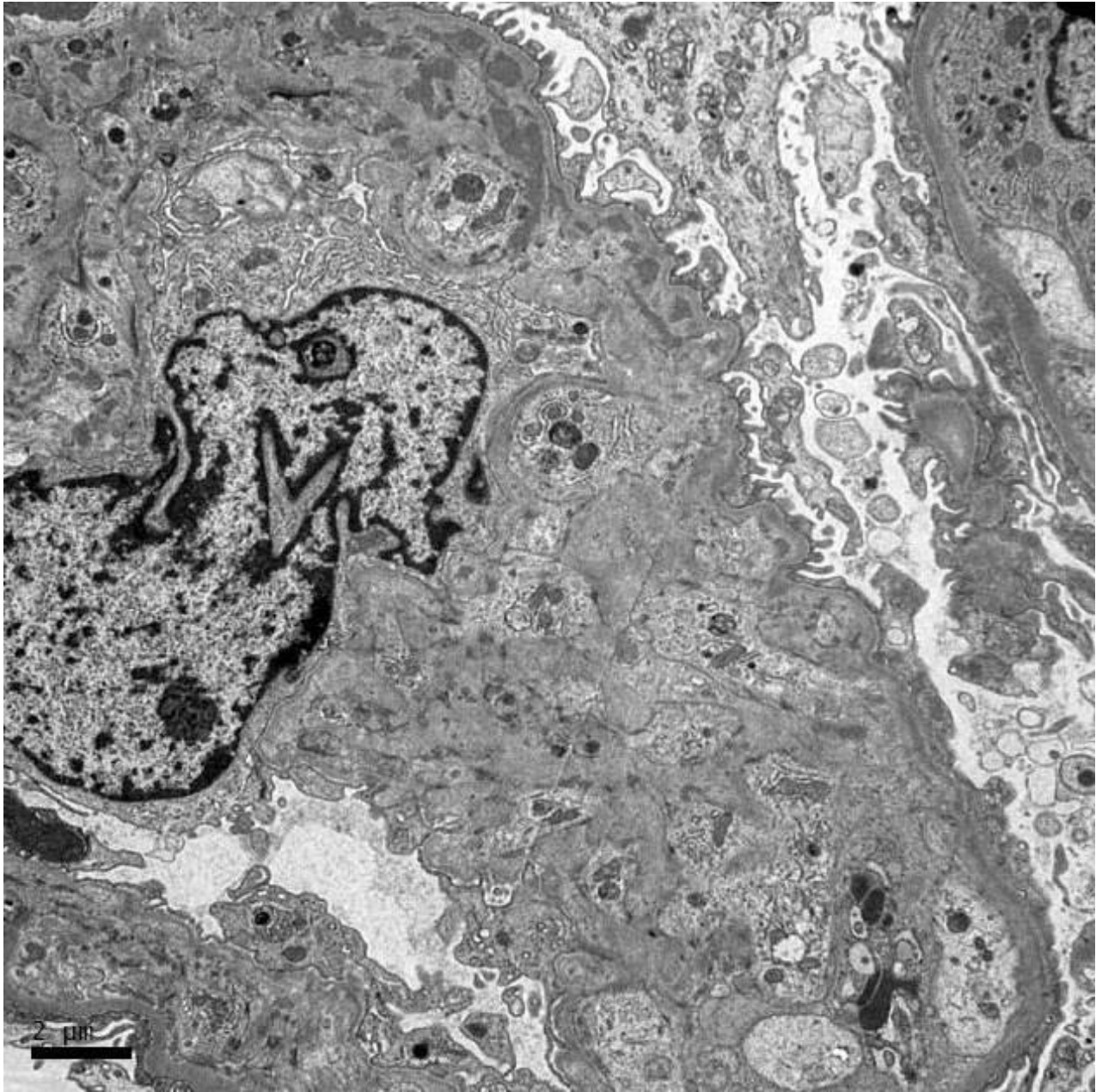


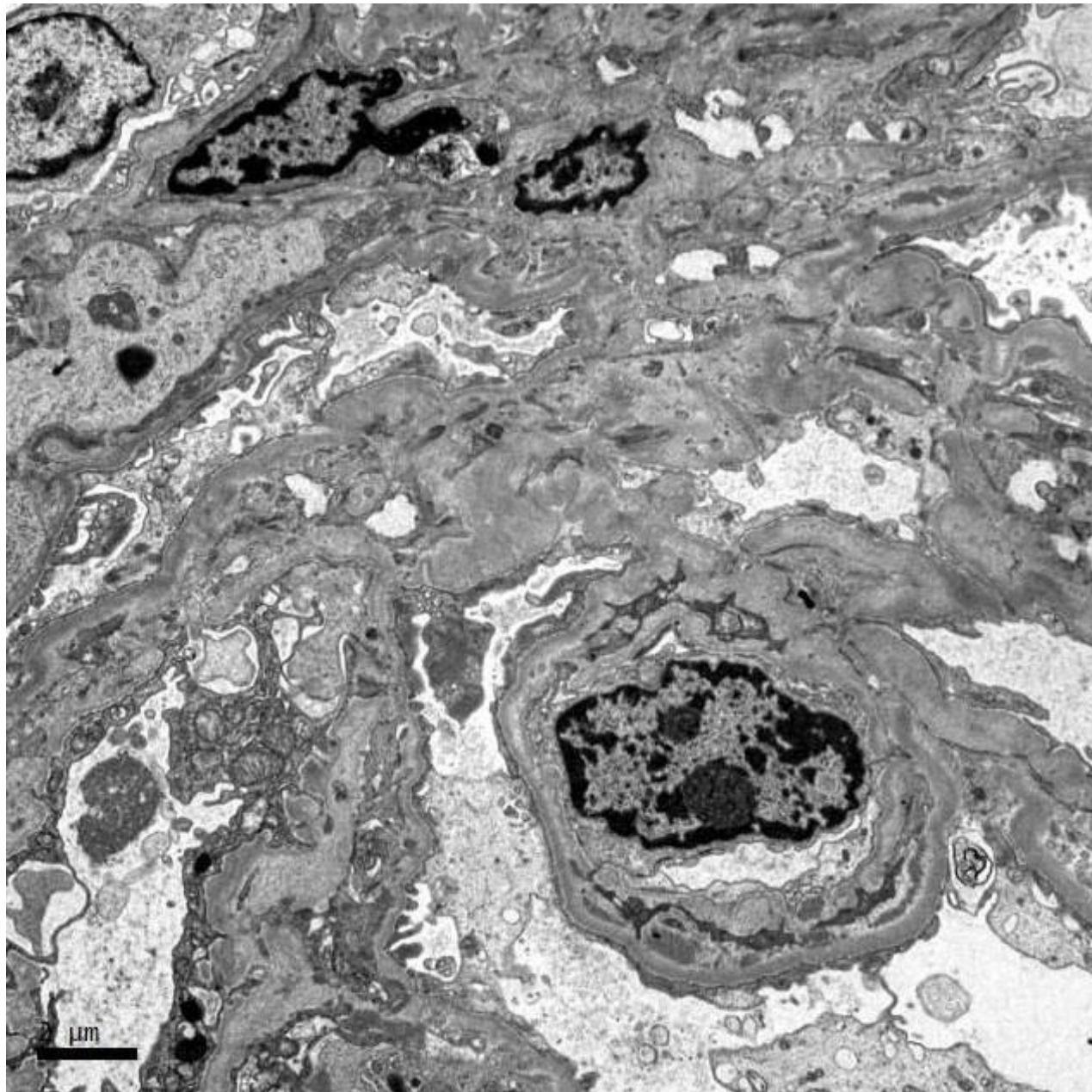




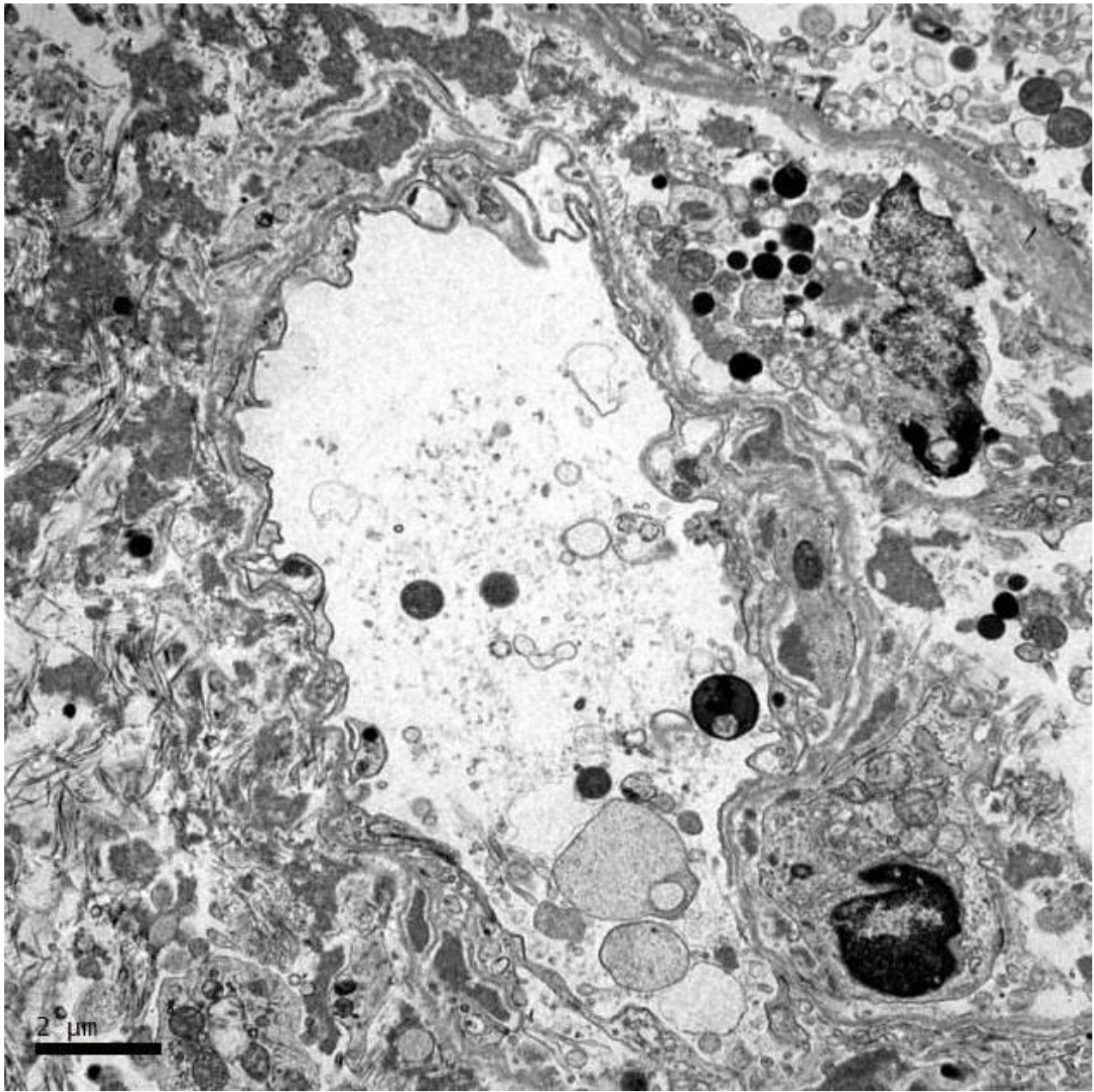


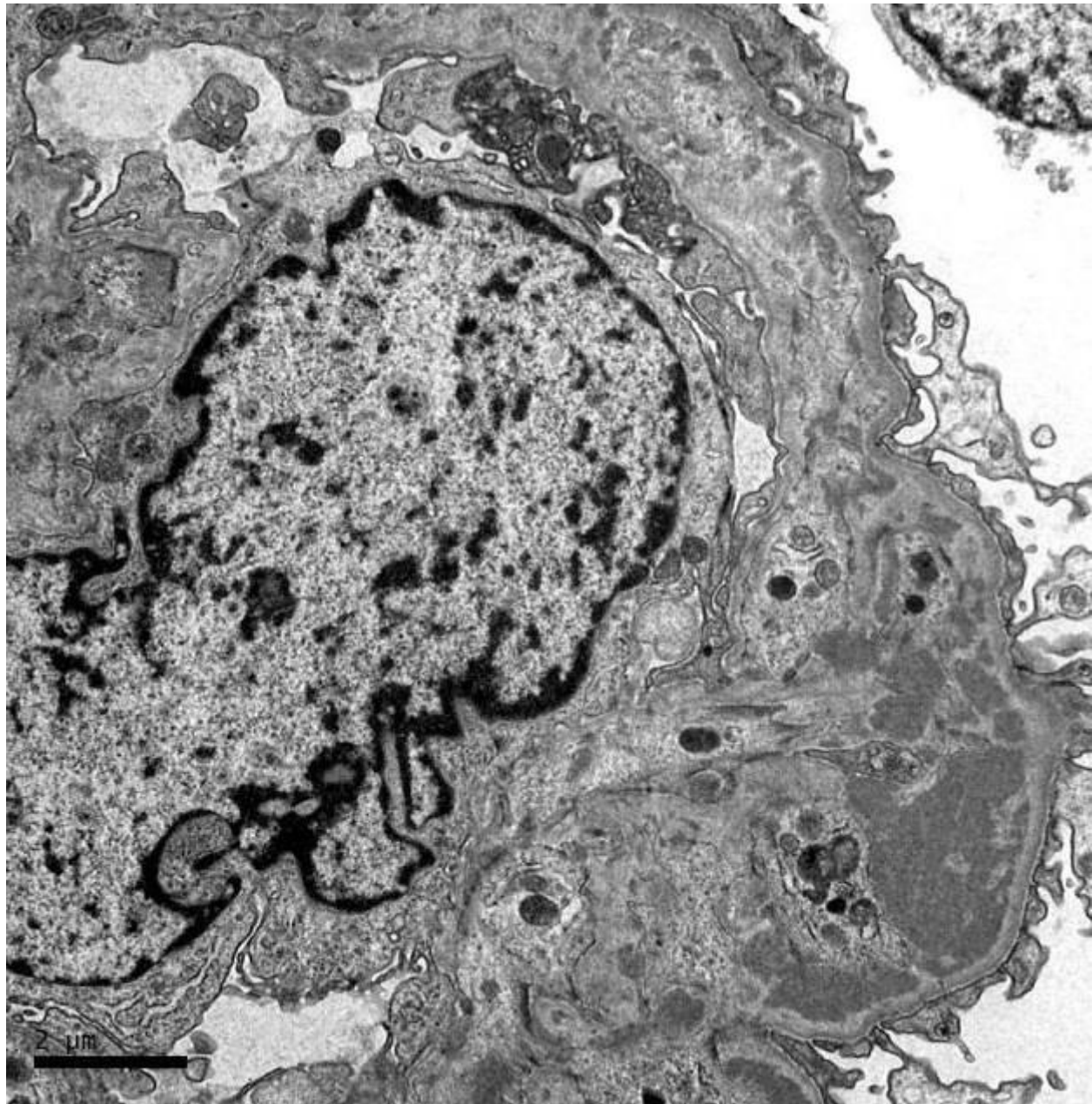
















# RENAL BIOPSY CLINICOPATHOLOGICAL WORKSHOP 2018



**PATHOLOGY**



Division of Pathology  
Singapore General Hospital



Department of Renal Medicine  
Singapore General Hospital



**MEDICINE**