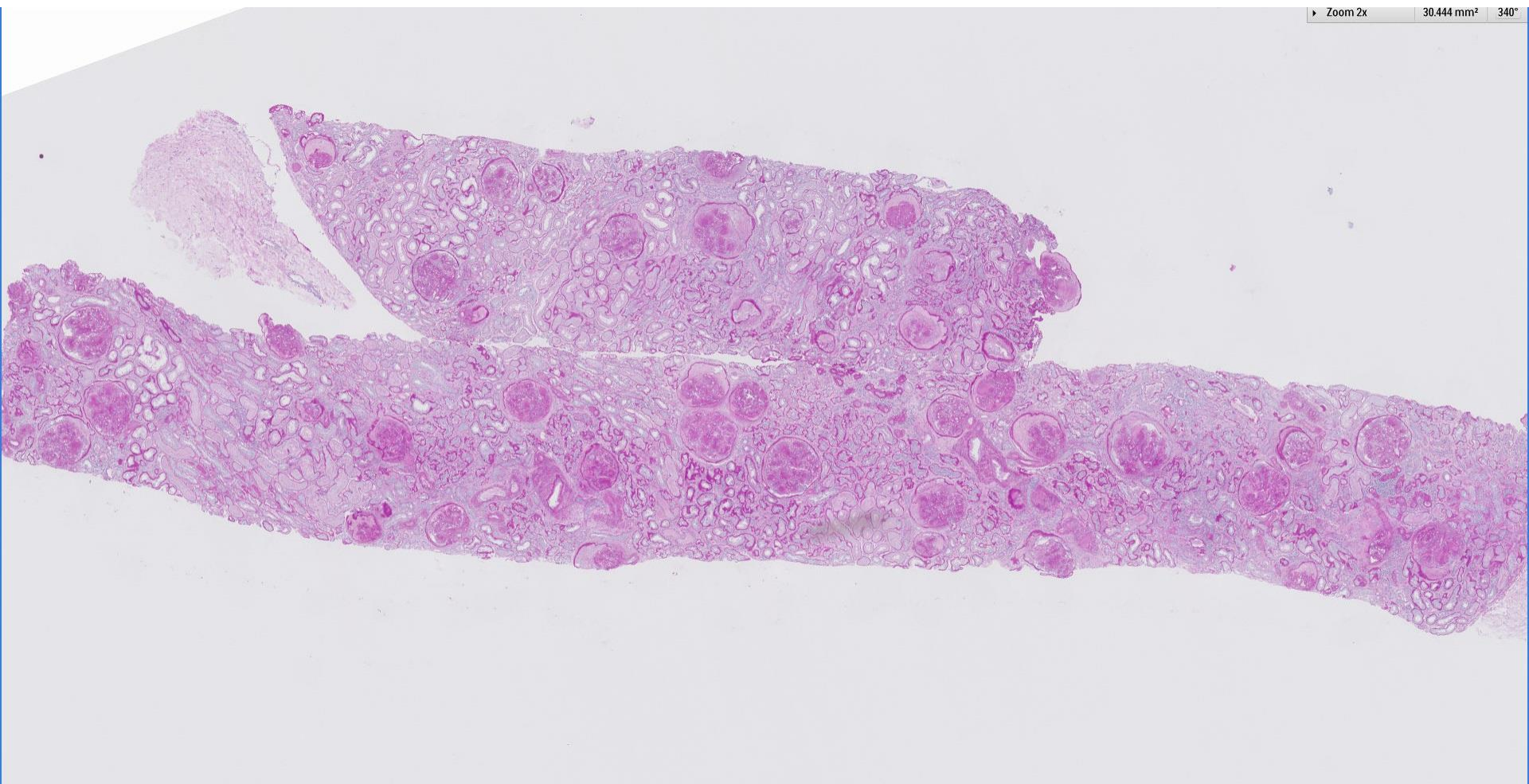
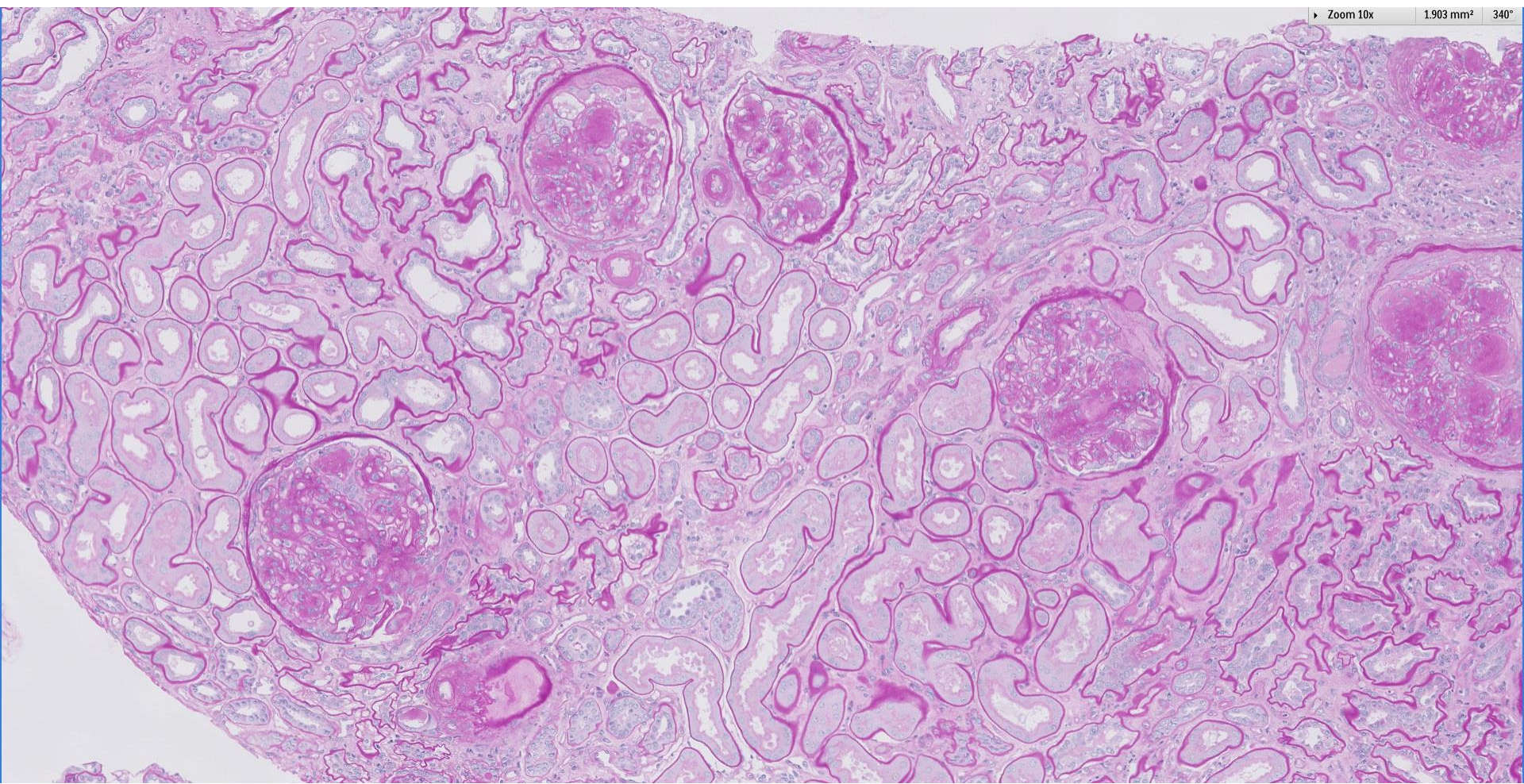


## *Case 22*

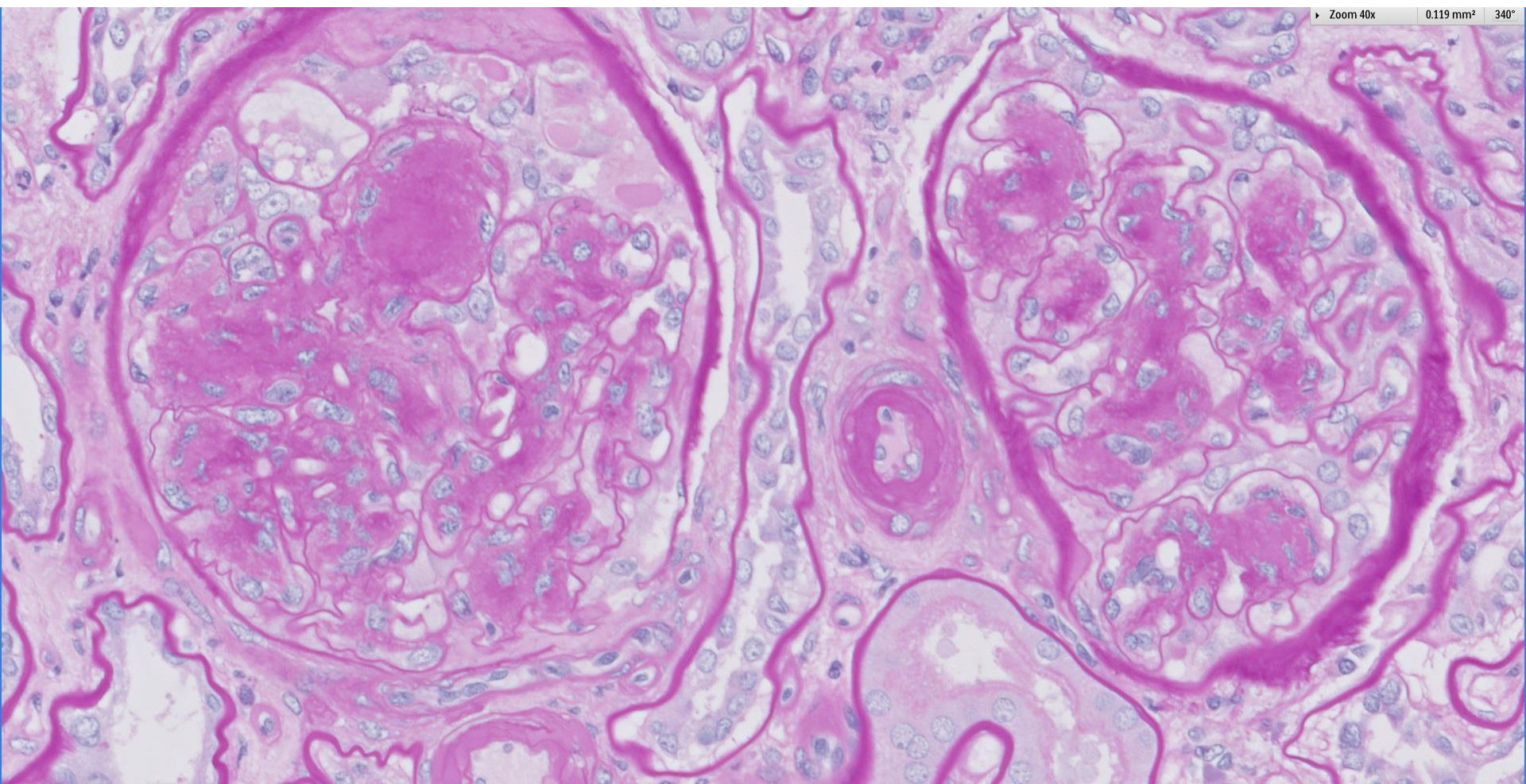
45 year old male with diabetes and BMI 40 kg/m<sup>2</sup> now presents with nephrotic syndrome.



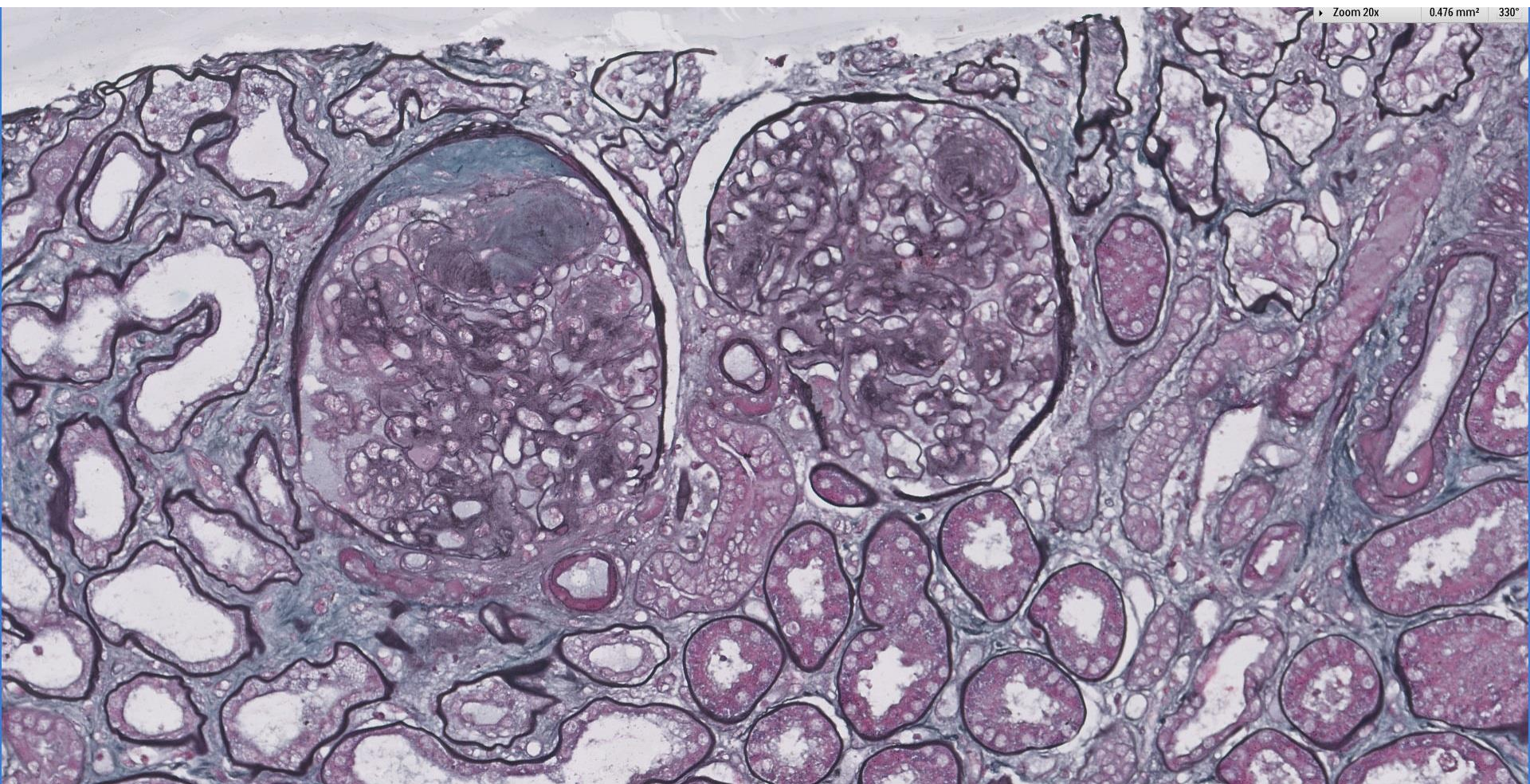






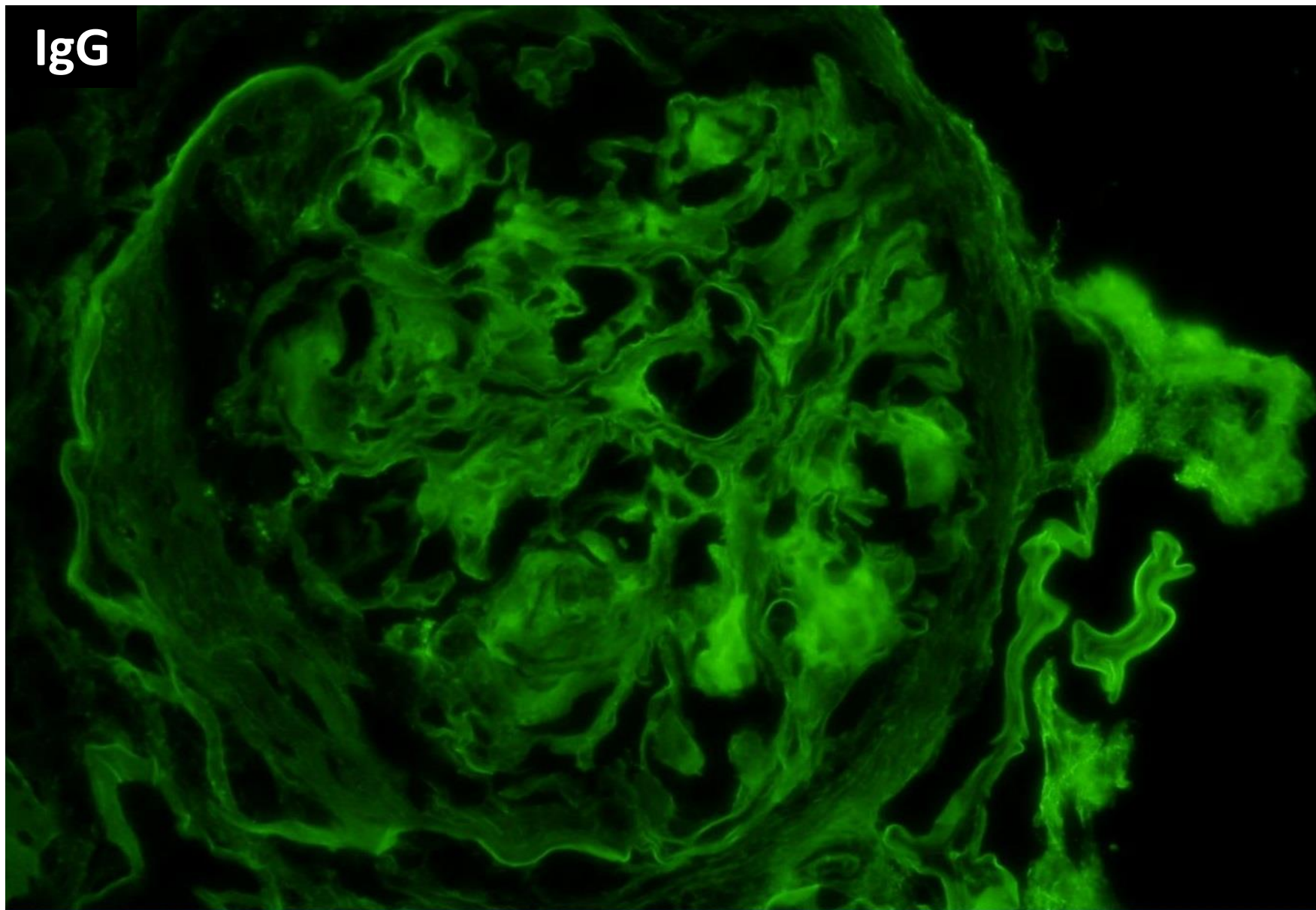




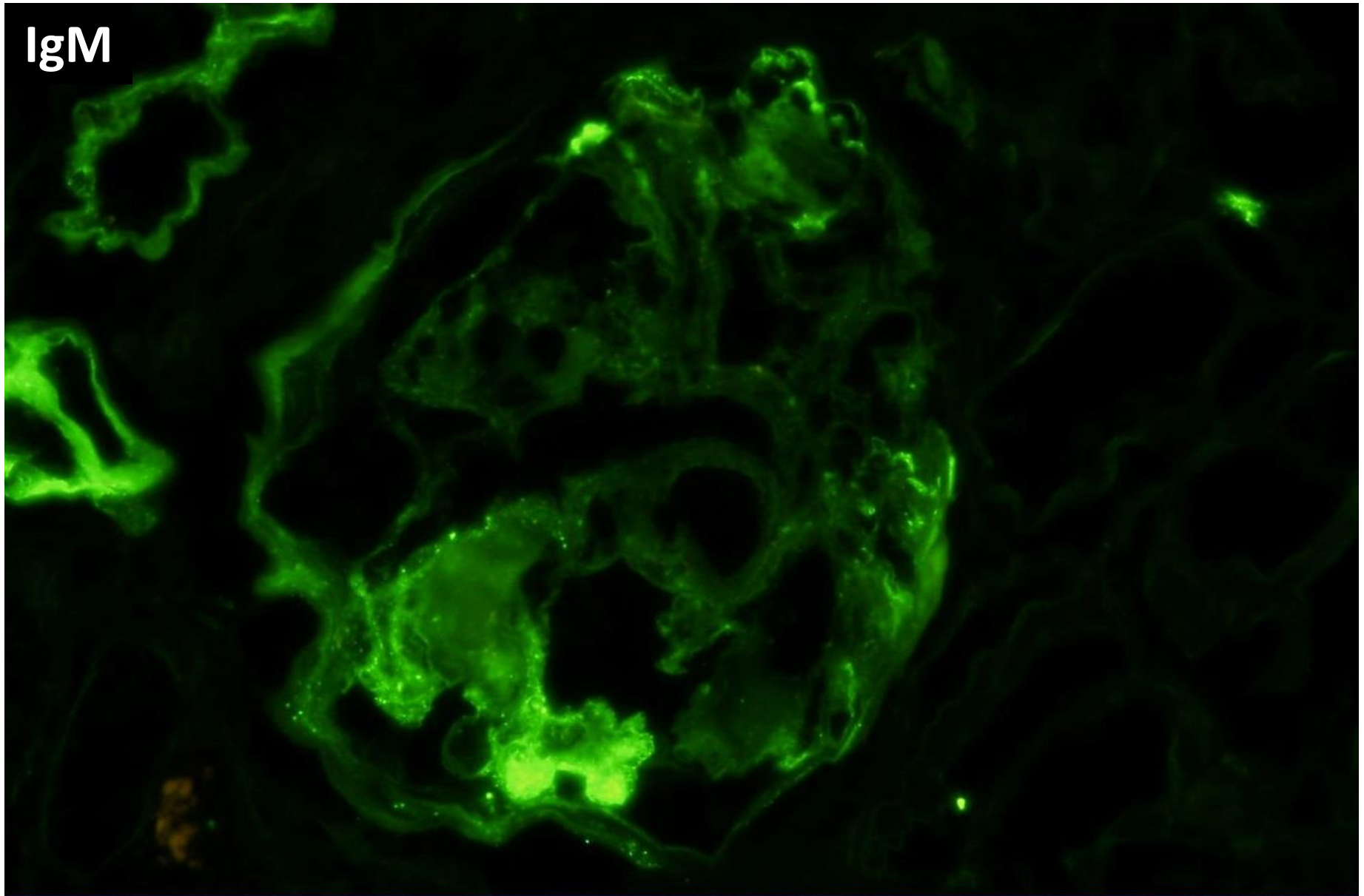




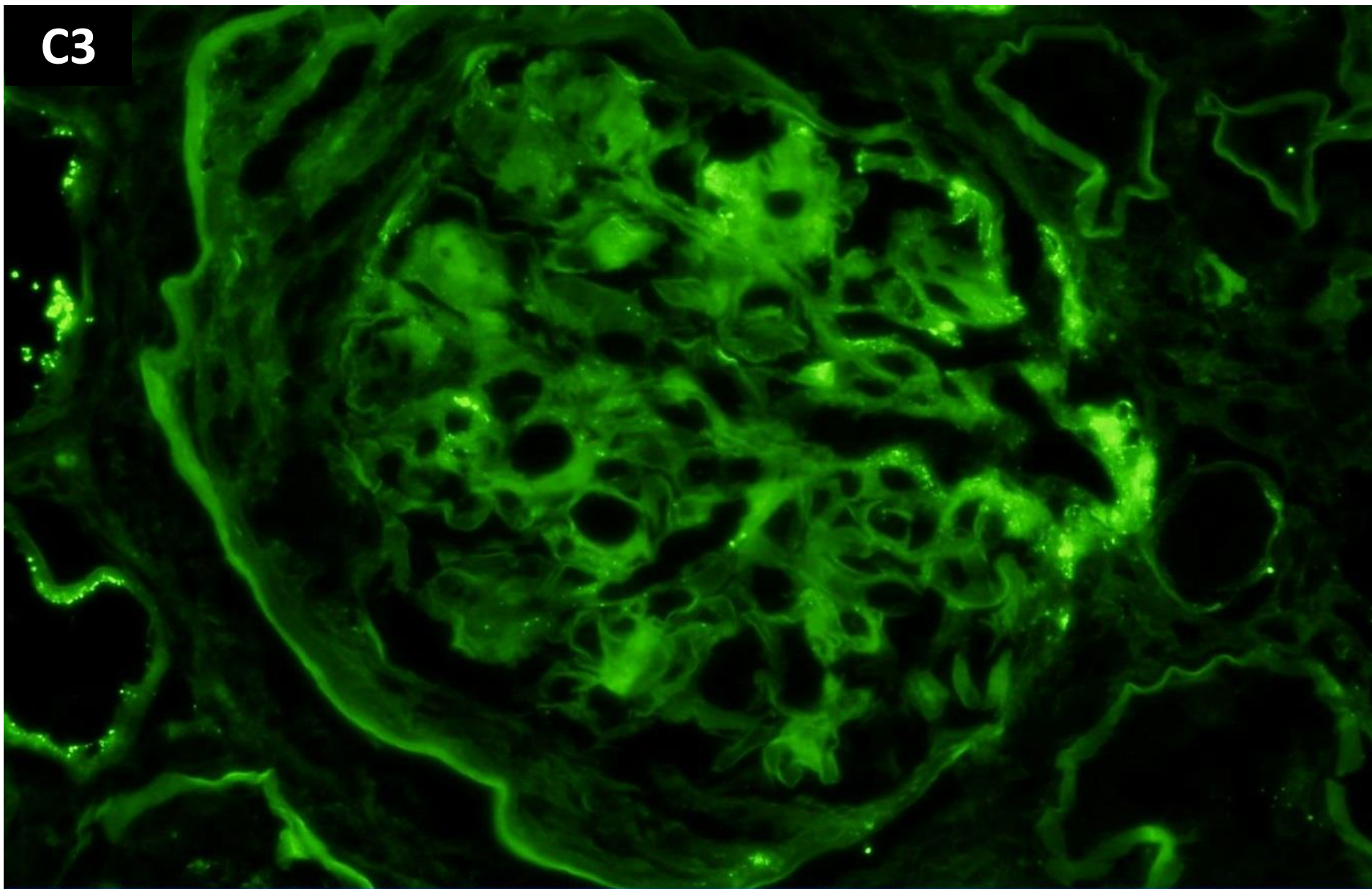
IgG



IgM

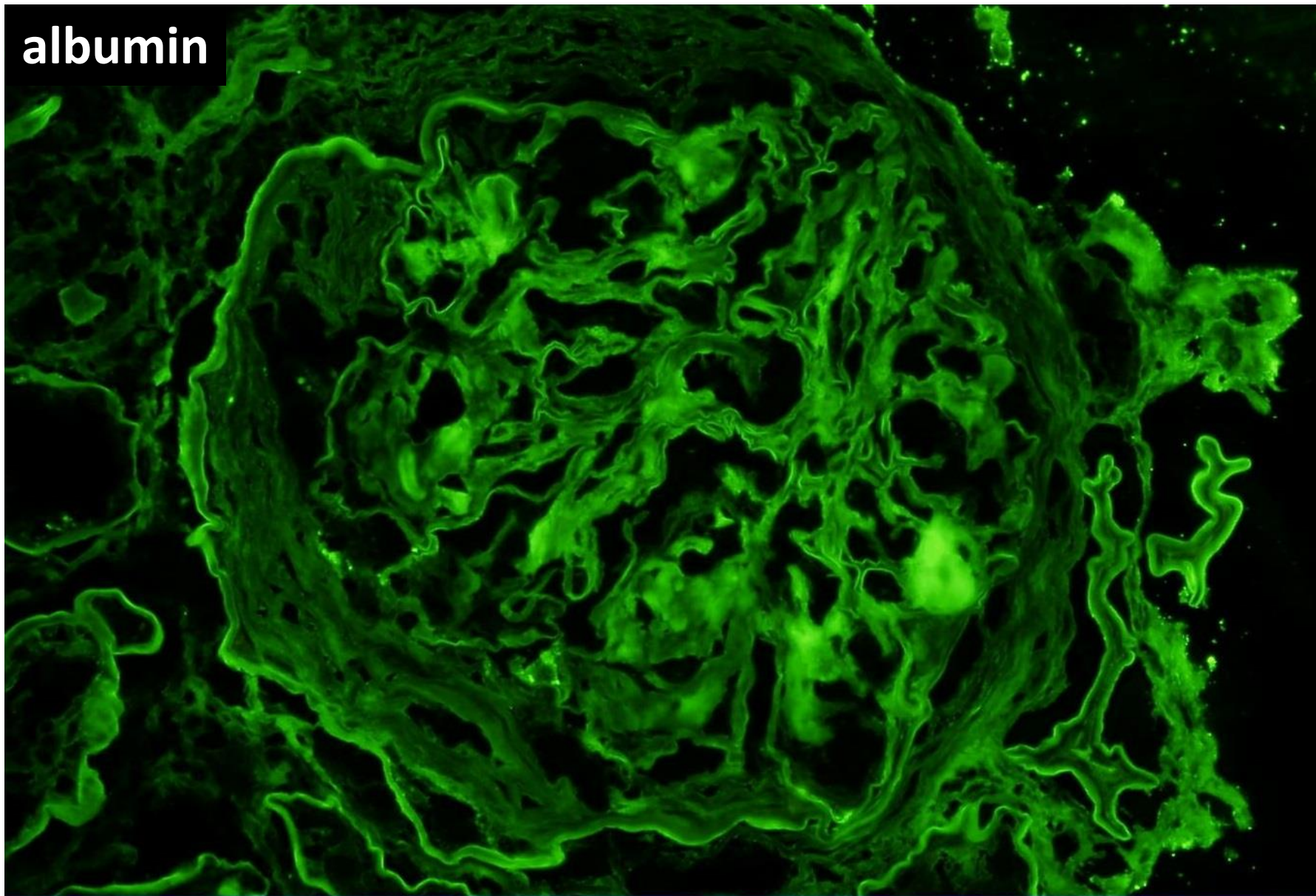


C3

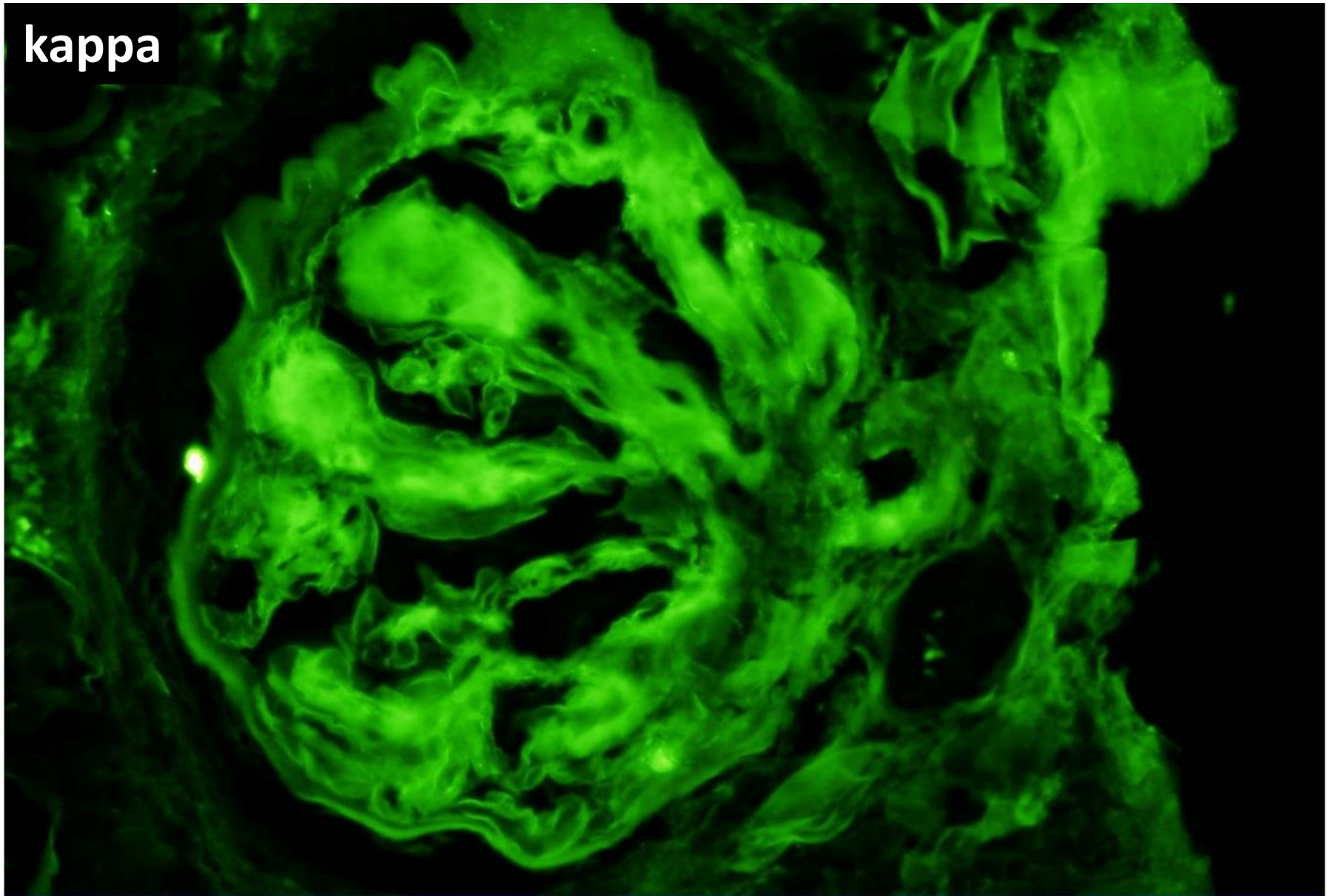




albumin

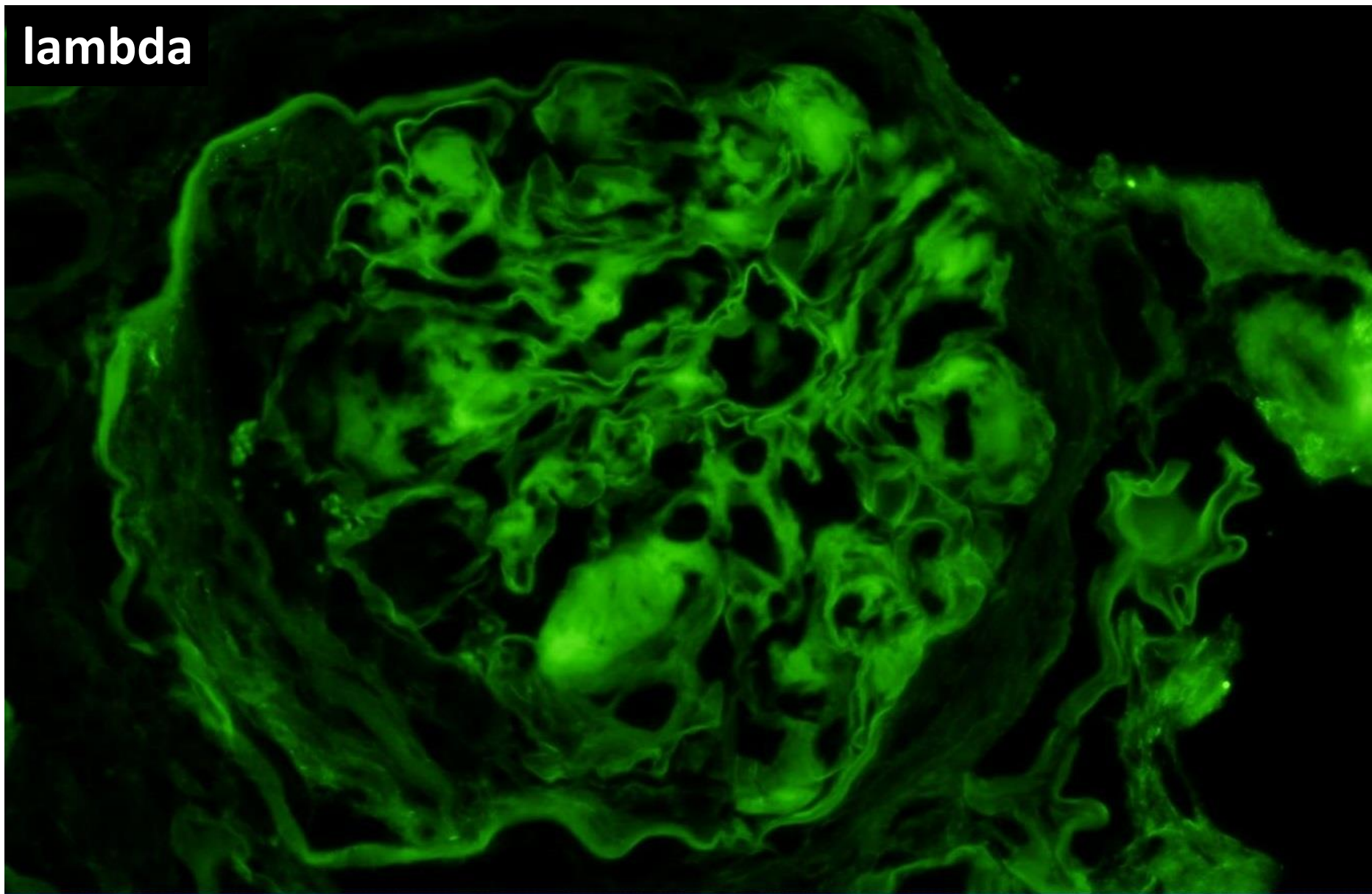


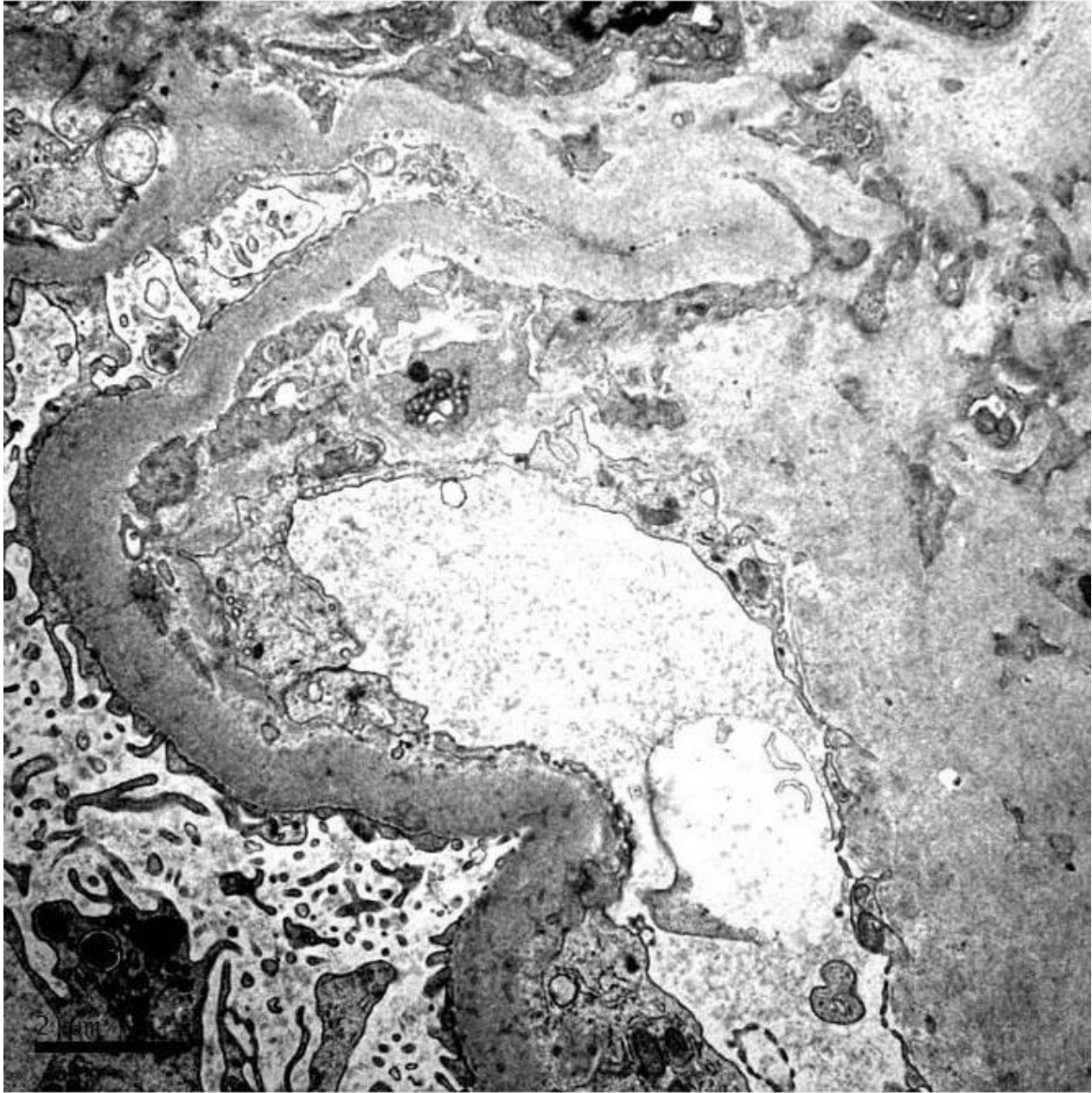
kappa



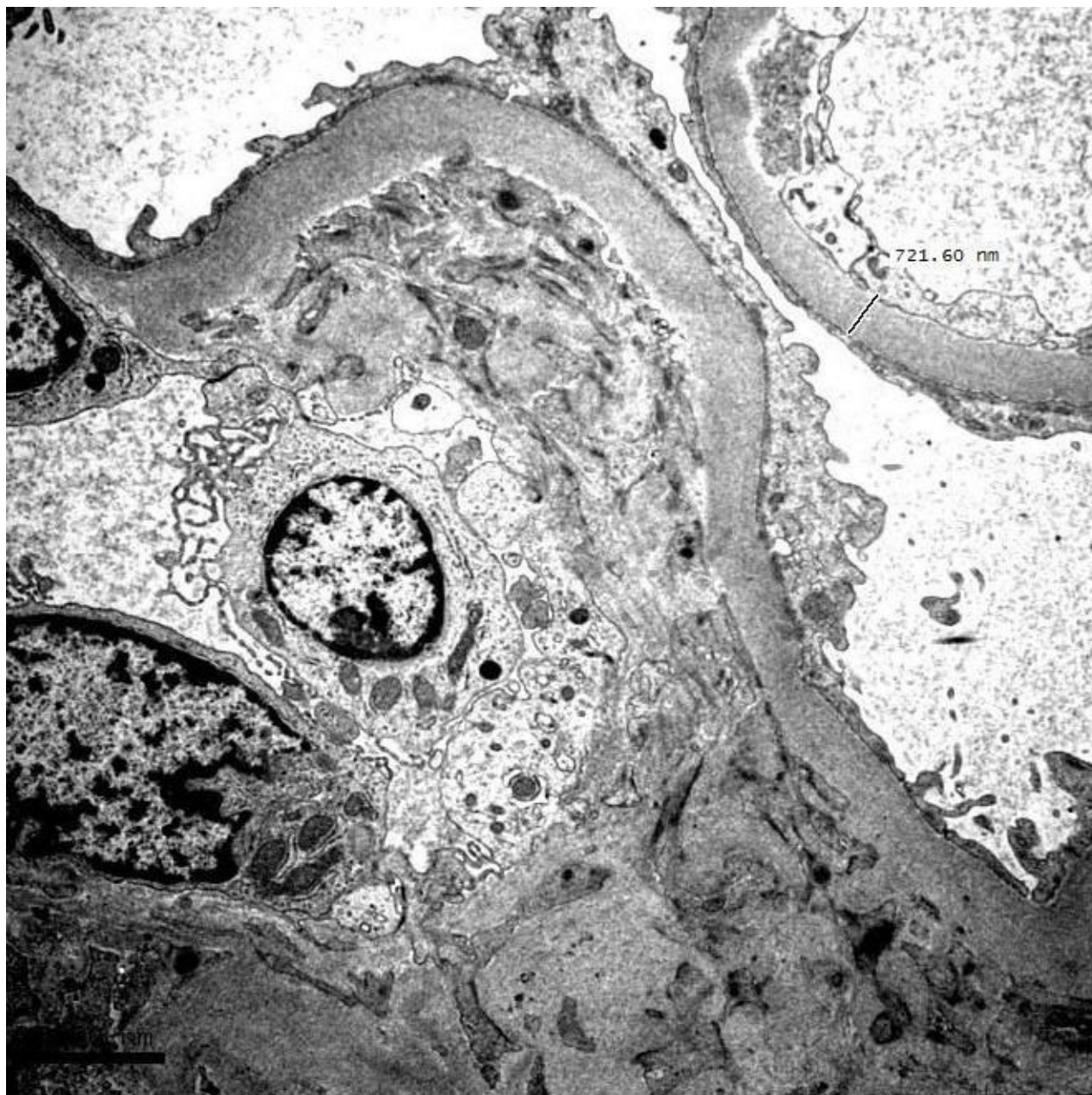


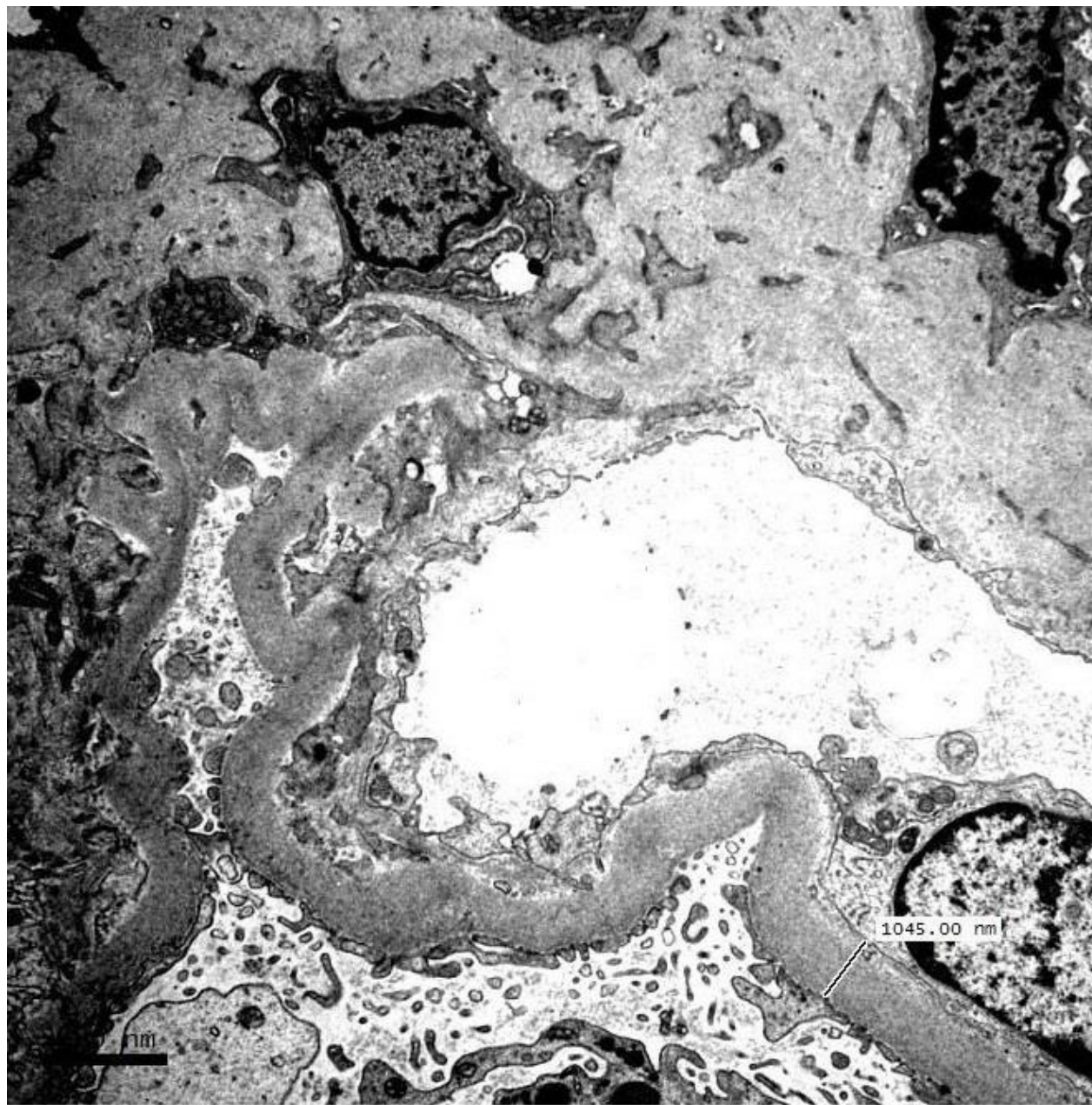
lambda















# RENAL BIOPSY CLINICOPATHOLOGICAL WORKSHOP 2018

