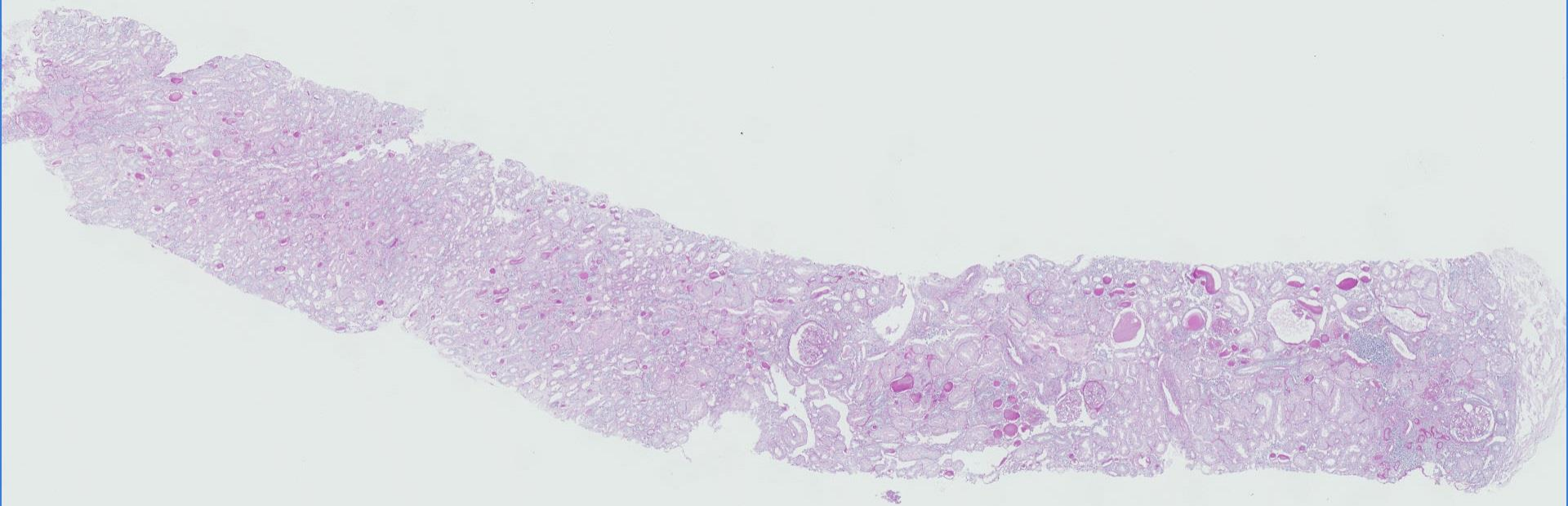
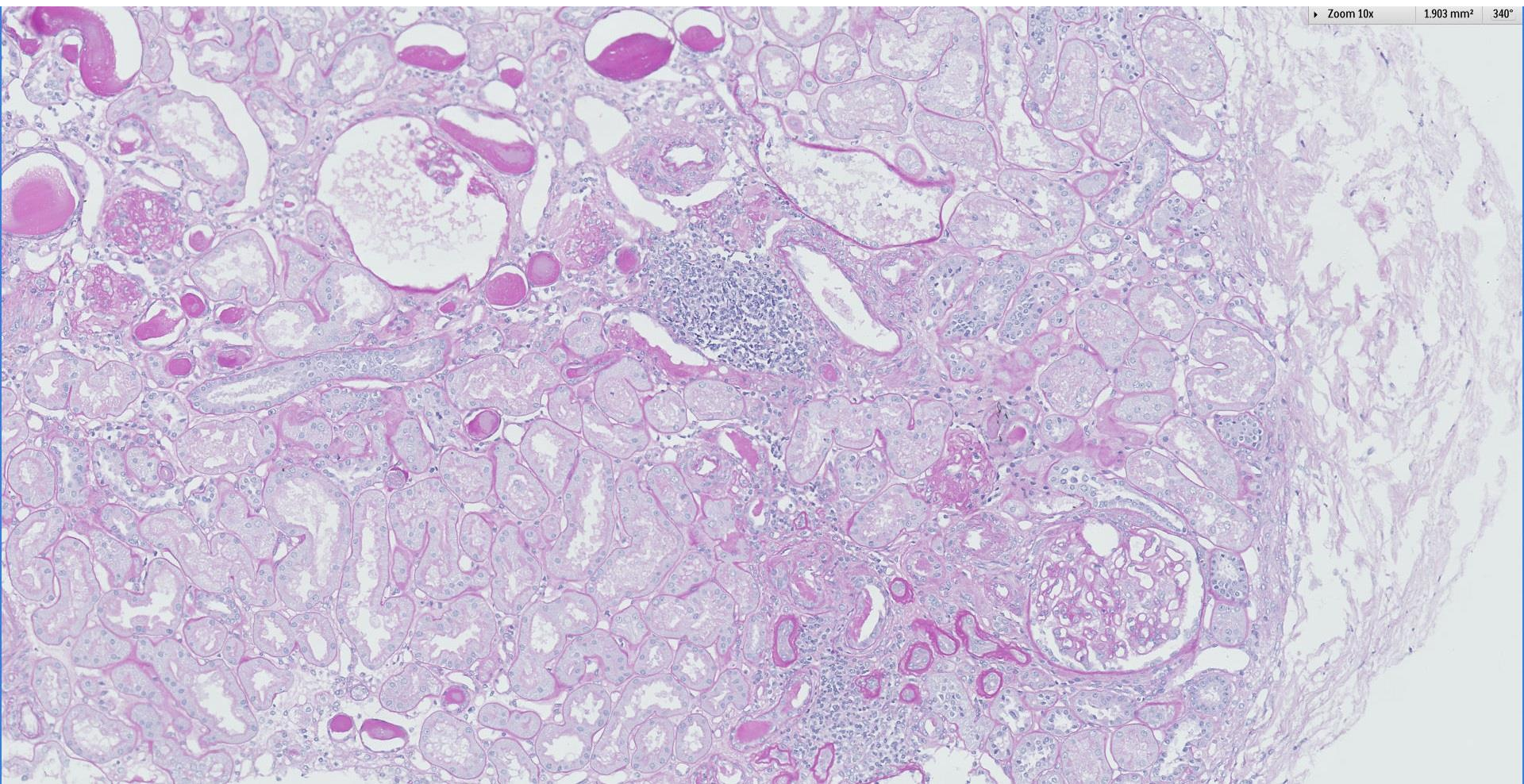


## *Case 16*

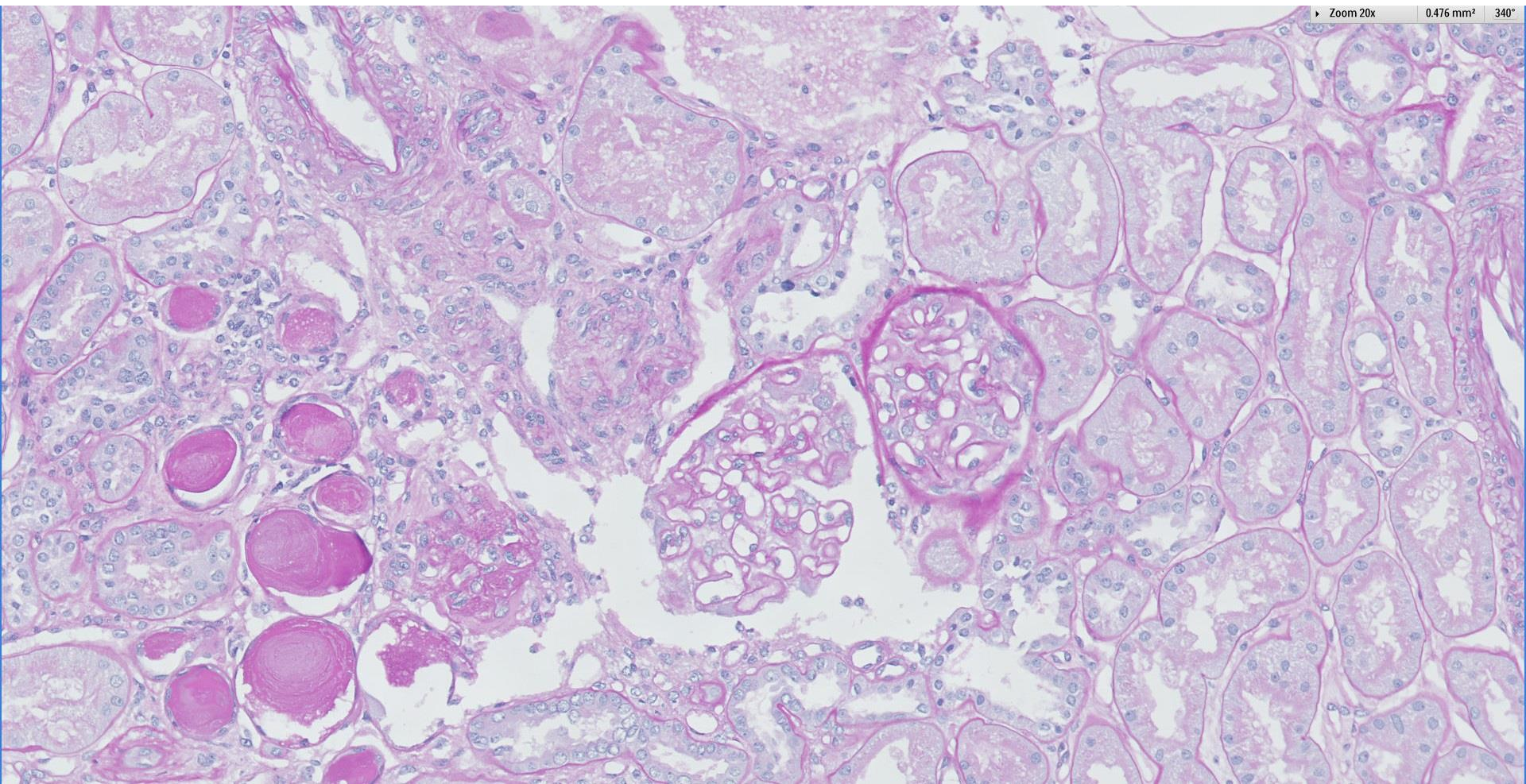
73 year old man with hypertension, proteinuria and history of renal biopsy done 10 years ago which showed membranous nephropathy treated with losartan.







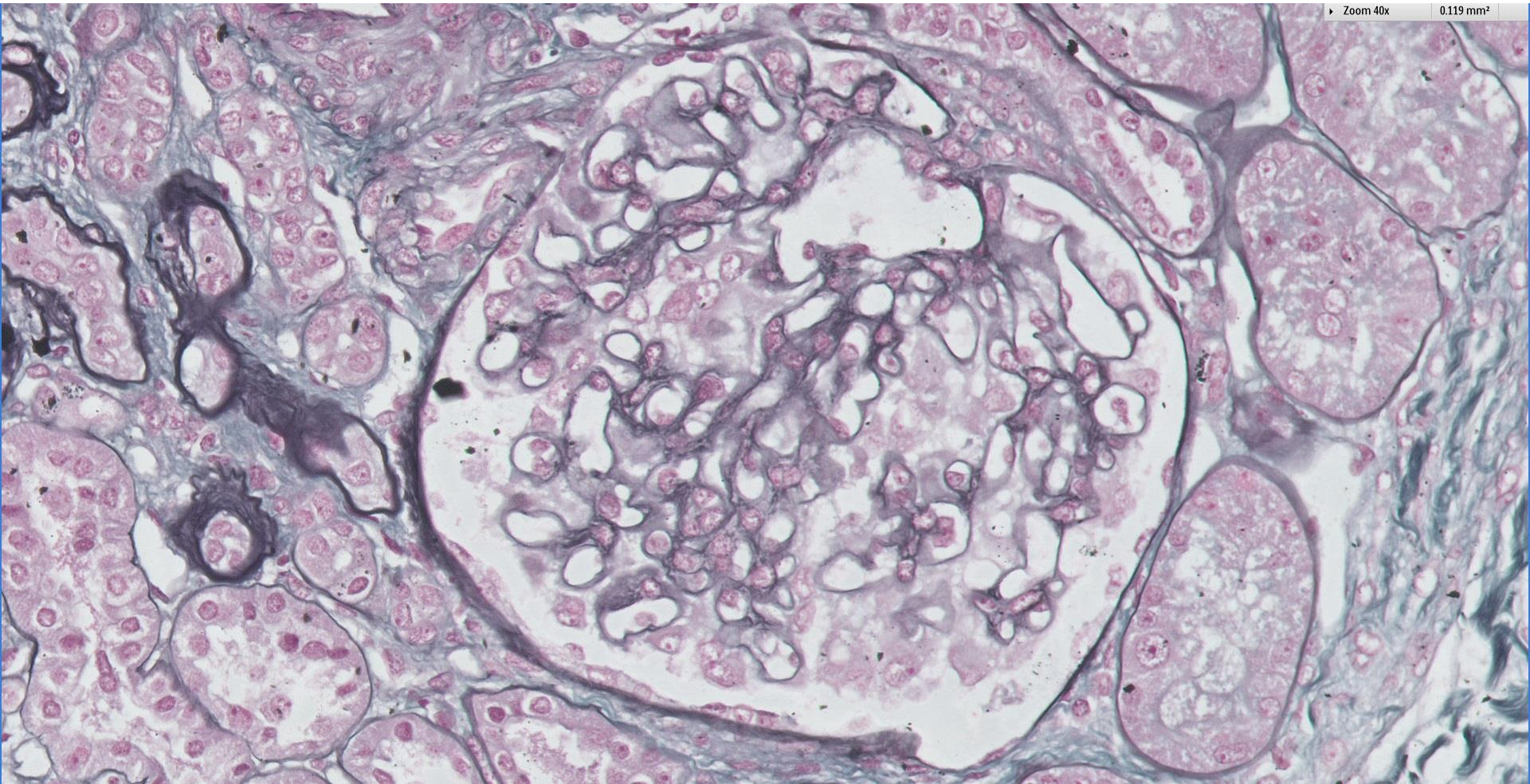






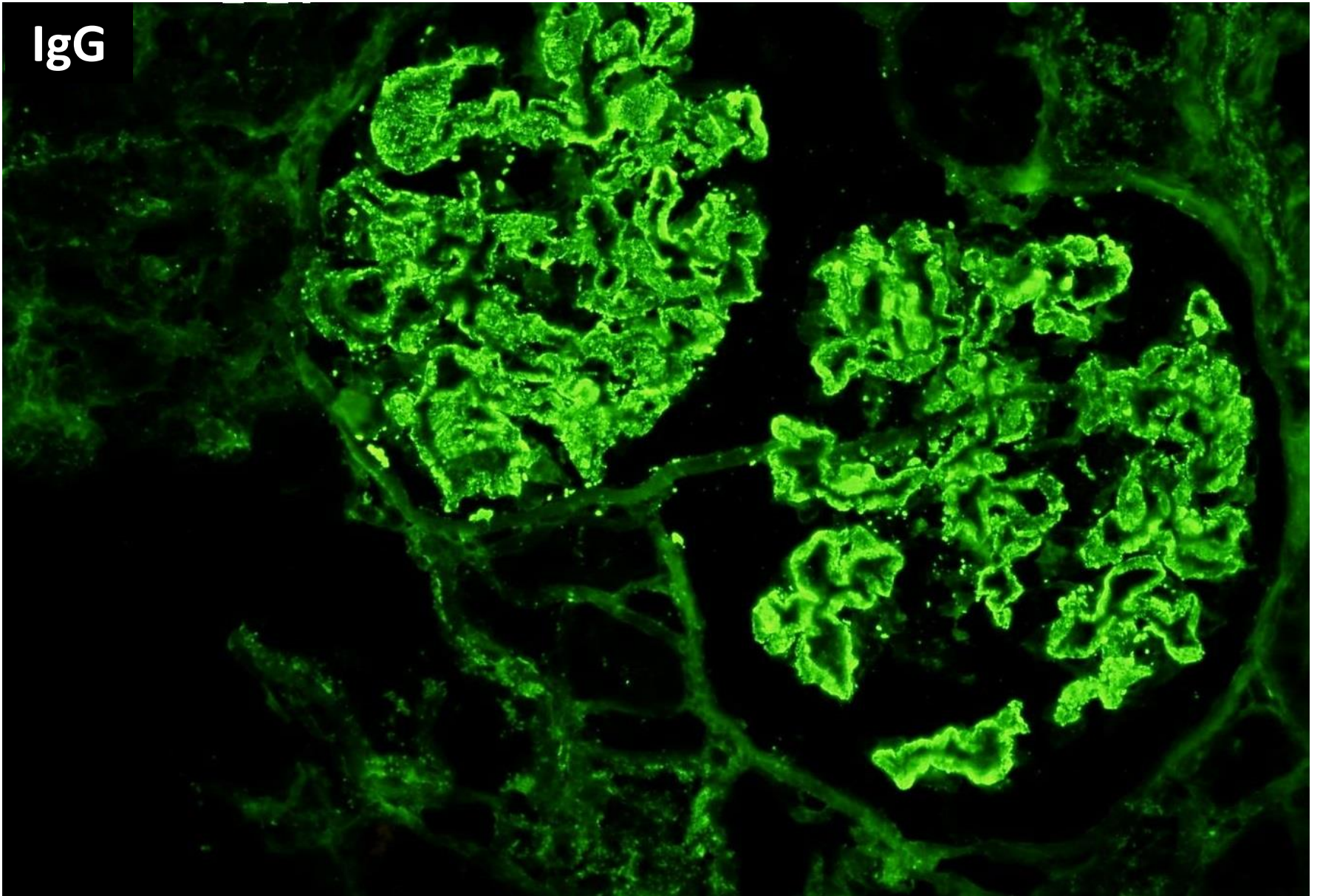
Zoom 40x

0.119 mm<sup>2</sup>

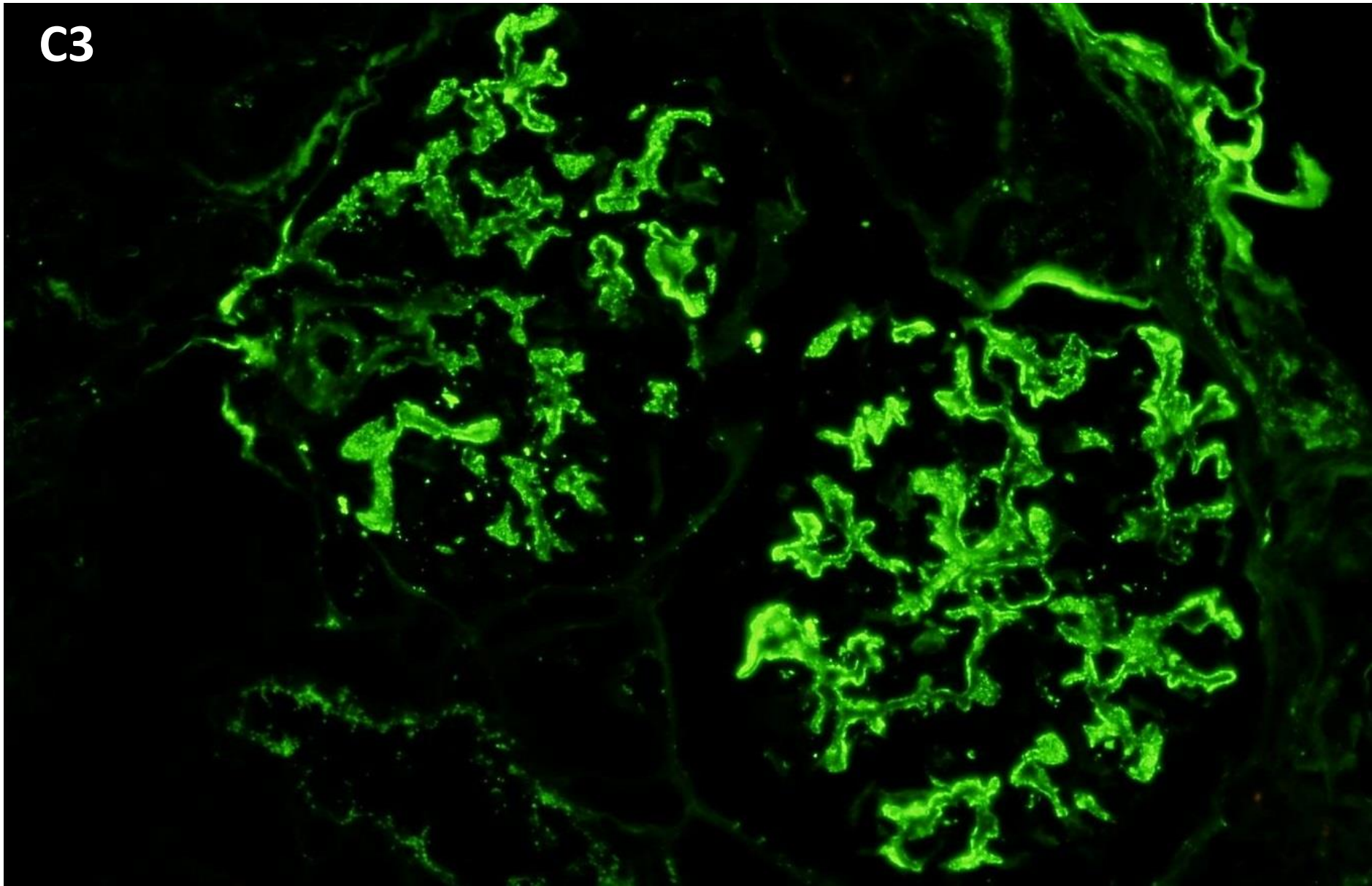




IgG

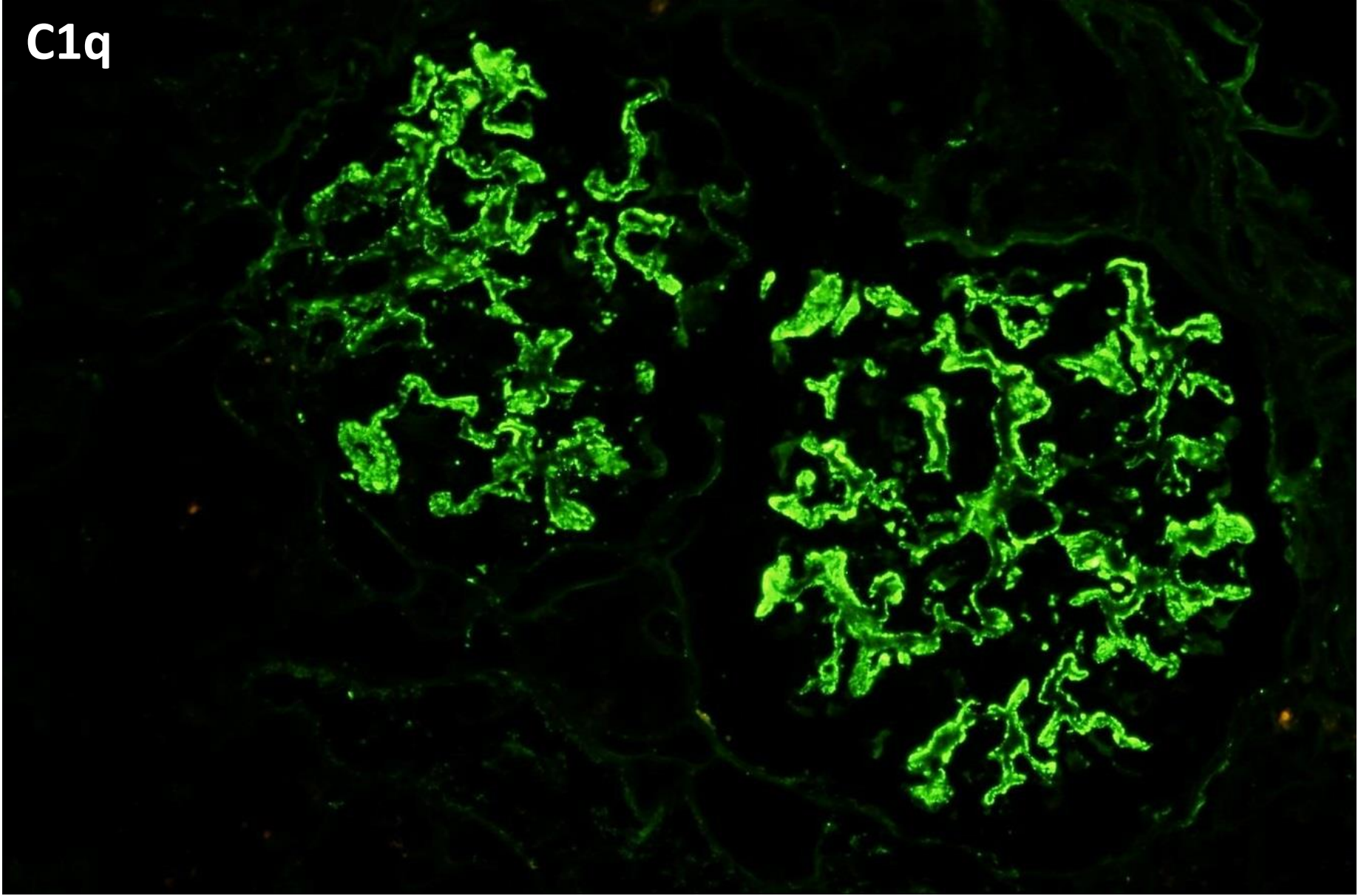


C3



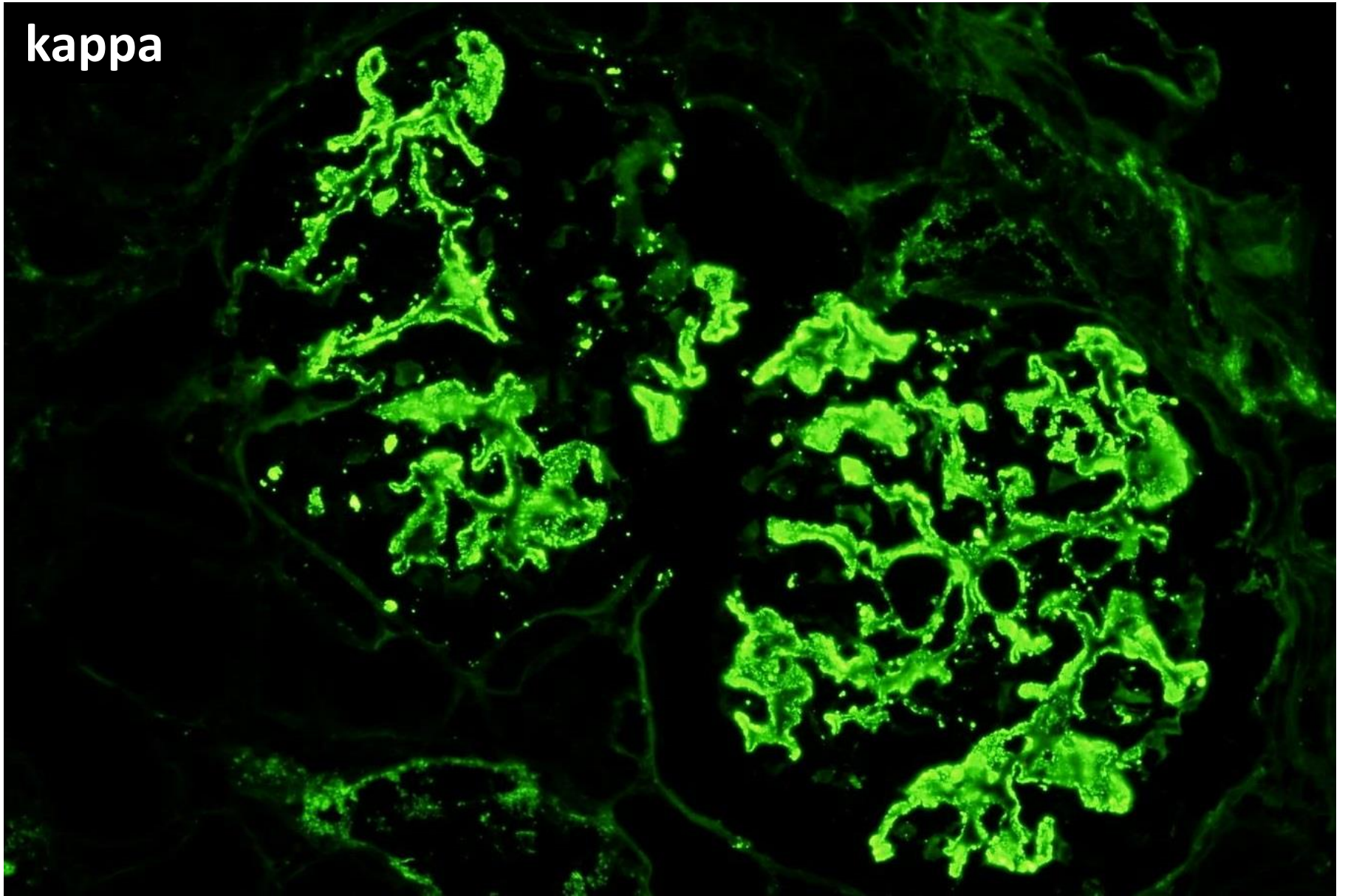


C1q

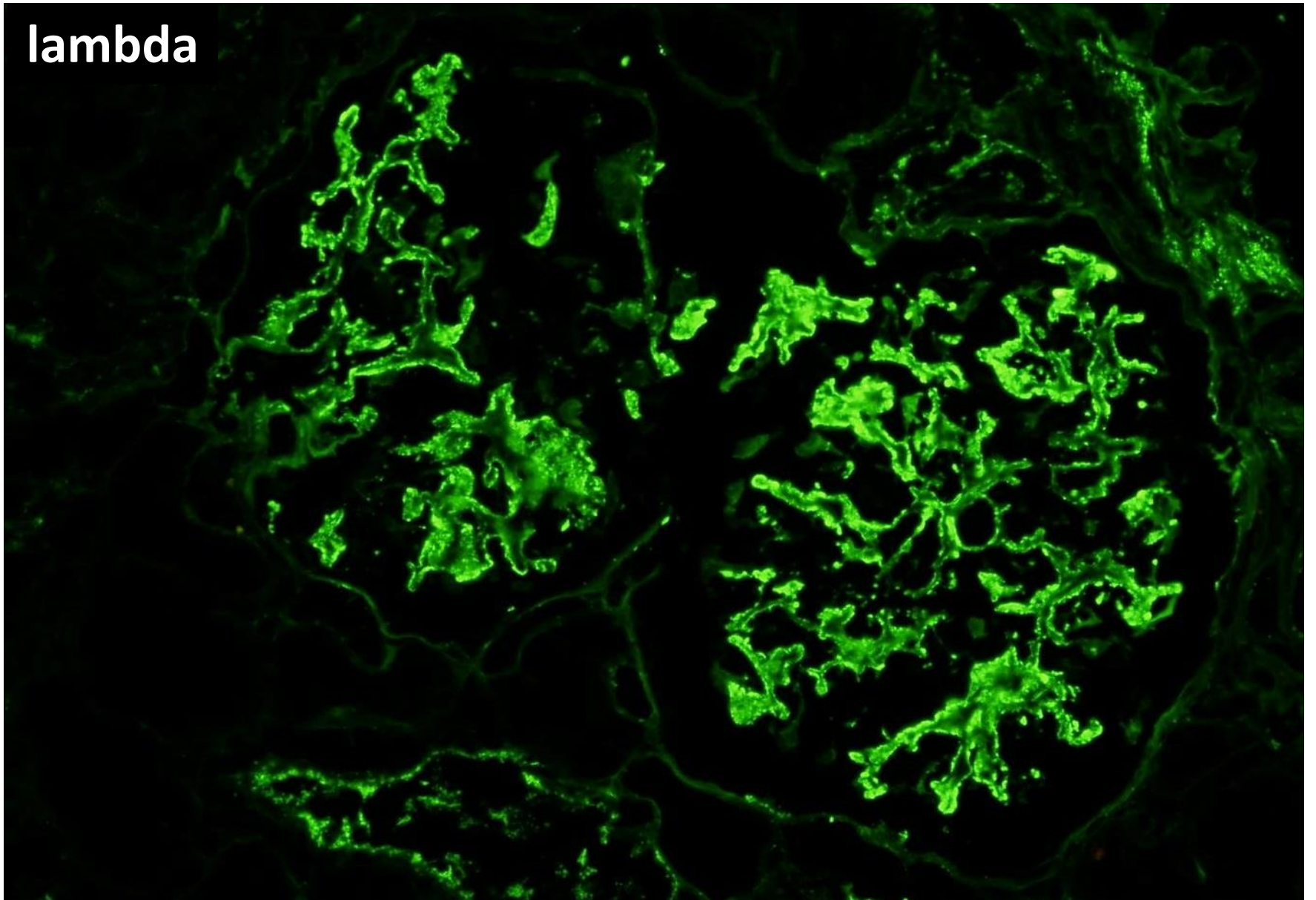




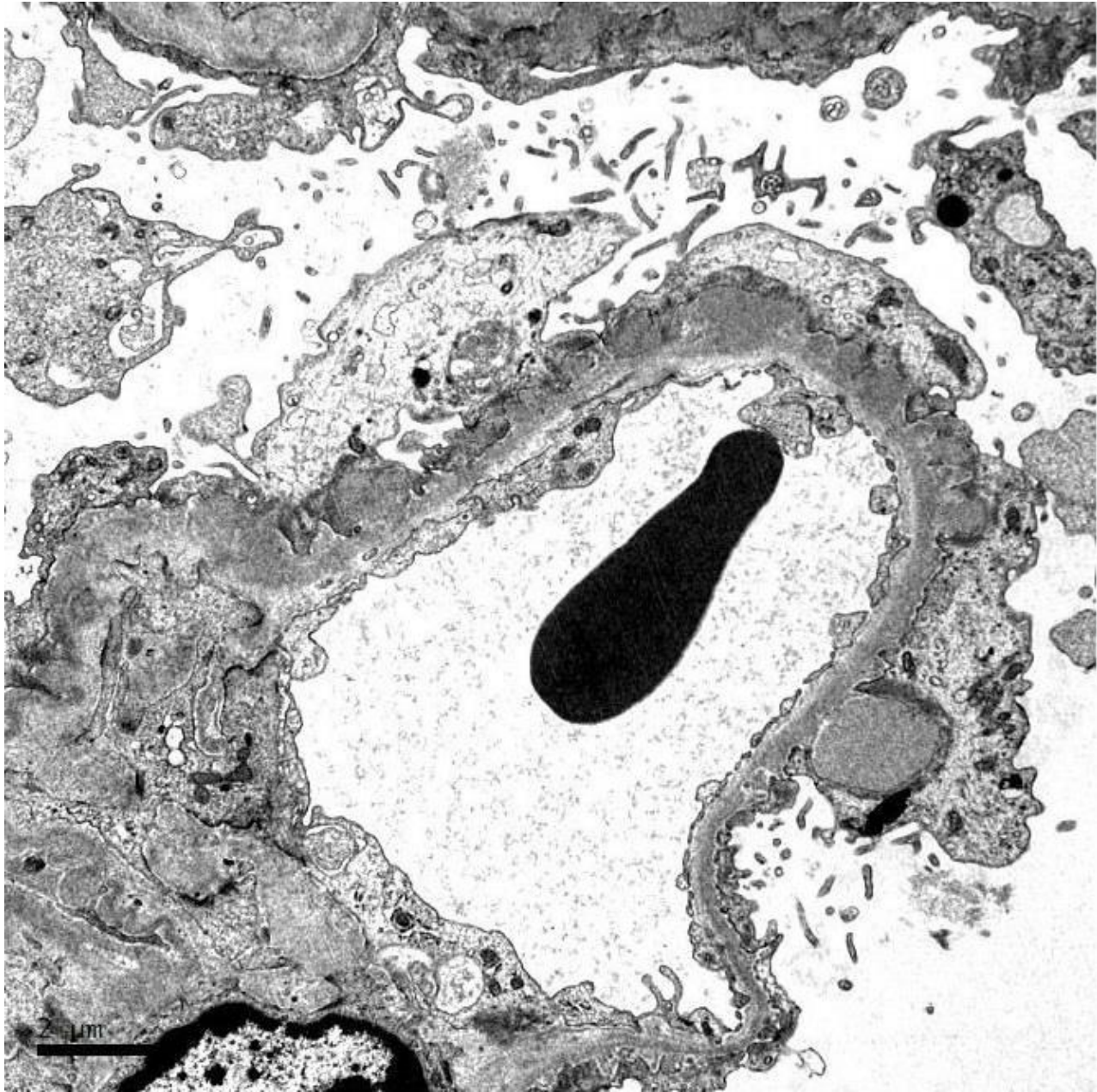
kappa

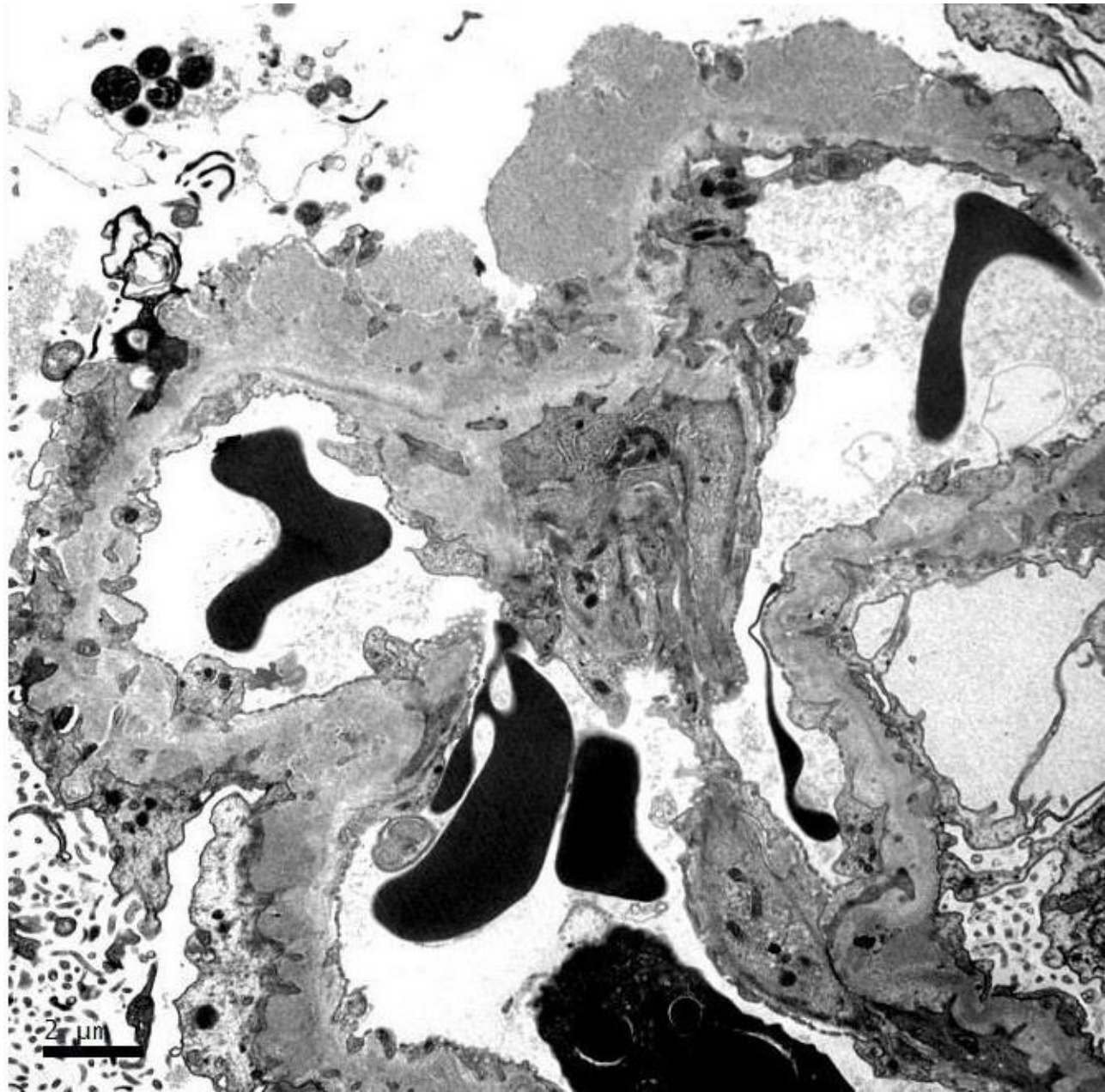


lambda

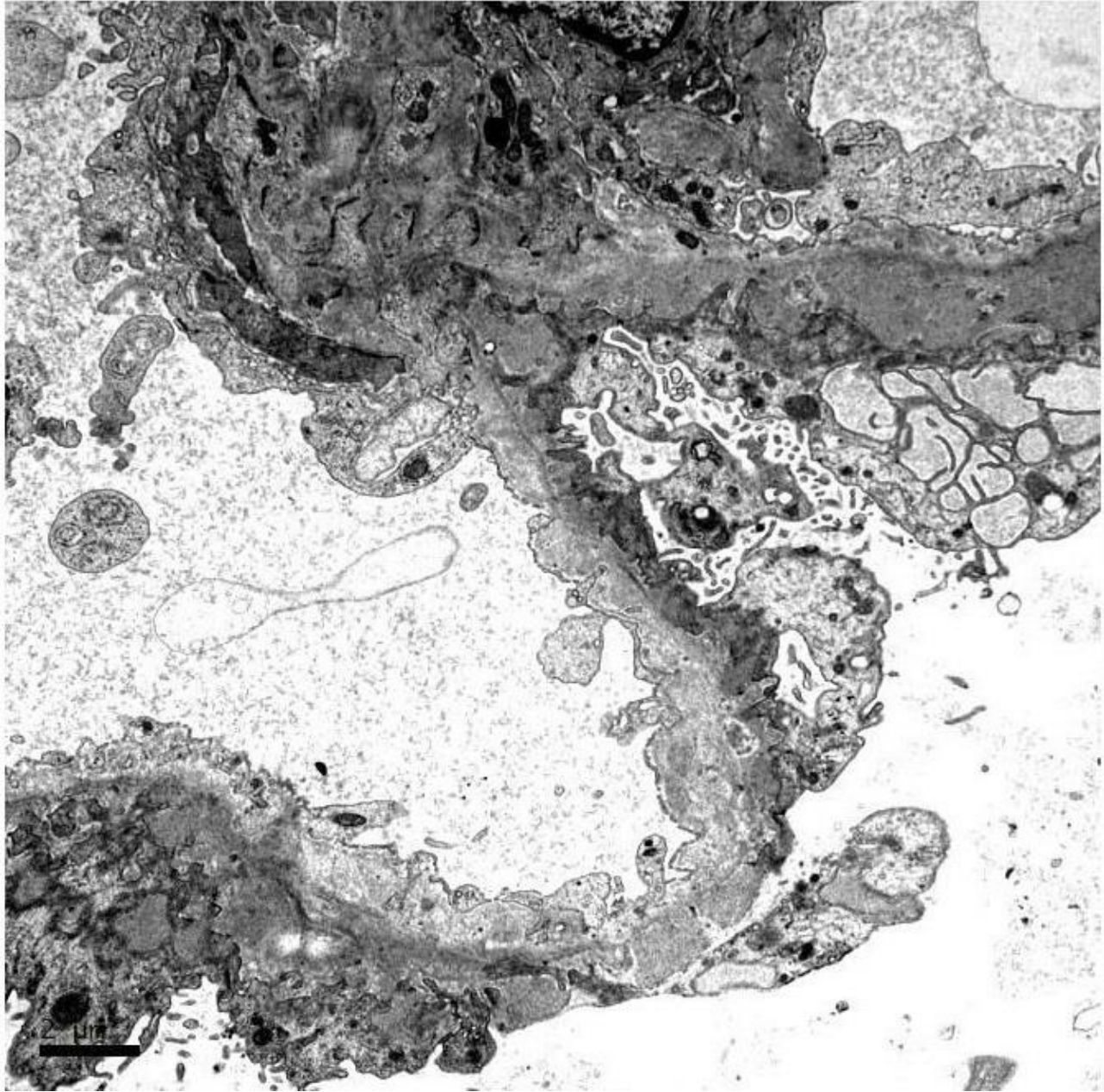


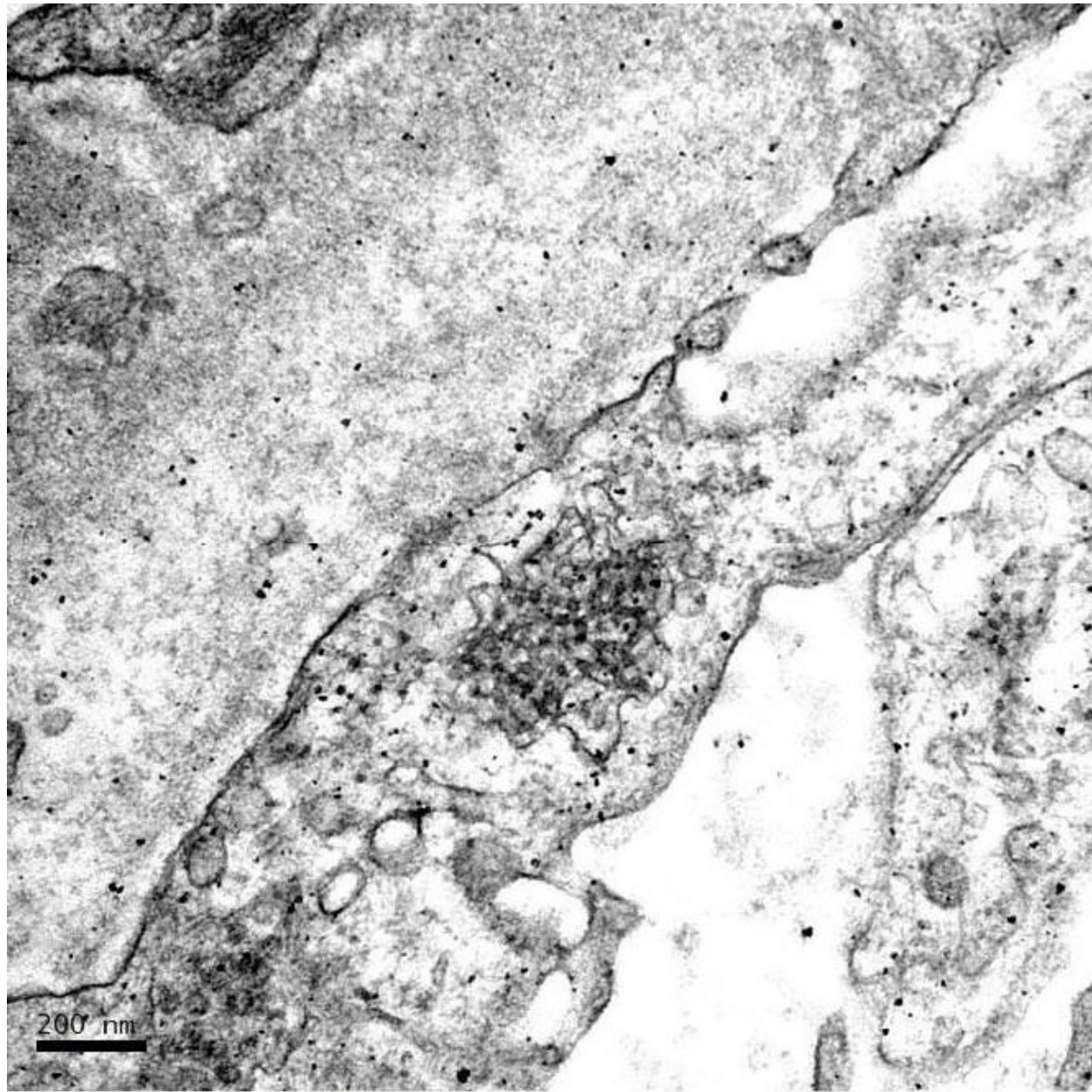




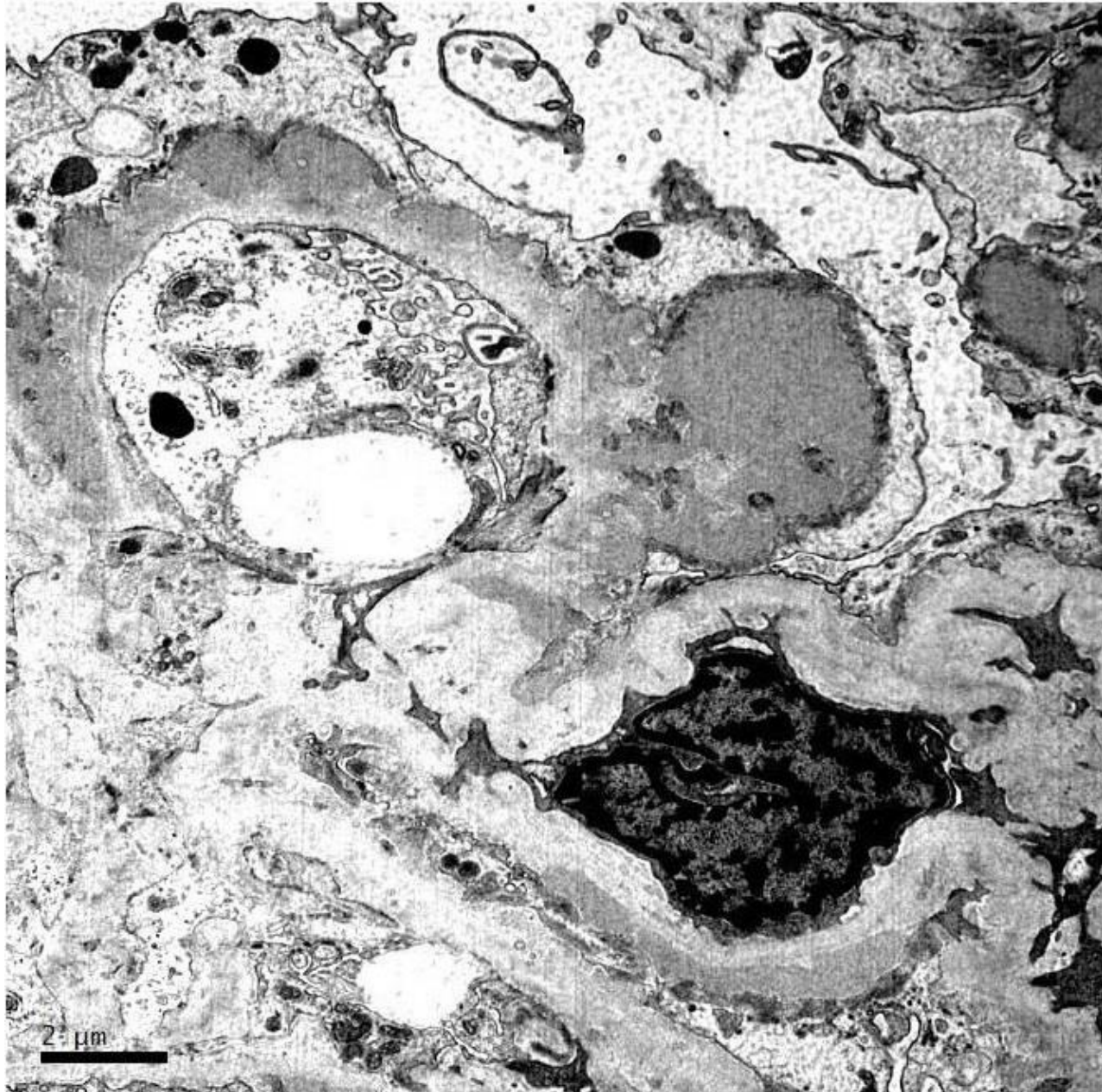
















# RENAL BIOPSY CLINICOPATHOLOGICAL WORKSHOP 2018



**PATHOLOGY**



Division of Pathology  
Singapore General Hospital



Department of Renal Medicine  
Singapore General Hospital



**MEDICINE**