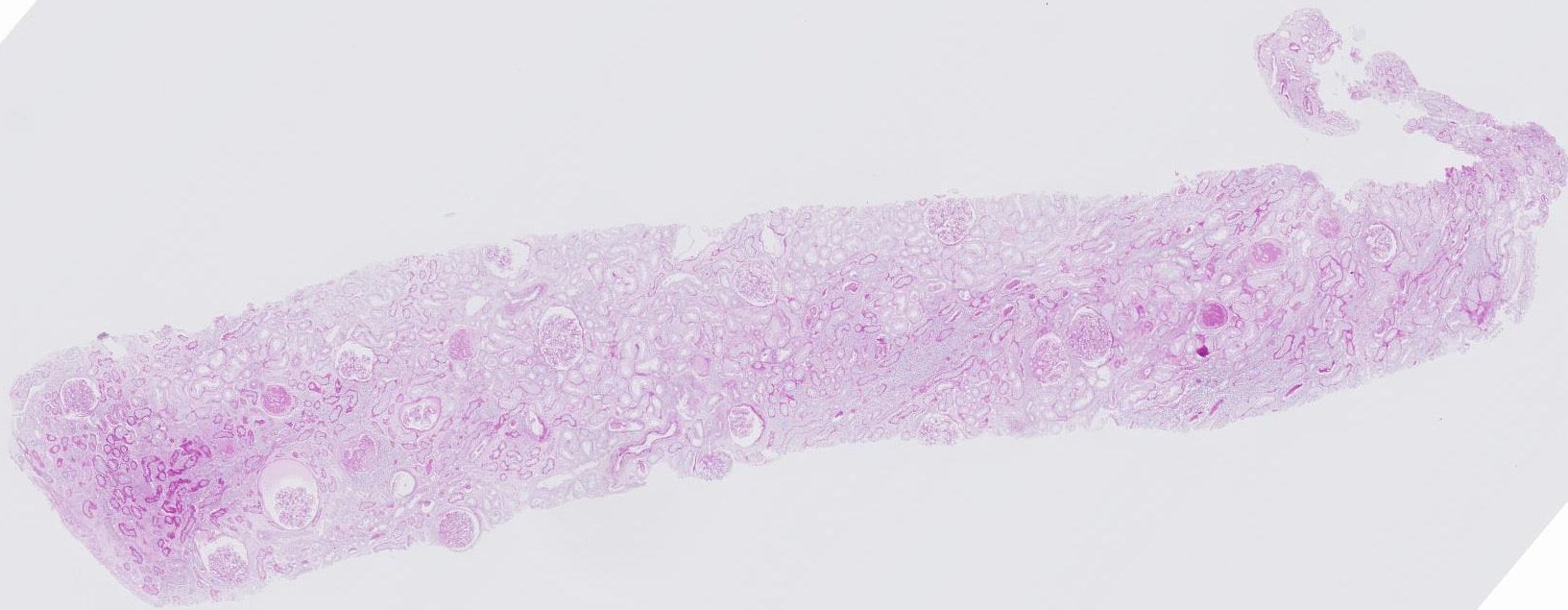
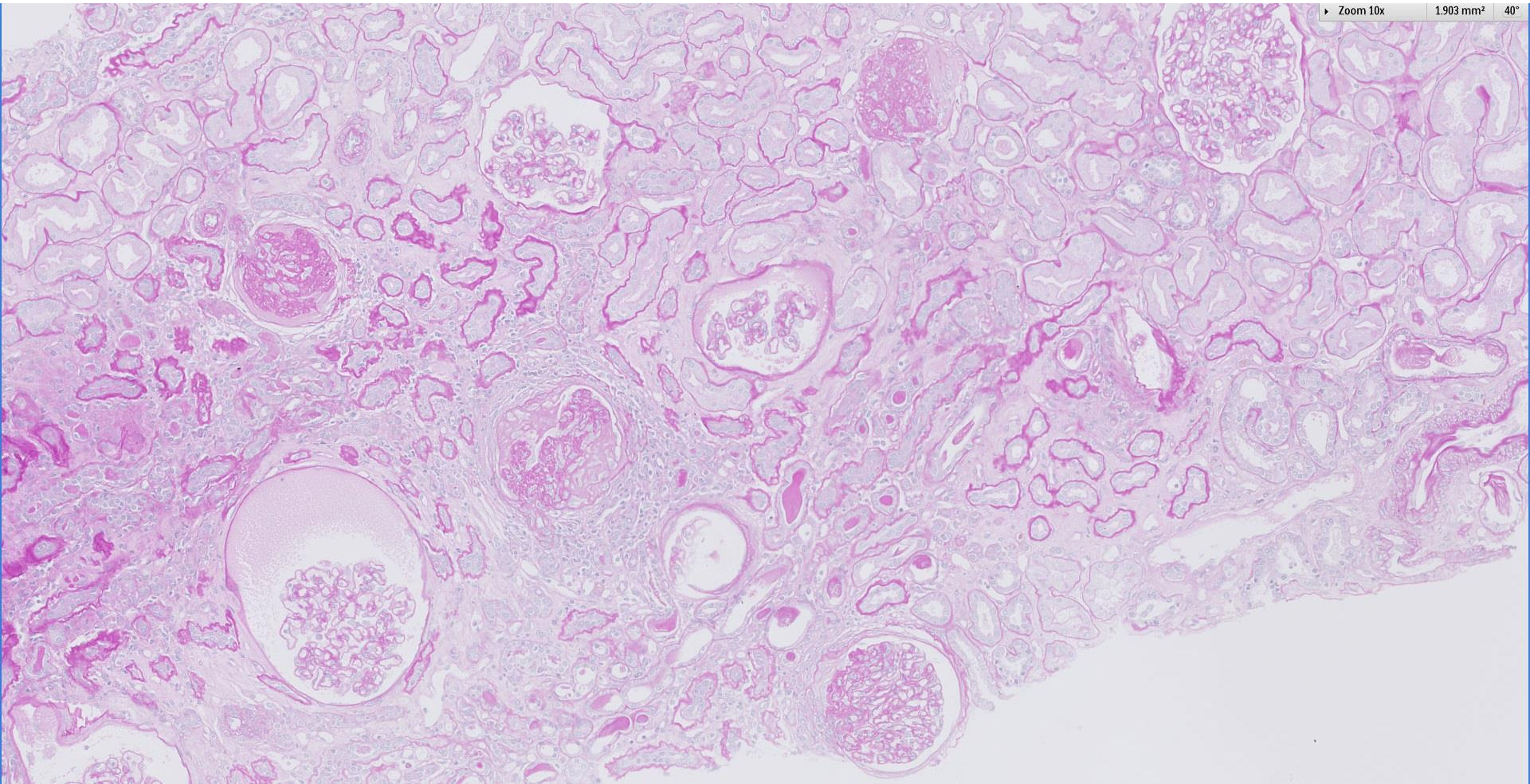
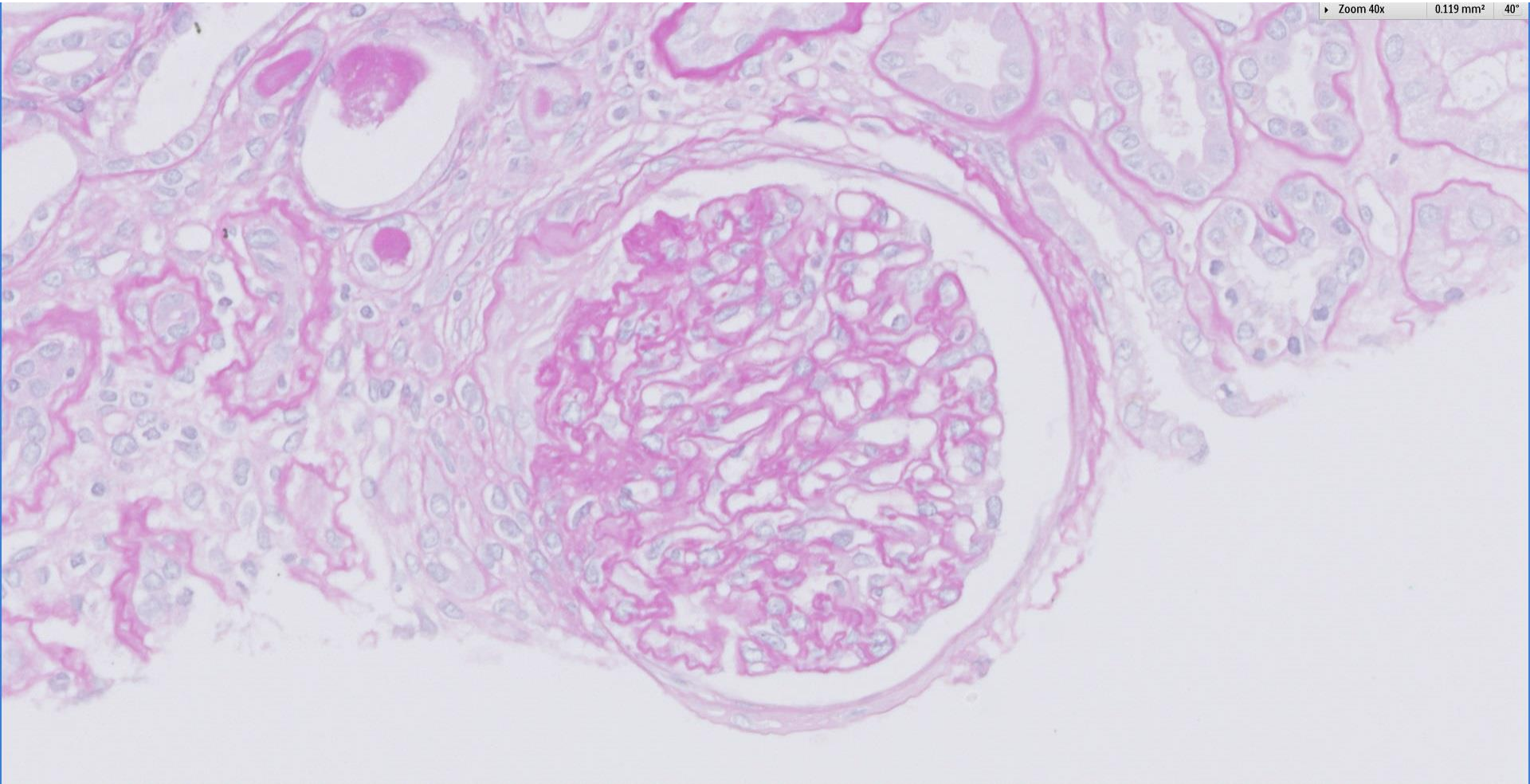


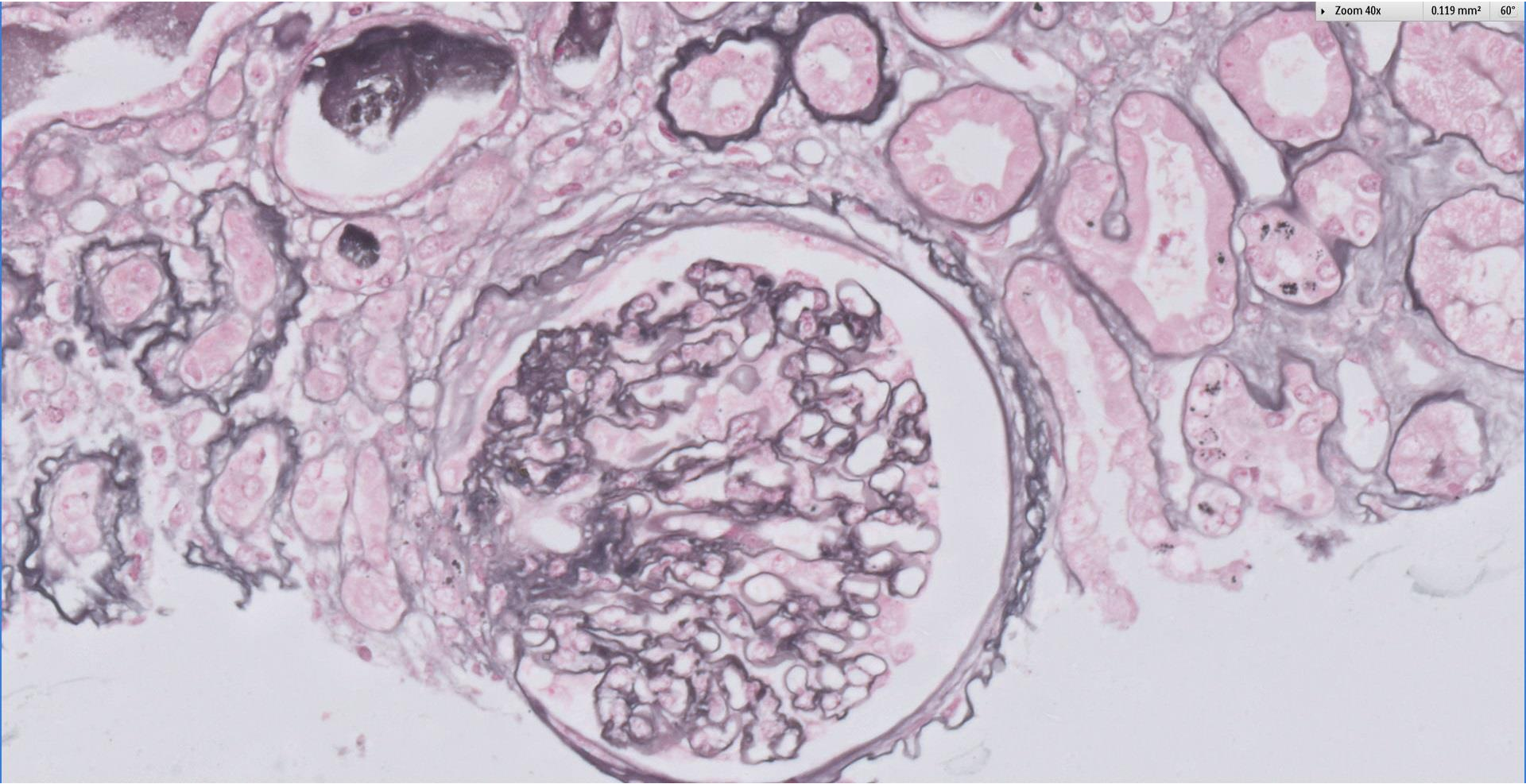
## Case 9

52 year old male with asymptomatic microscopic haematuria and proteinuria.

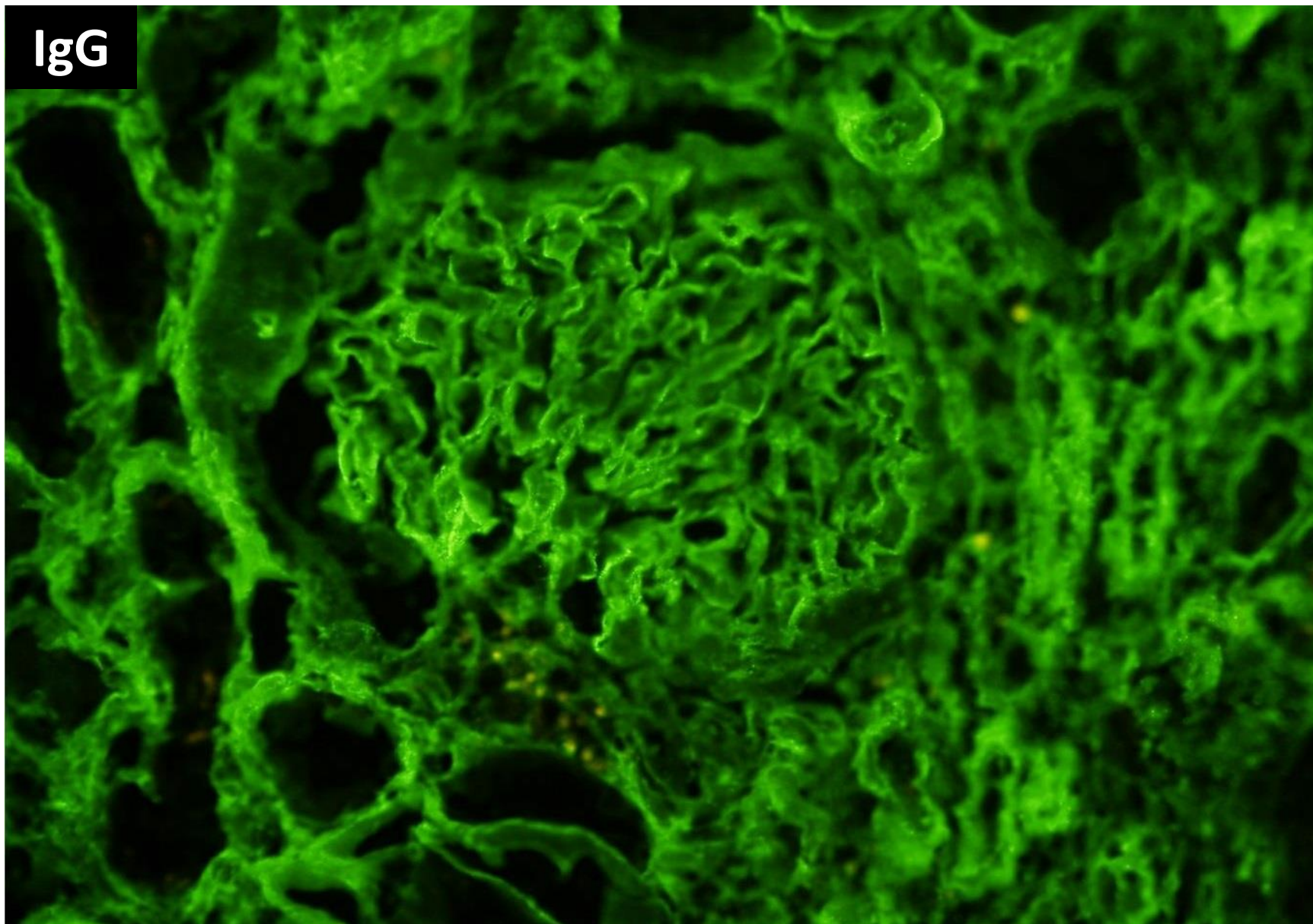




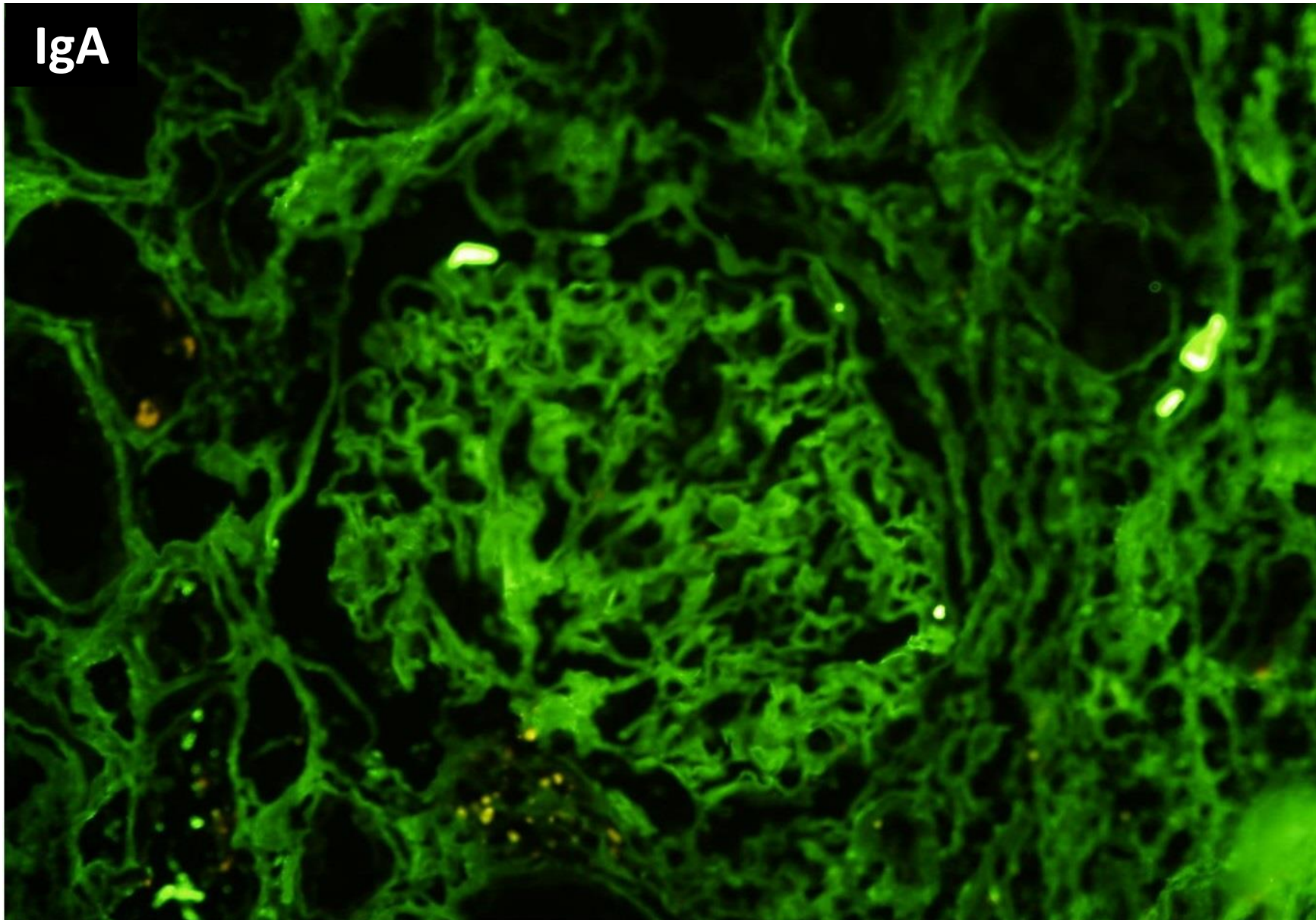




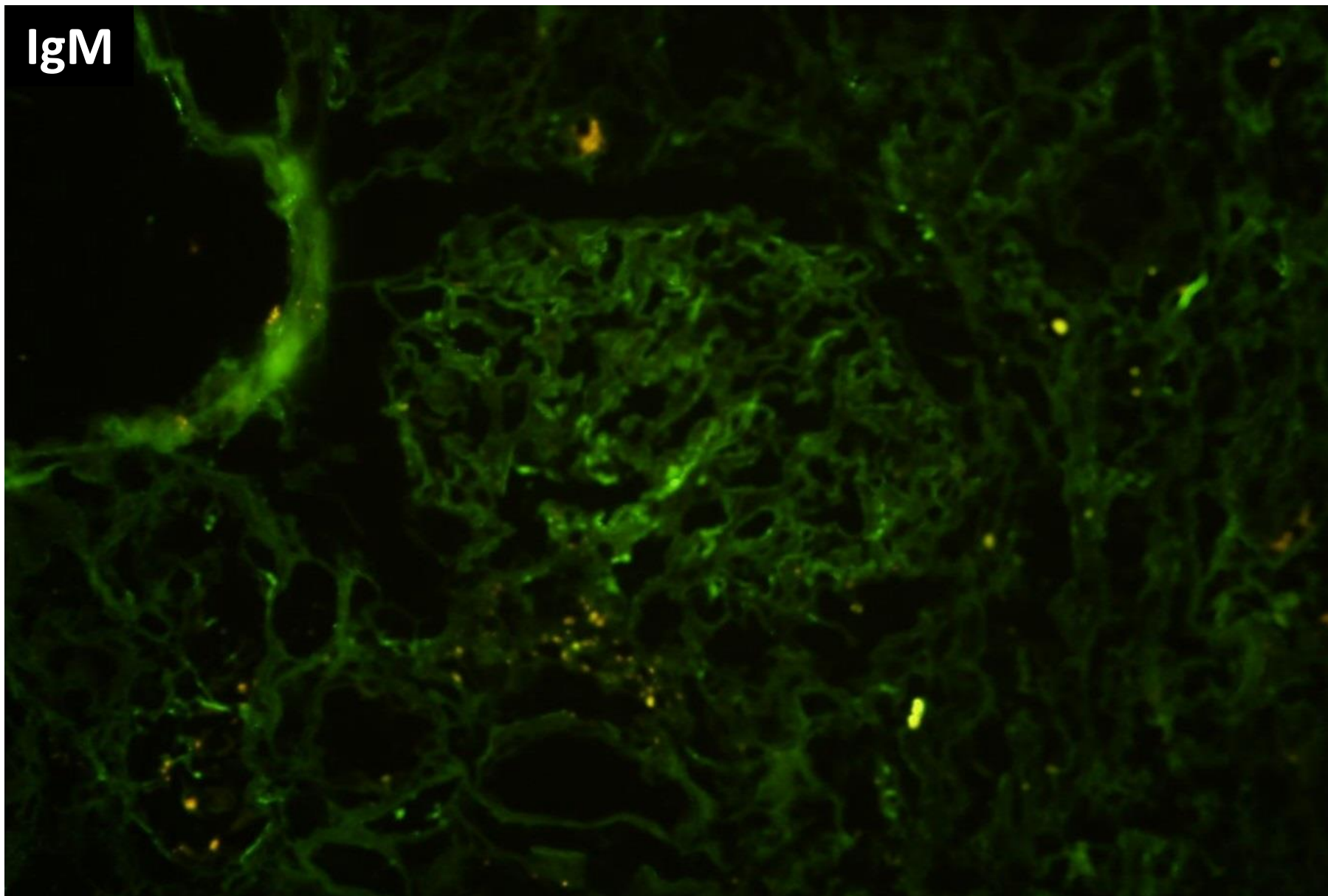
IgG



IgA

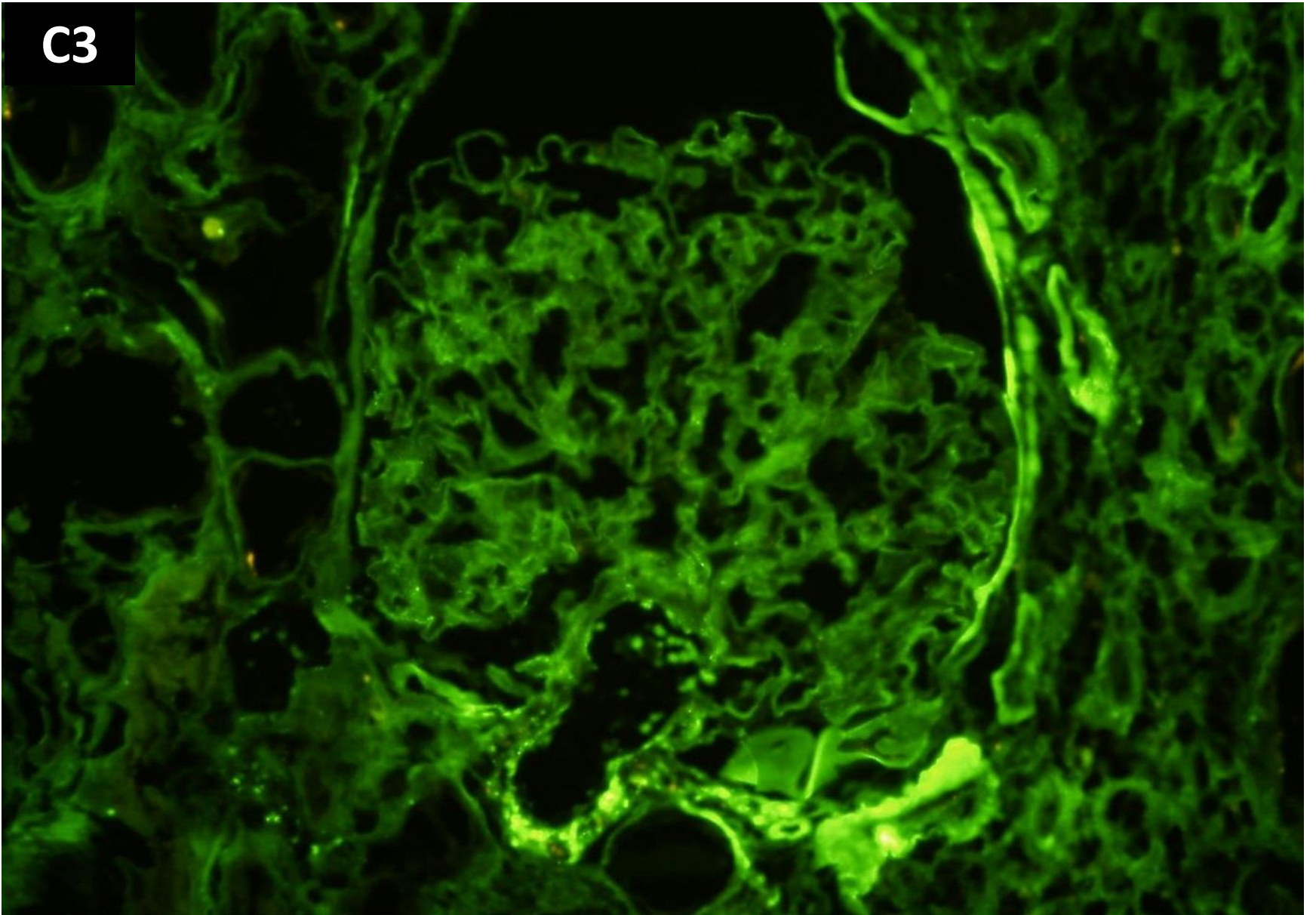


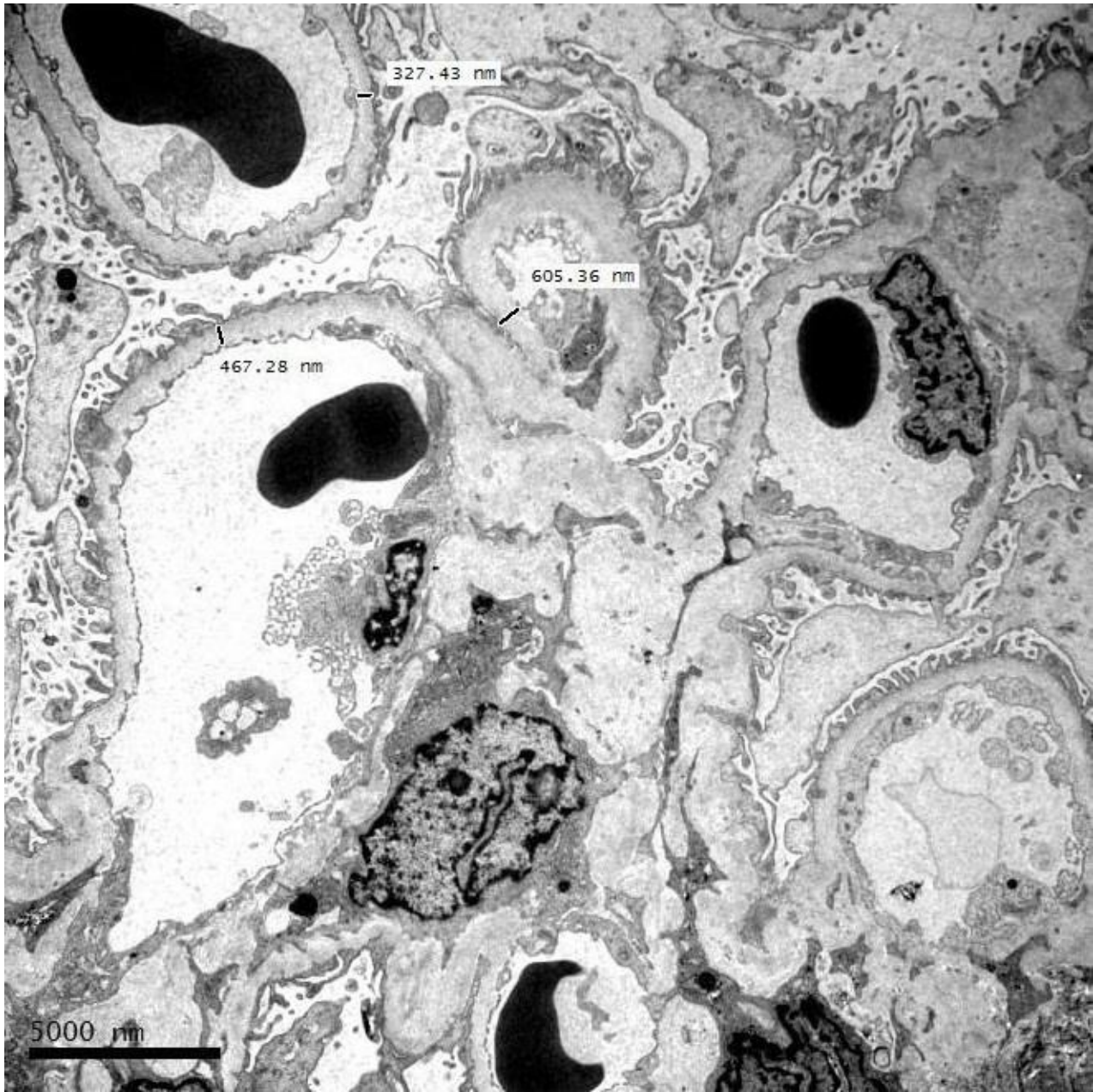
IgM

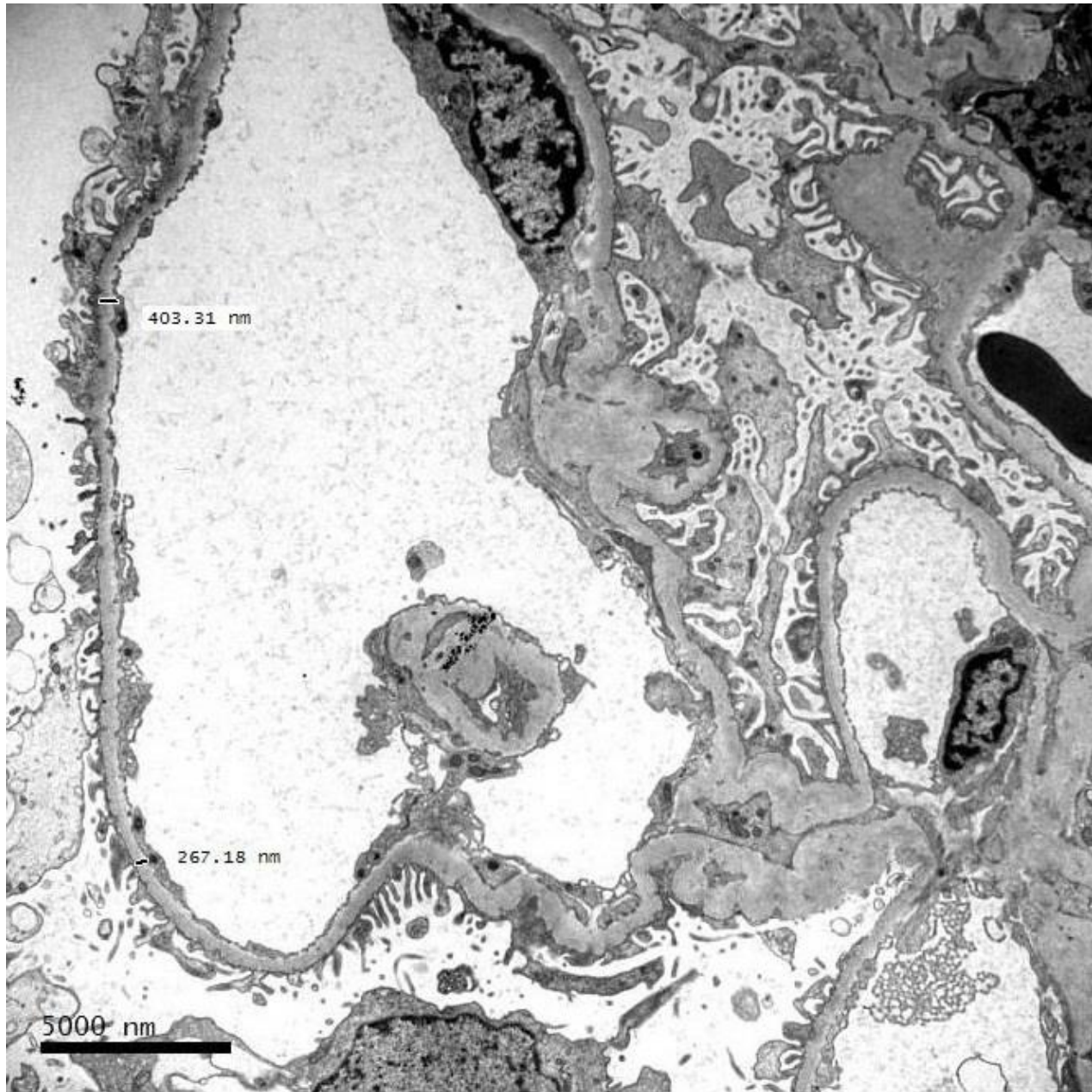


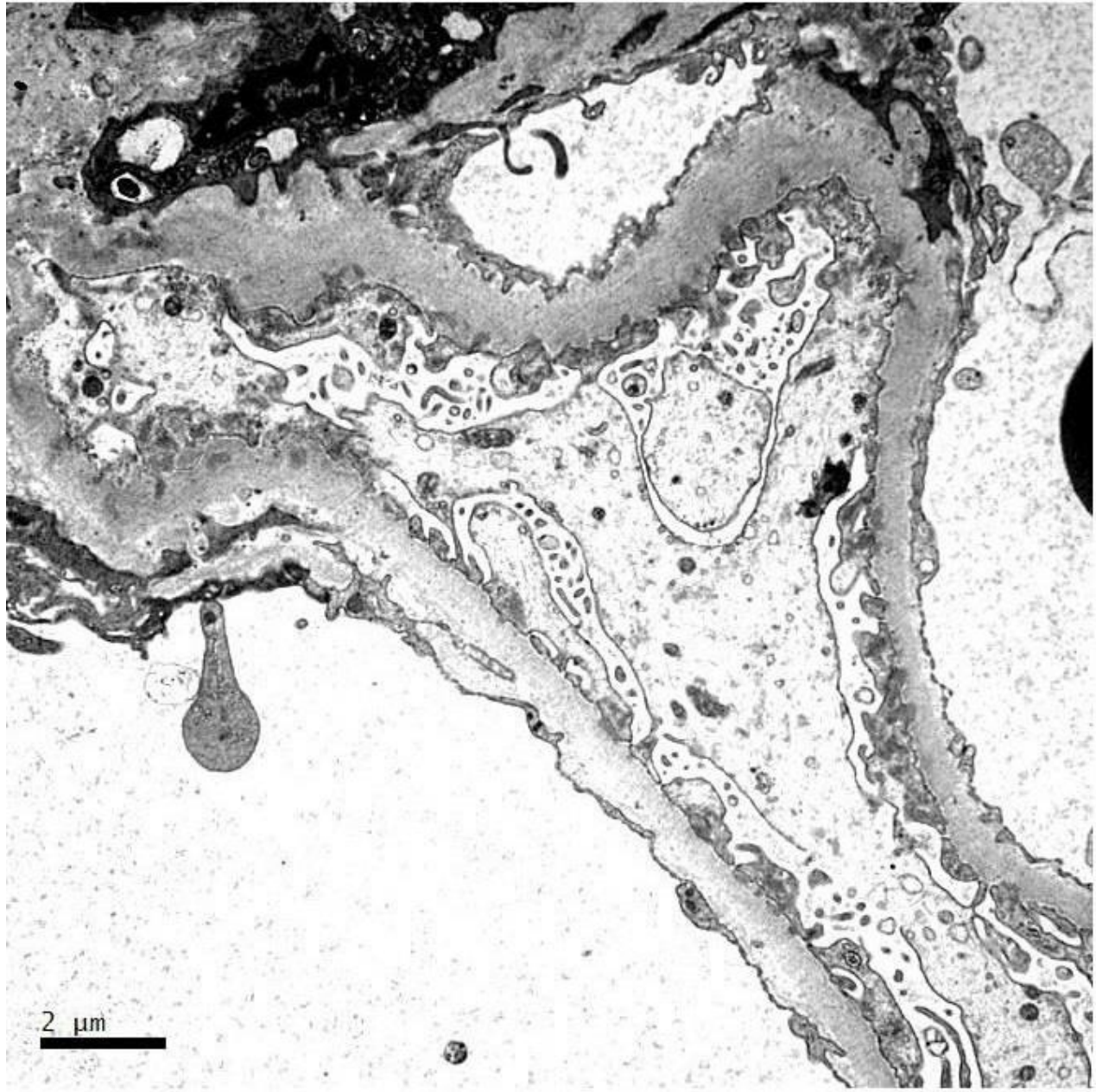


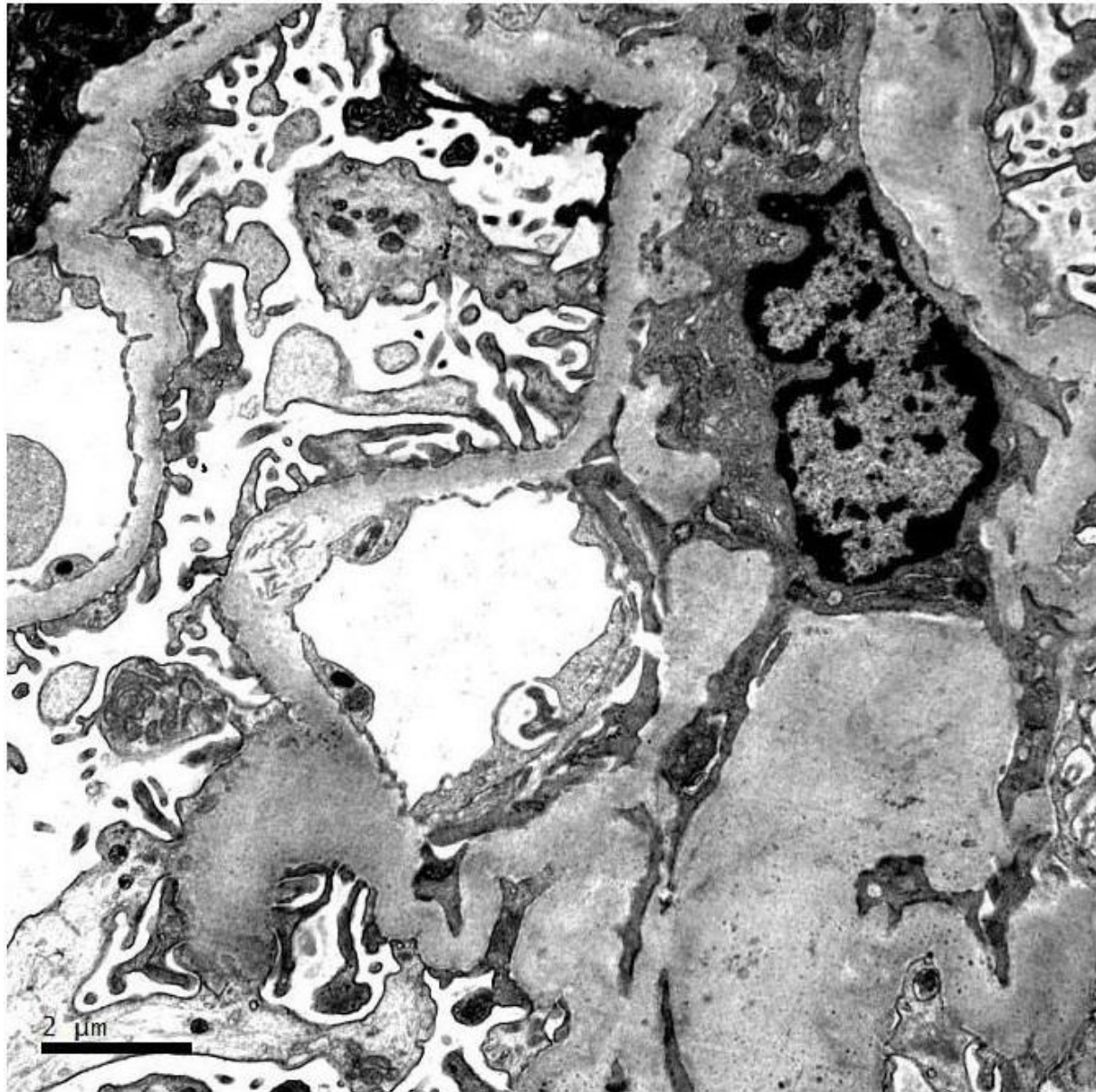
C3

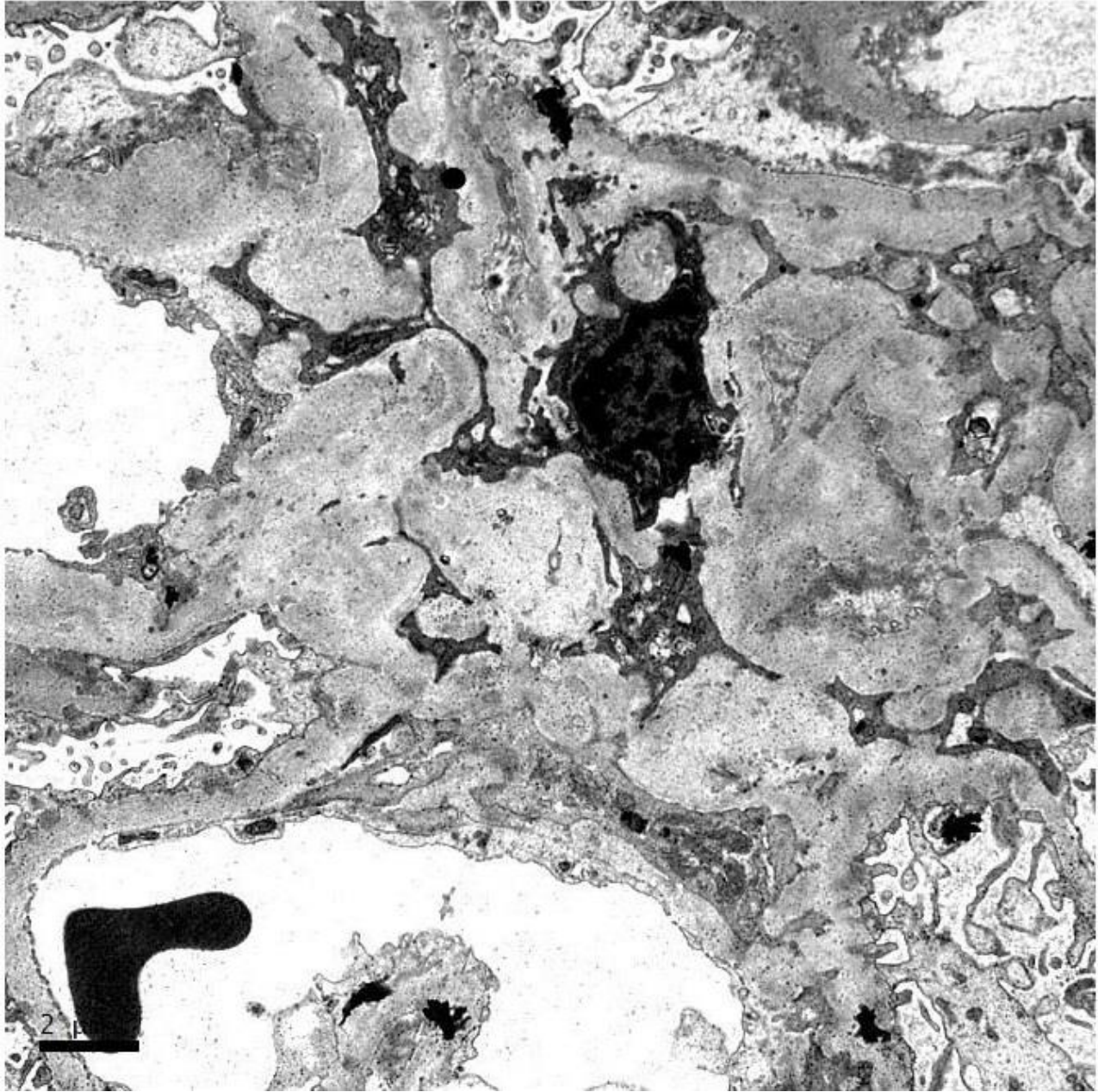


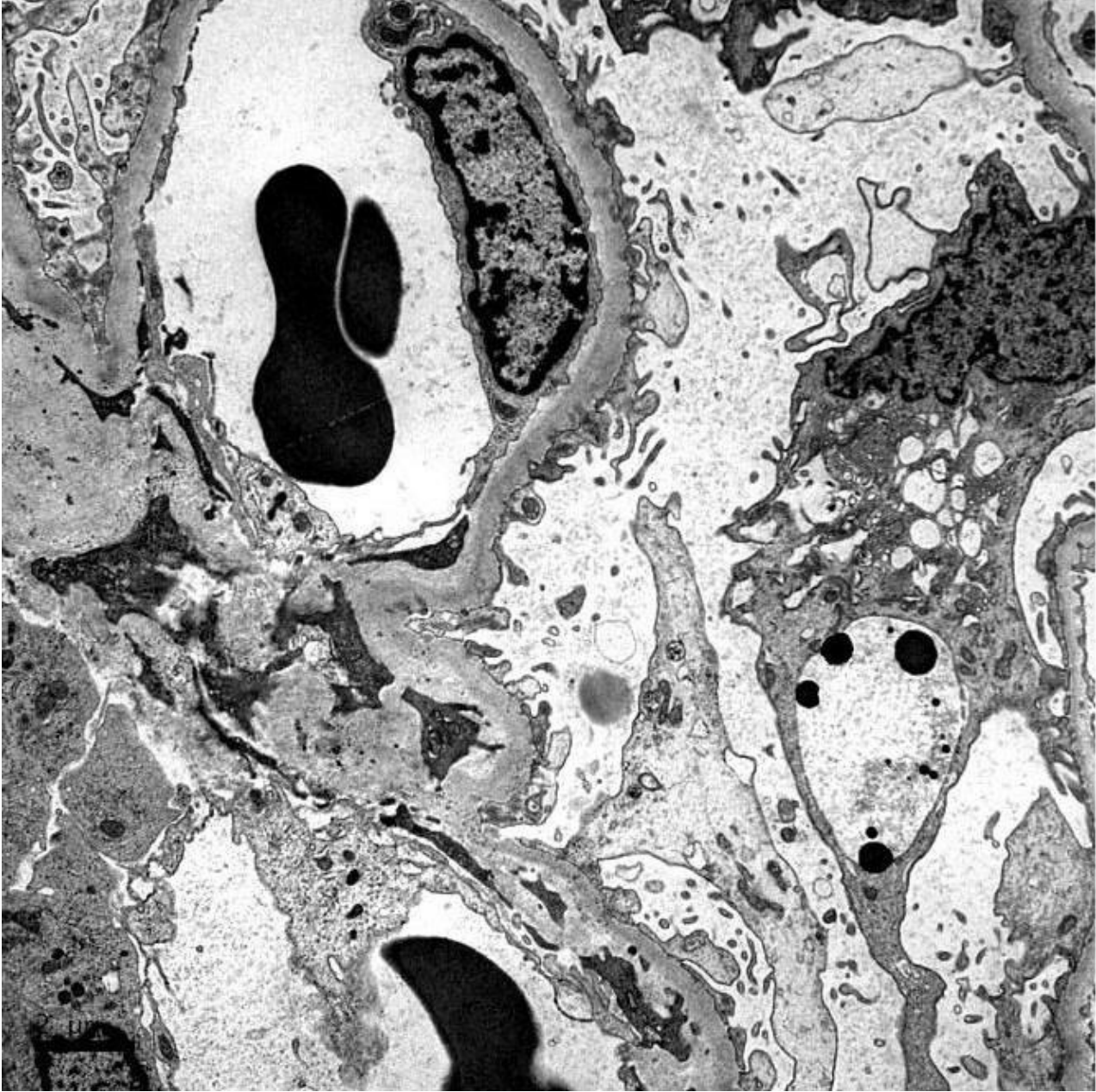


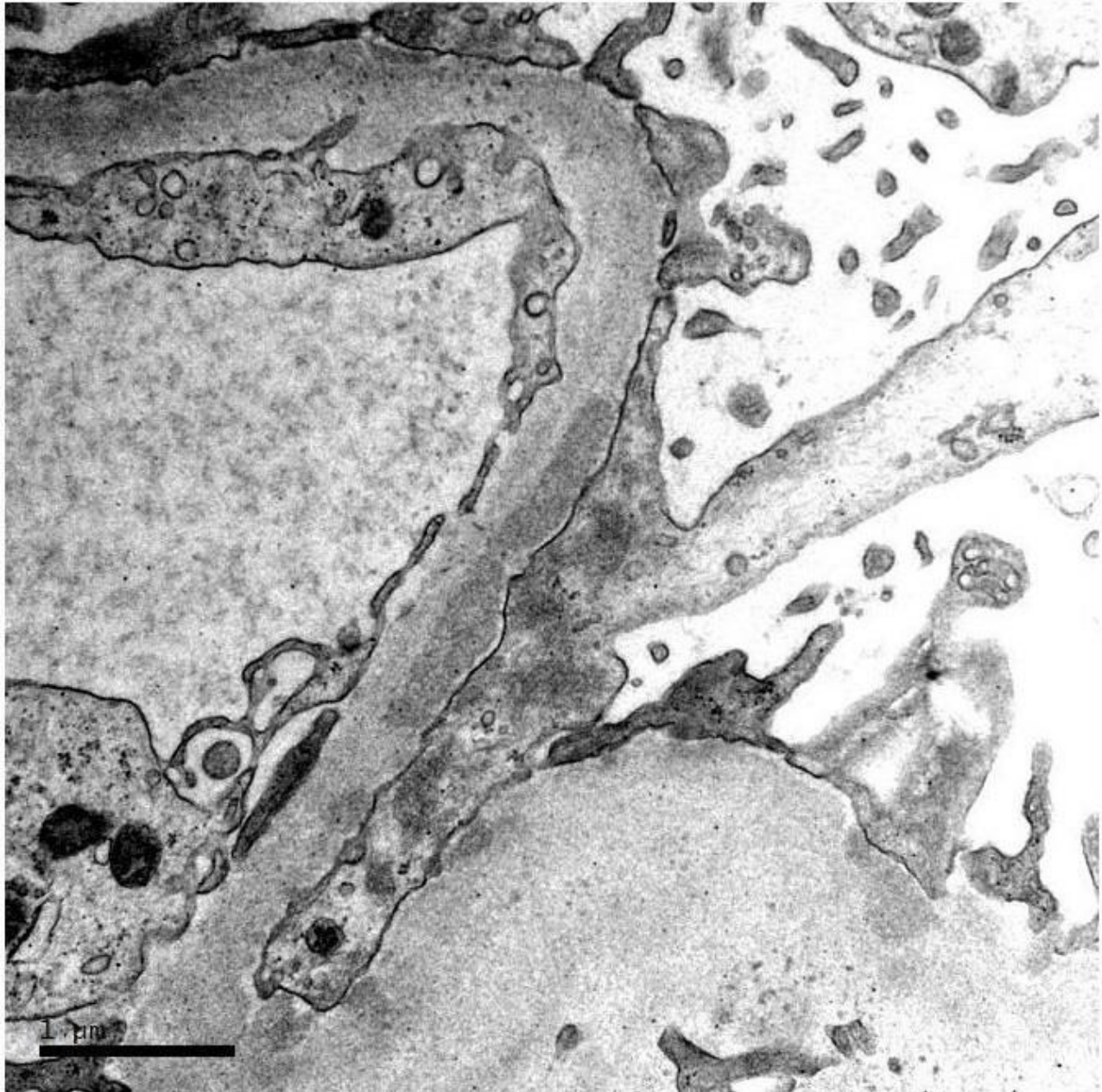




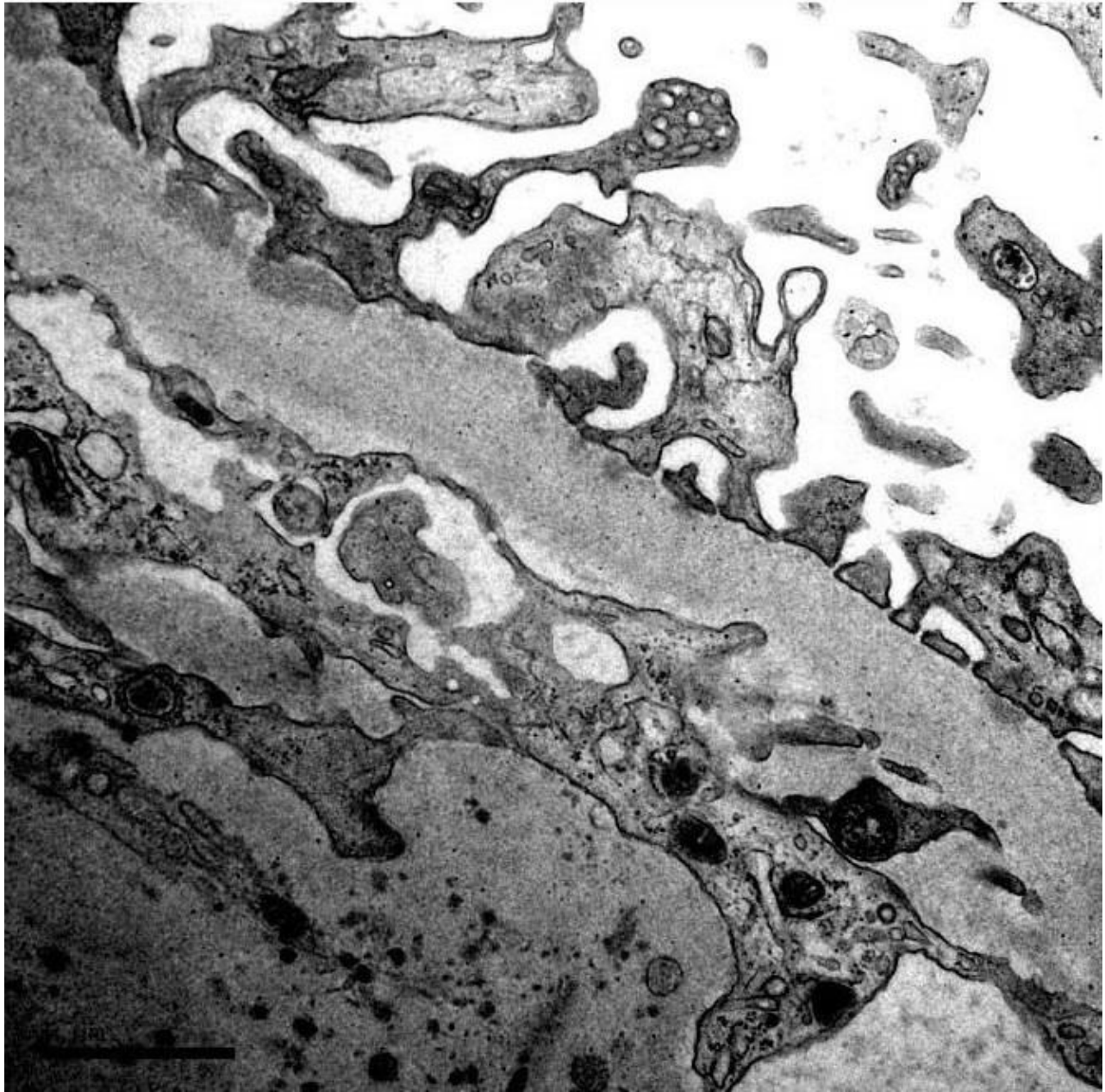


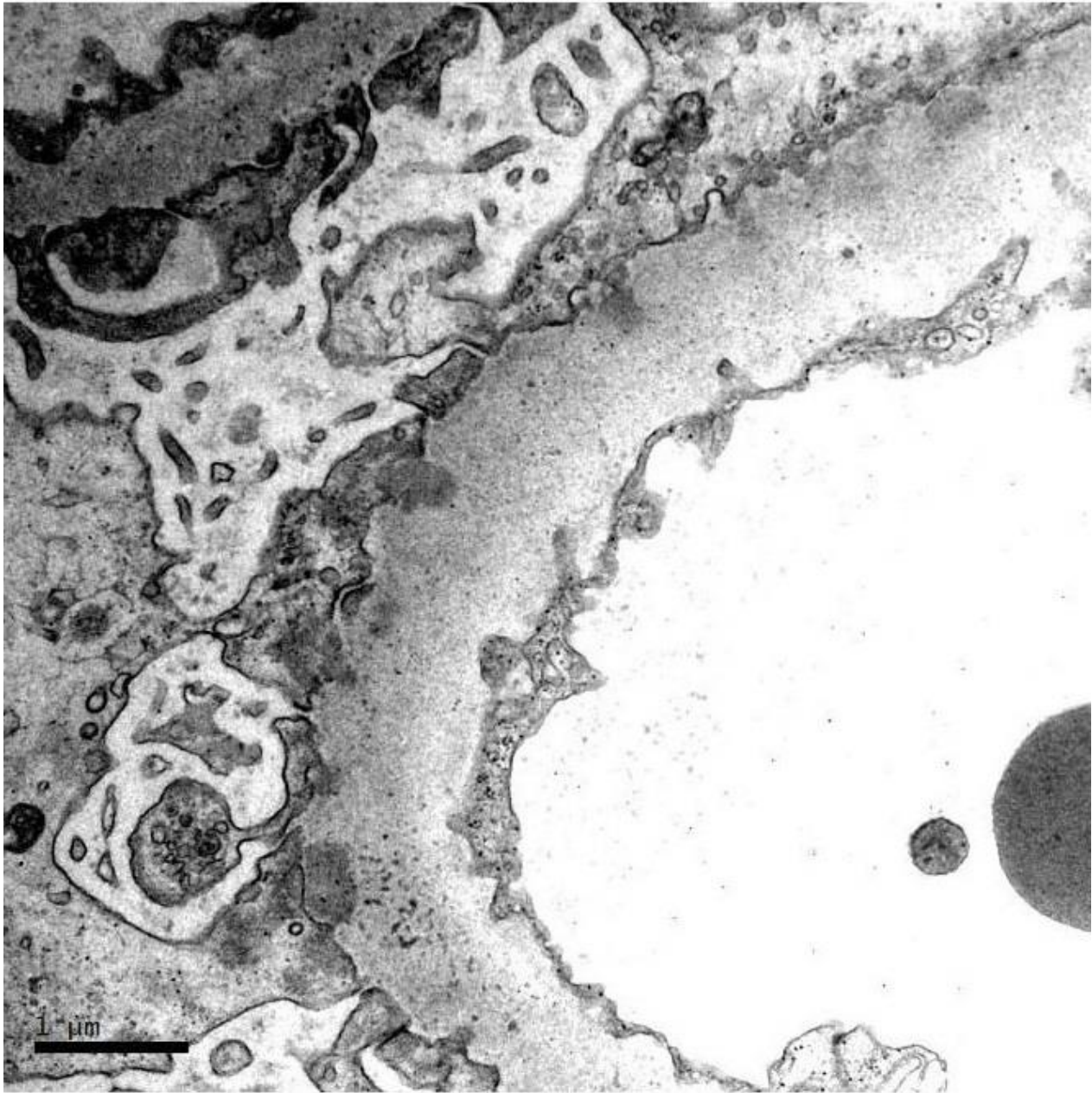














# RENAL BIOPSY CLINICOPATHOLOGICAL WORKSHOP 2018



**PATHOLOGY**



Division of Pathology  
Singapore General Hospital



Department of Renal Medicine  
Singapore General Hospital



**MEDICINE**