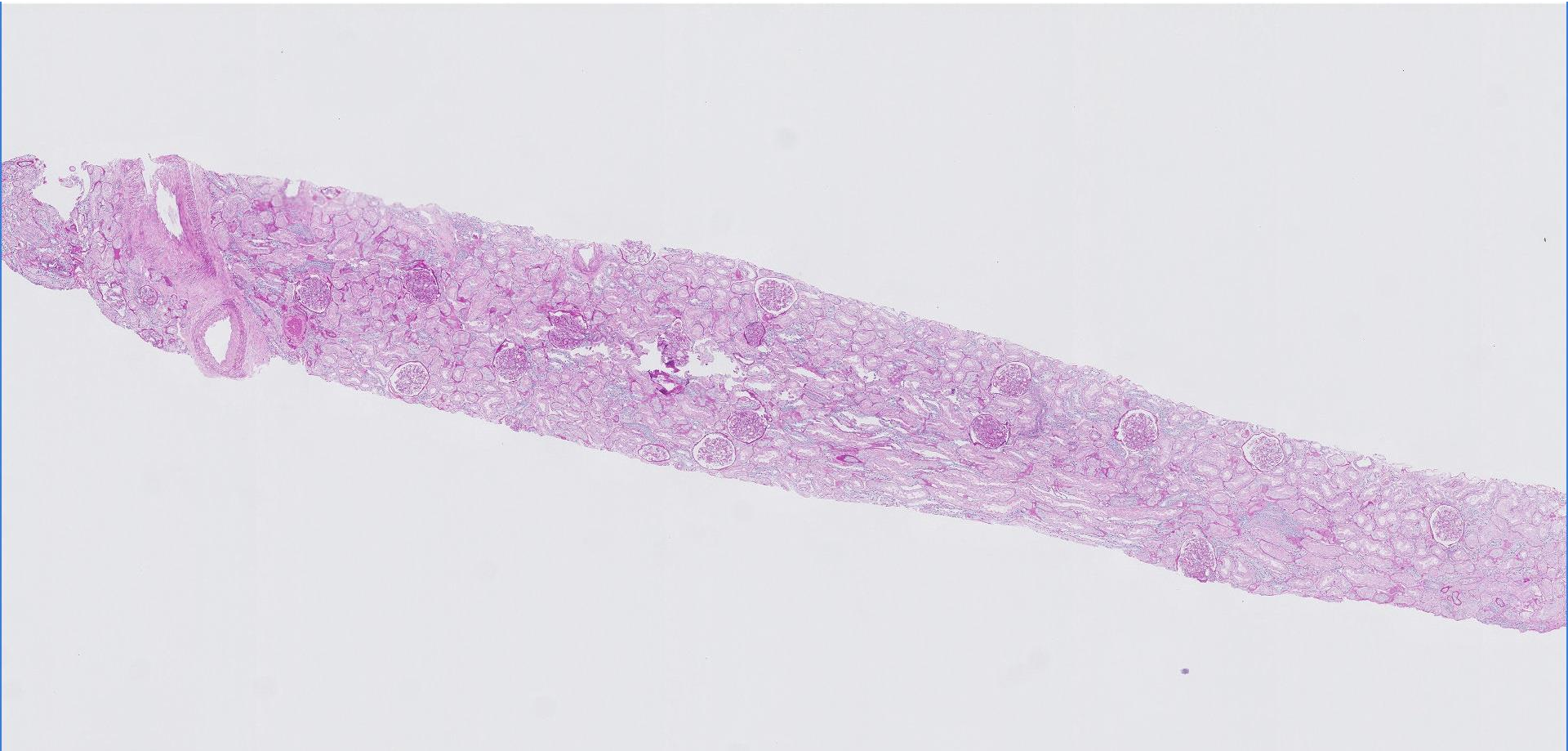
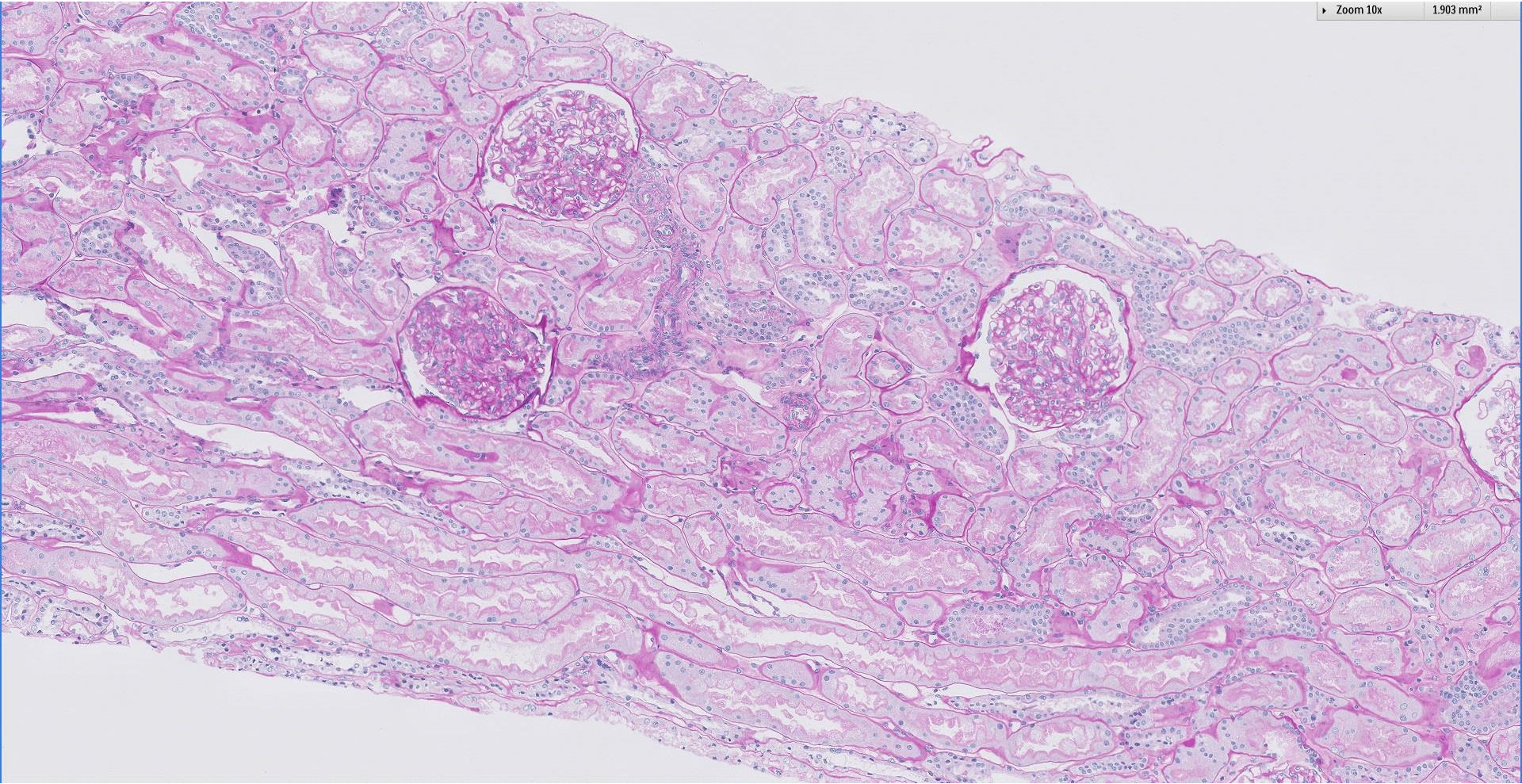


Case 3

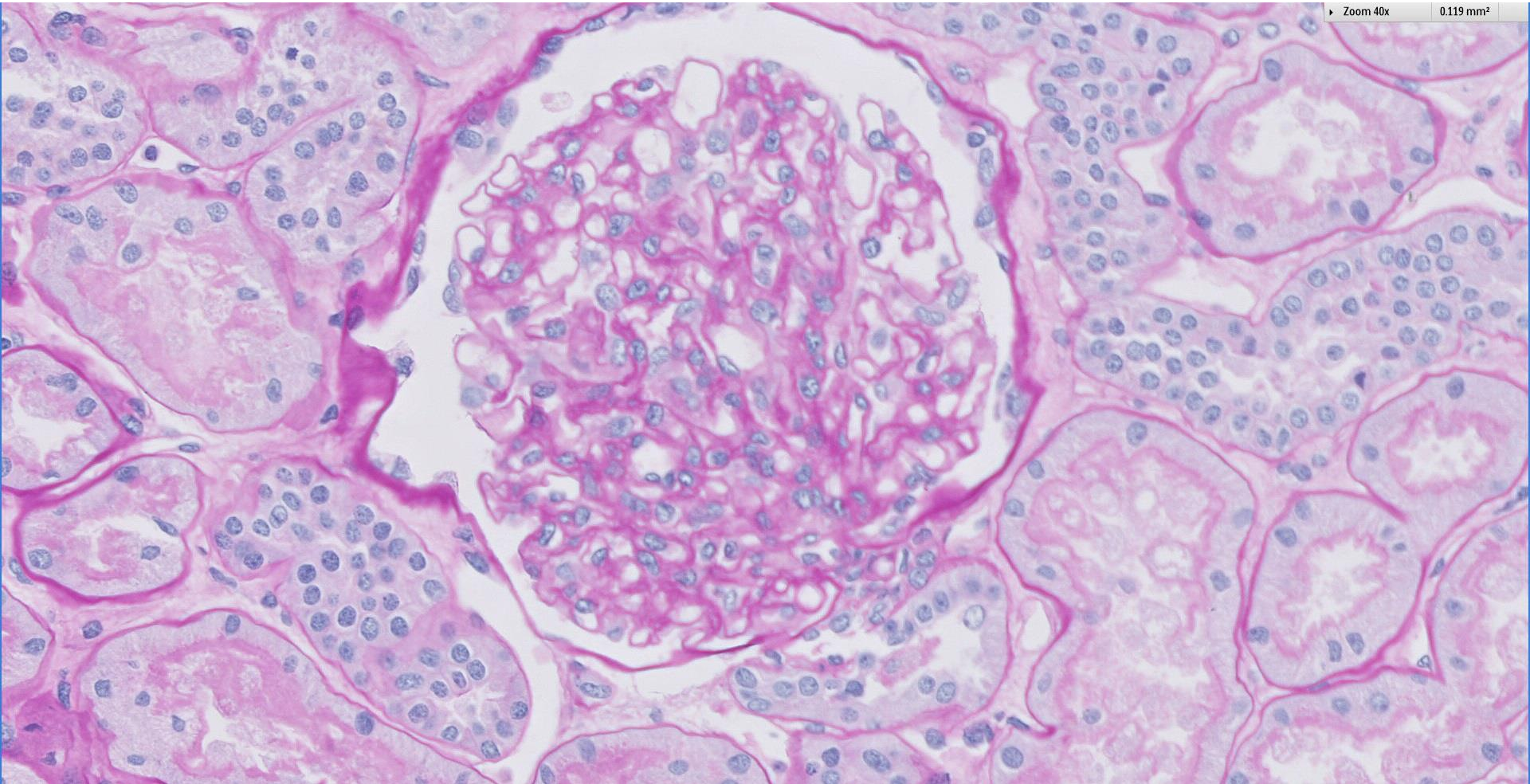
43 year old male with urine red blood cells 20 per hpf and TUP 8.6 g/day. Virology serology negative.



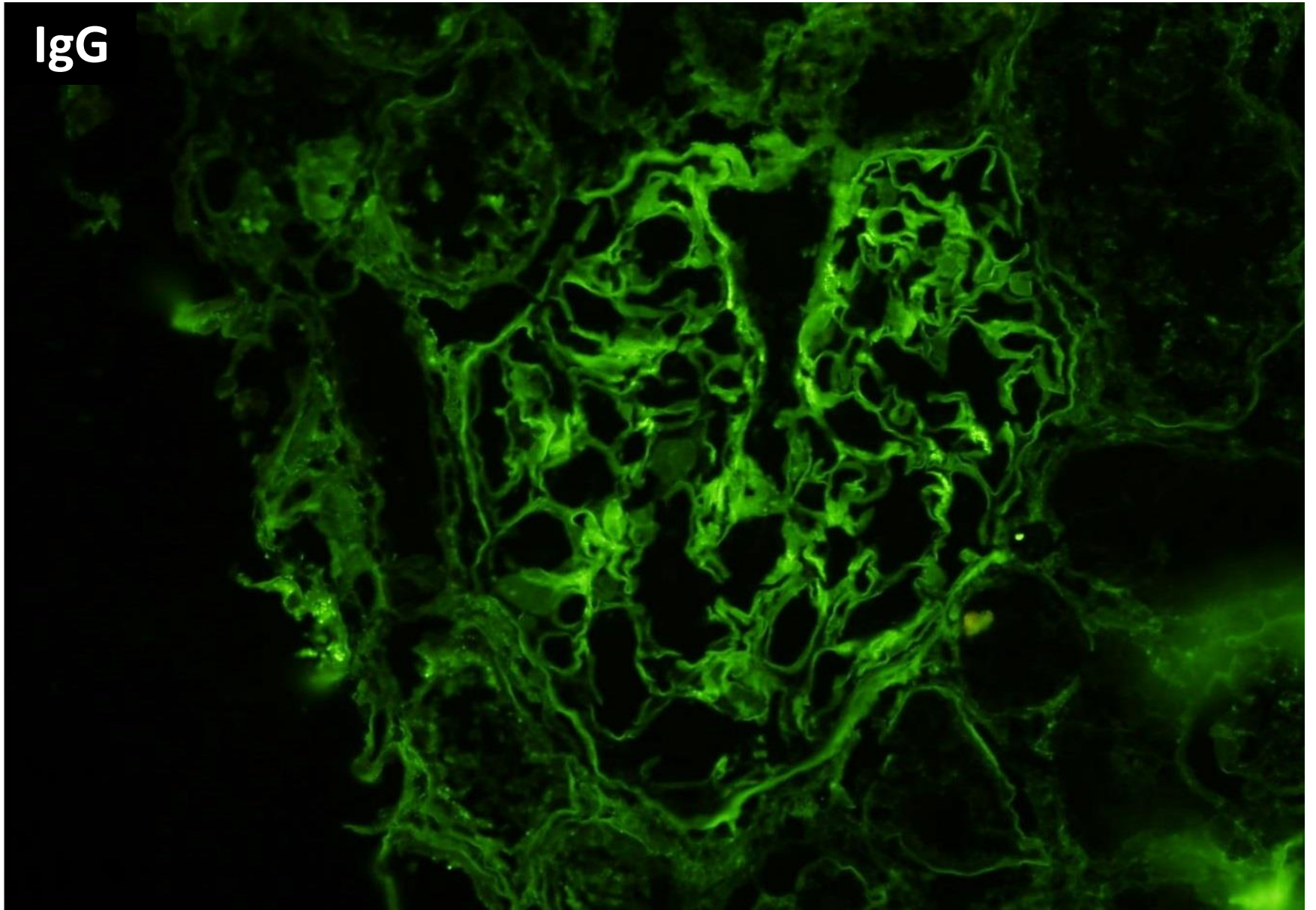


Zoom 40x

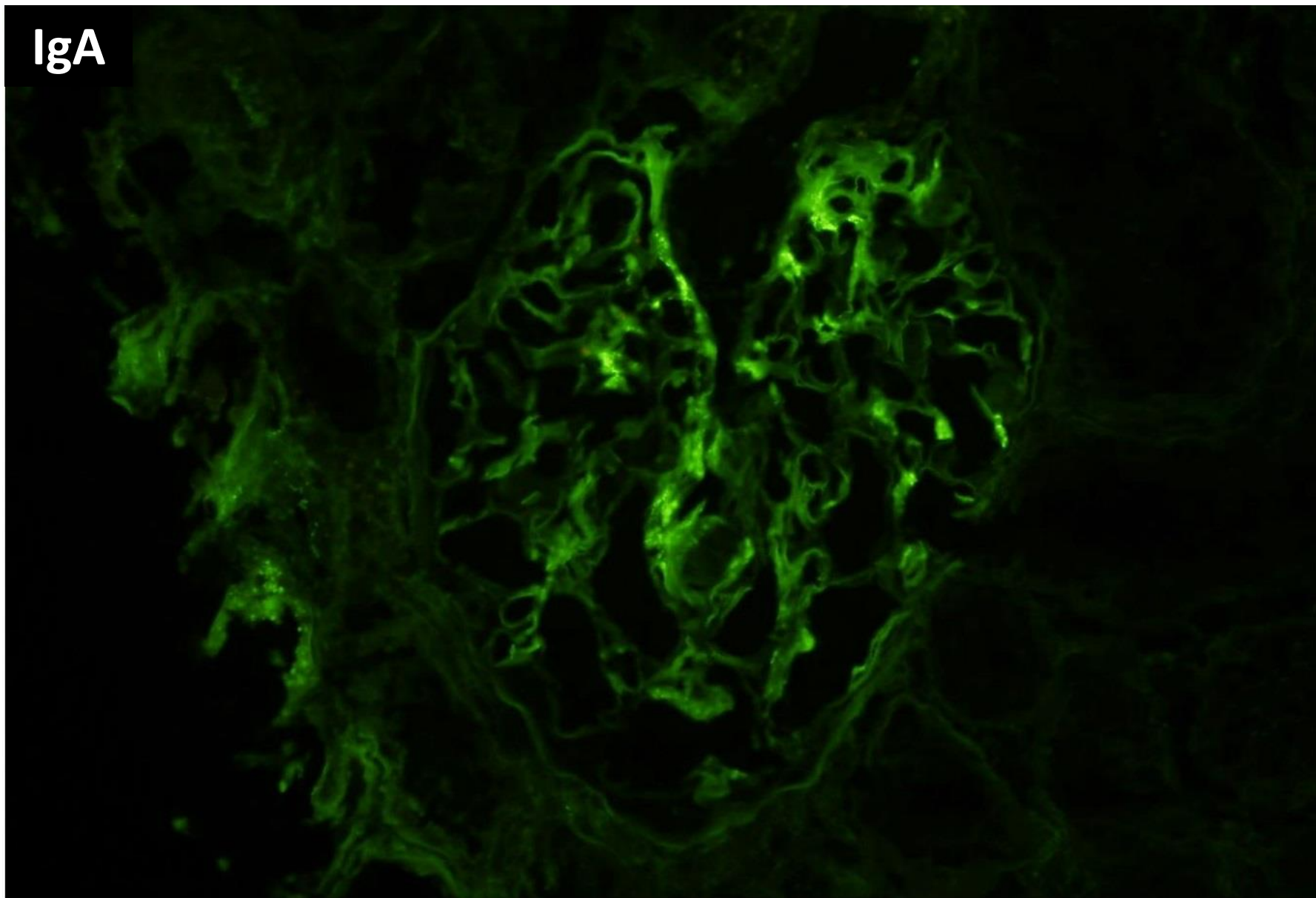
0.119 mm²



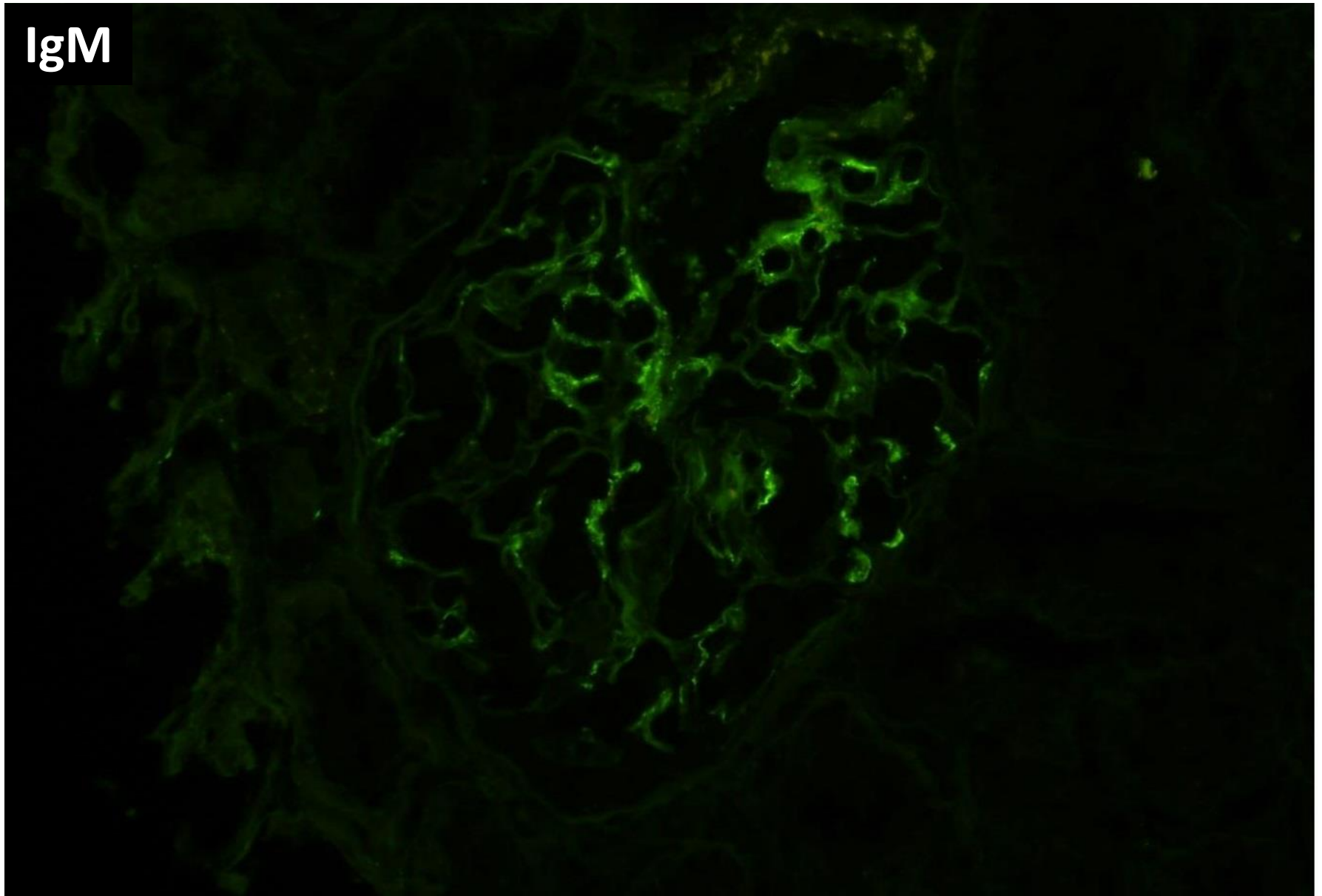
IgG



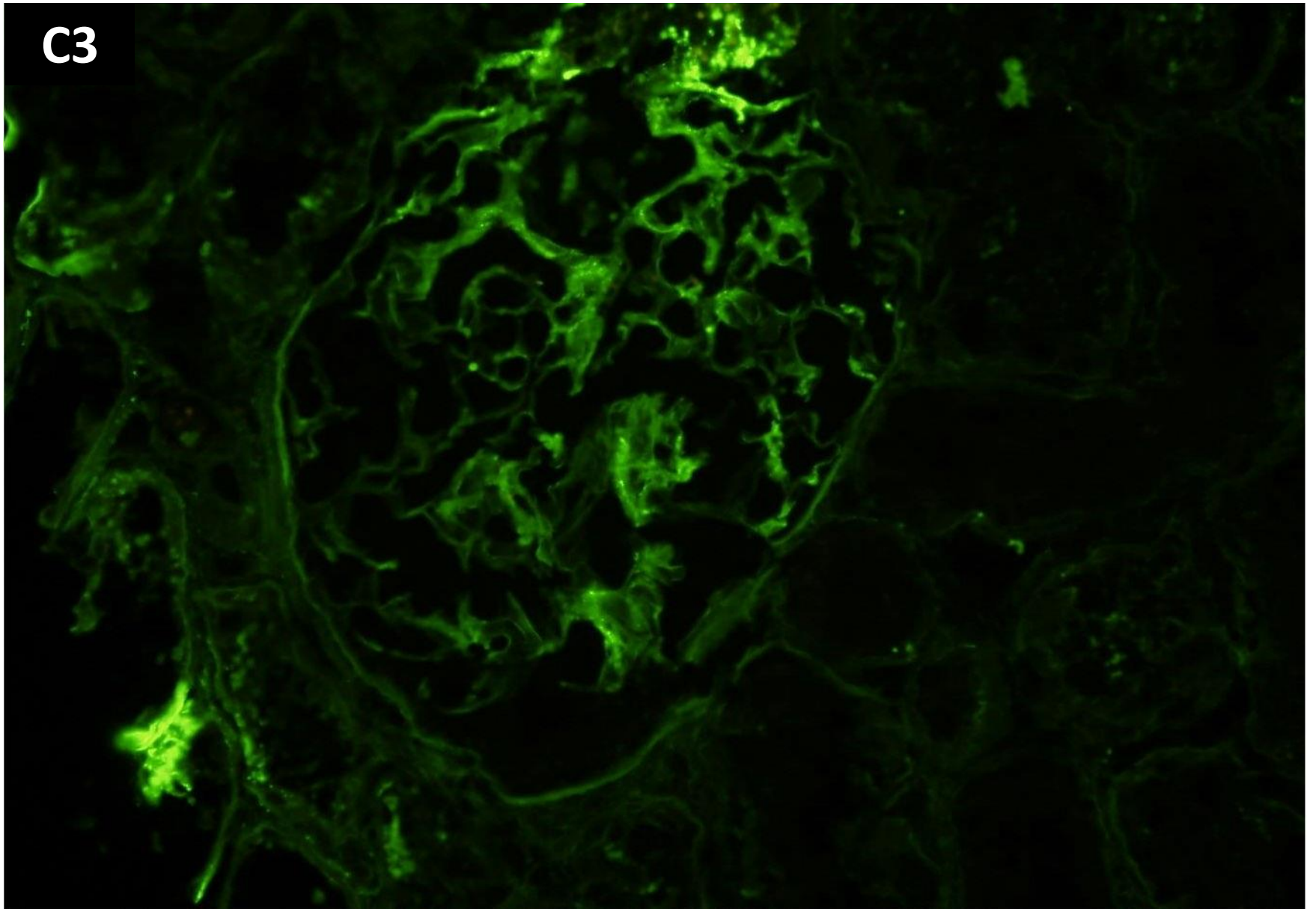
IgA

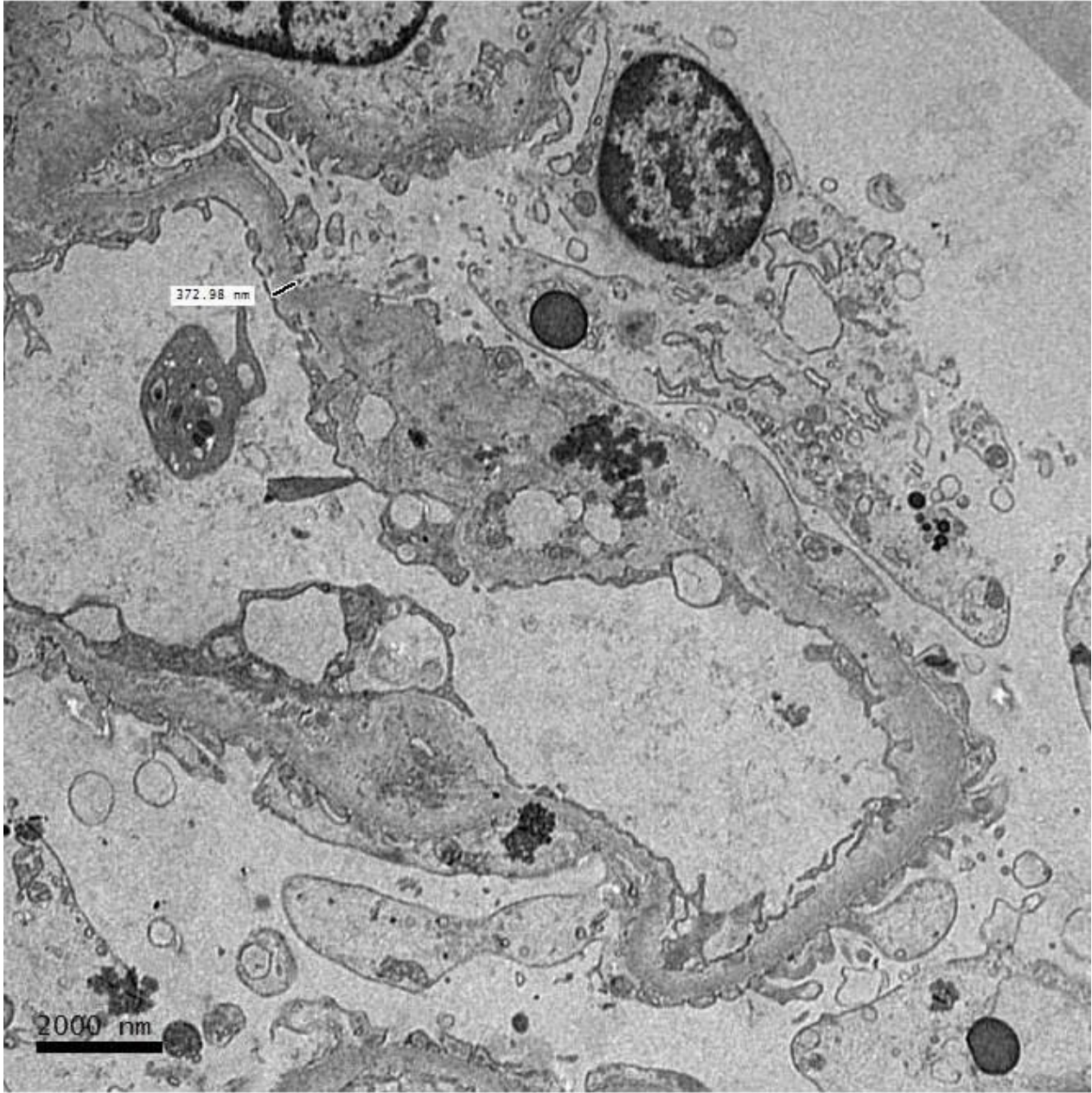


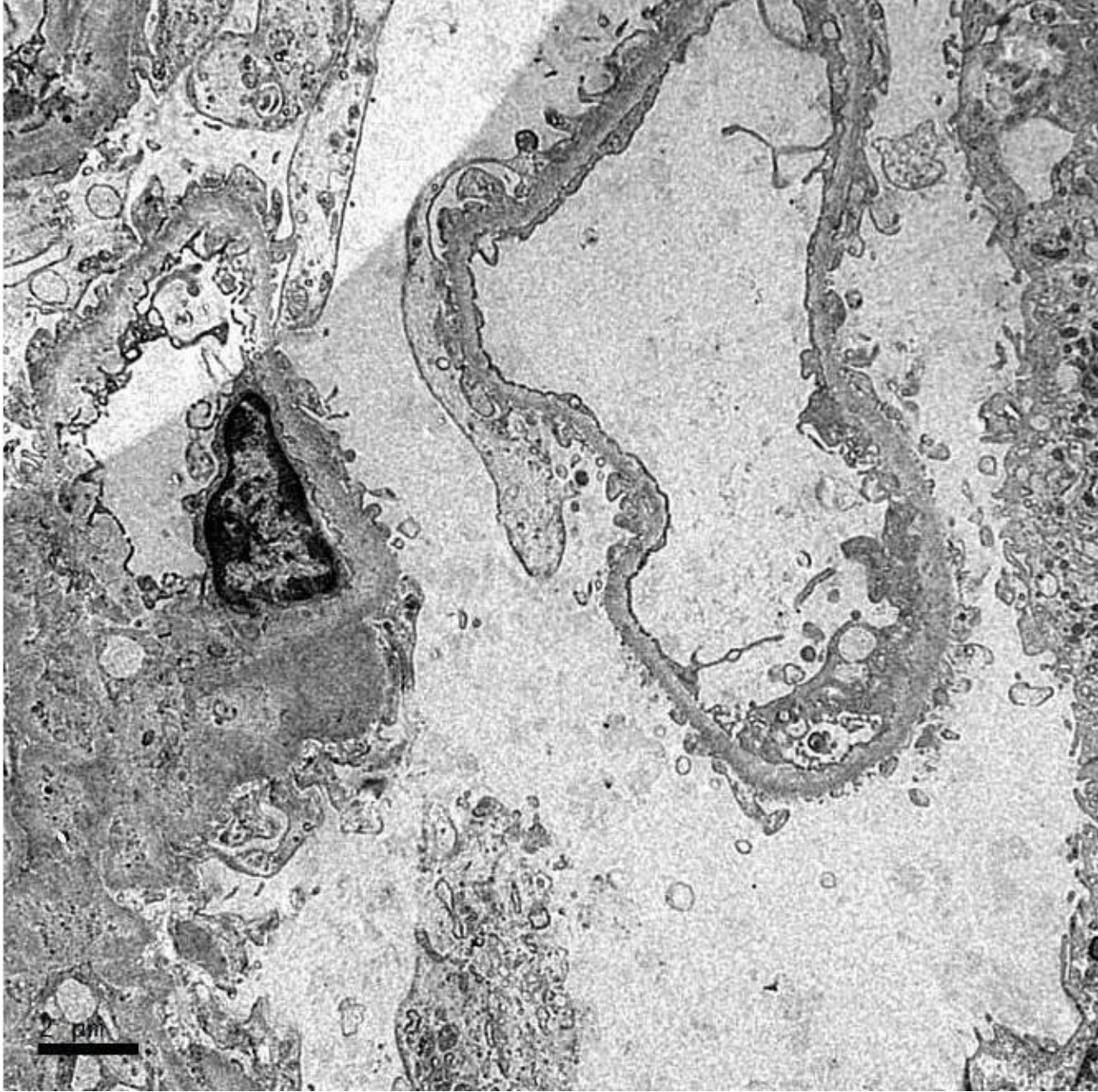
IgM

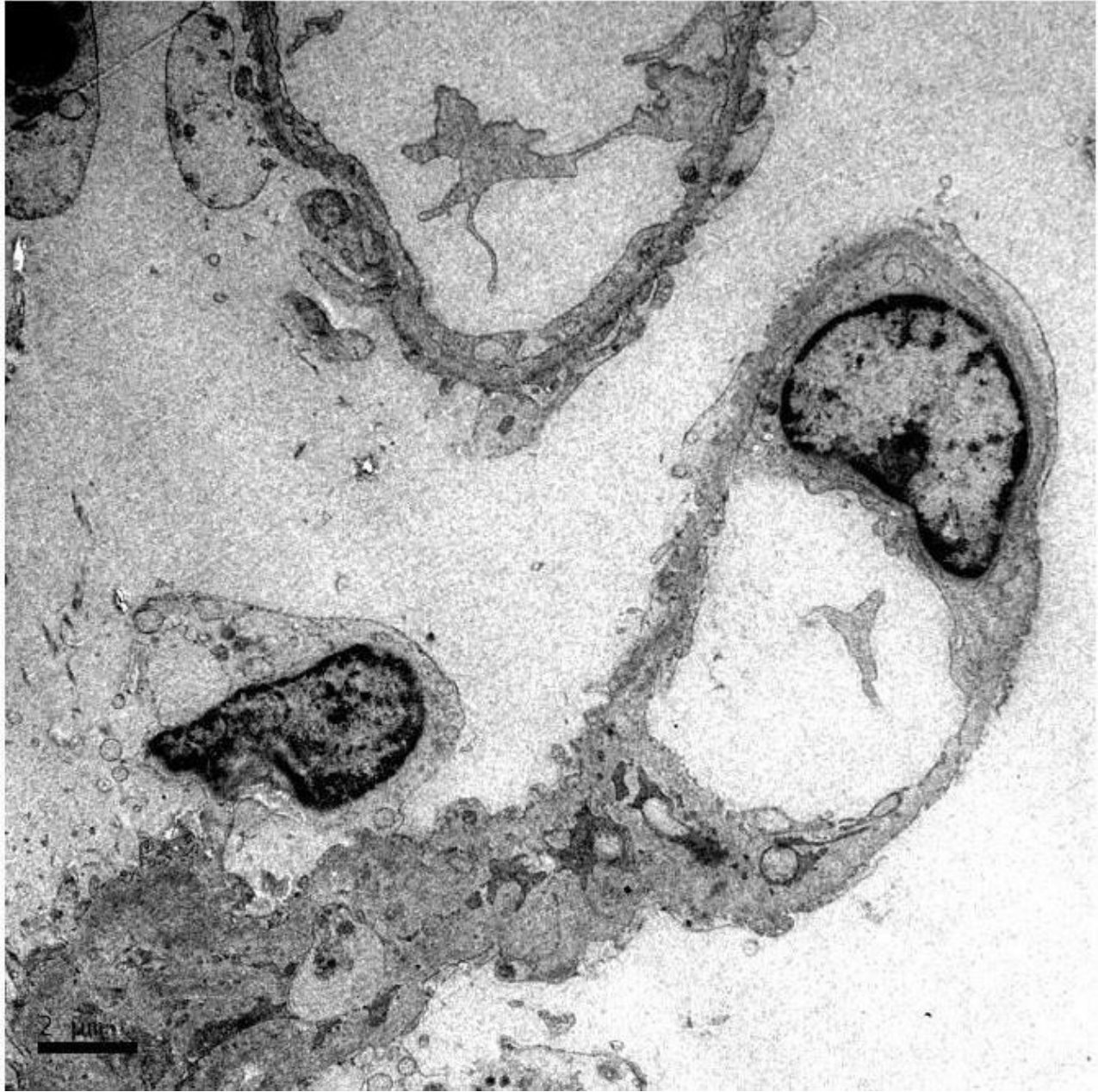


C3











RENAL BIOPSY CLINICOPATHOLOGICAL WORKSHOP 2018



PATHOLOGY



Division of Pathology
Singapore General Hospital



Department of Renal Medicine
Singapore General Hospital



MEDICINE