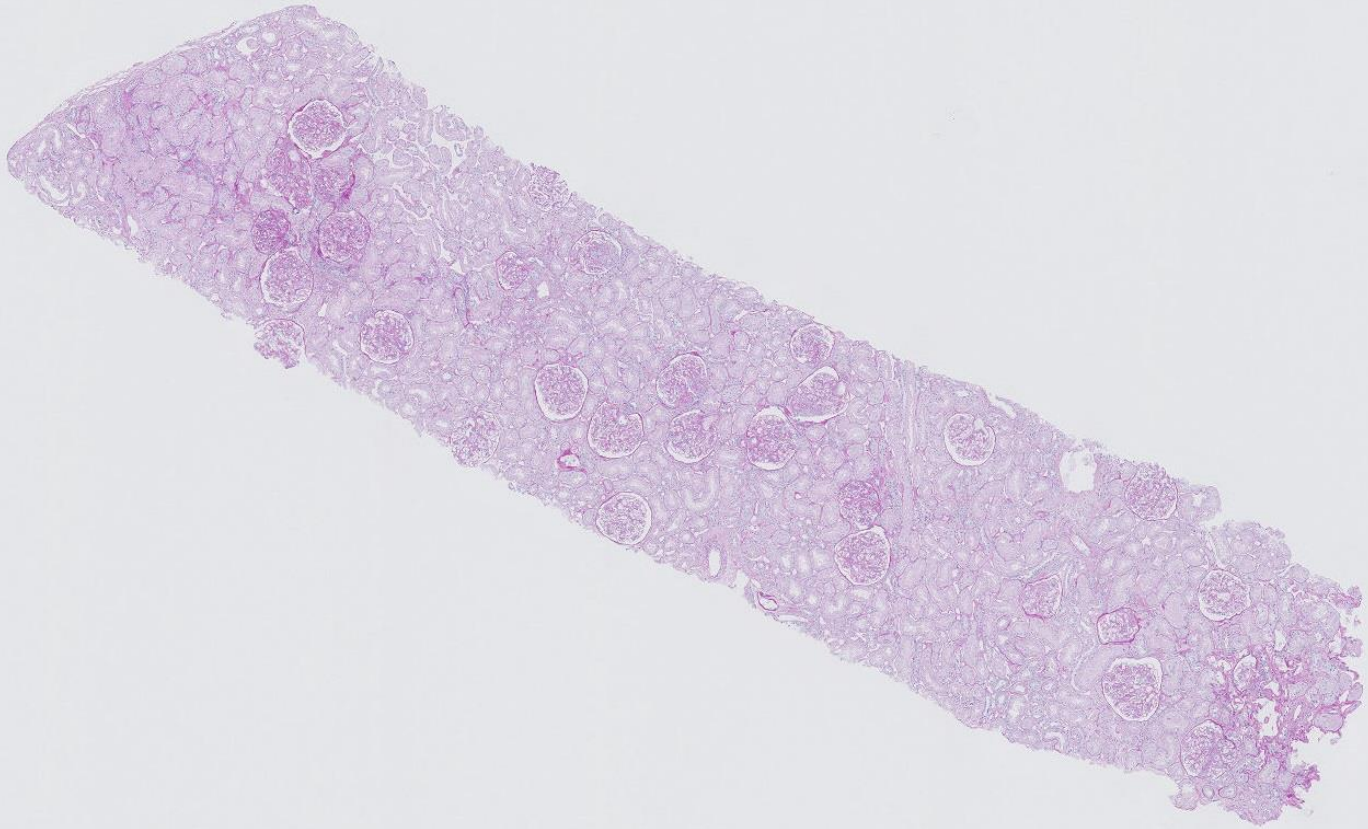


## Case 10

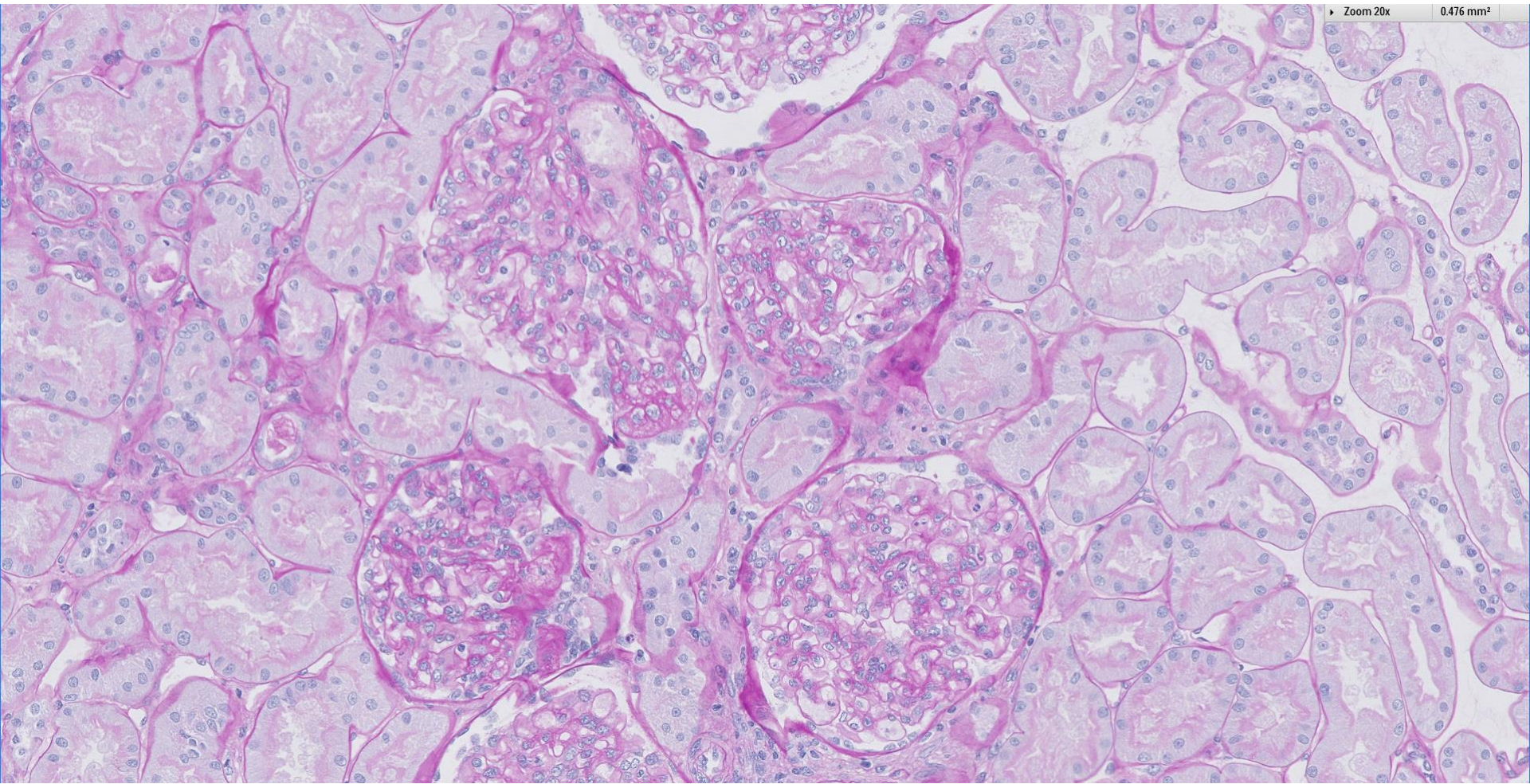
20 year old male with lower limb swelling for 1 month.  
Serum Cr 70, albumin 18 and UPCR 7.38 g/g. Virology &  
autoimmune markers negative.





Zoom 20x

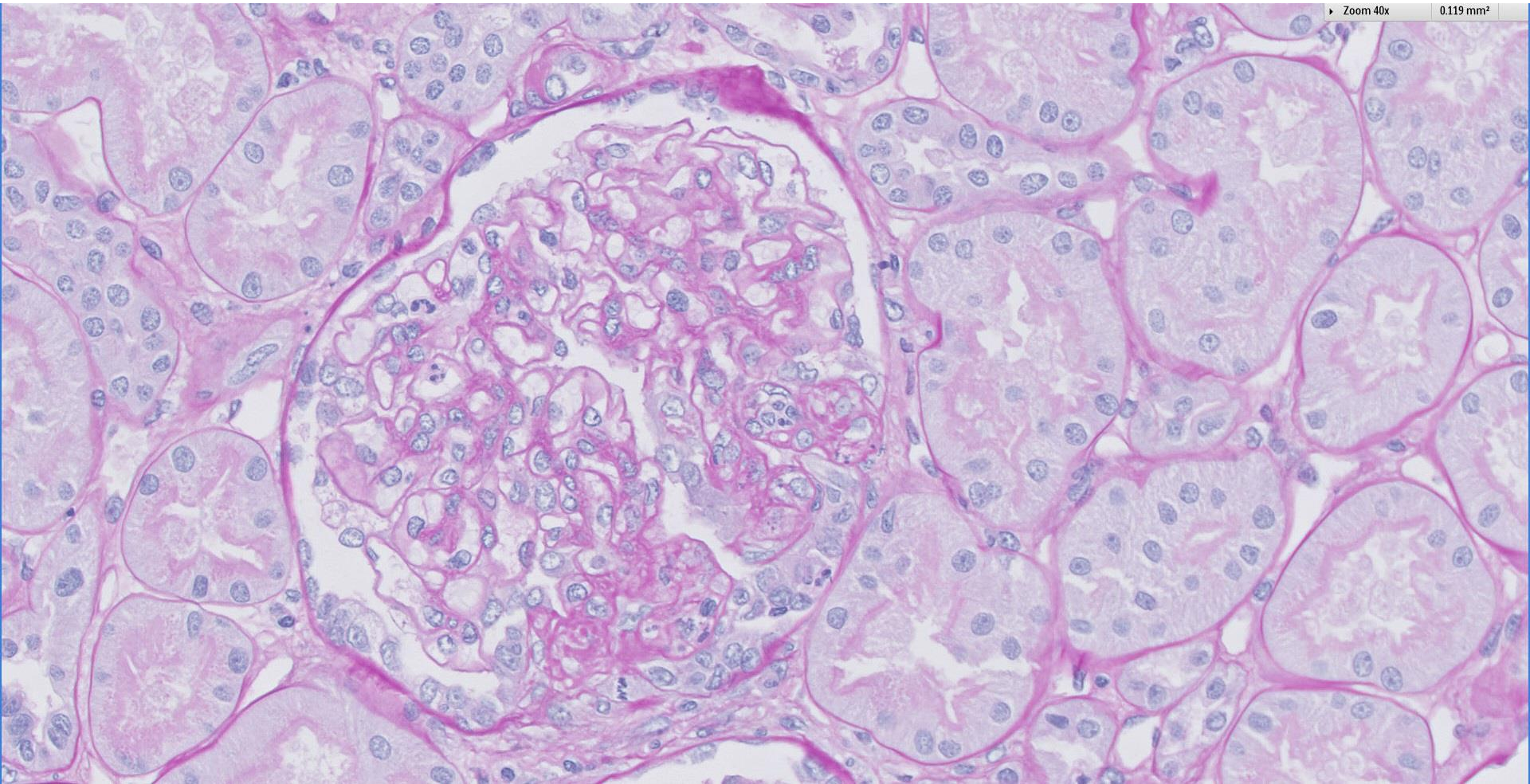
0.476 mm<sup>2</sup>



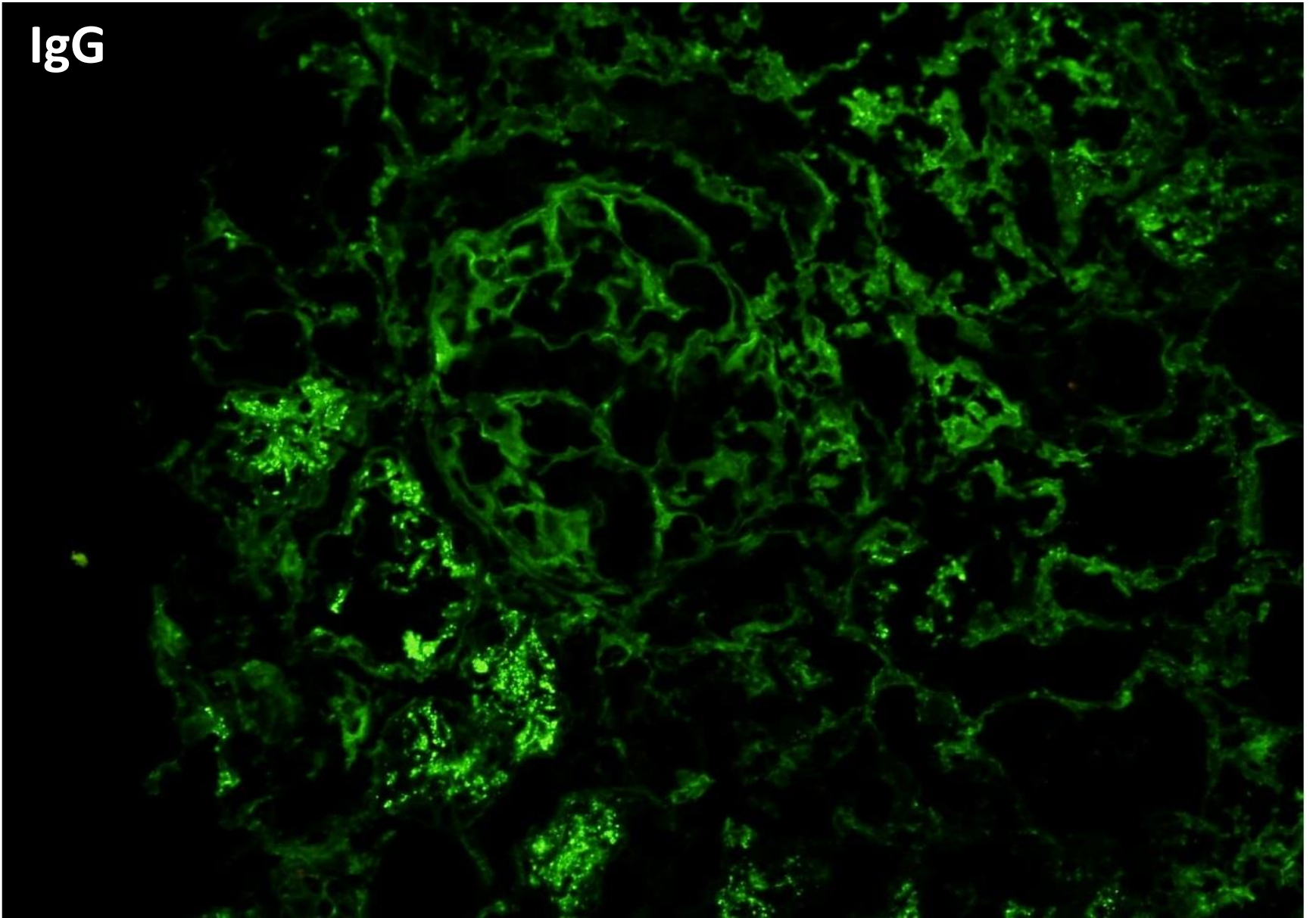


Zoom 40x

0.119 mm<sup>2</sup>

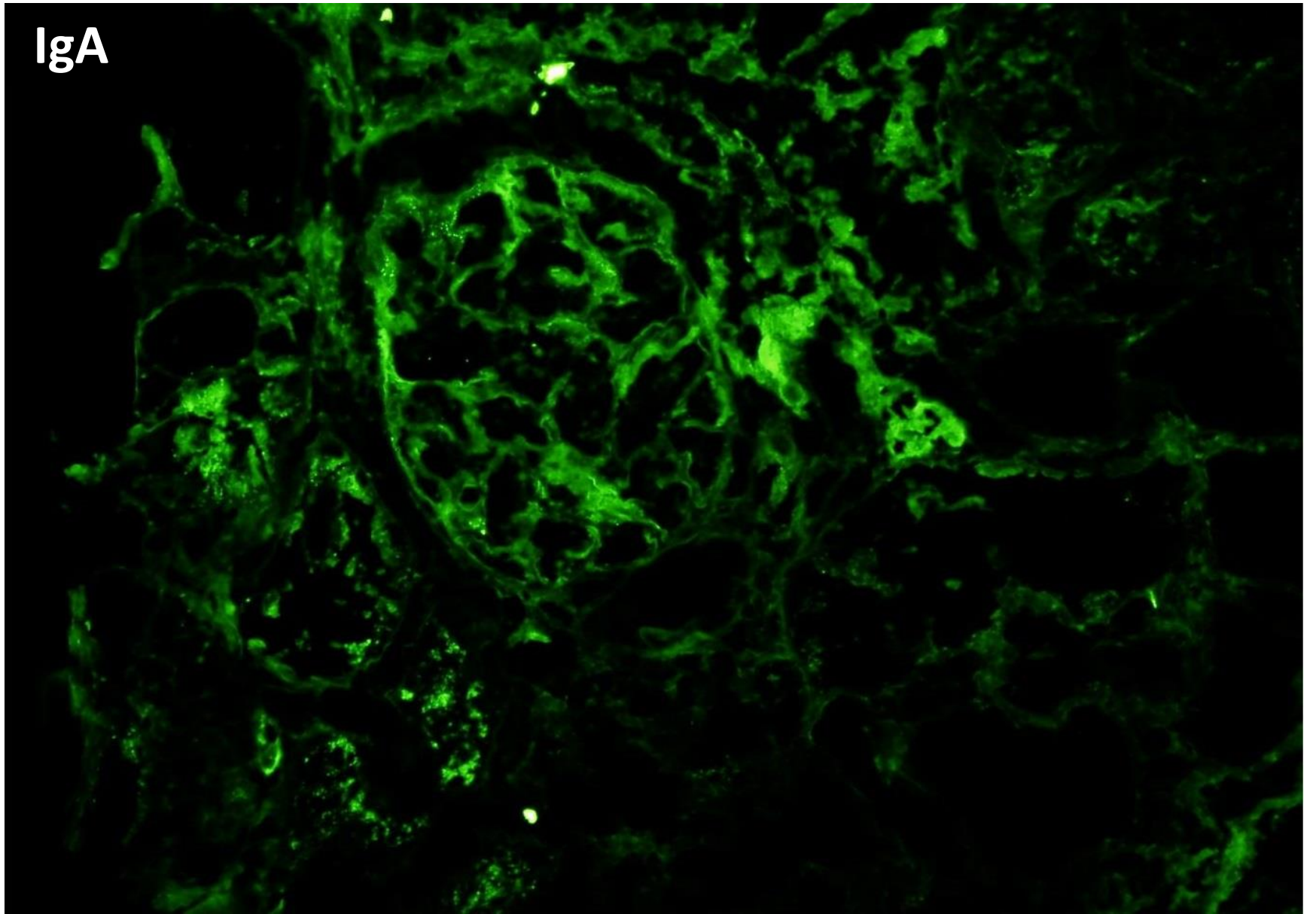


IgG

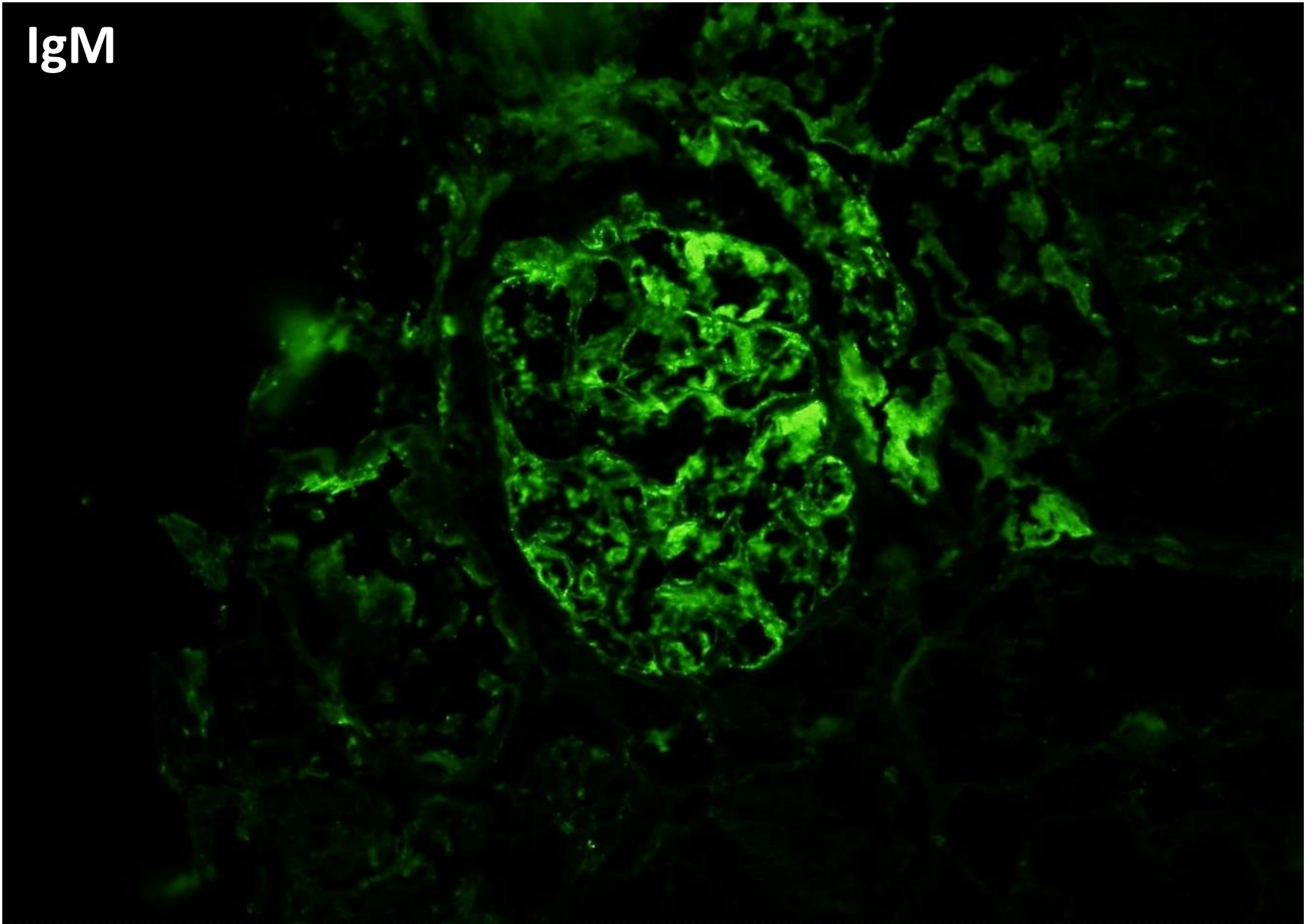




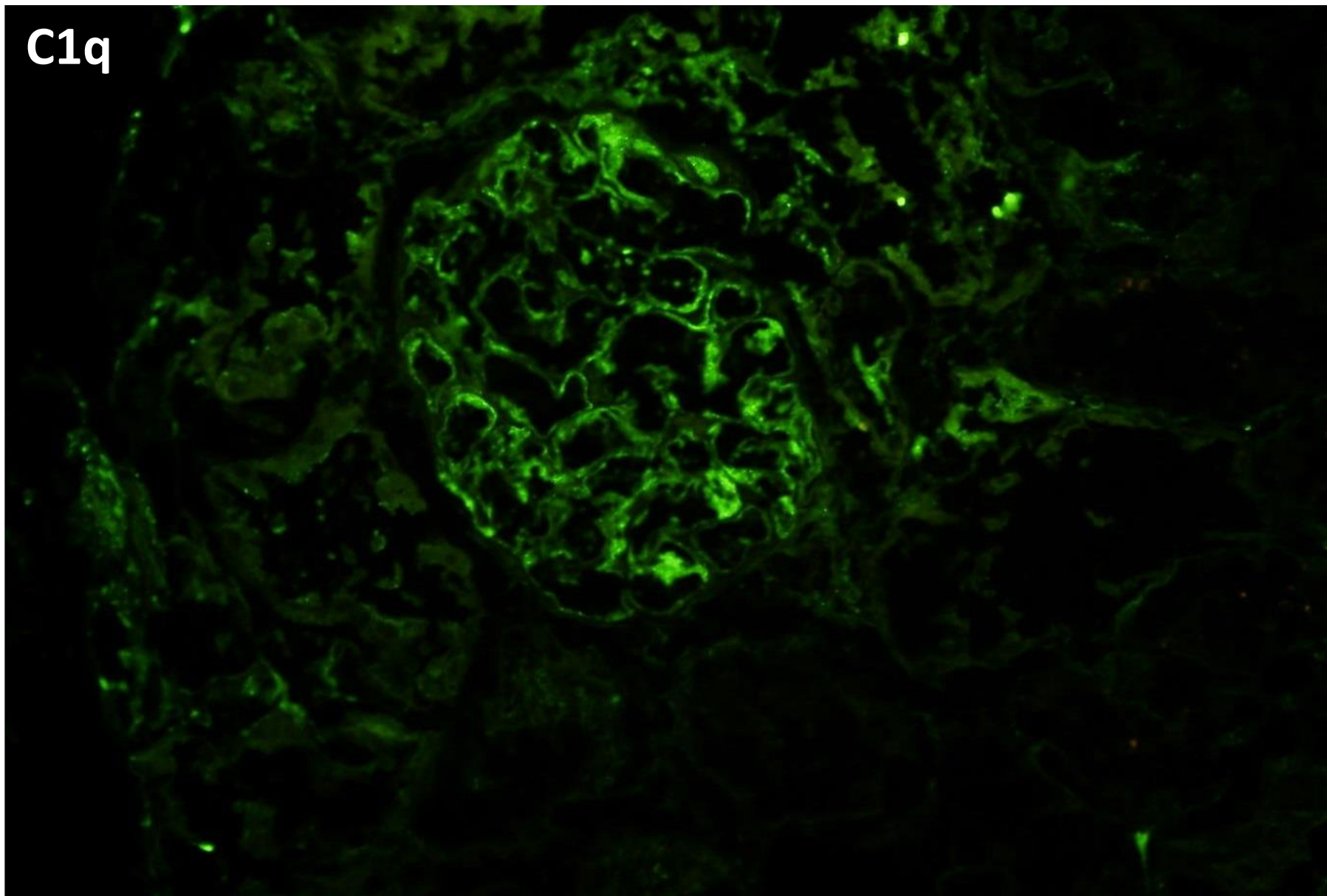
IgA



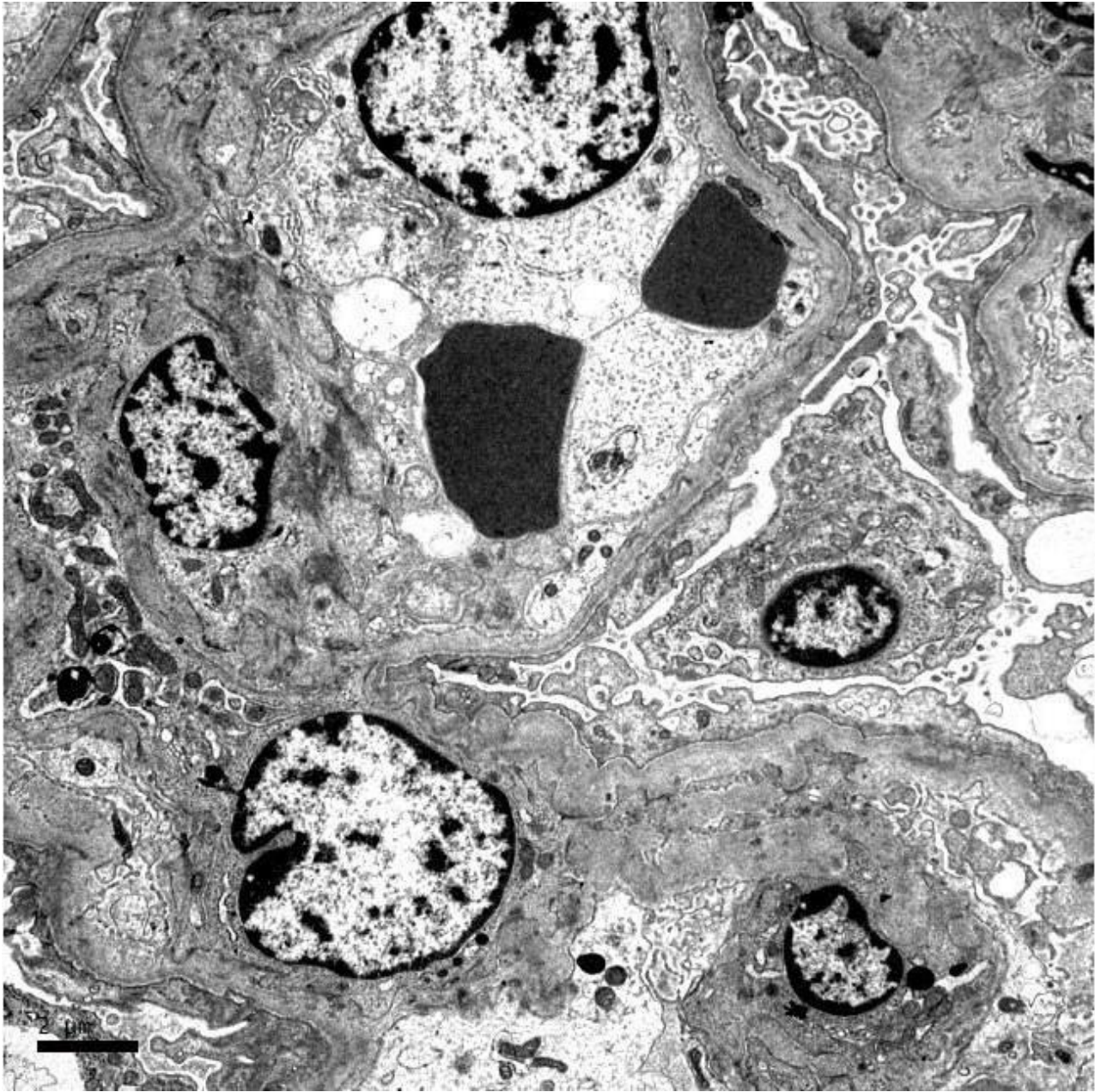
IgM

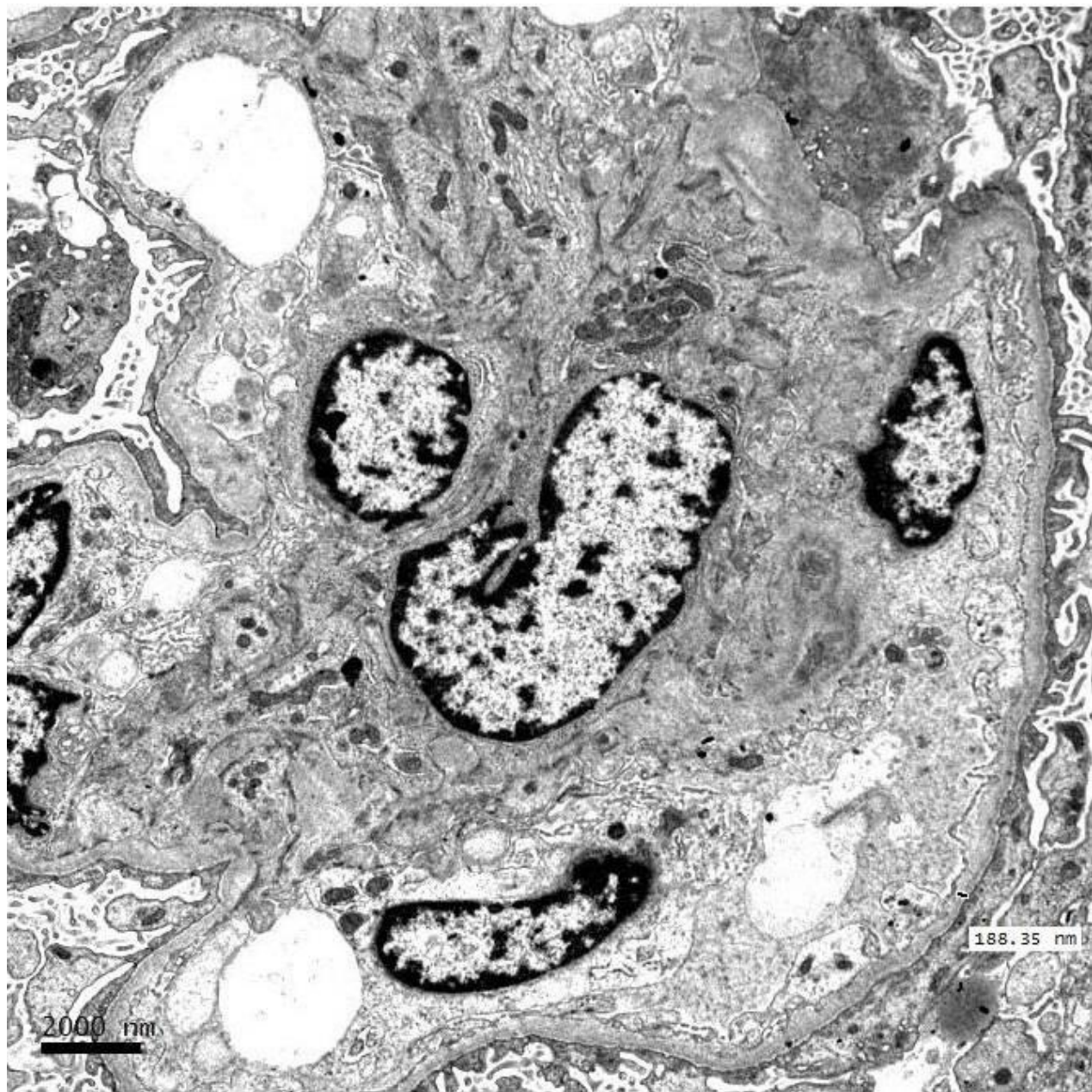


C1q

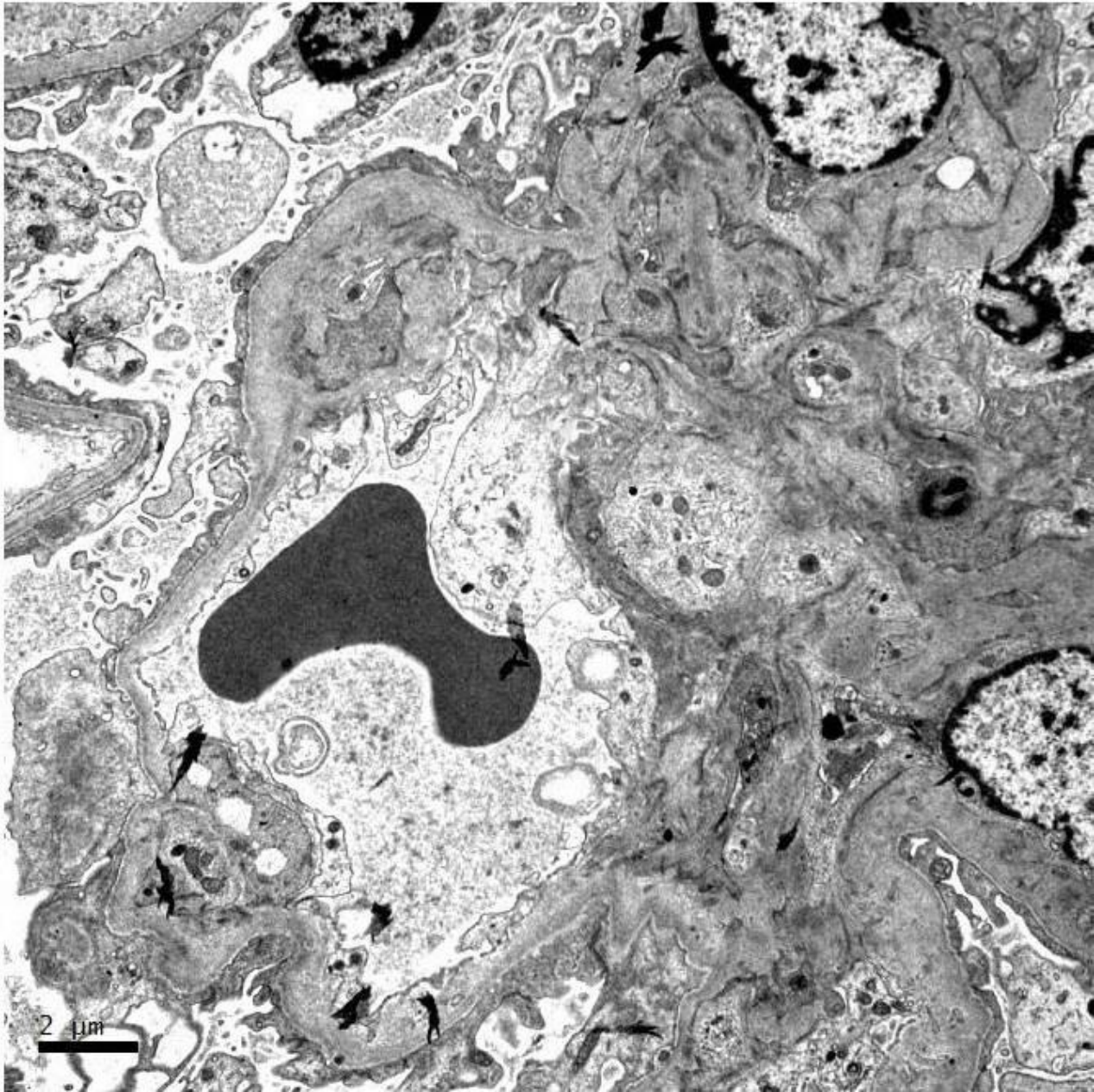


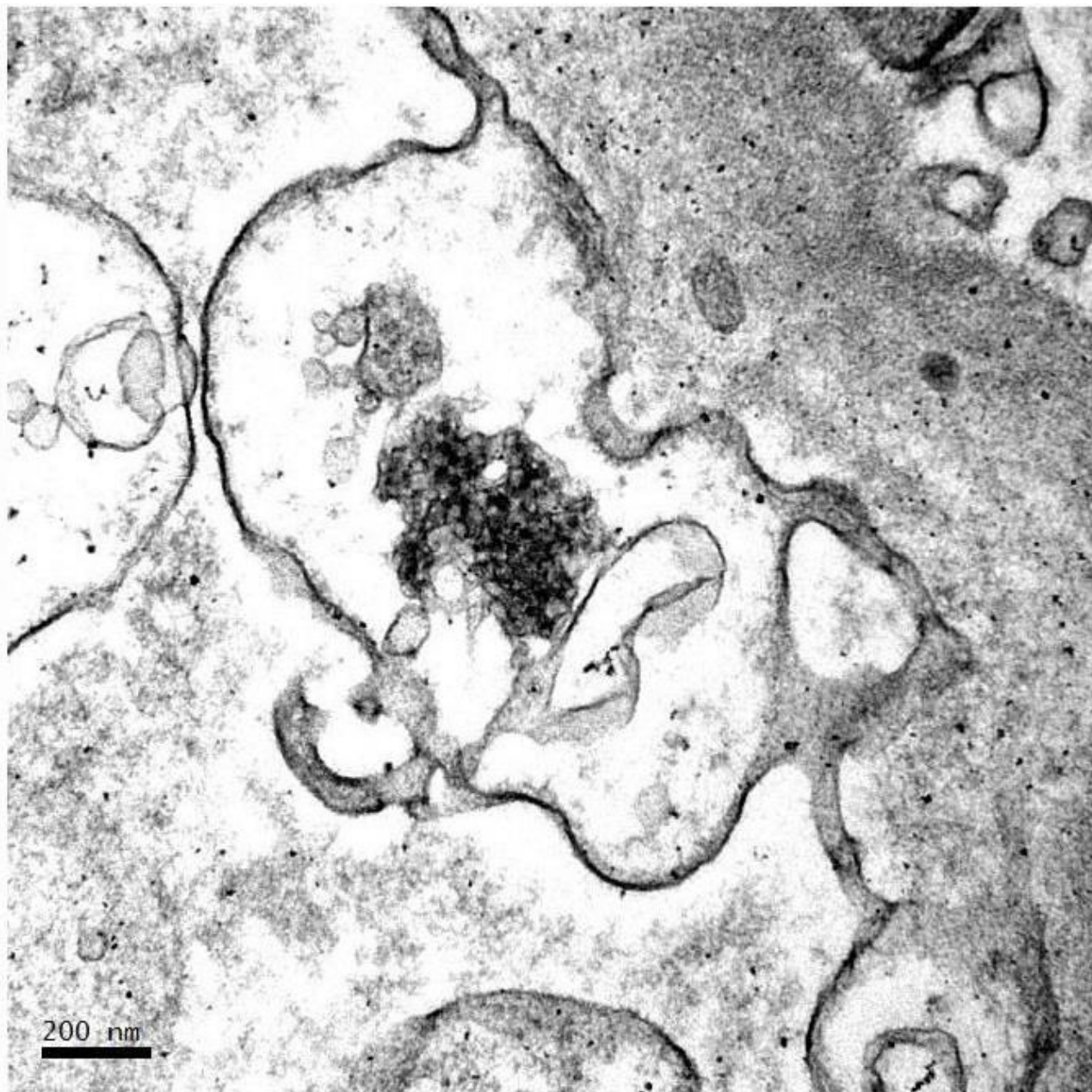
















# RENAL BIOPSY CLINICOPATHOLOGICAL WORKSHOP 2018



**PATHOLOGY**



Division of Pathology  
Singapore General Hospital



Department of Renal Medicine  
Singapore General Hospital



**MEDICINE**