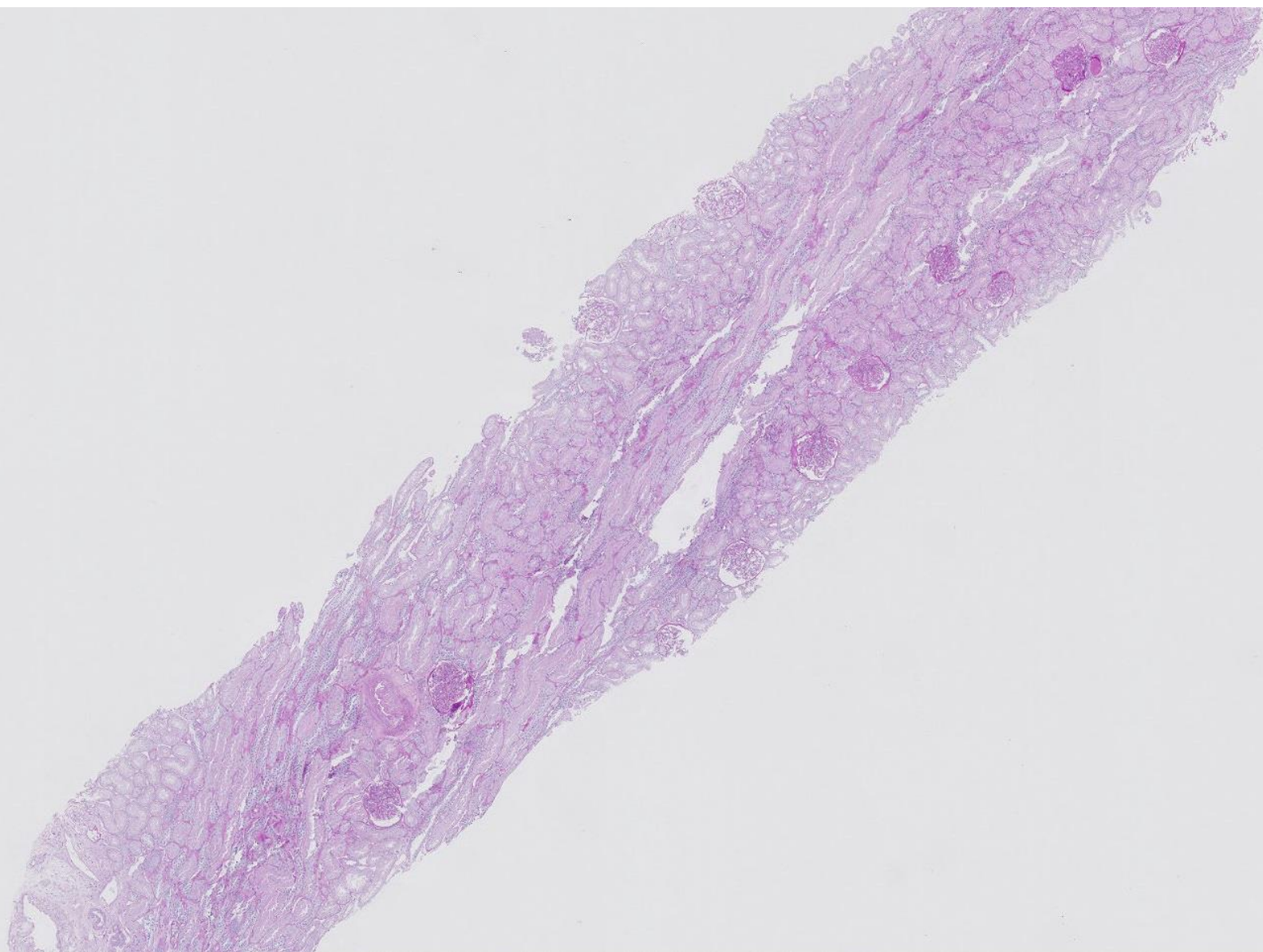


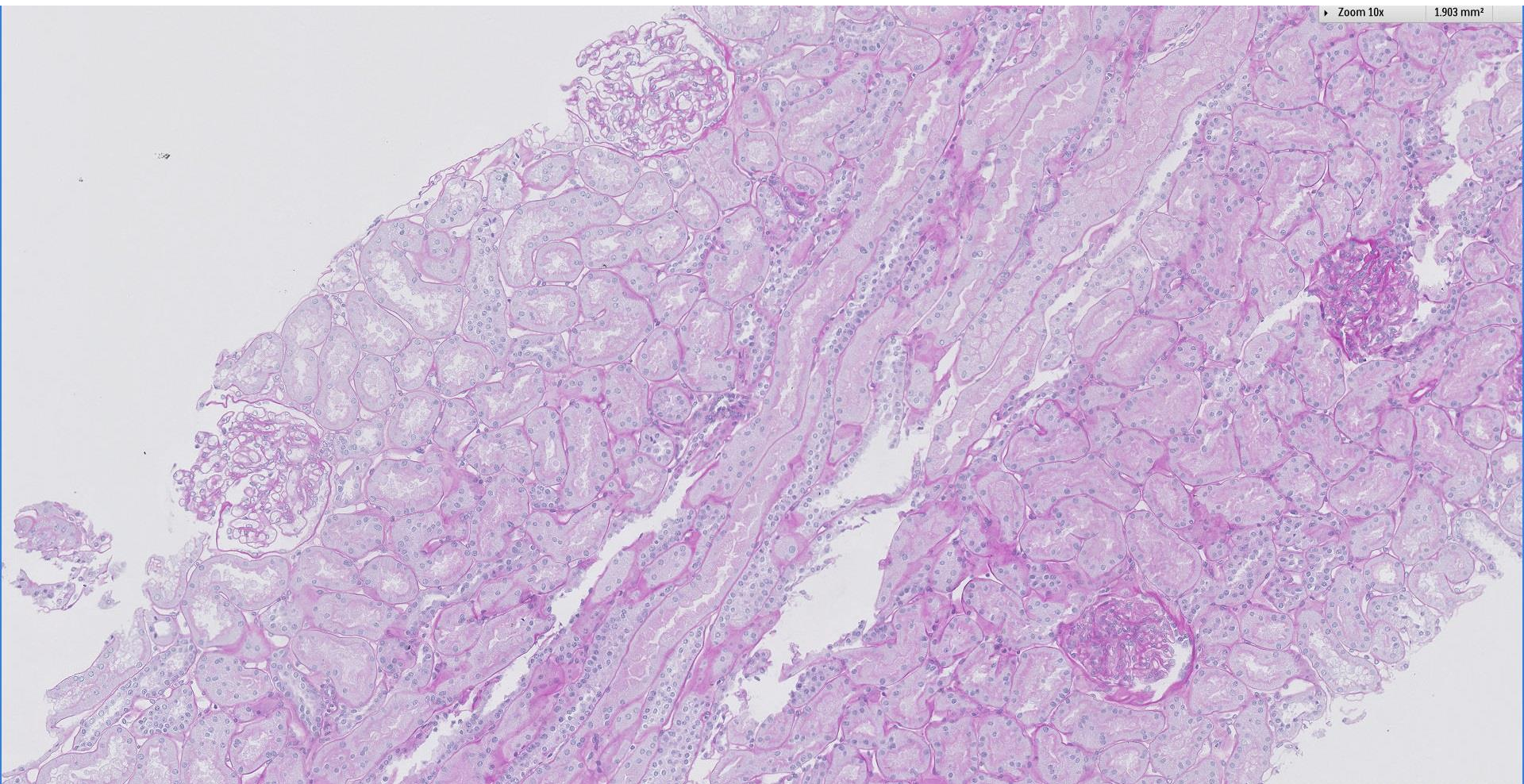
Case 1

35 year old female with anasarca, UPCR 15.9 and normal renal function.



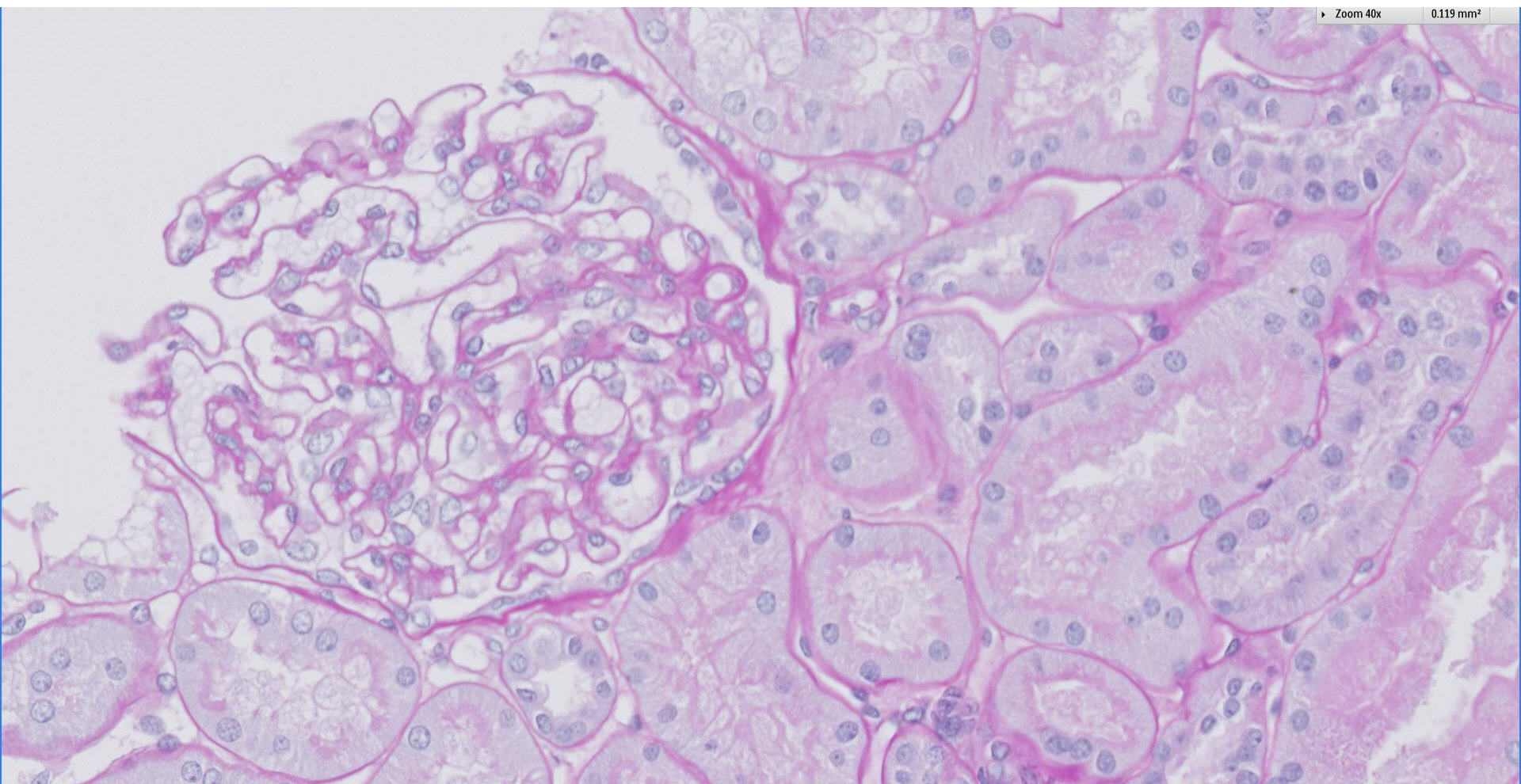
► Zoom 10x

1.903 mm²

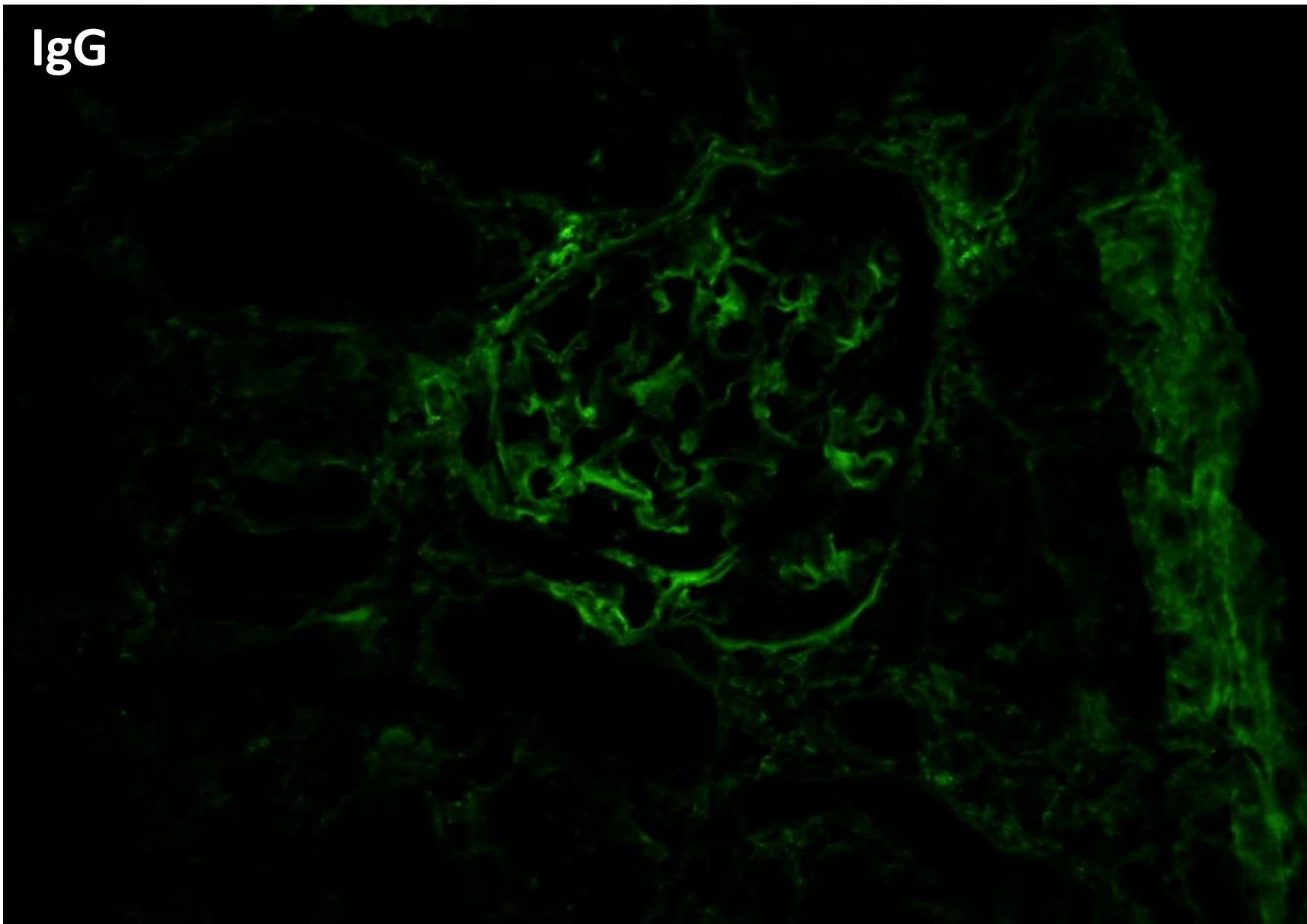


► Zoom 40x

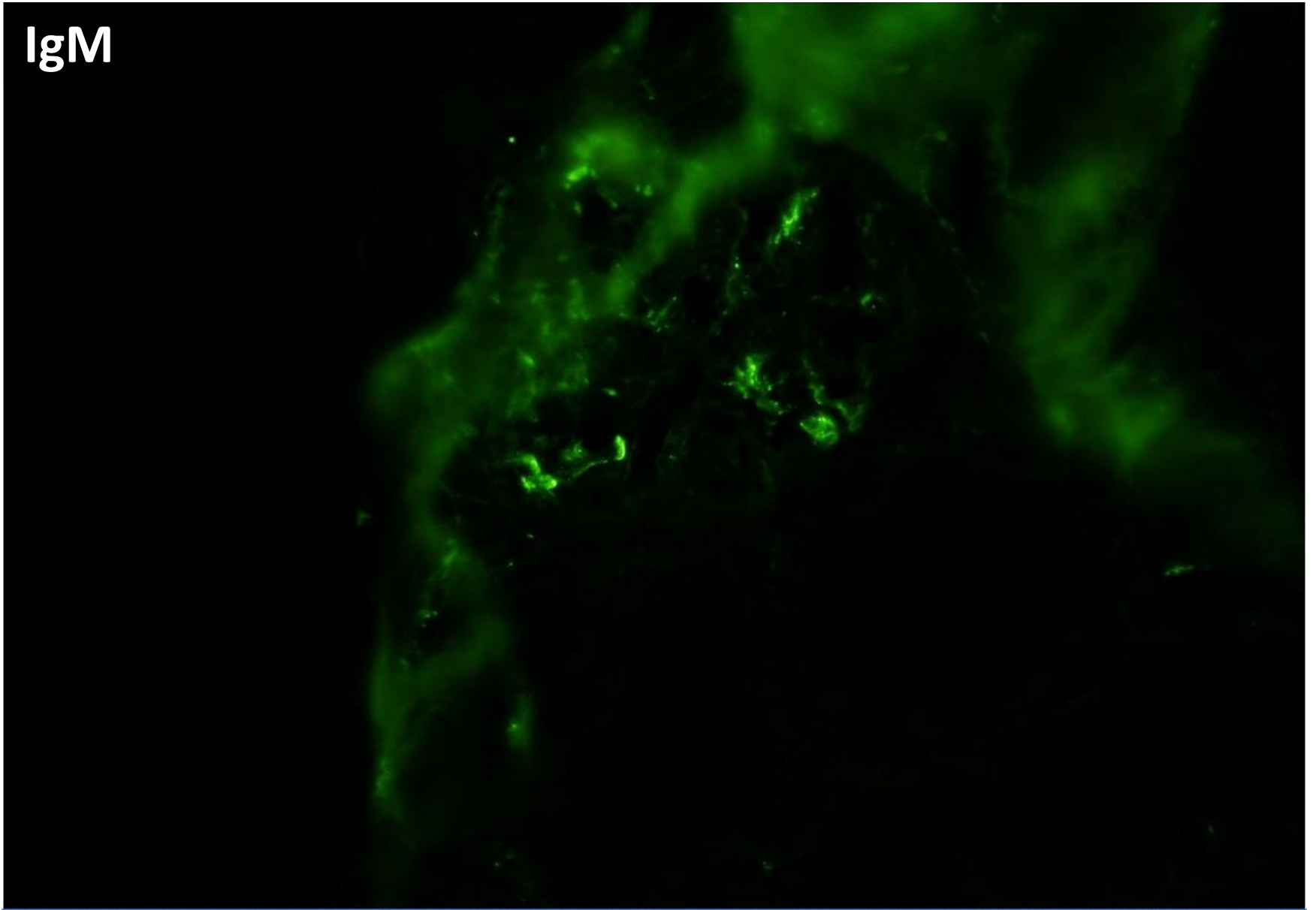
0.119 mm²



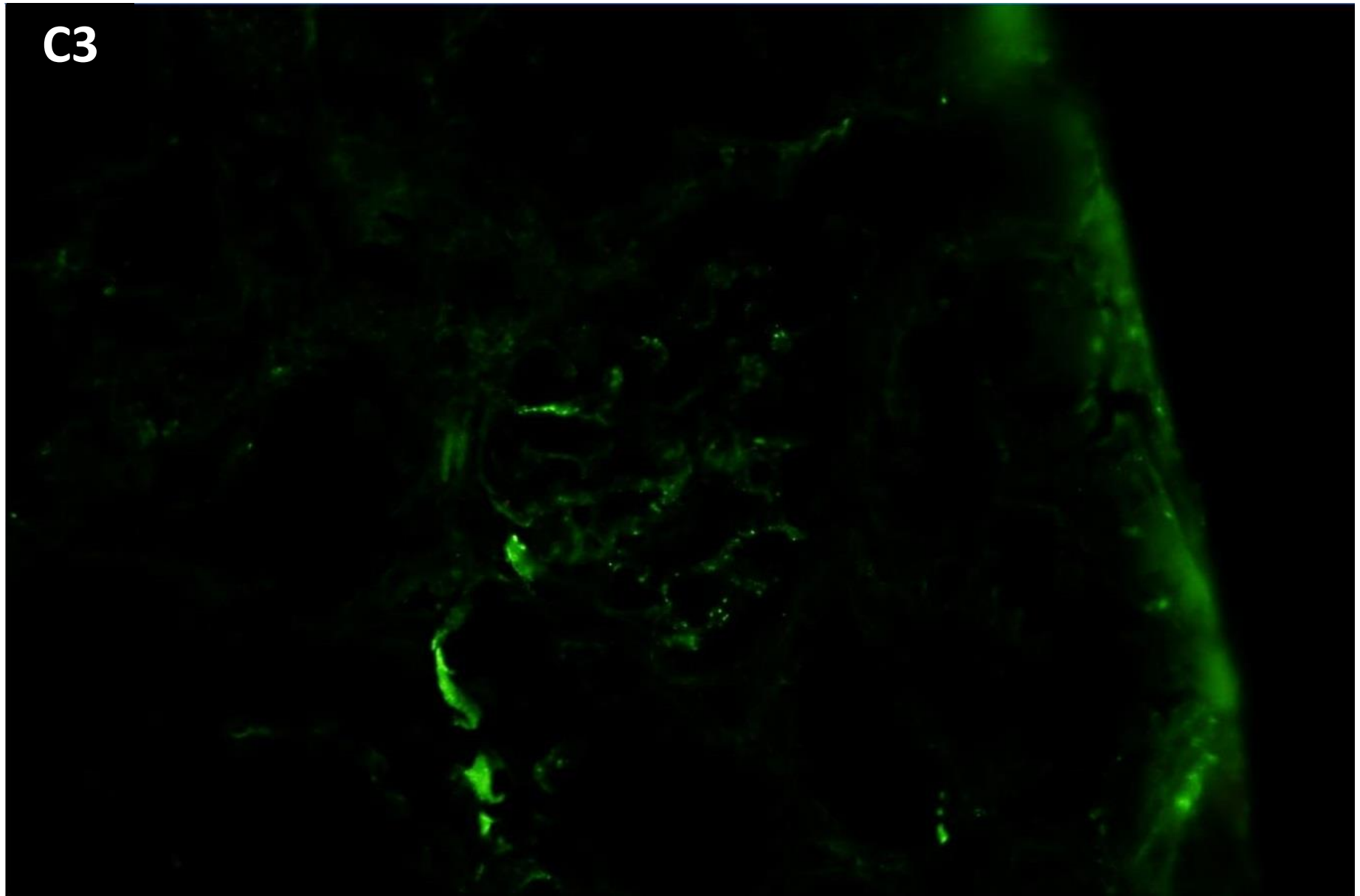
IgG

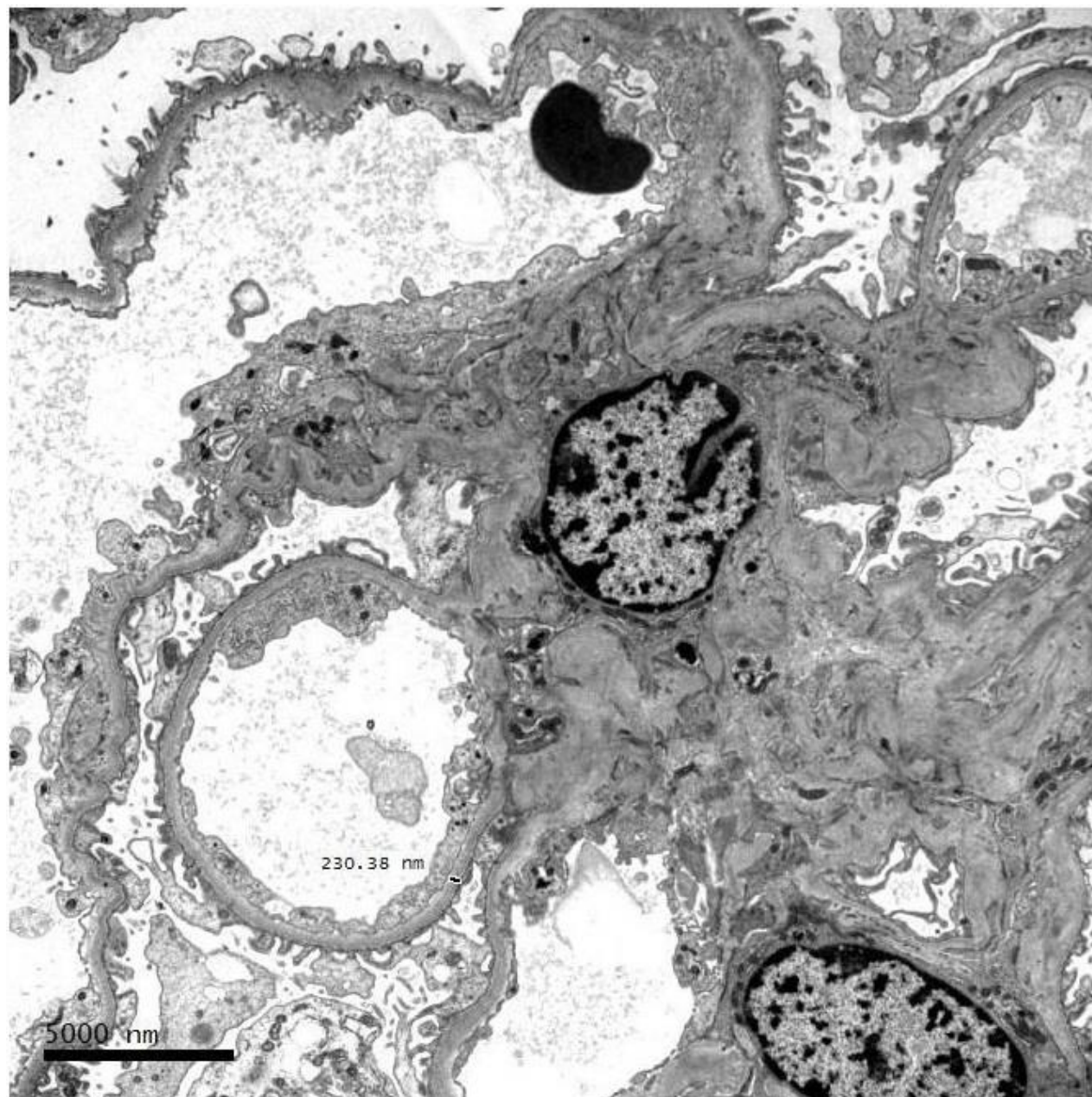


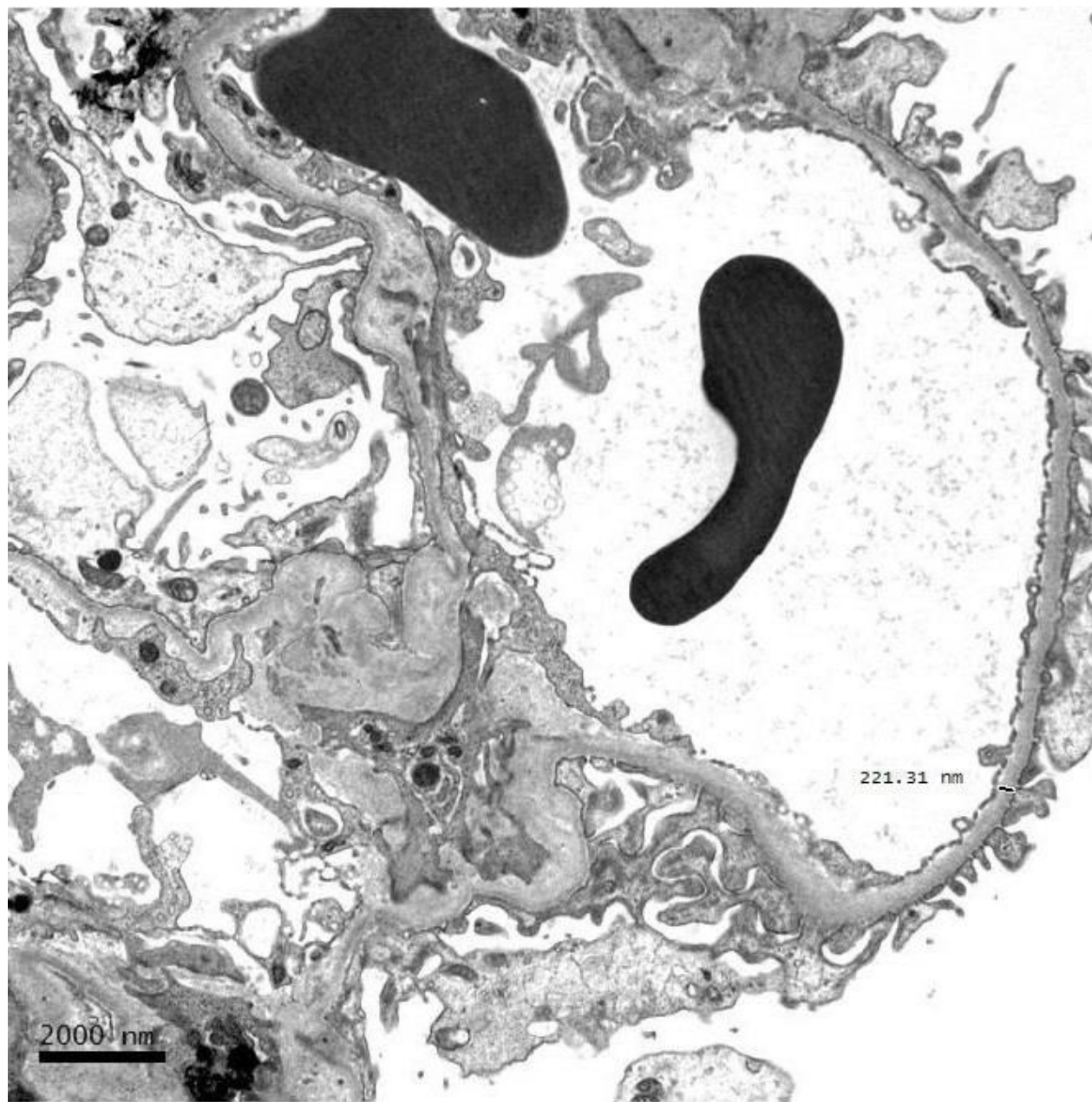
IgM

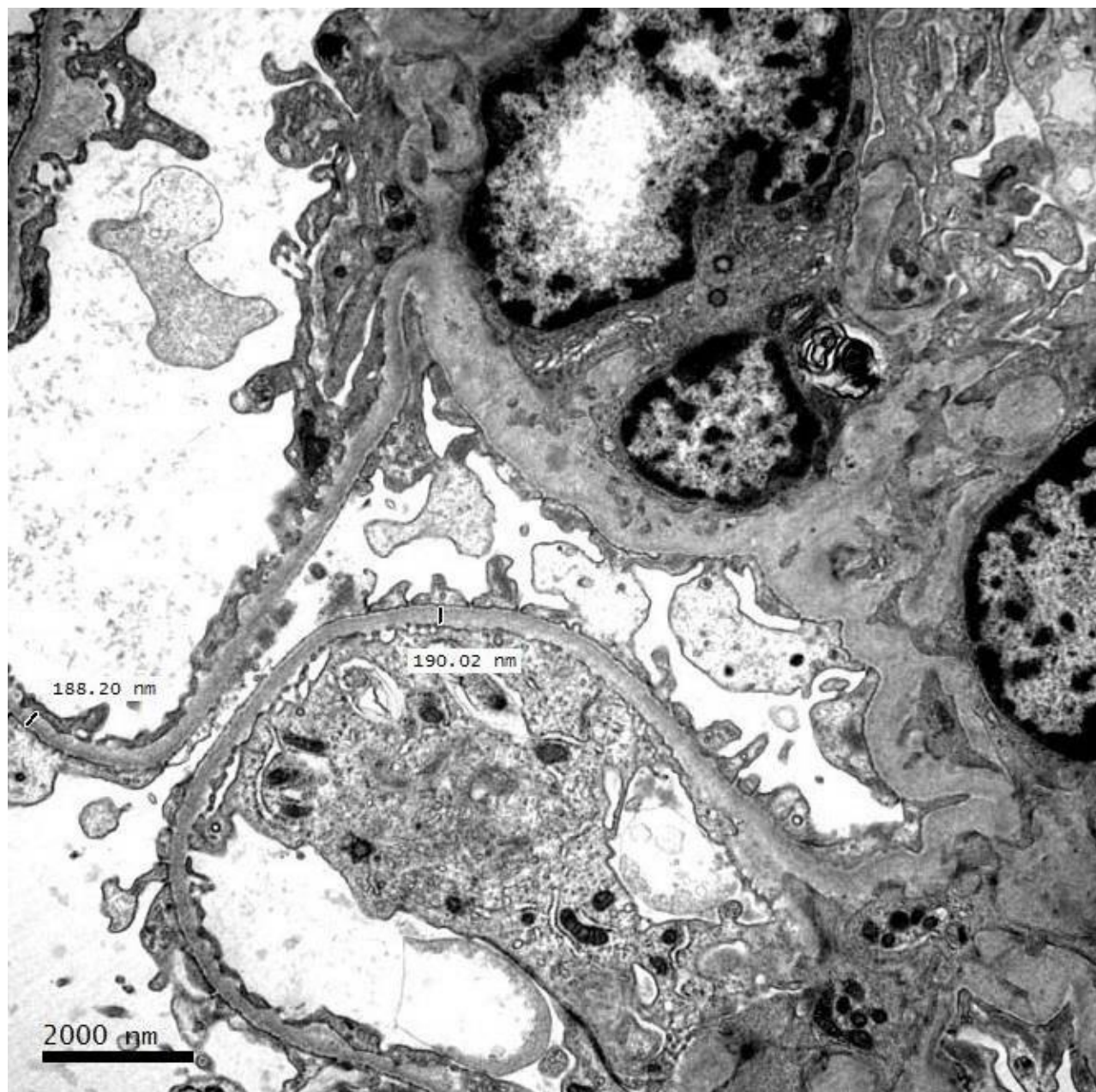


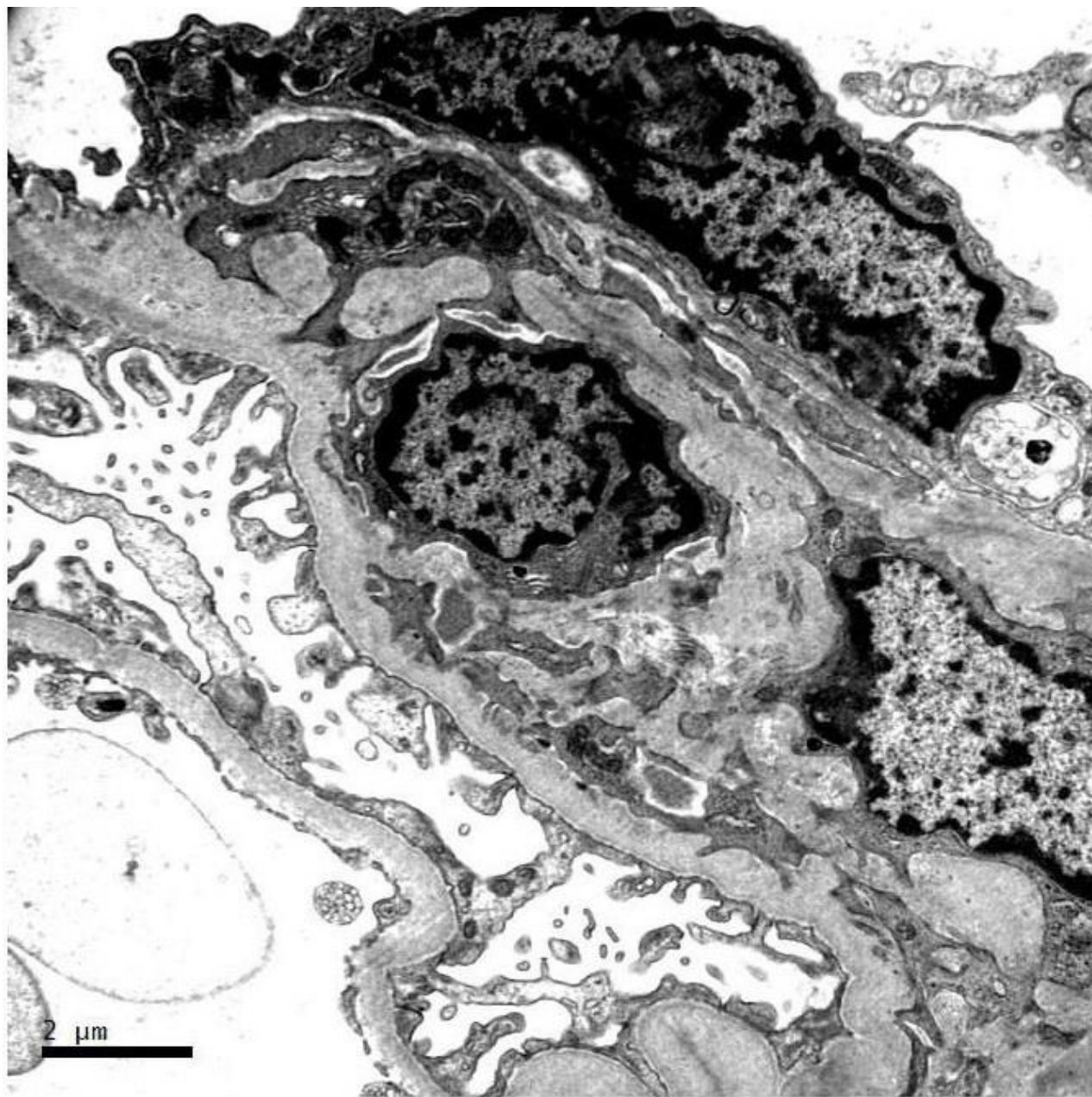
C3













RENAL BIOPSY CLINICOPATHOLOGICAL WORKSHOP 2018

