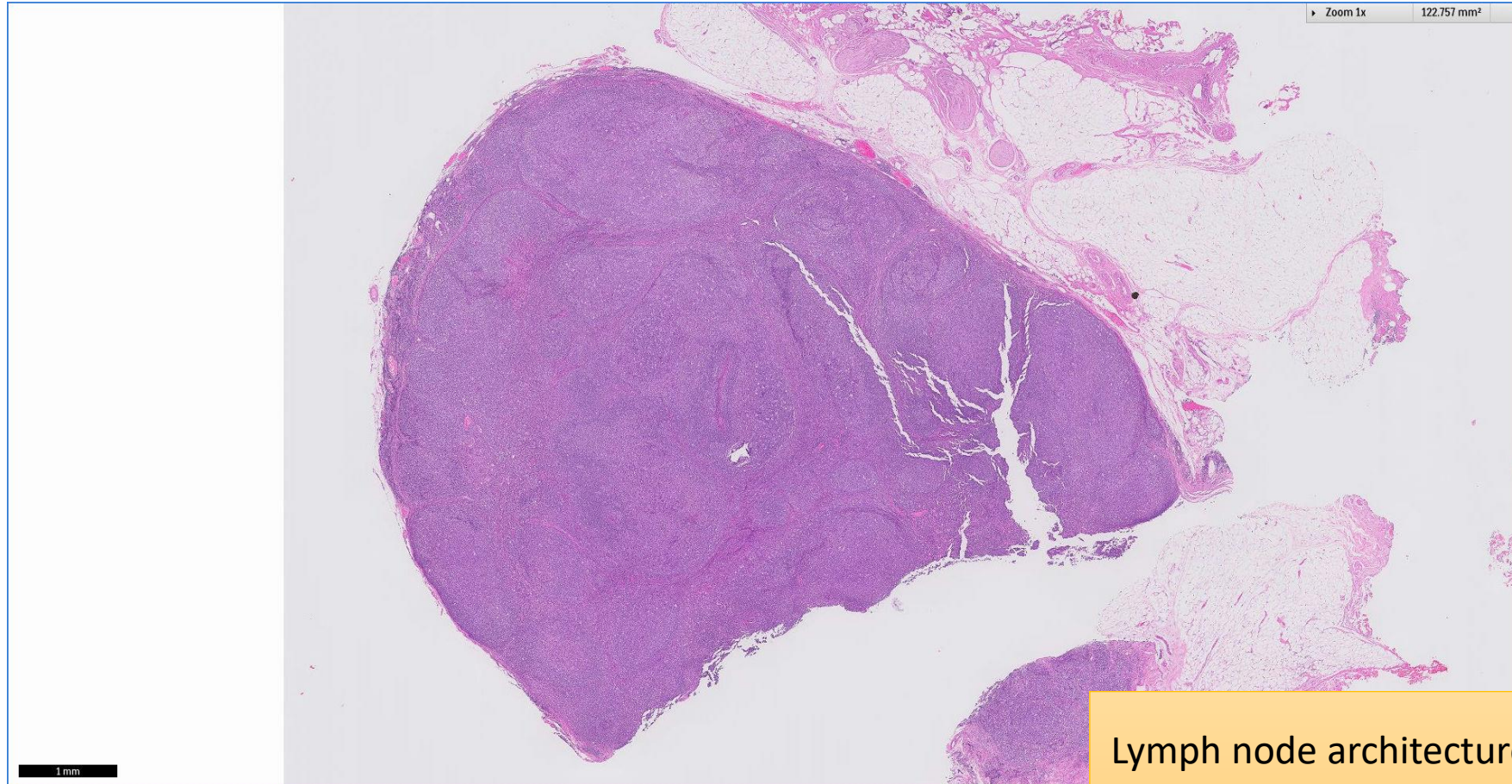


SGH CASE 42: 17RE167

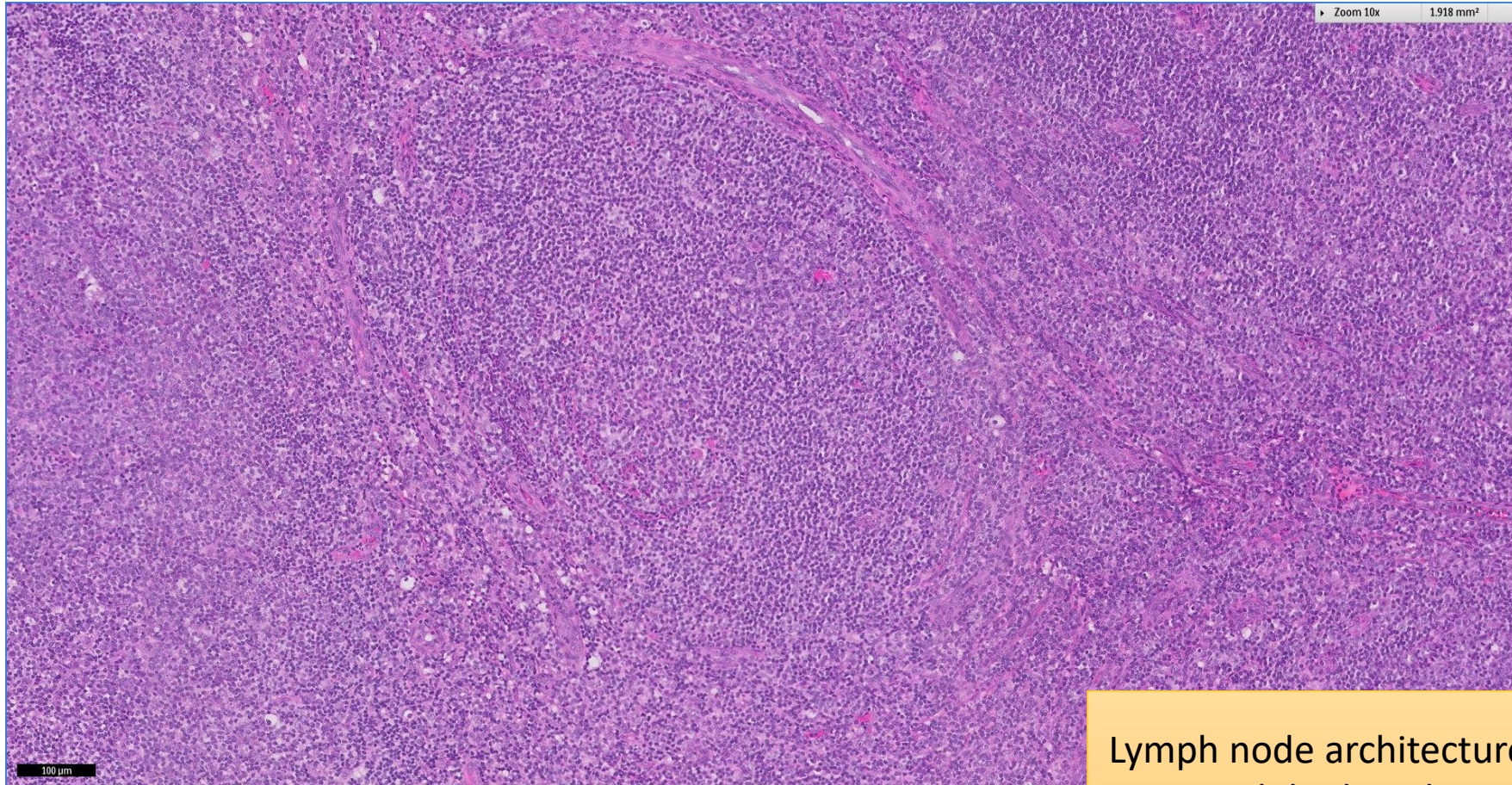
- Clinical History:
 - 80+ years old, Female. Cervical lymphadenopathy.
- Specimen:
 - Left cervical lymph node excision biopsy

SGH CASE 42: 17RE167 H&E



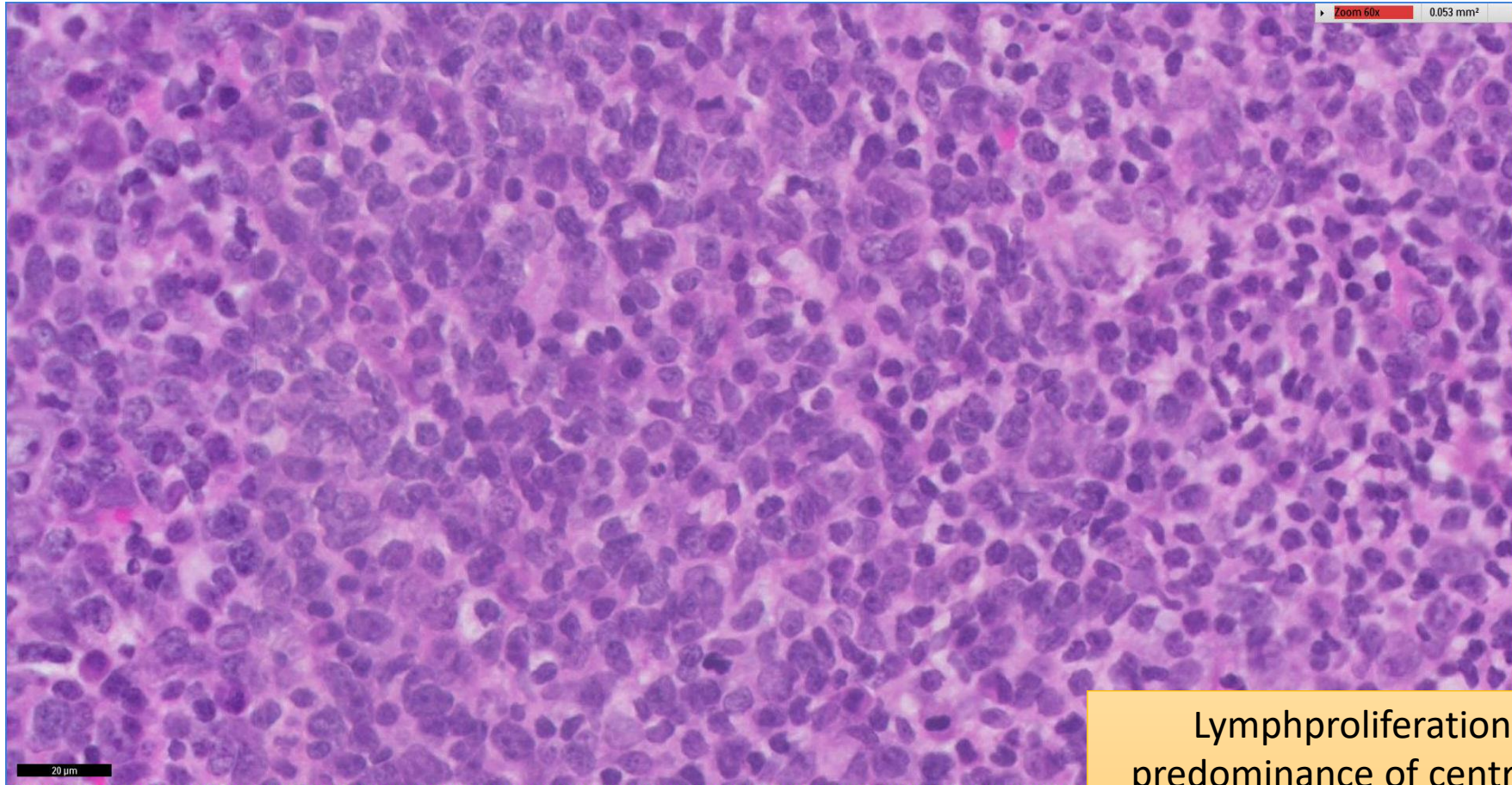
Lymph node architecture distorted by a nodular lymphoproliferation

SGH CASE 42: 17RE167 H&E



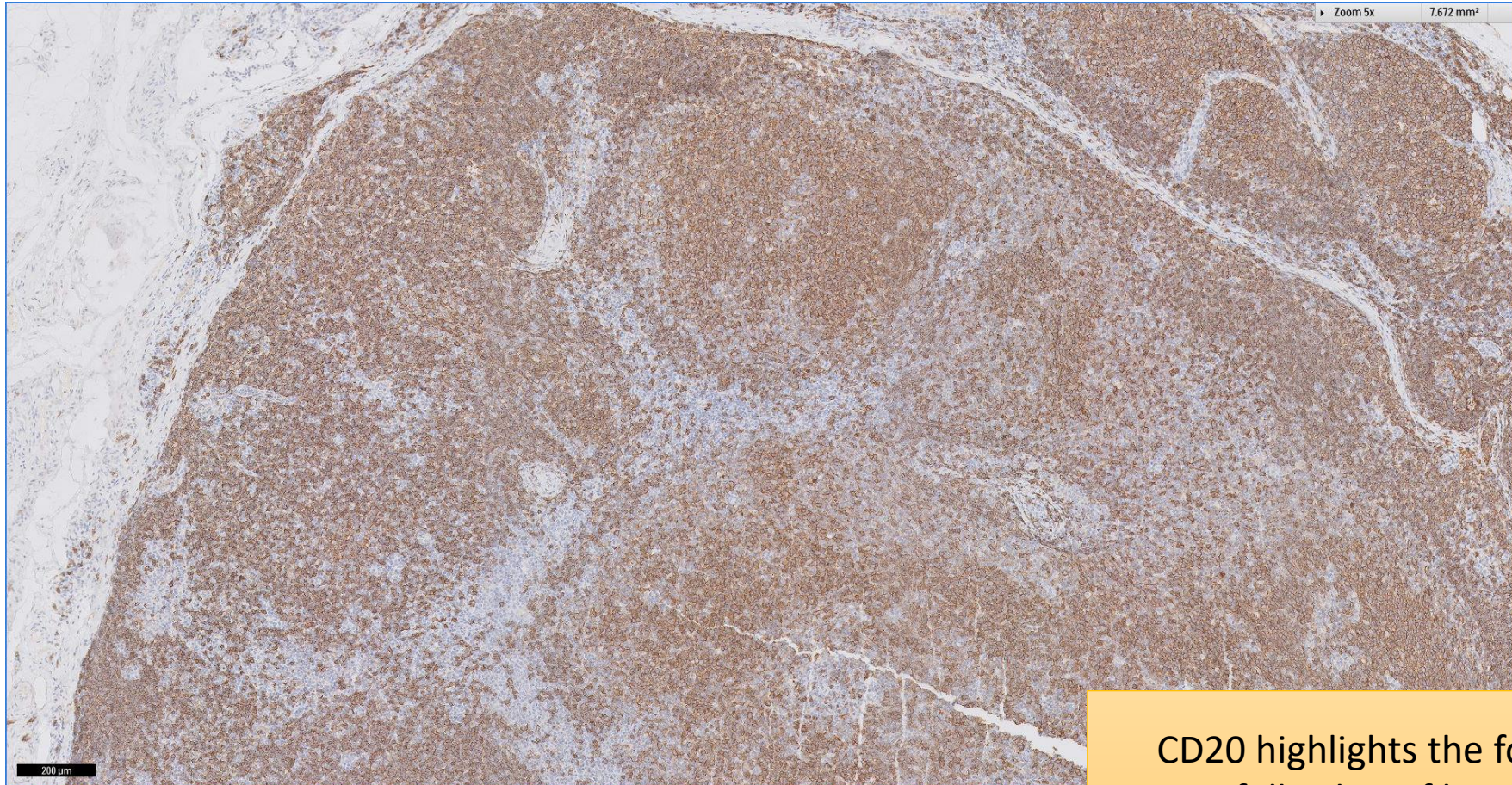
Lymph node architecture distorted by a nodular lymphoproliferation

SGH CASE 42: 17RE167 H&E



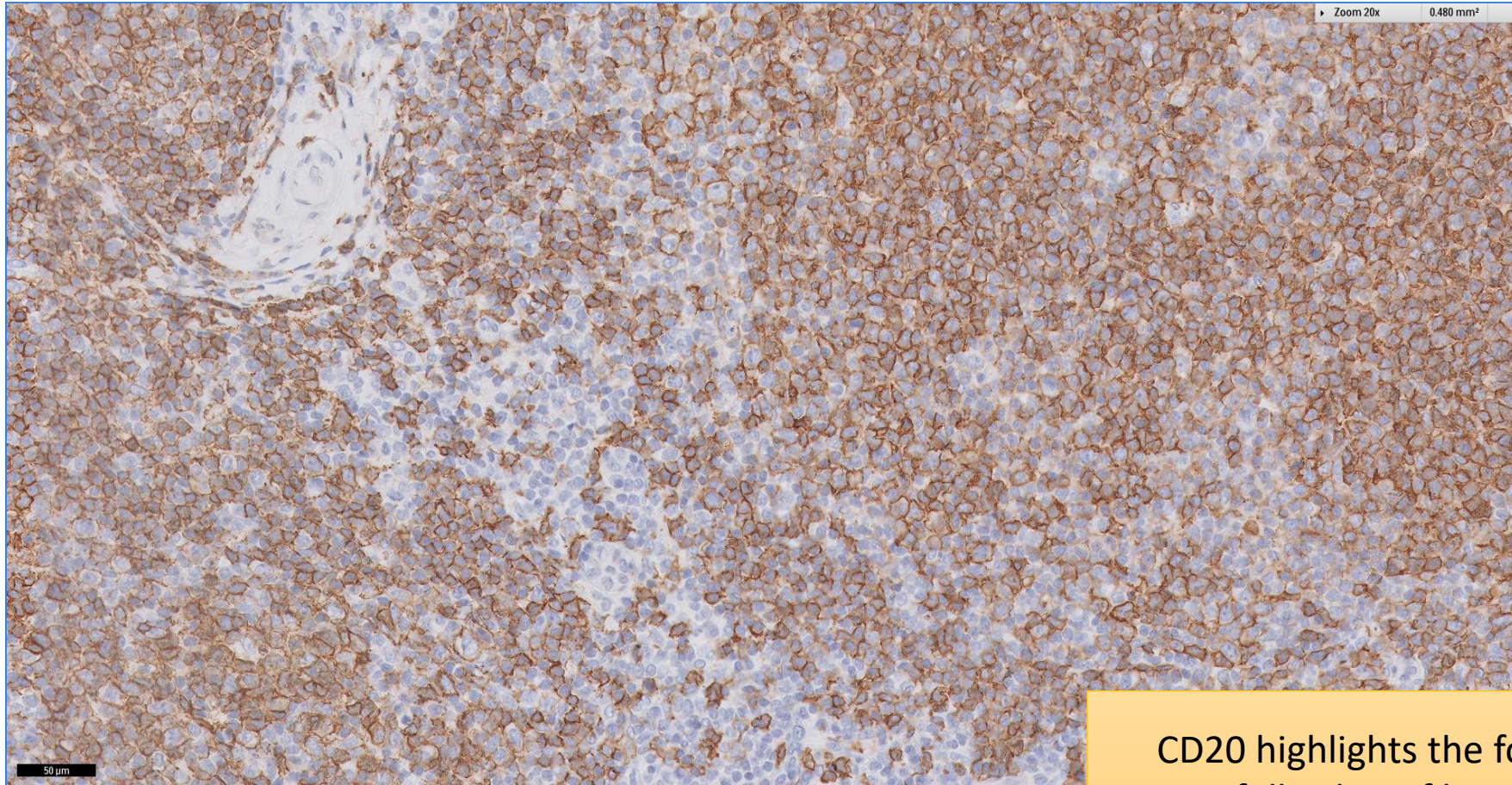
Lymphoproliferation shows a predominance of centroblasts over centrocytes in the follicle centres

SGH CASE 42: 17RE167 CD20



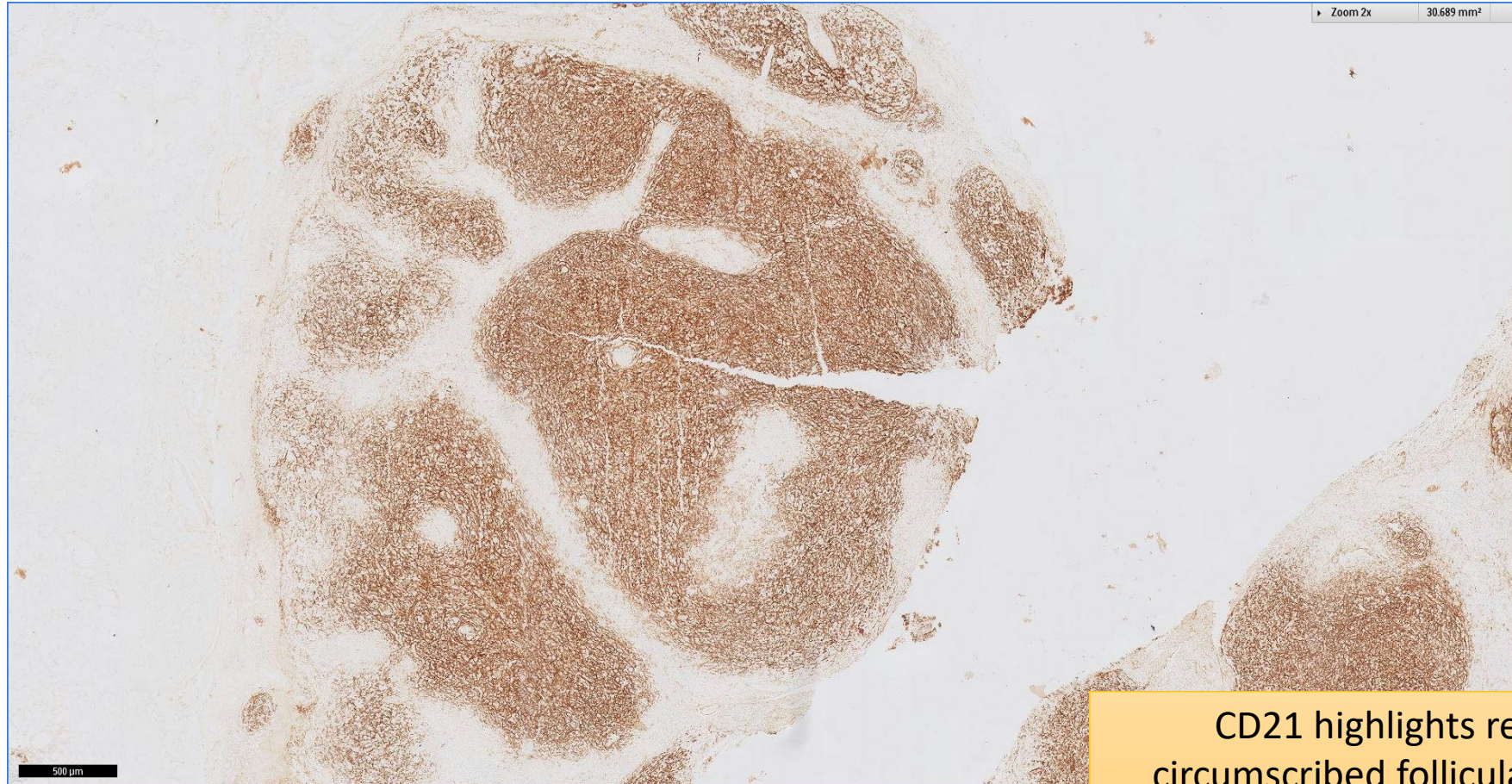
CD20 highlights the follicles and interfollicular infiltrate of B-cells

SGH CASE 42: 17RE167 CD20



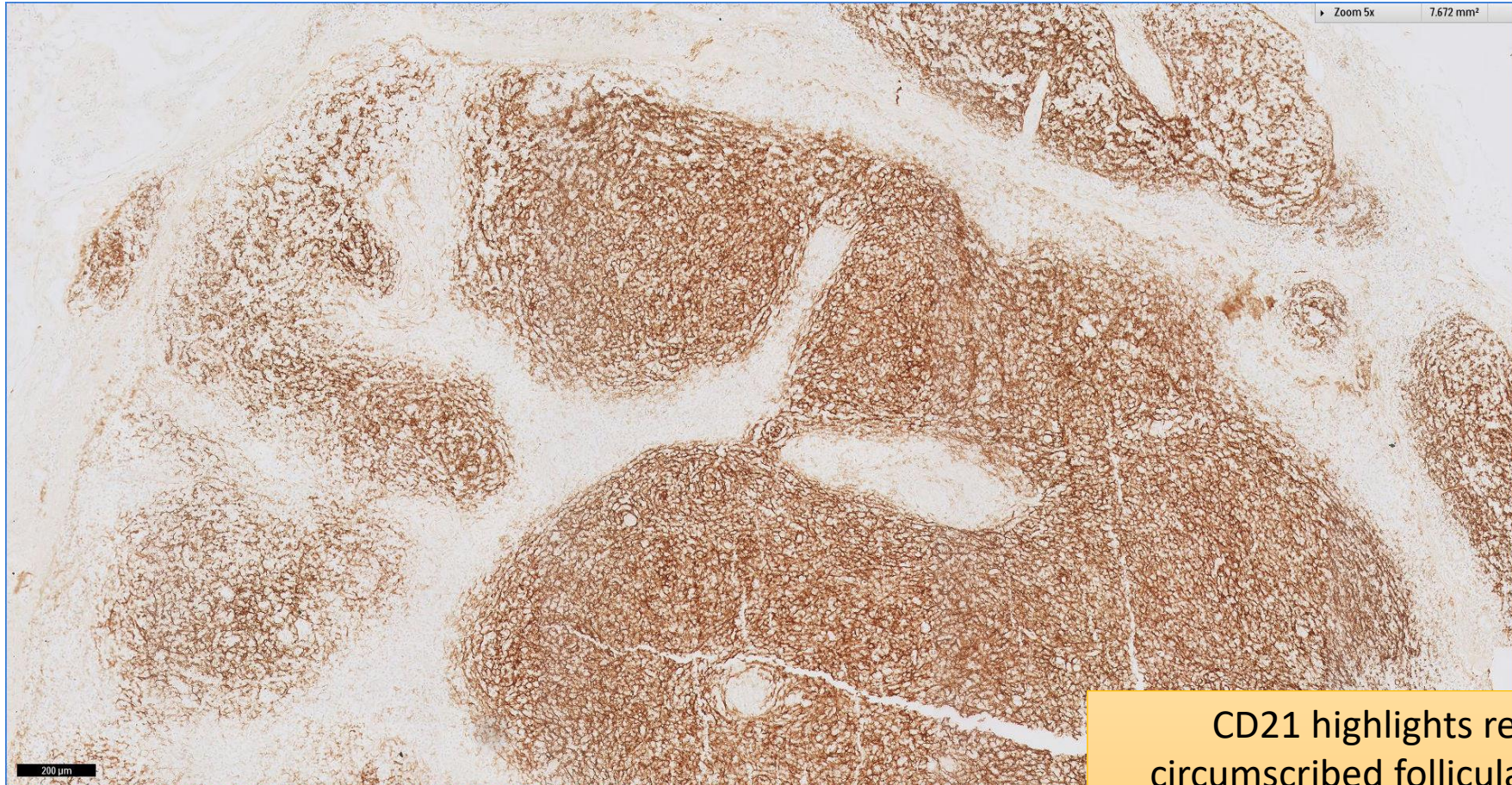
CD20 highlights the follicles and interfollicular infiltrate of B-cells

SGH CASE 42: 17RE167 CD21



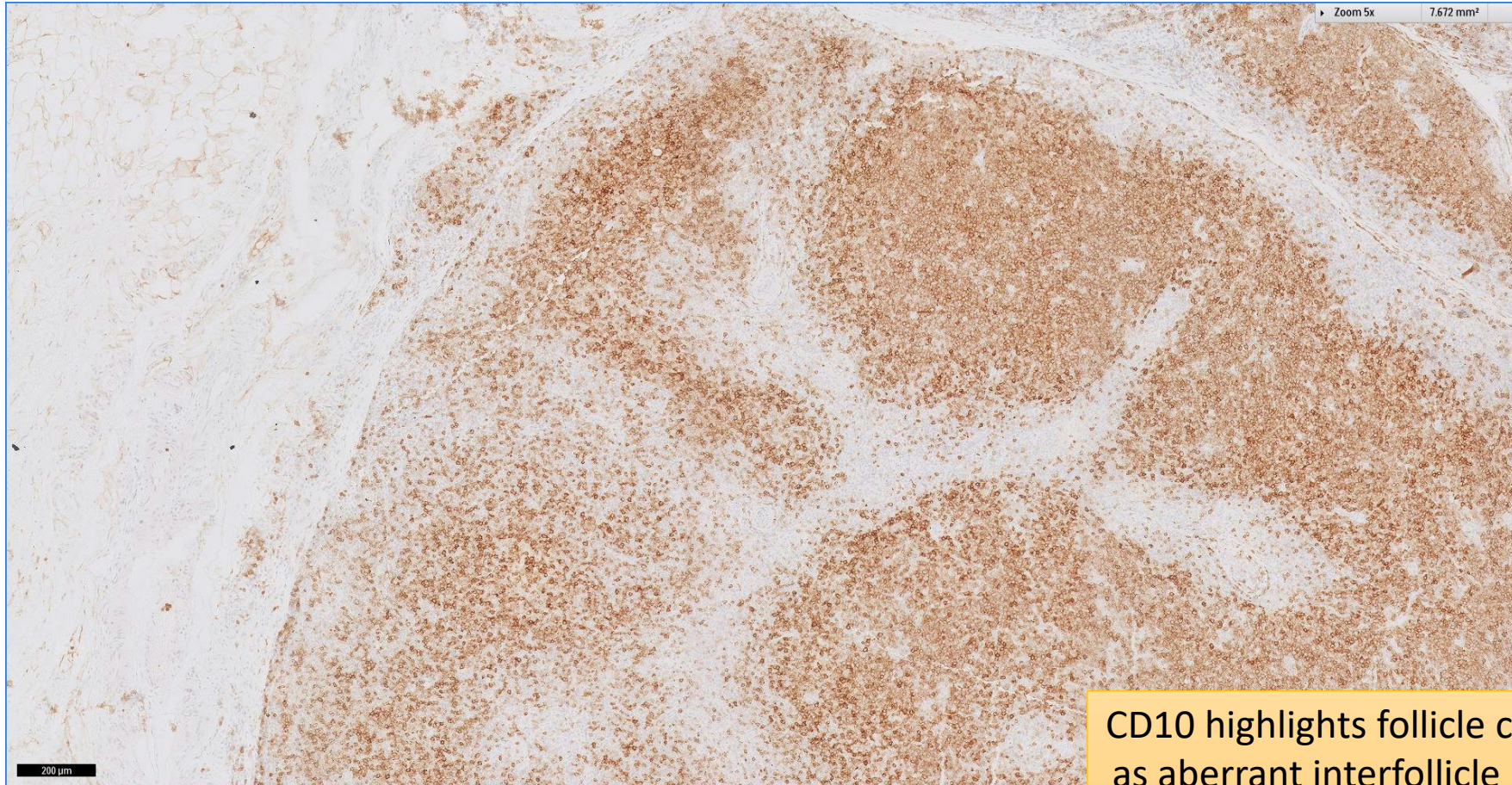
**CD21 highlights relatively
circumscribed follicular dendritic
meshworks**

SGH CASE 42: 17RE167 CD21



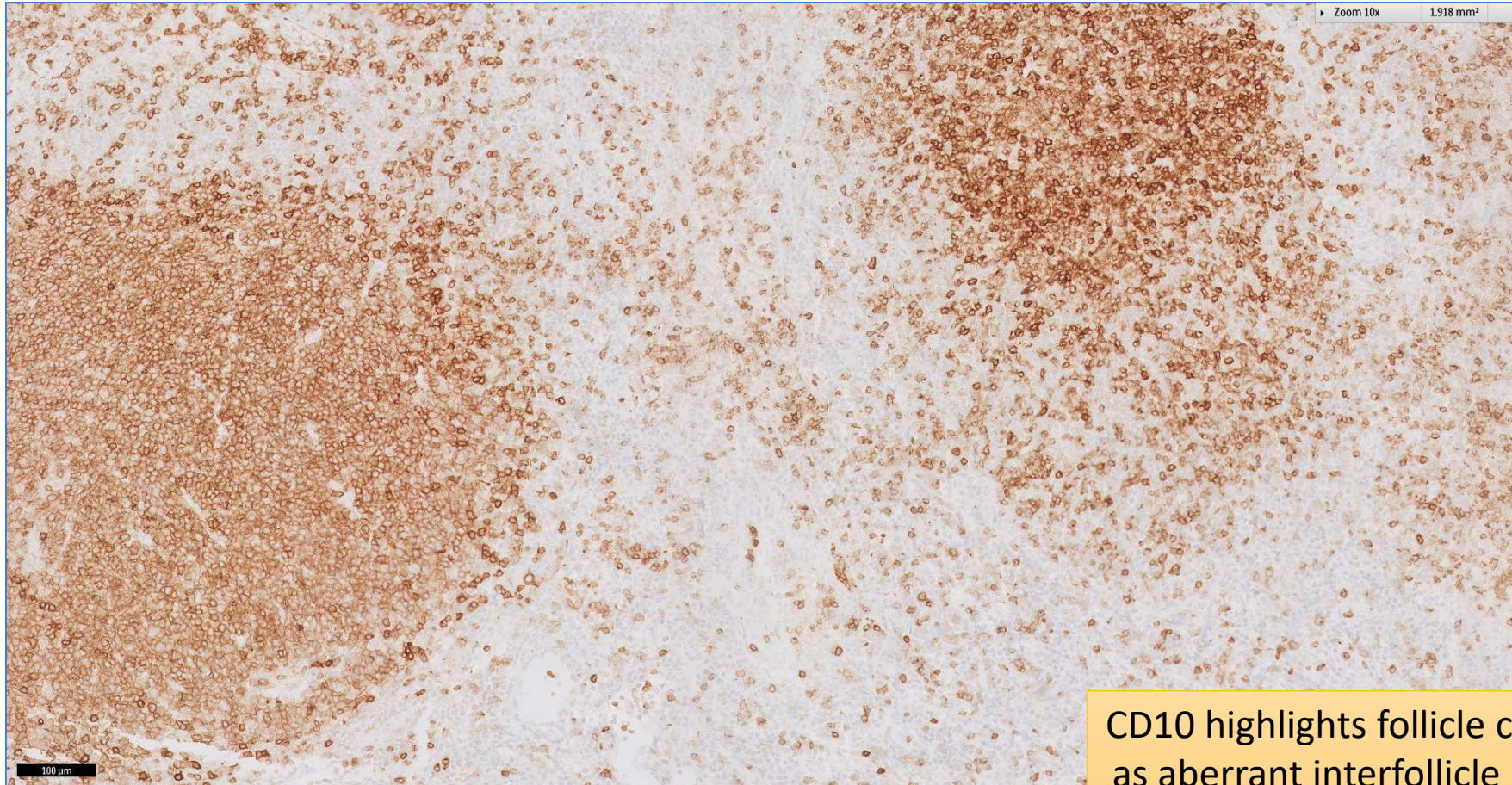
CD21 highlights relatively circumscribed follicular dendritic meshworks

SGH CASE 42: 17RE167 CD10



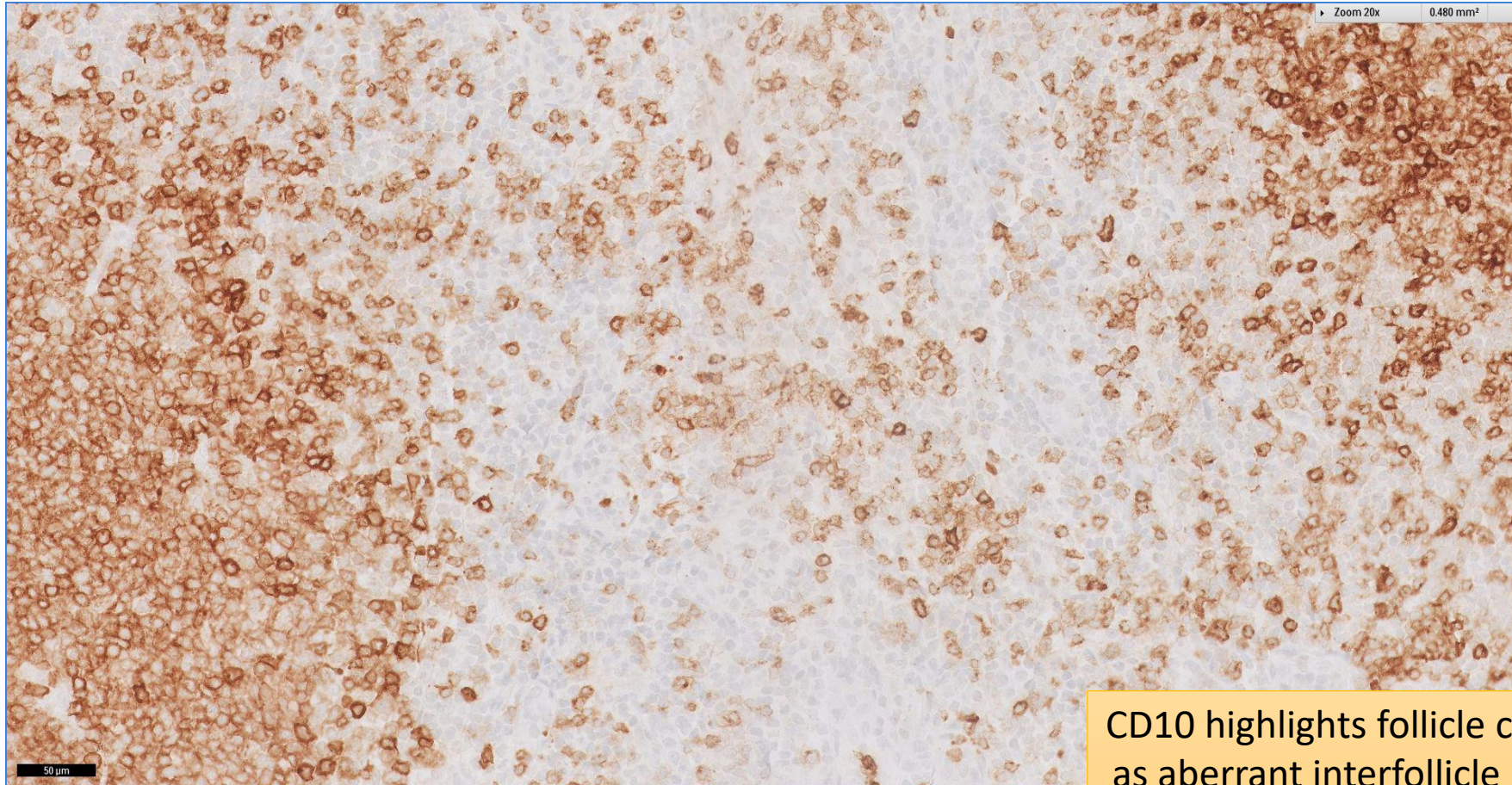
CD10 highlights follicle centres as well as aberrant interfollicle infiltration by CD10(+) lymphomatous cells

SGH CASE 42: 17RE167 CD10



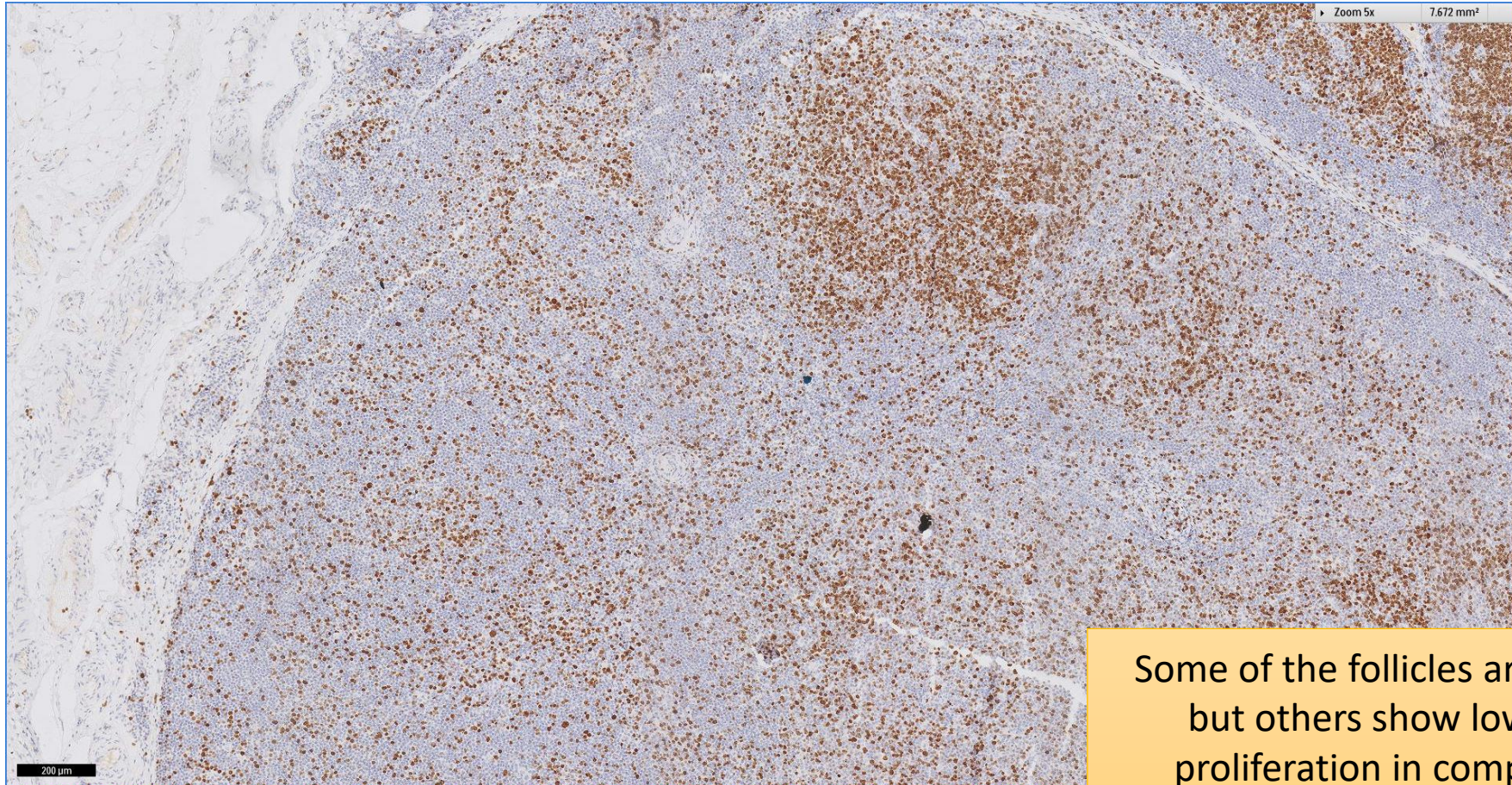
CD10 highlights follicle centres as well as aberrant interfollicle infiltration by CD10(+) lymphomatous cells

SGH CASE 42: 17RE167 CD10



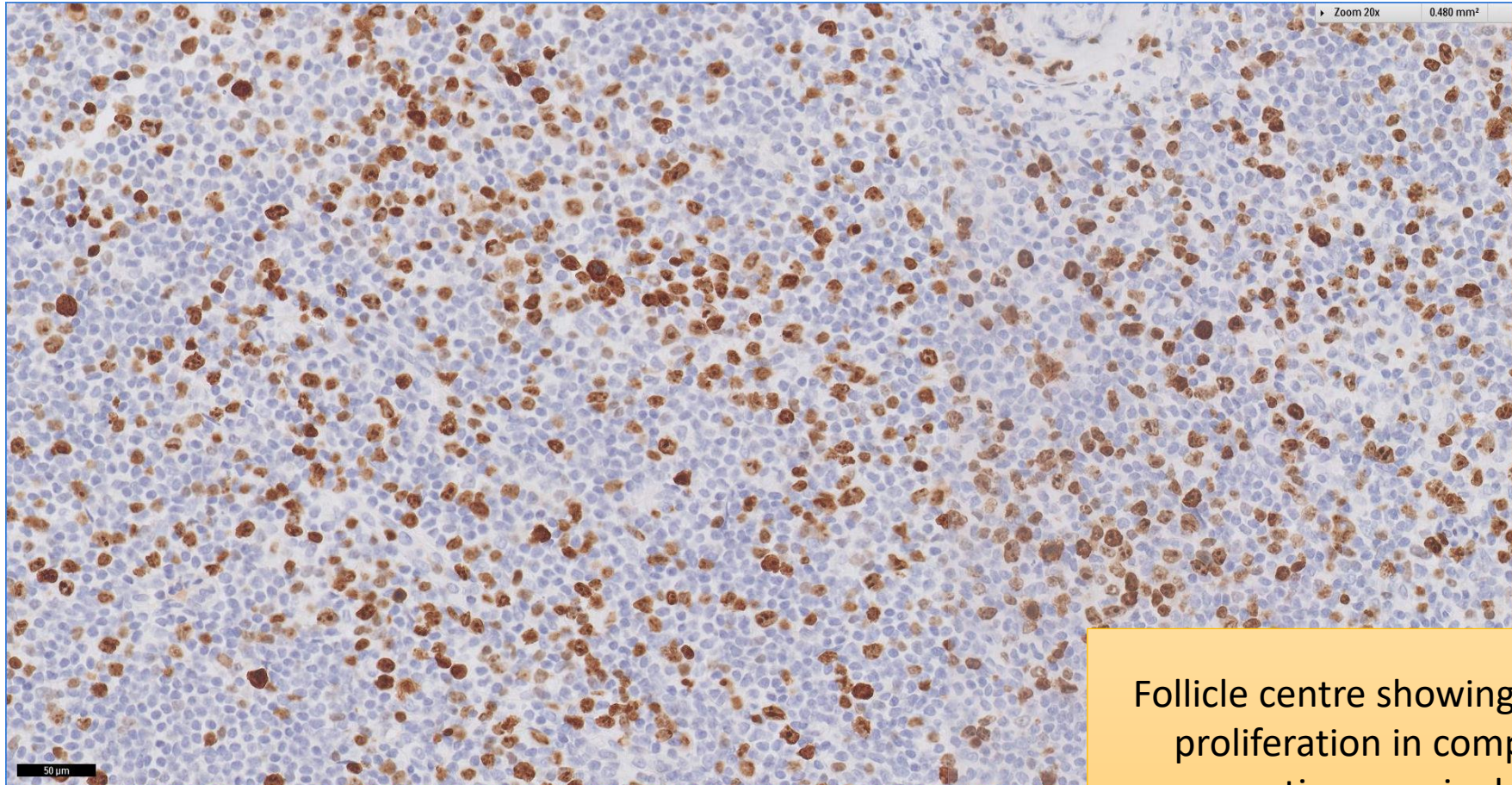
CD10 highlights follicle centres as well as aberrant interfollicle infiltration by CD10(+) lymphomatous cells

SGH CASE 42: 17RE167 KI67



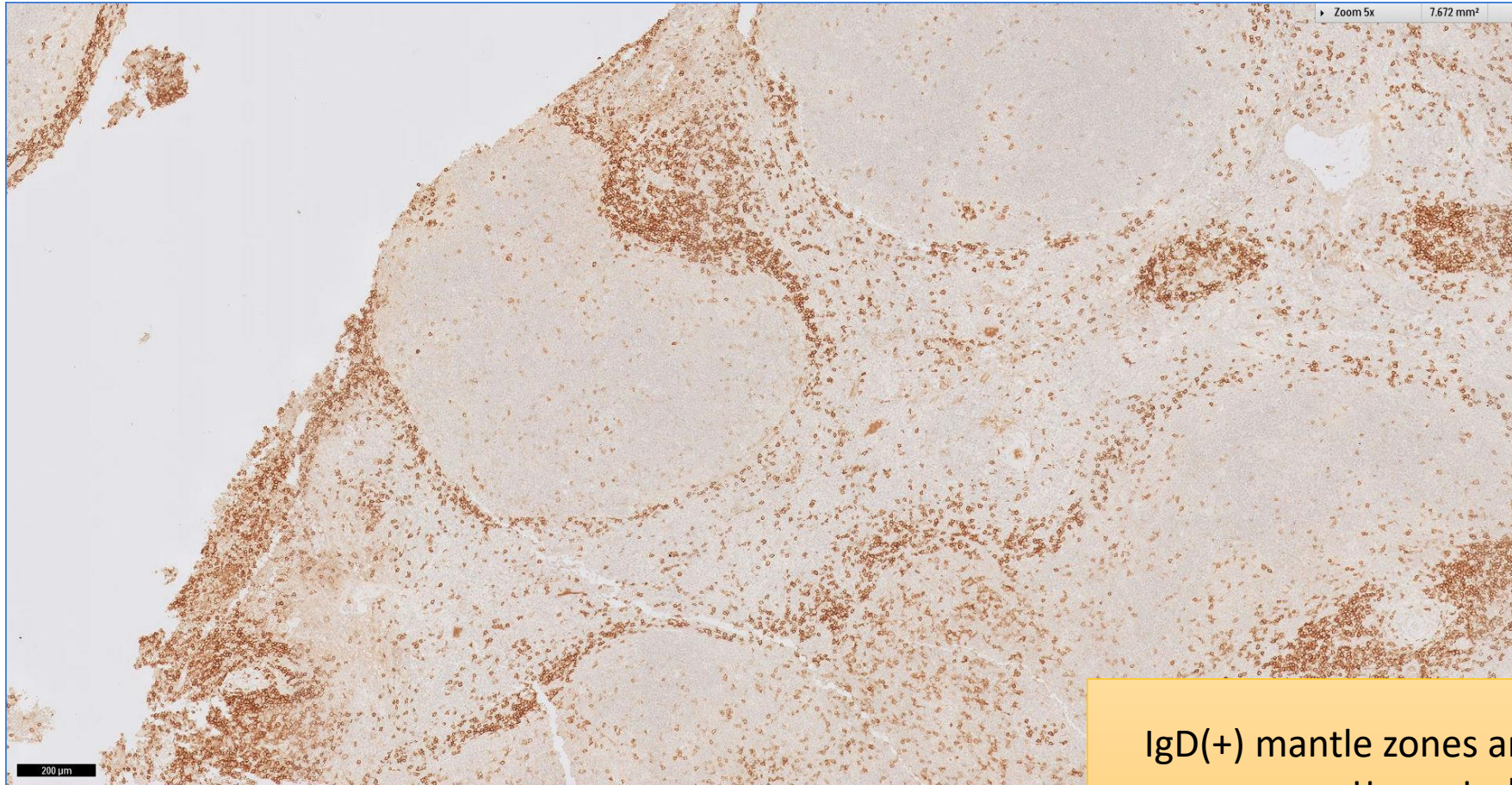
Some of the follicles are Ki-67 high but others show lower Ki-67 proliferation in comparison to reactive germinal centres

SGH CASE 42: 17RE167 KI67



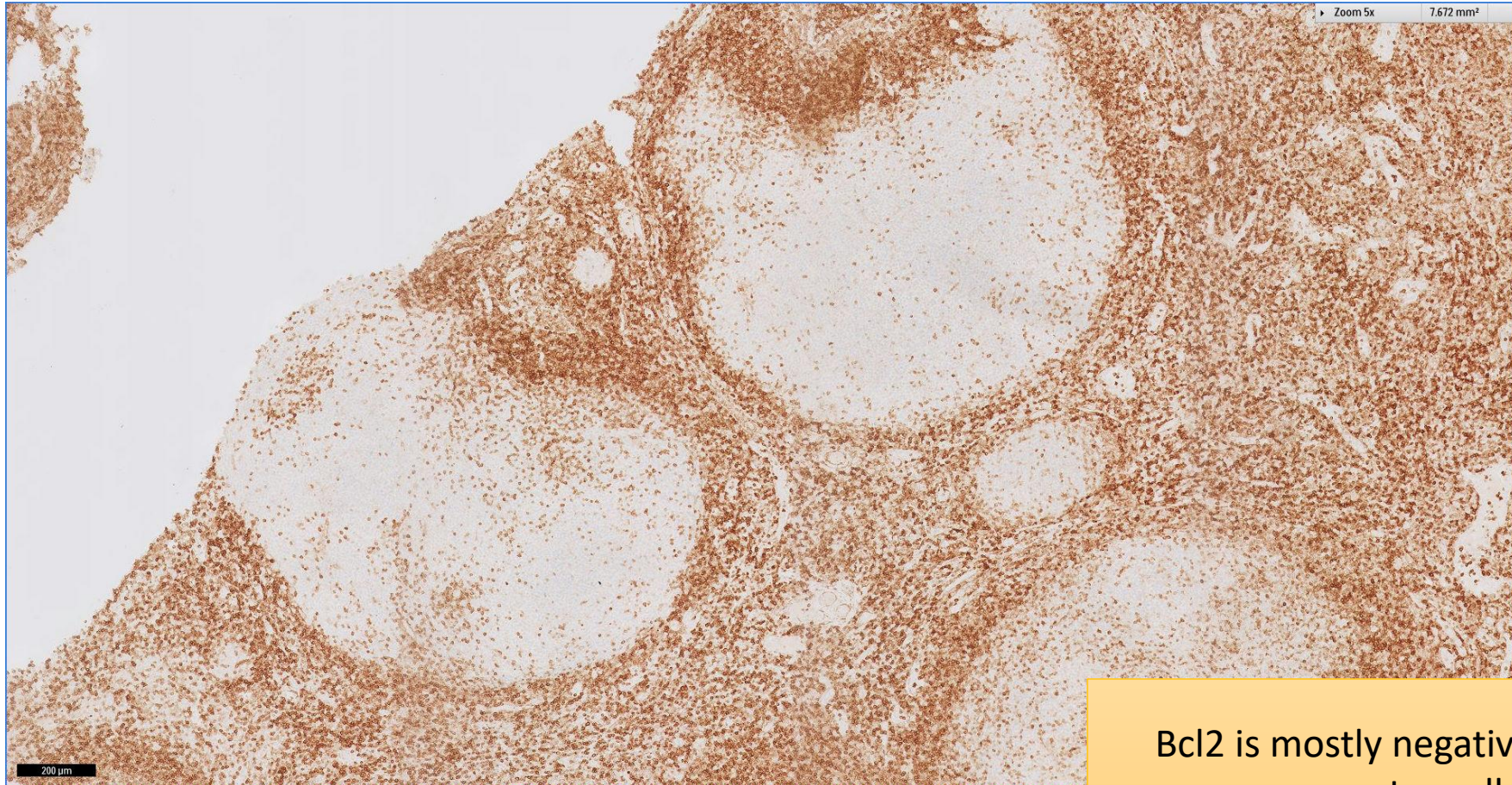
Follicle centre showing lower Ki-67 proliferation in comparison to reactive germinal centres

SGH CASE 42: 17RE167 IgD



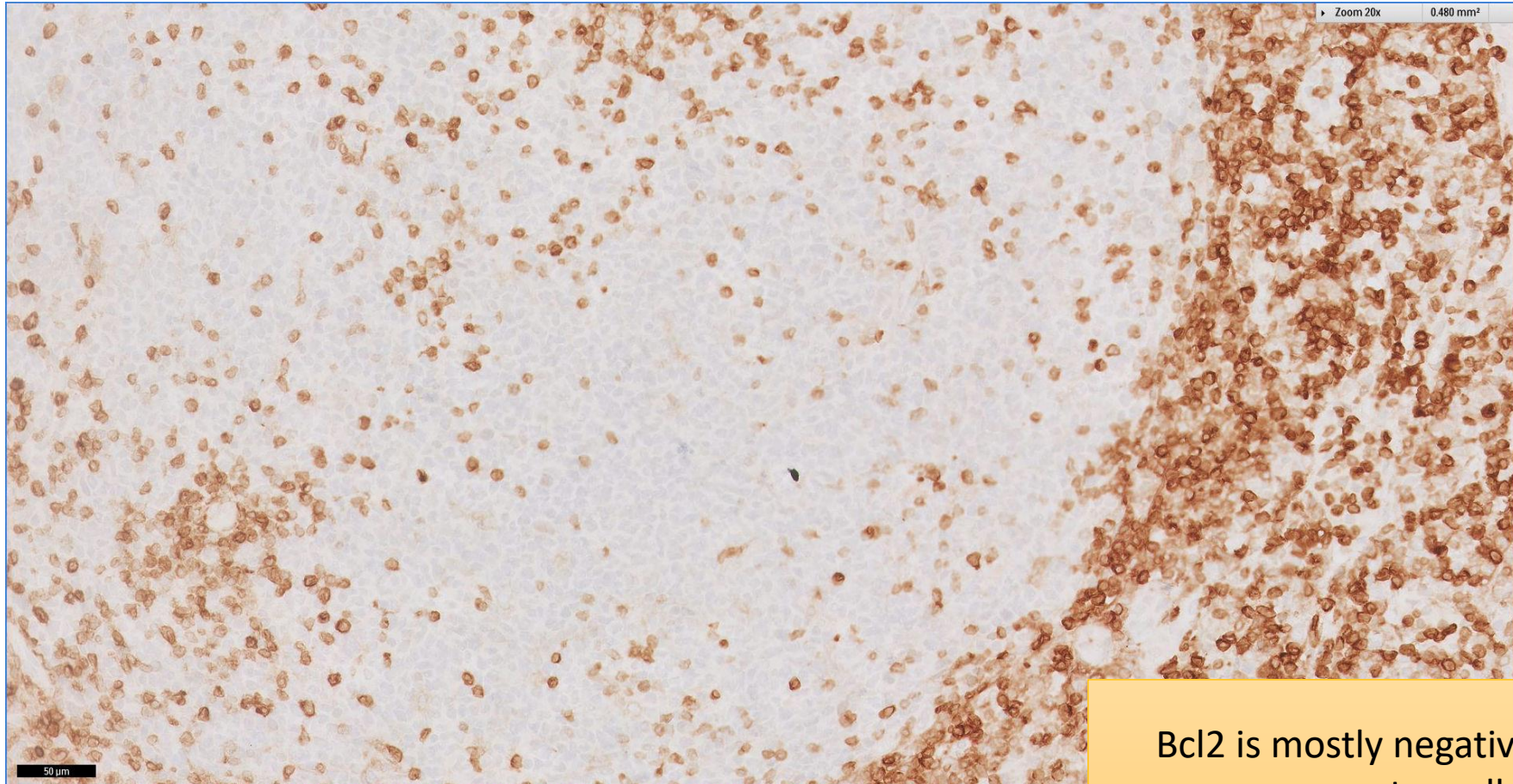
IgD(+) mantle zones are generally attenuated

SGH CASE 42: 17RE167 BCL2



Bcl2 is mostly negative in follicle centre cells

SGH CASE 42: 17RE167 BCL2



Bcl2 is mostly negative in follicle centre cells

SGH CASE 42: 17RE167

- Diagnosis
 - Follicular lymphoma, WHO Grade 3A, bcl-2 negative