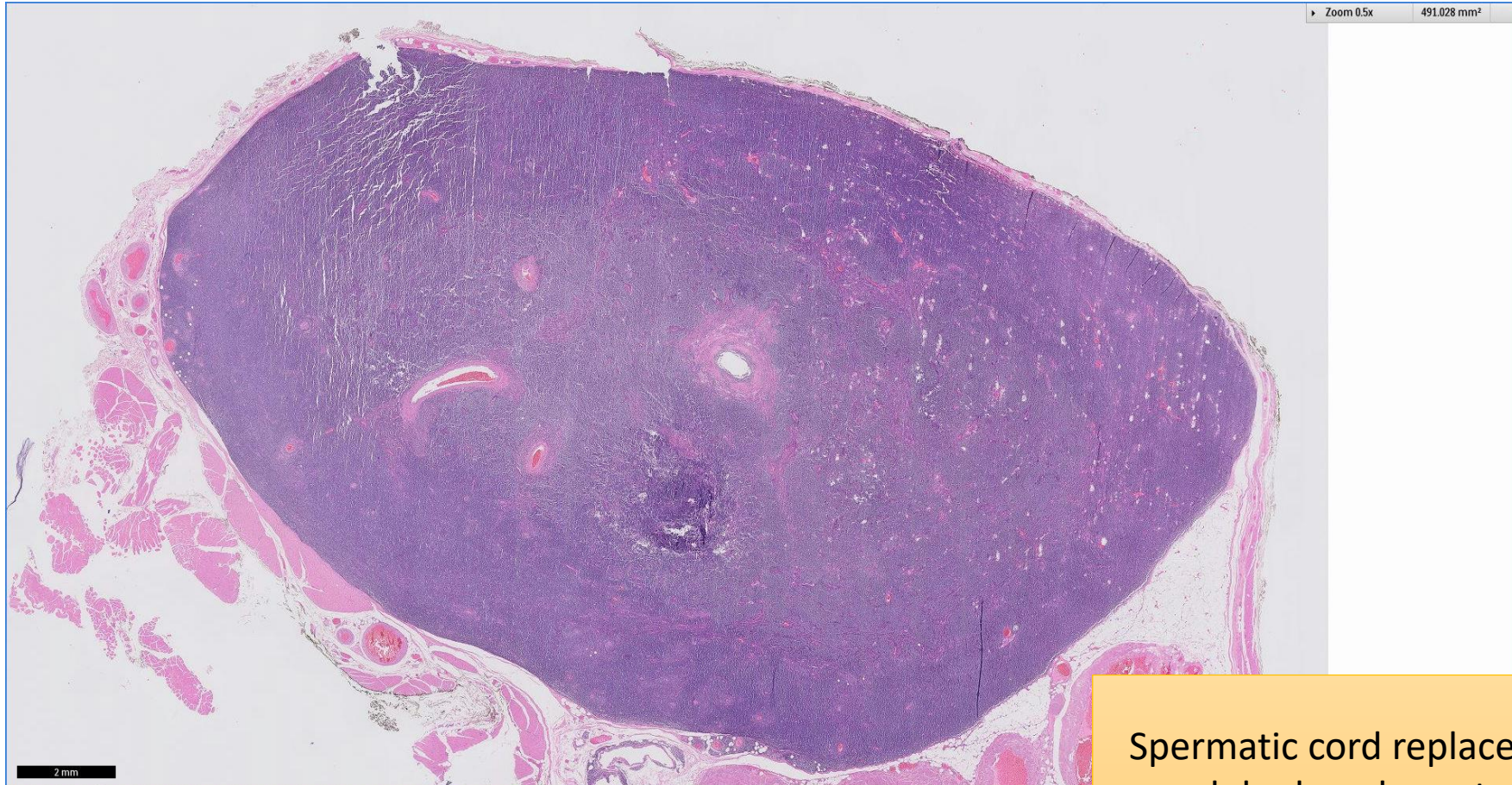


# SGH CASE 41: 17RE166

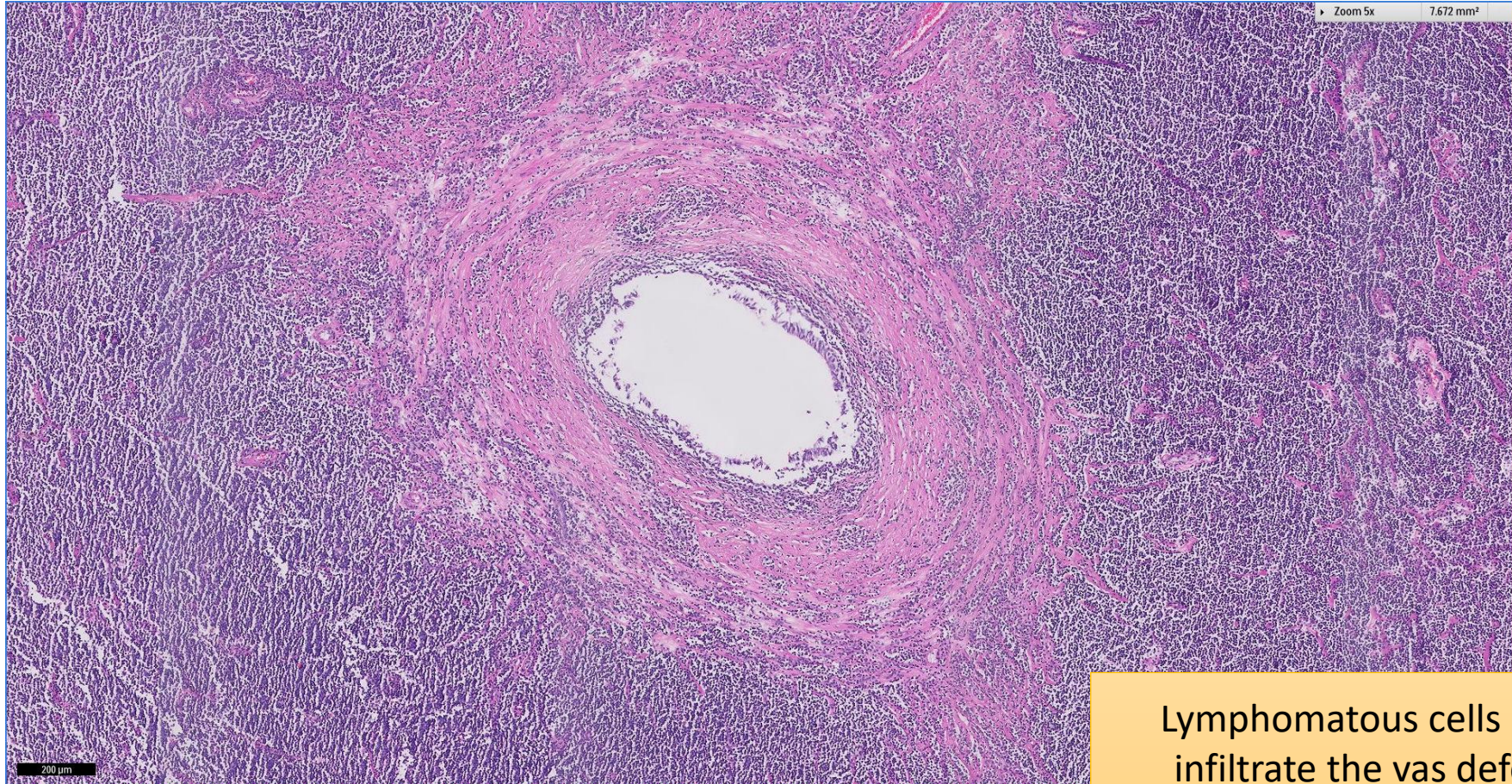
- Clinical History:
  - 50+ years old, Male. Large spermatic cord tumour that pushes against the testis.
- Specimen:
  - Left radical orchidectomy specimen.

# SGH CASE 41: 17RE166 H&E



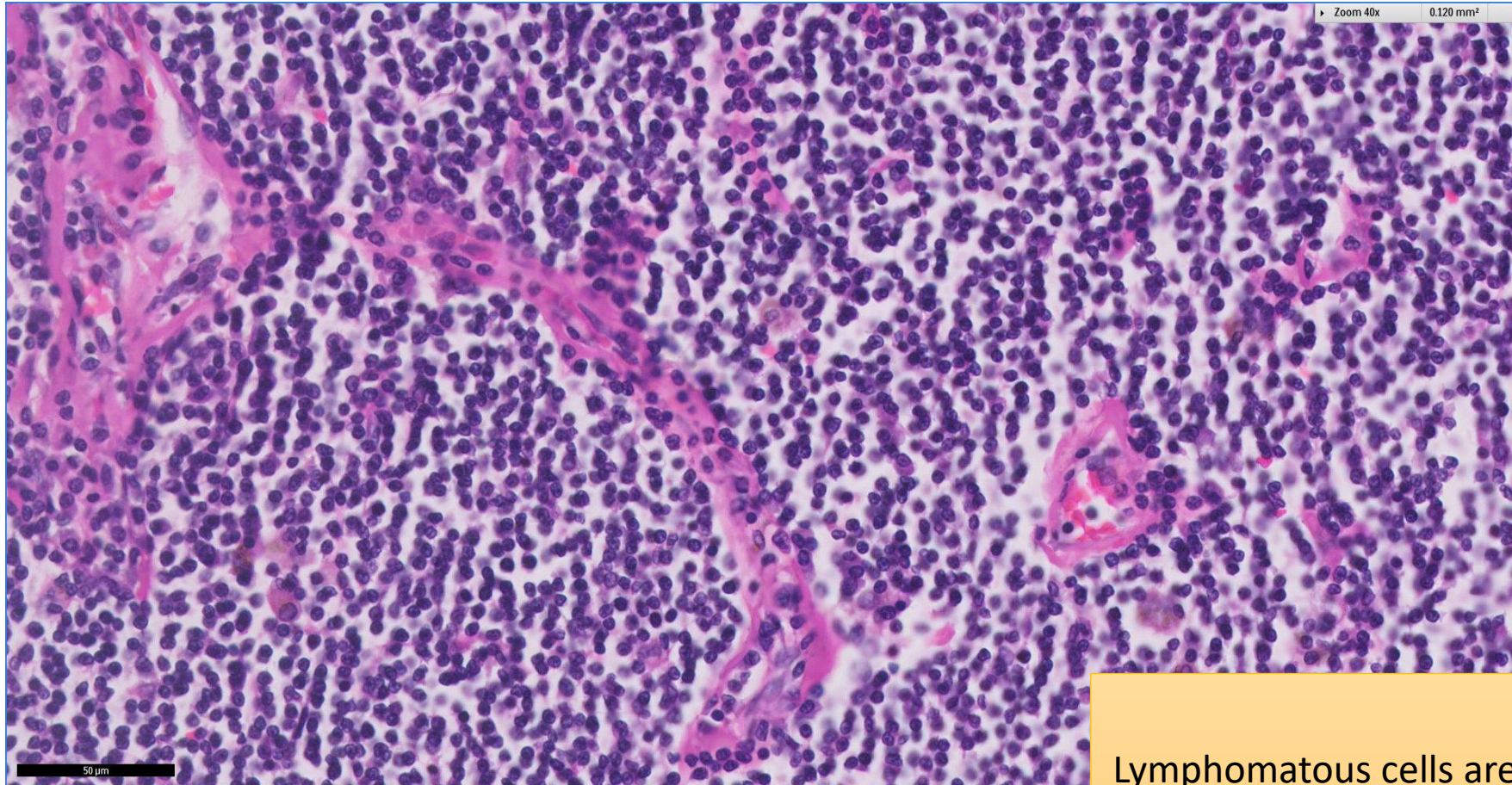
Spermatic cord replaced by vaguely nodular lymphomatous infiltrate

# SGH CASE 41: 17RE166 H&E



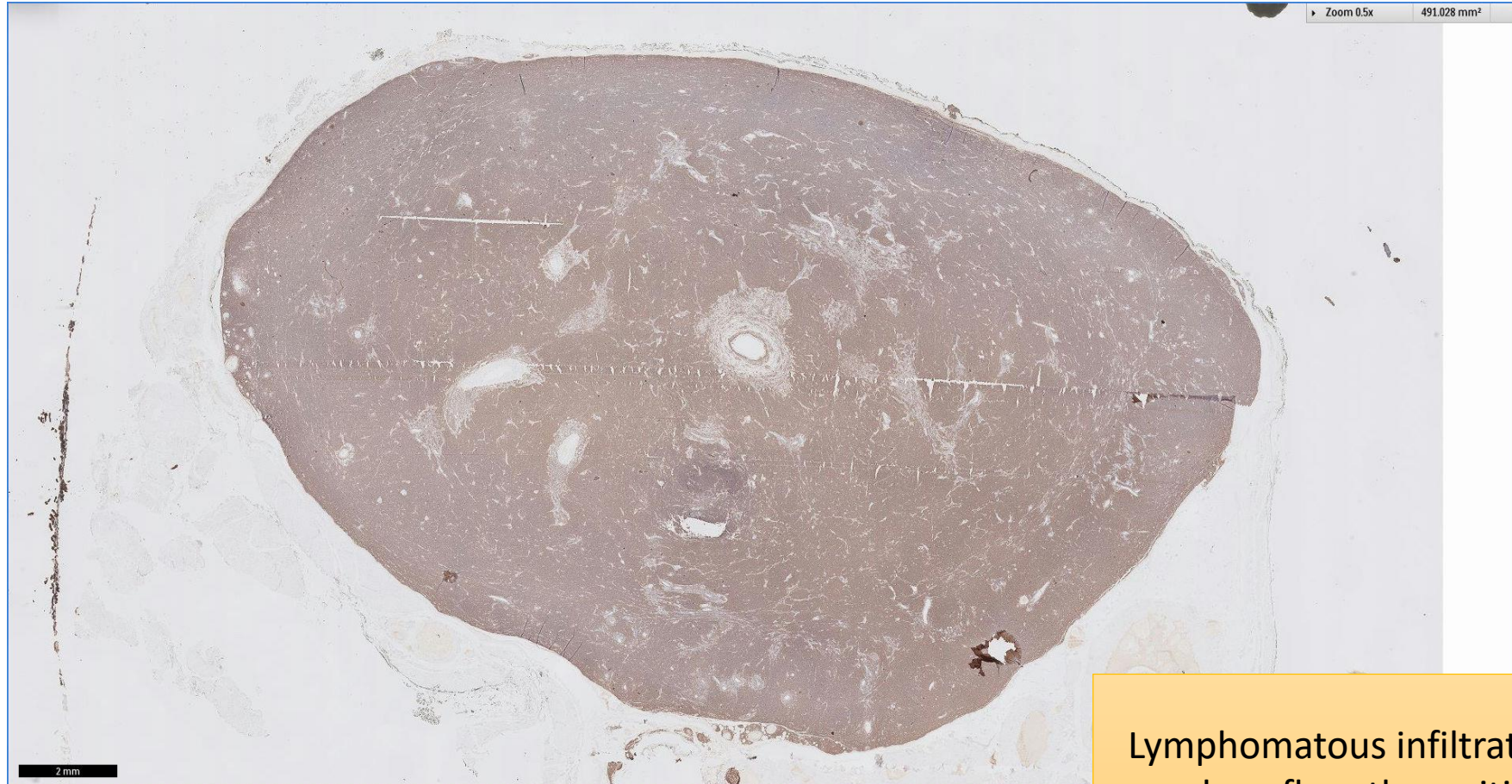
Lymphomatous cells appears to infiltrate the vas deferens and undermines its lining epithelium

# SGH CASE 41: 17RE166 H&E



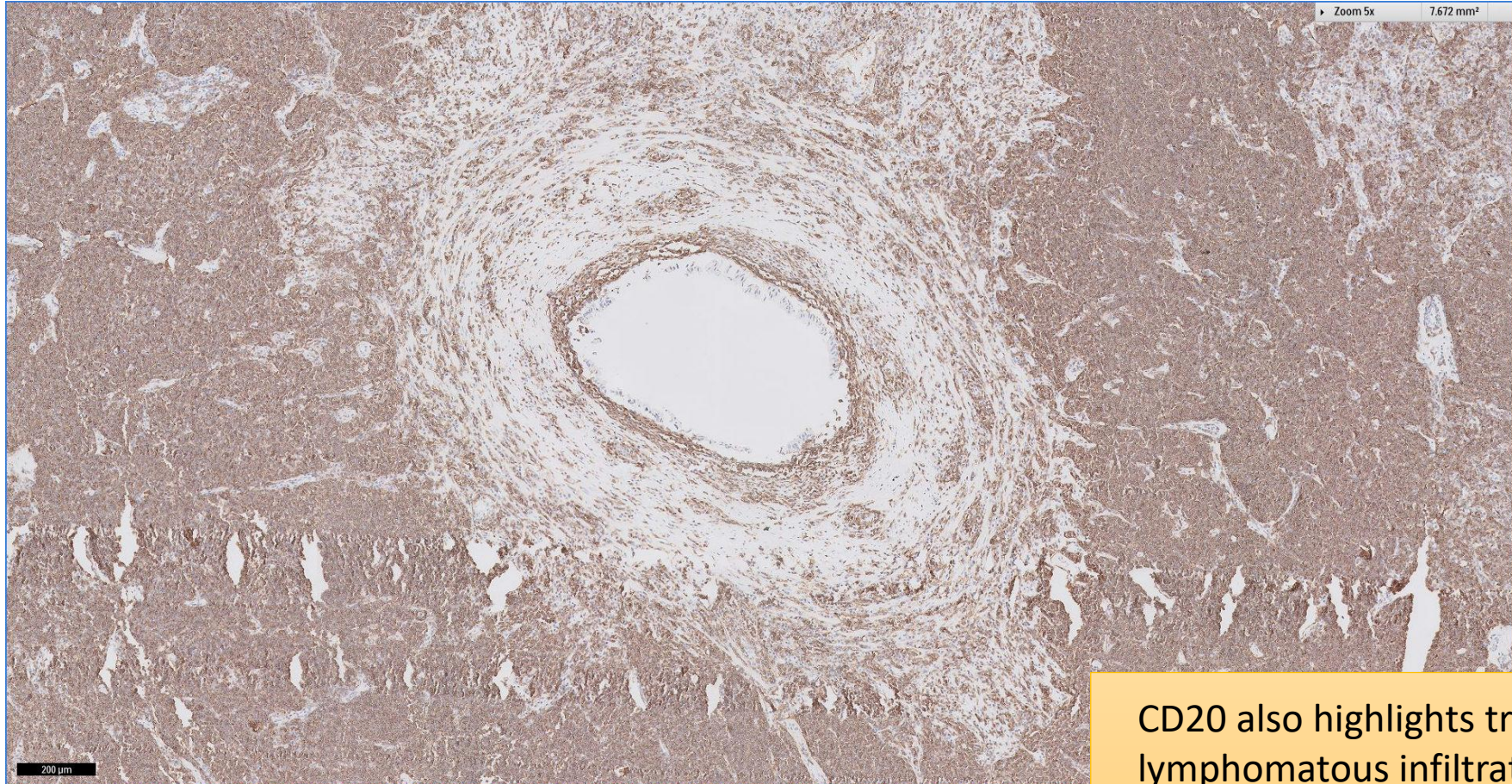
Lymphomatous cells are mostly small

# SGH CASE 41: 17RE166 CD20



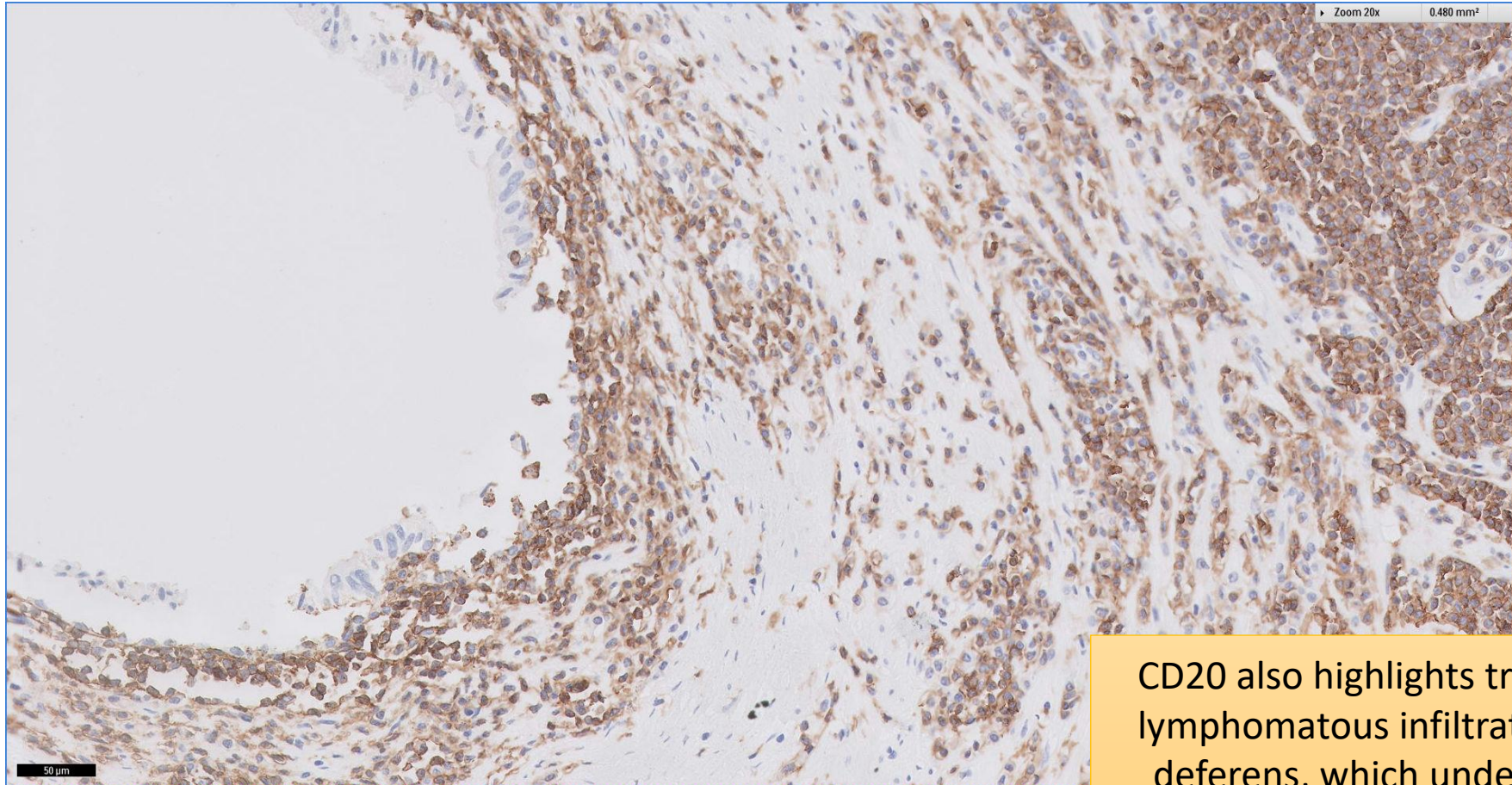
Lymphomatous infiltrate is diffusely and confluent positive for CD20

# SGH CASE 41: 17RE166 CD20



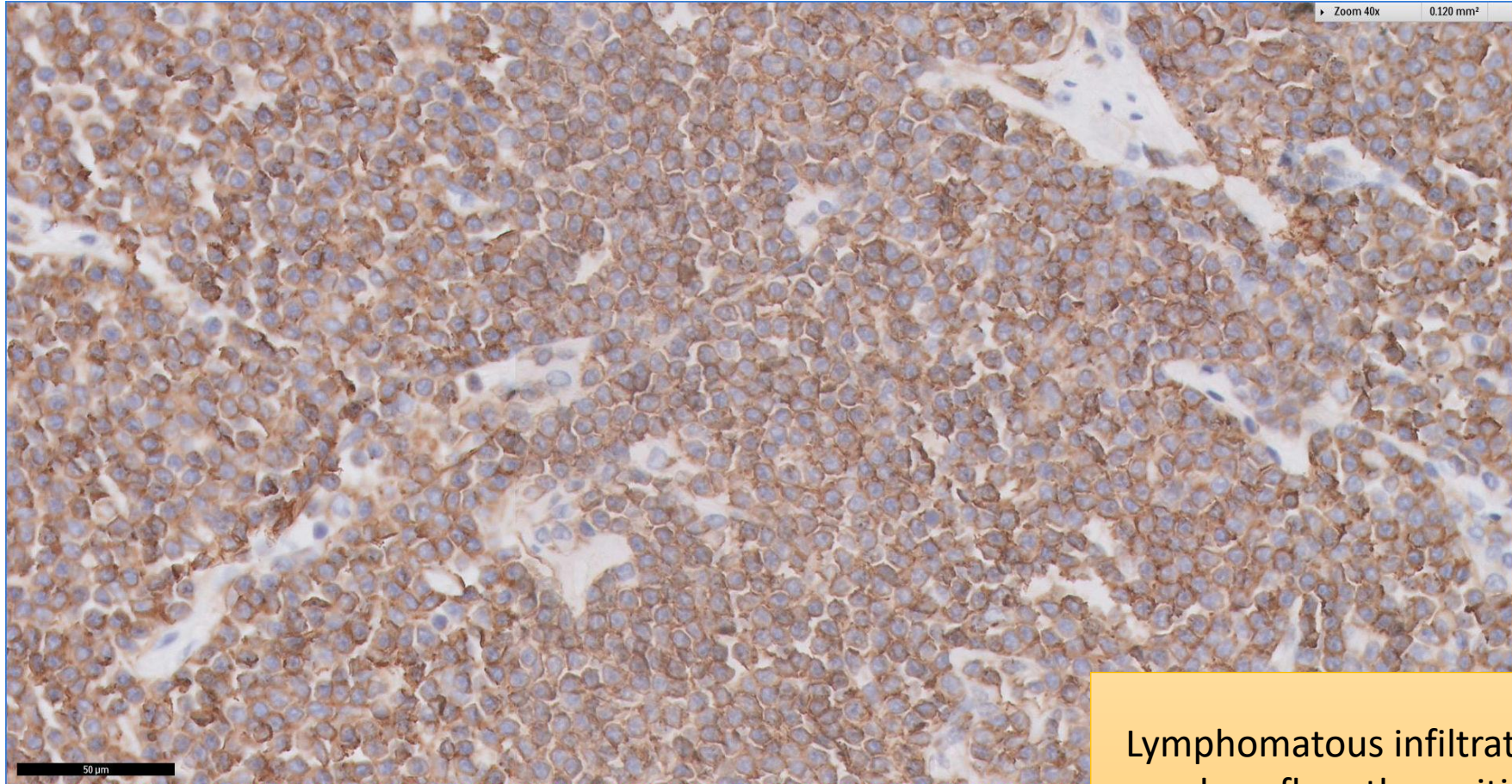
CD20 also highlights transmurinal B-lymphomatous infiltrate in the vas deferens

# SGH CASE 41: 17RE166 CD20



CD20 also highlights transmurular B-lymphomatous infiltrate in the vas deferens, which undermines the lining epithelium (left)

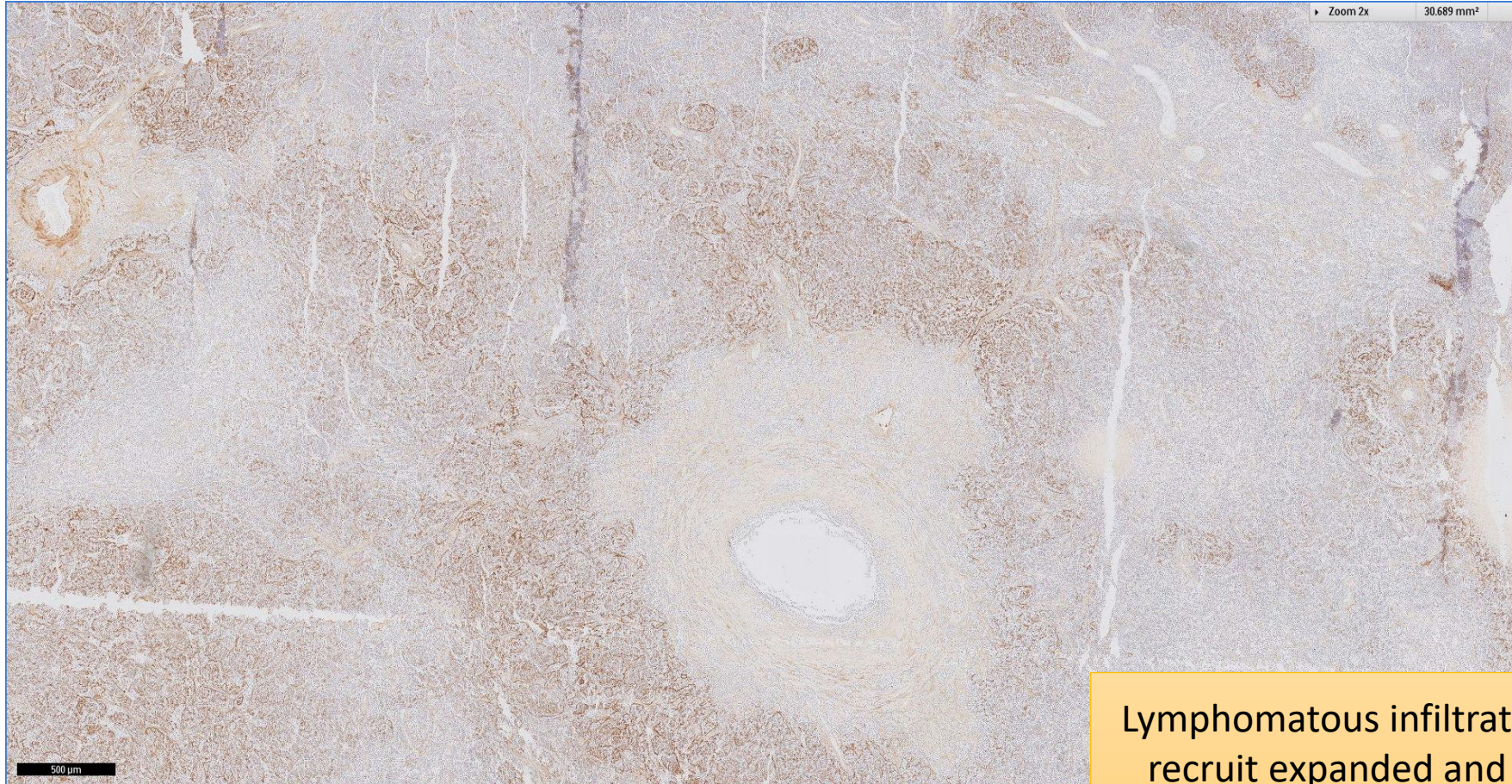
# SGH CASE 41: 17RE166 CD20



Lymphomatous infiltrate is diffusely and confluent positive for CD20

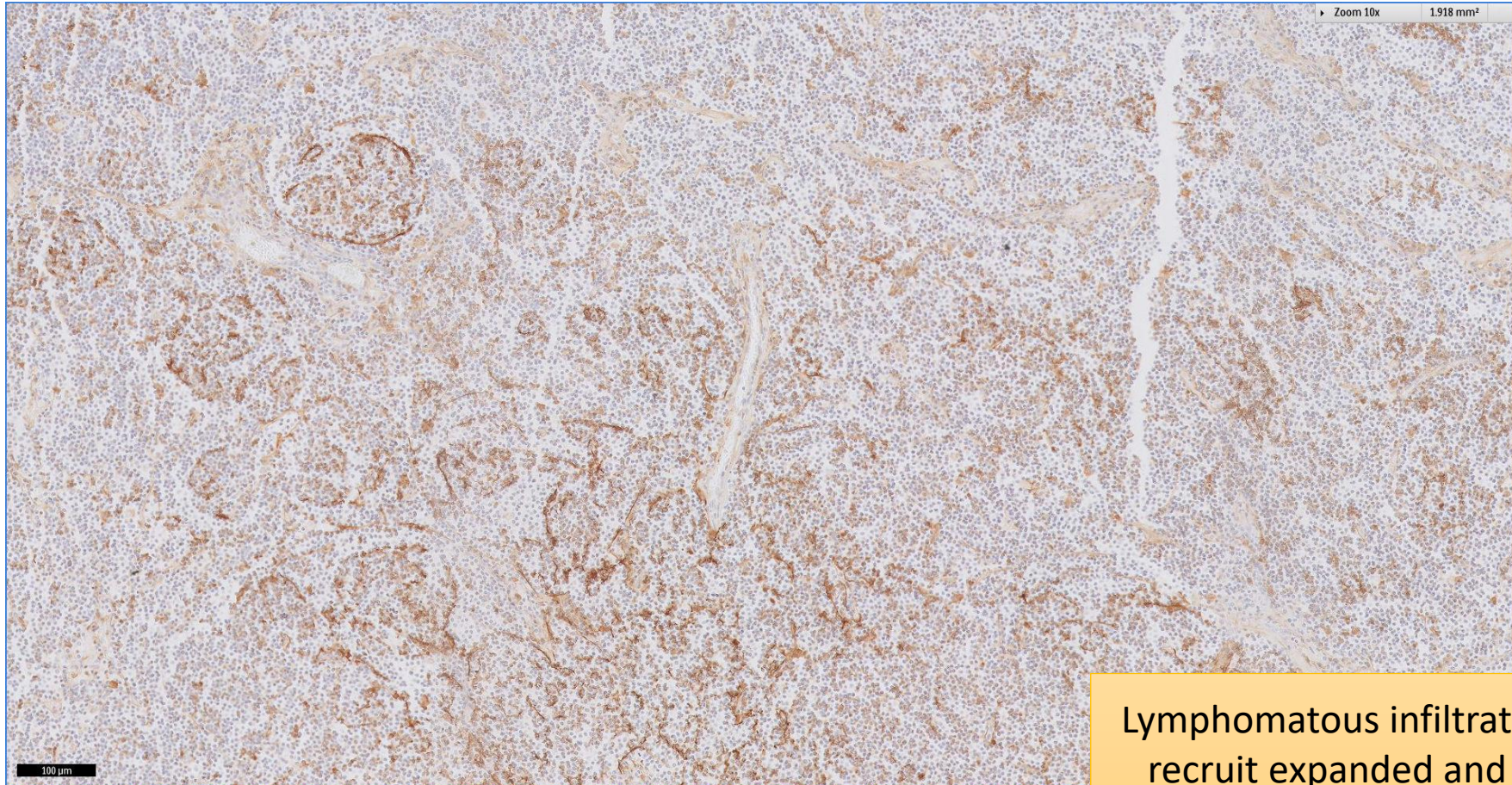


# SGH CASE 41: 17RE166 CD21



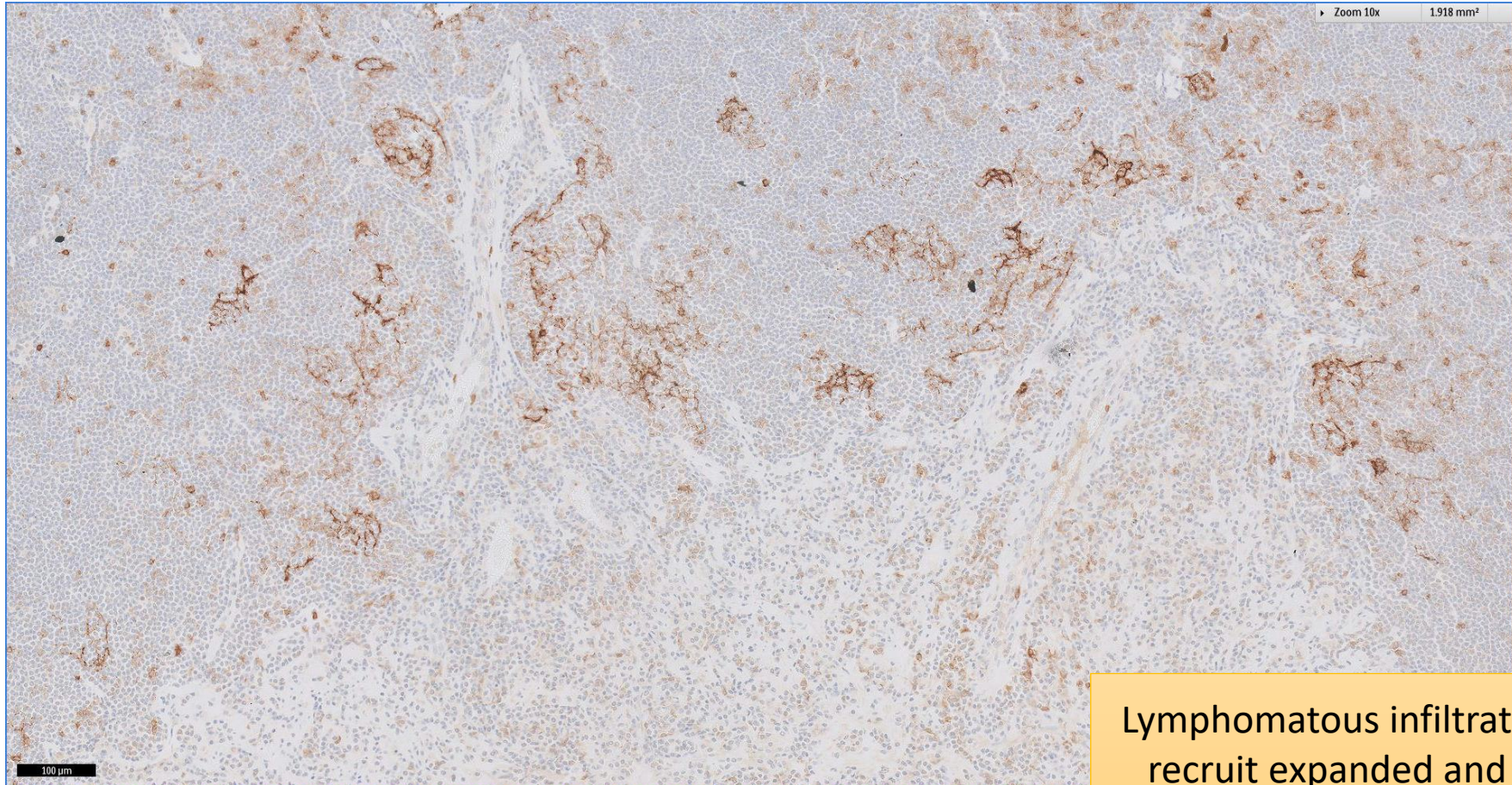
Lymphomatous infiltrate extensively recruit expanded and attenuated follicular dendritic meshworks

# SGH CASE 41: 17RE166 CD21



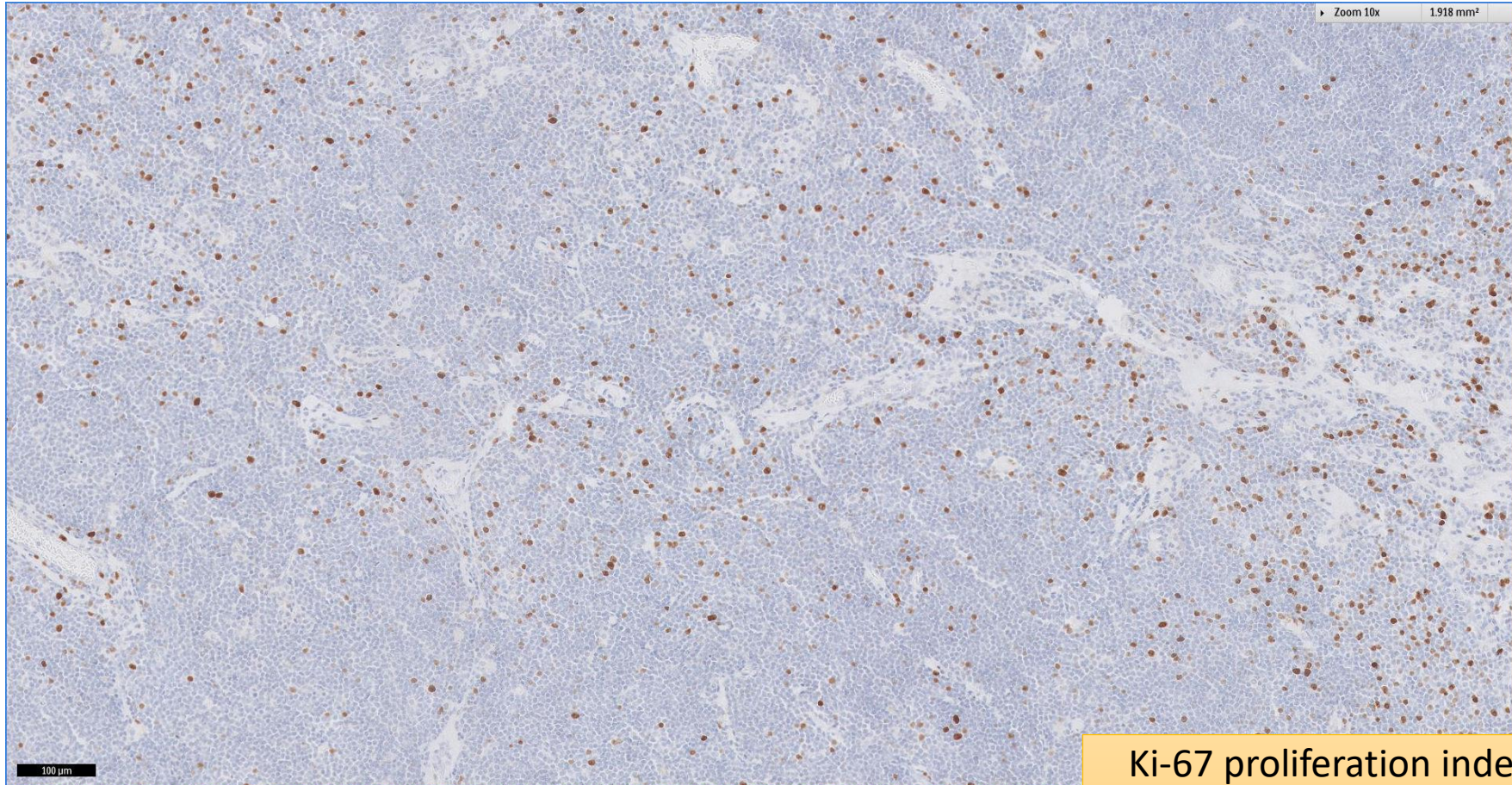
Lymphomatous infiltrate extensively recruit expanded and attenuated follicular dendritic meshworks

# SGH CASE 41: 17RE166 CD23



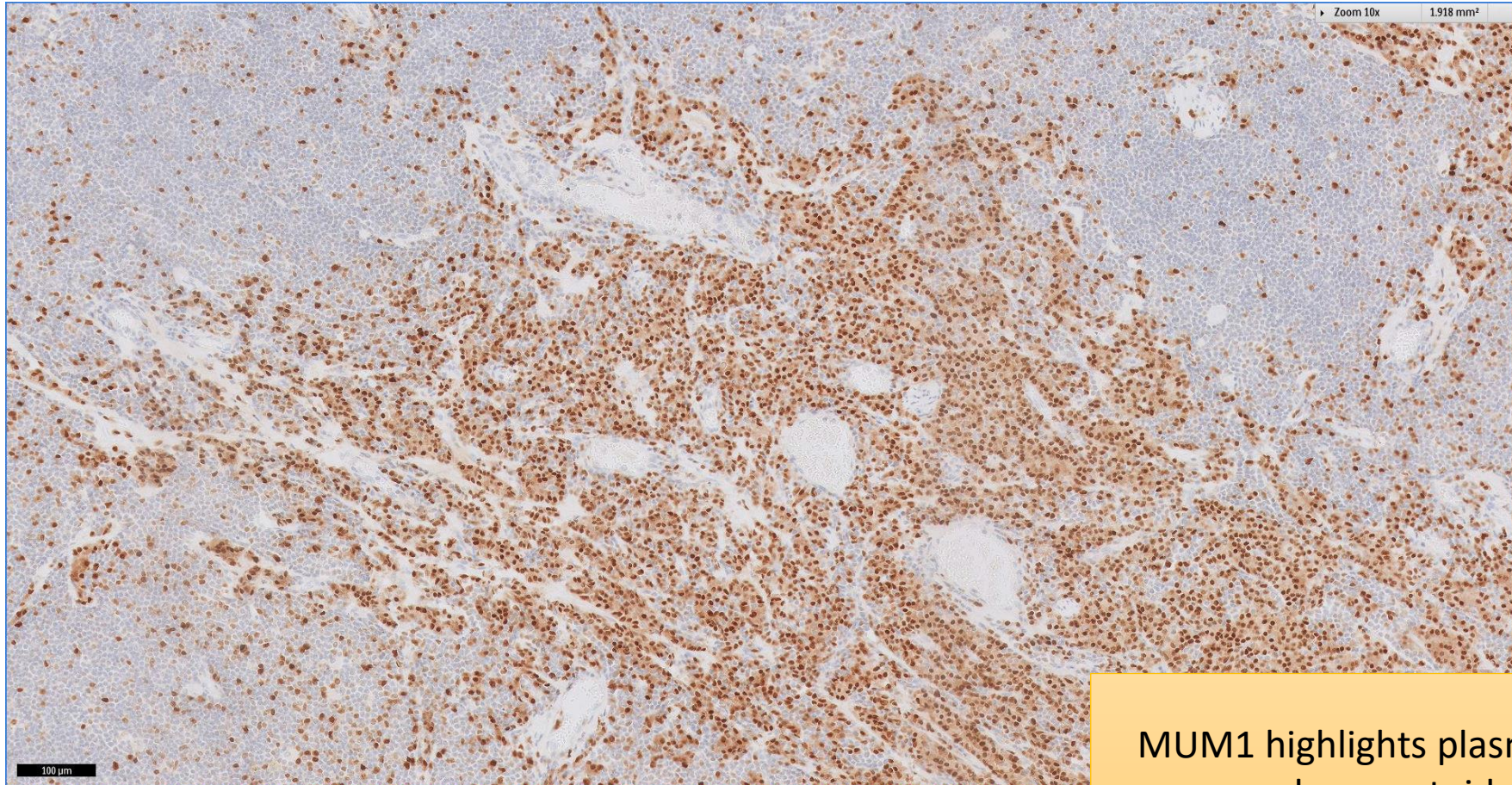
Lymphomatous infiltrate extensively recruit expanded and attenuated follicular dendritic meshworks

# SGH CASE 41: 17RE166 KI67



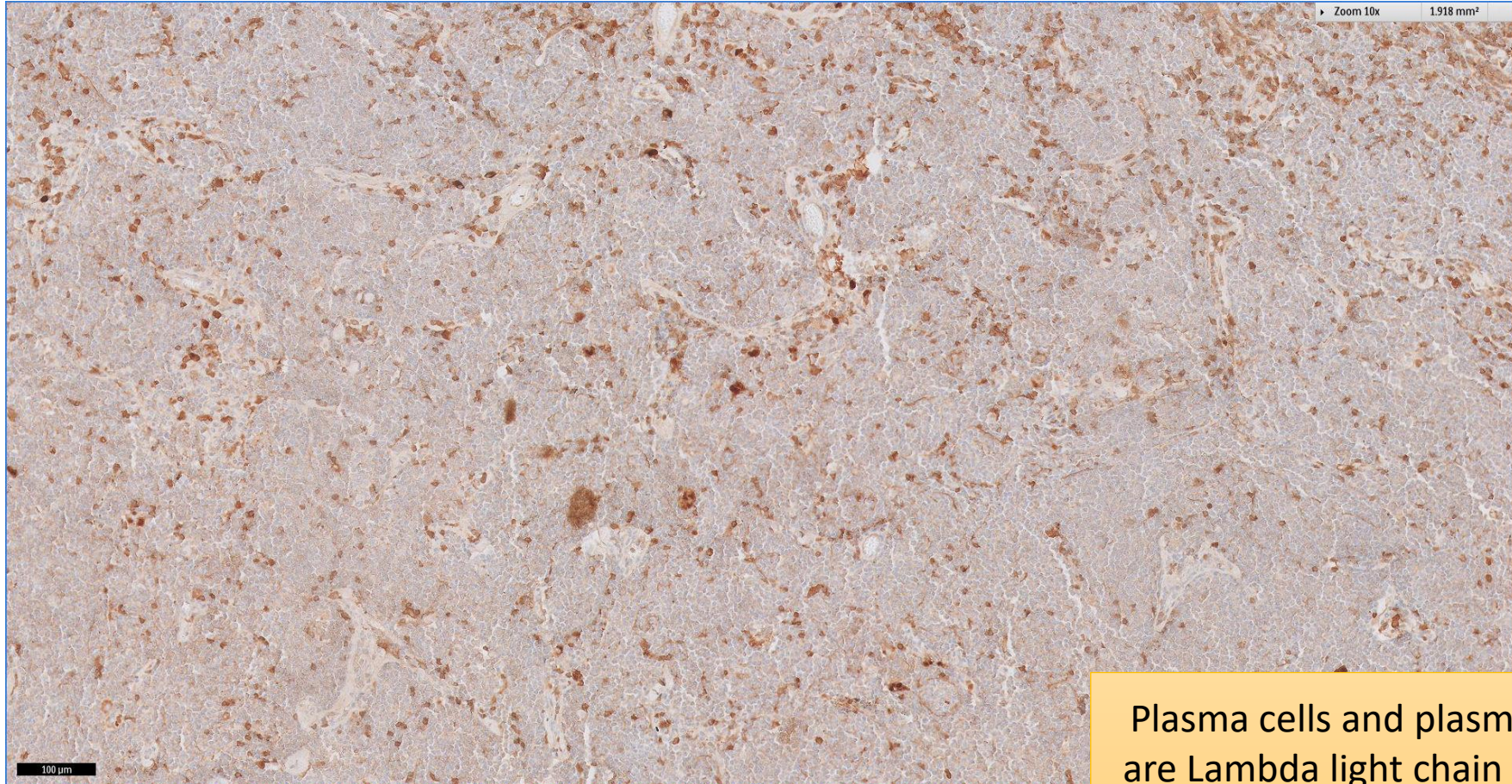
Ki-67 proliferation index is generally low and partly reflect remnant germinal centre cells of colonised follicles (bottom right)

# SGH CASE 41: 17RE166 MUM1



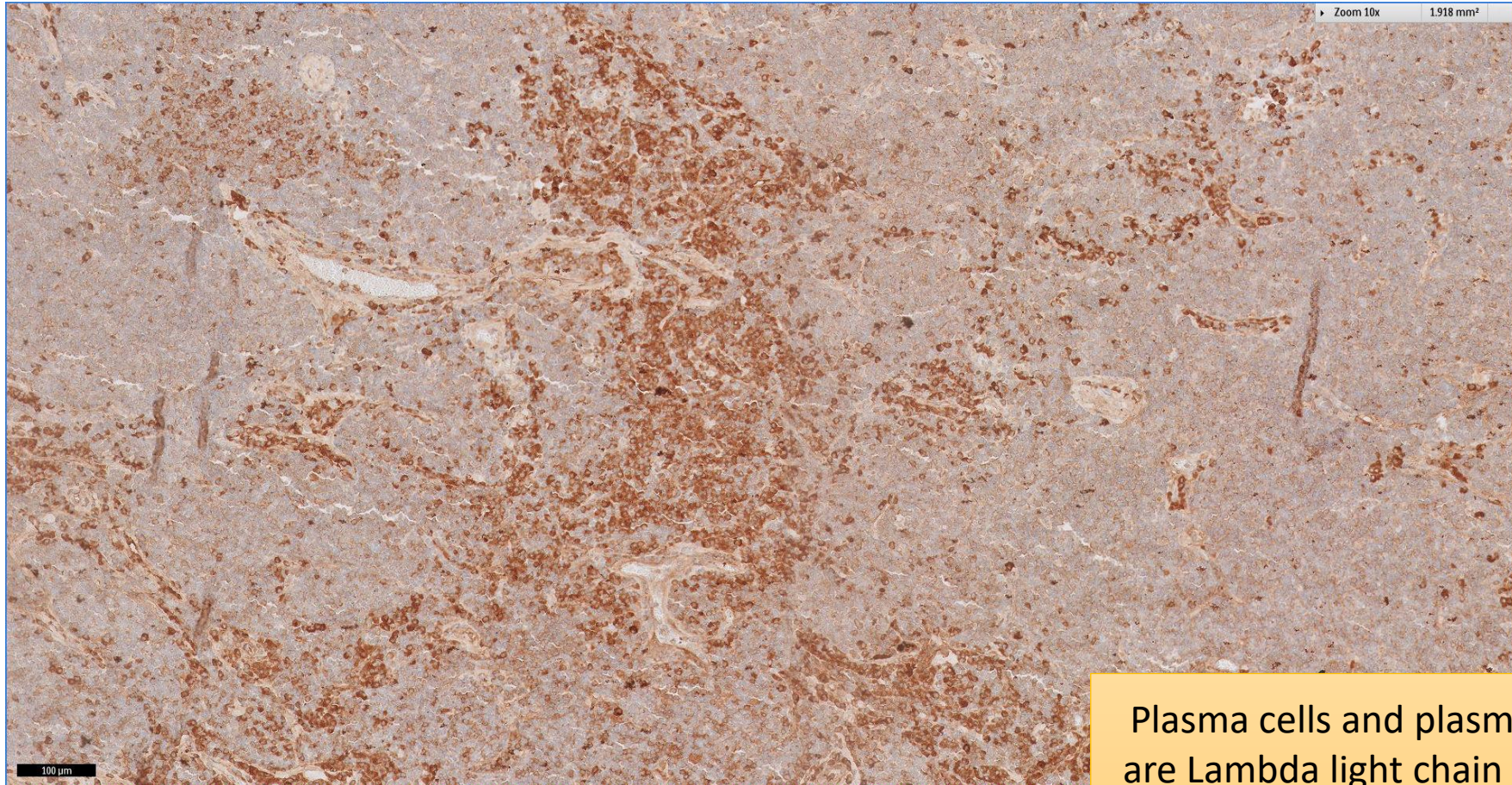
MUM1 highlights plasma cells and plasmacytoid cells

# SGH CASE 41: 17RE166 KAPPA-IHC



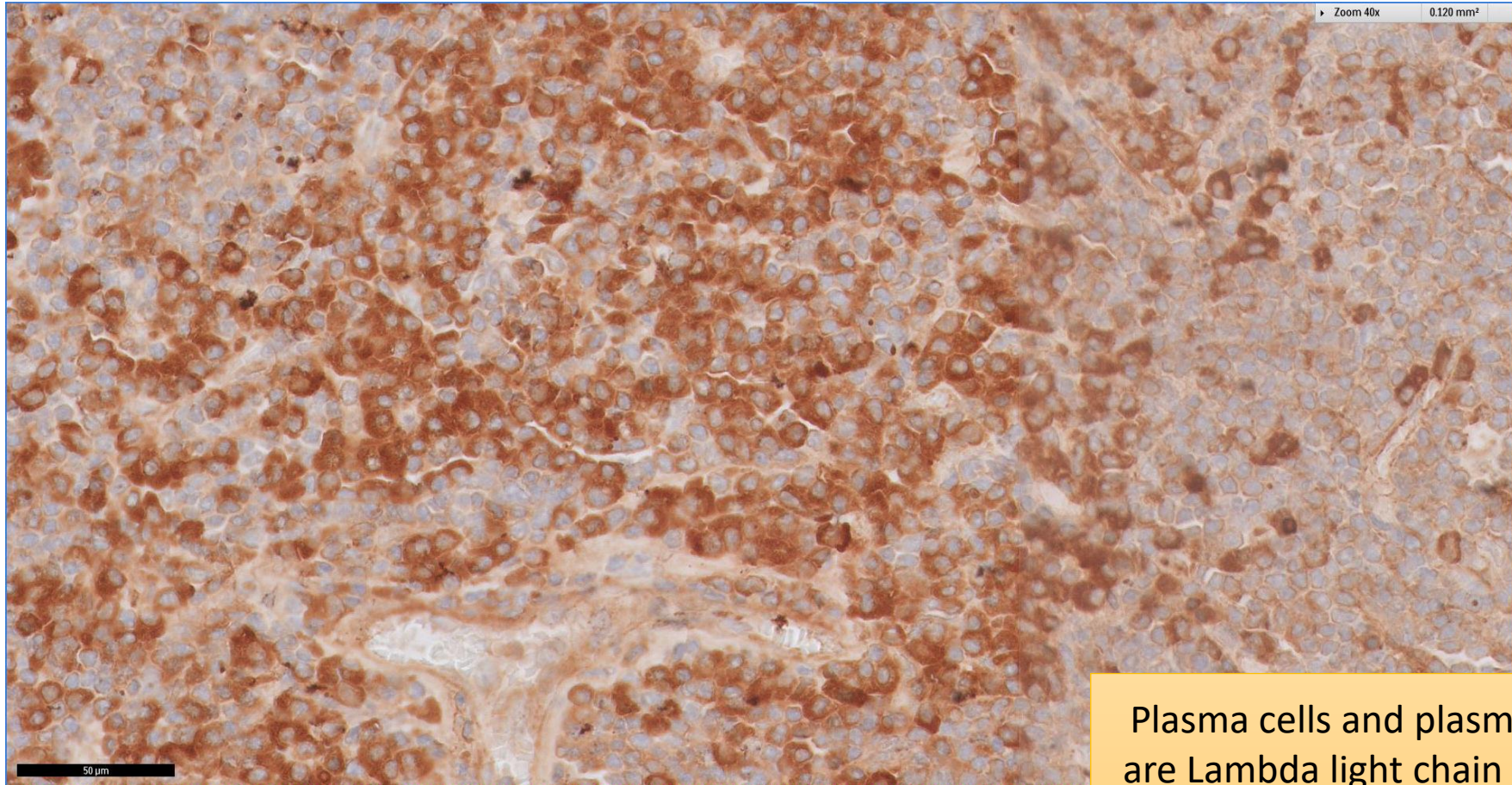
Plasma cells and plasmacytoid cells are Lambda light chain restricted on immunohistochemistry

# SGH CASE 41: 17RE166 LAMBDA-IHC



Plasma cells and plasmacytoid cells are Lambda light chain restricted on immunohistochemistry

# SGH CASE 41: 17RE166 LAMBDA-IHC



Plasma cells and plasmacytoid cells are Lambda light chain restricted on immunohistochemistry



# SGH CASE 41: 17RE166

- Diagnosis
  - Extranodal Marginal Zone Lymphoma of Mucosa-associated Lymphoid Tissue