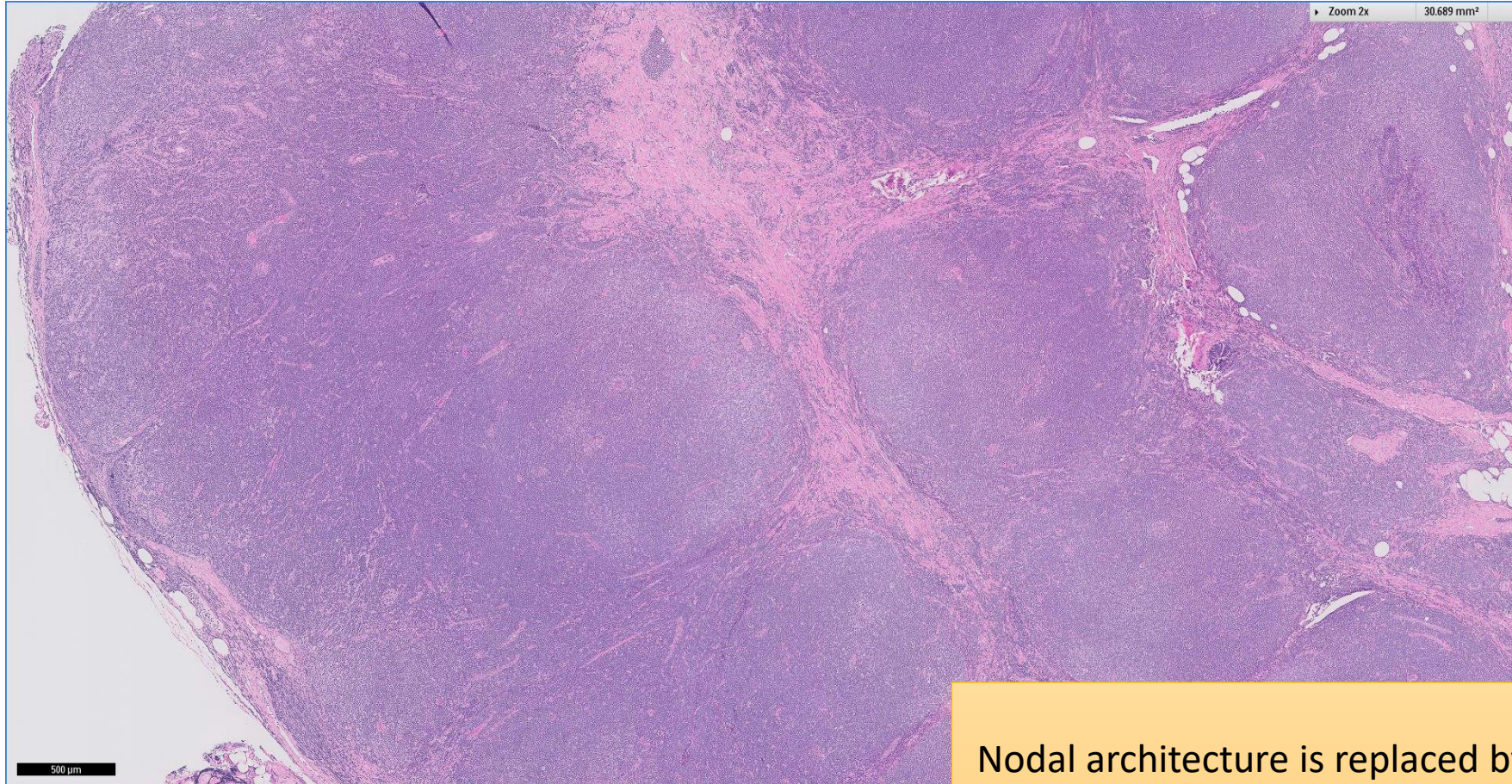

# SGH CASE 39: 17RE163 & 17RE164

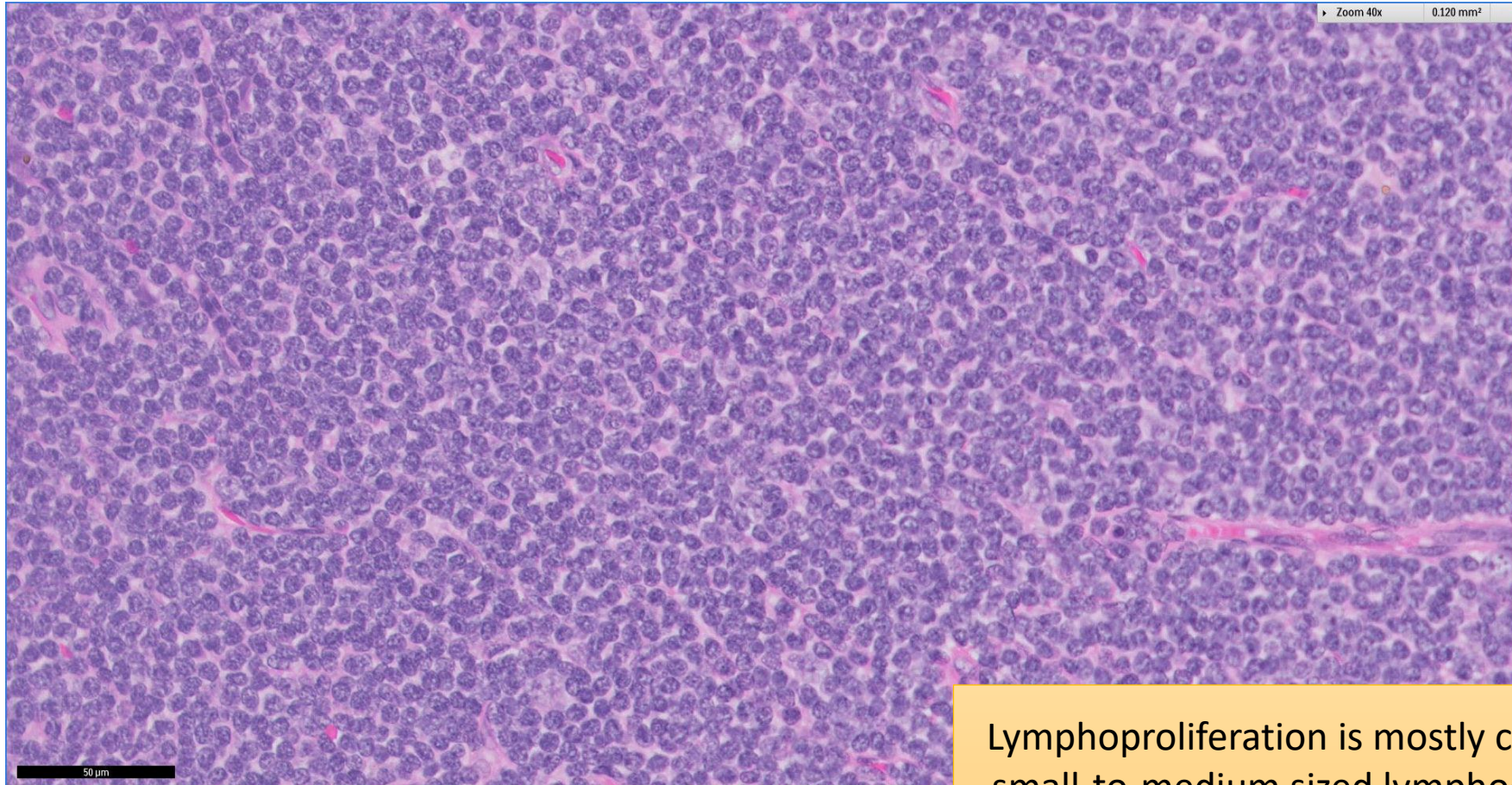
- Clinical History:
  - 50+ years old, Male. Previously treated for lymphoproliferative disorder with complete remission 7 years ago. CT scan shows multiple lymphadenopathy.
- Specimen:
  - Right inguinal lymph node (17RE163) and bone marrow biopsy (17RE164)

# SGH CASE 39: 17RE163 LYMPH NODE H&E



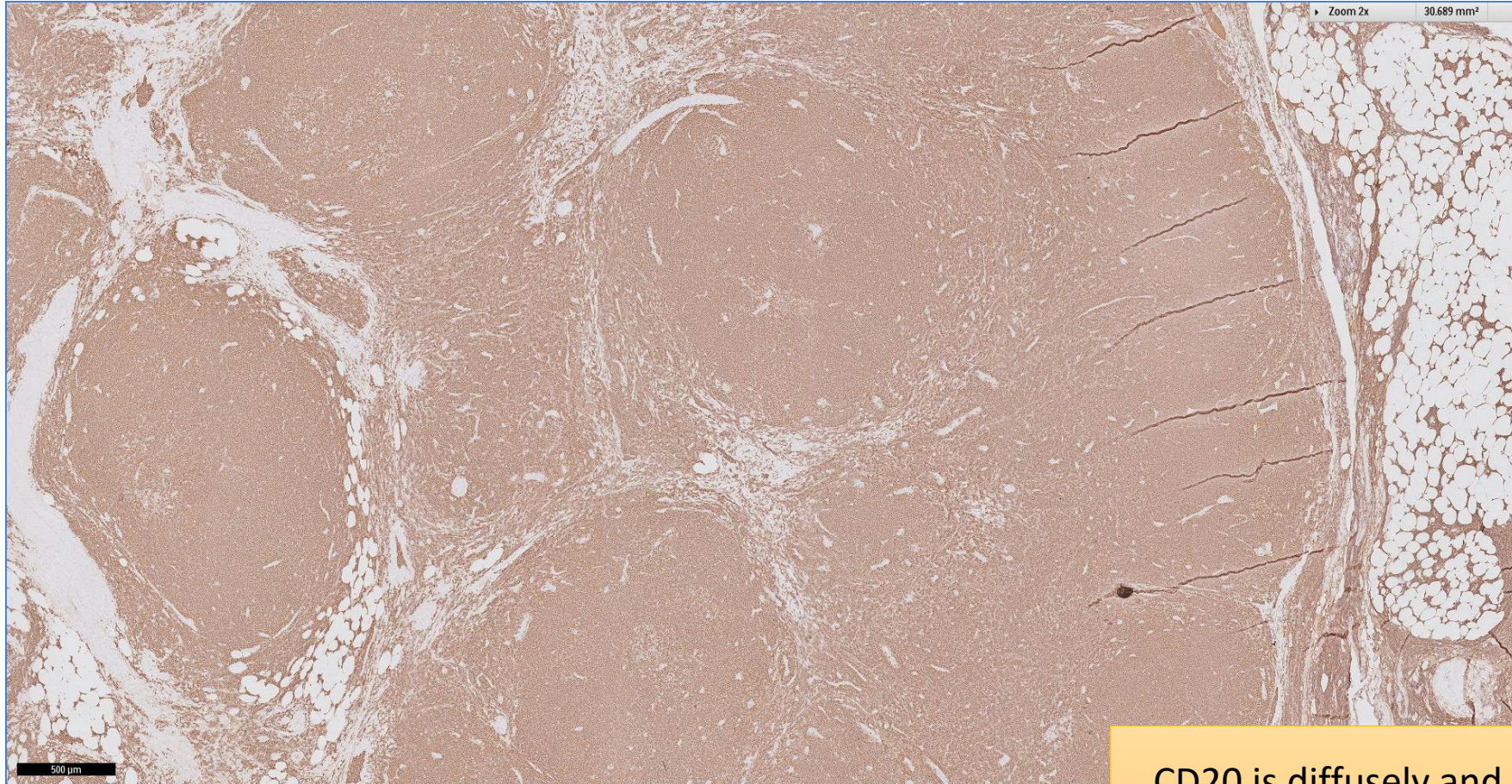
Nodal architecture is replaced by ill-defined,  
discrete and coalescent nodules

# SGH CASE 39: 17RE163 LYMPH NODE H&E



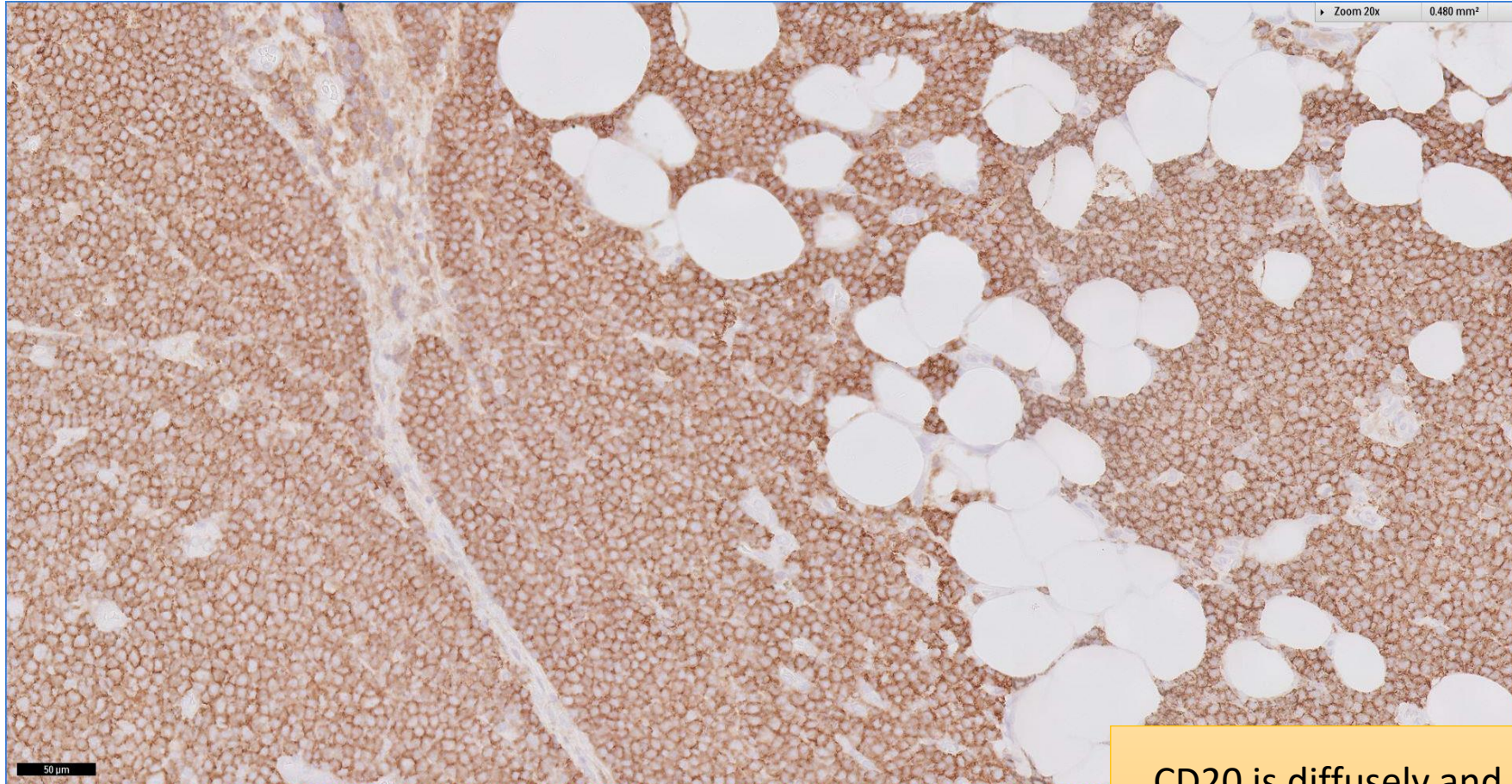
Lymphoproliferation is mostly composed of small-to-medium sized lymphocytes, some of which are monocytoïd

# SGH CASE 39: 17RE163 LYMPH NODE CD20



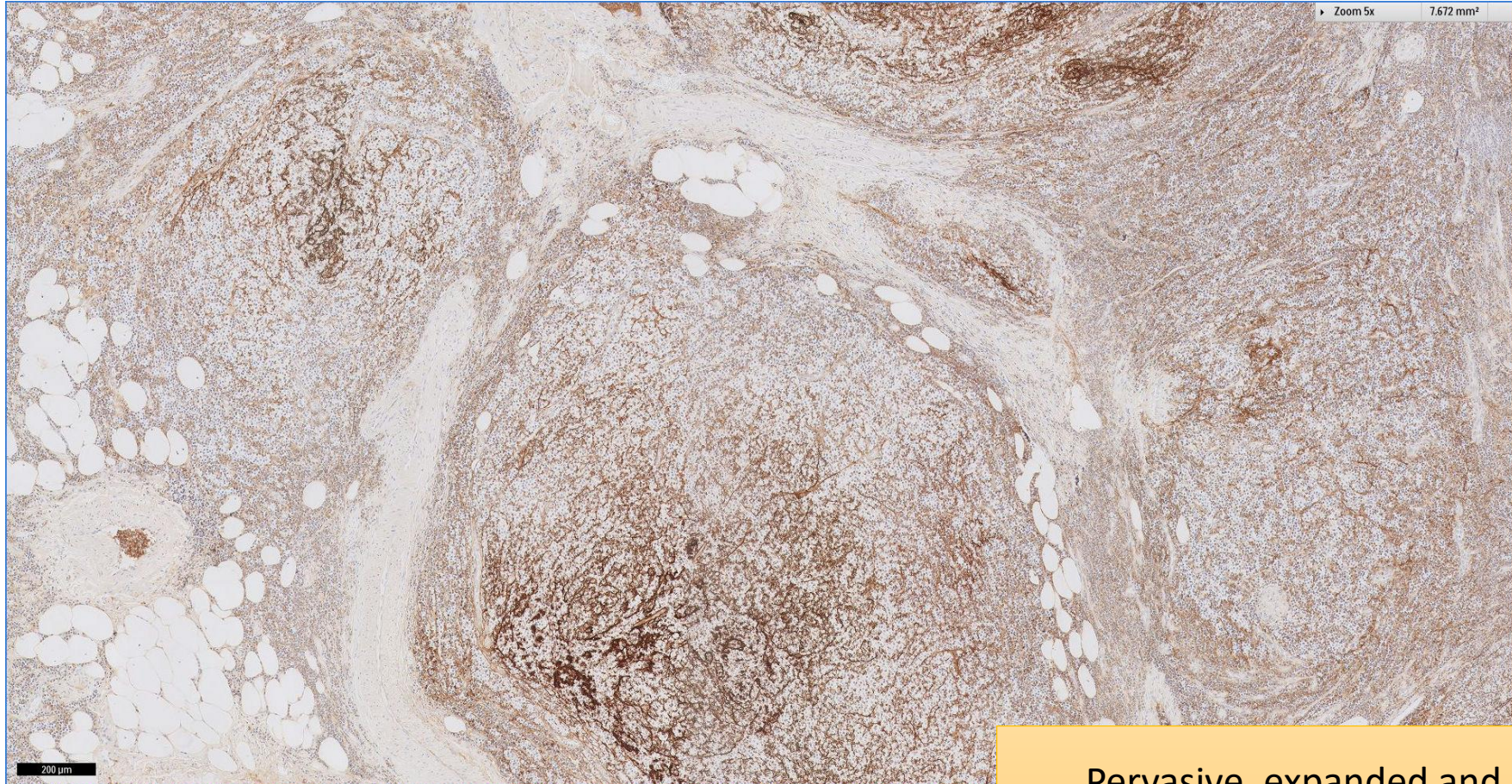
**CD20 is diffusely and confluenty positive in the lymphoproliferation**

# SGH CASE 39: 17RE163 LYMPH NODE CD20



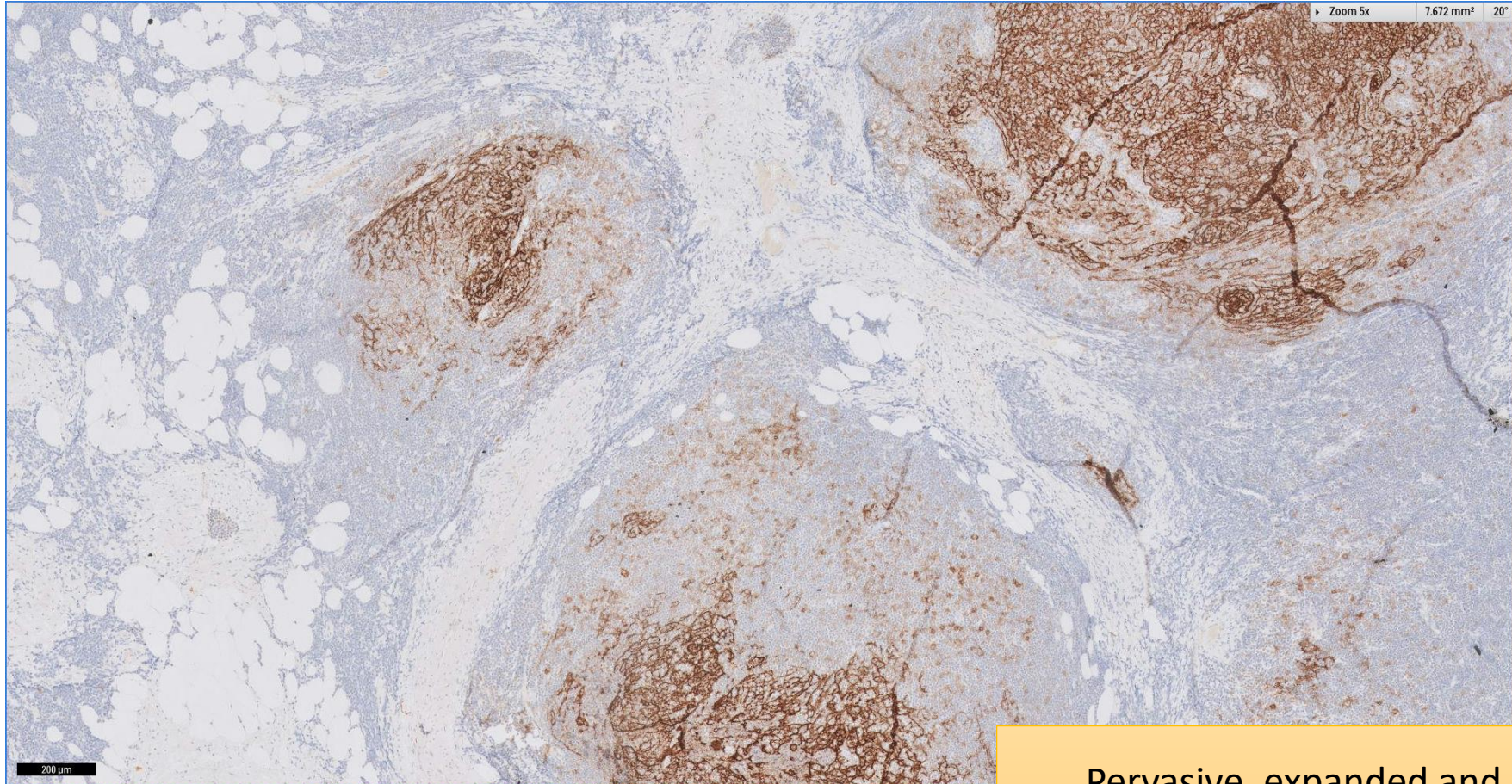
**CD20 is diffusely and confluent positive in the lymphoproliferation**

# SGH CASE 39: 17RE163 LYMPH NODE CD21



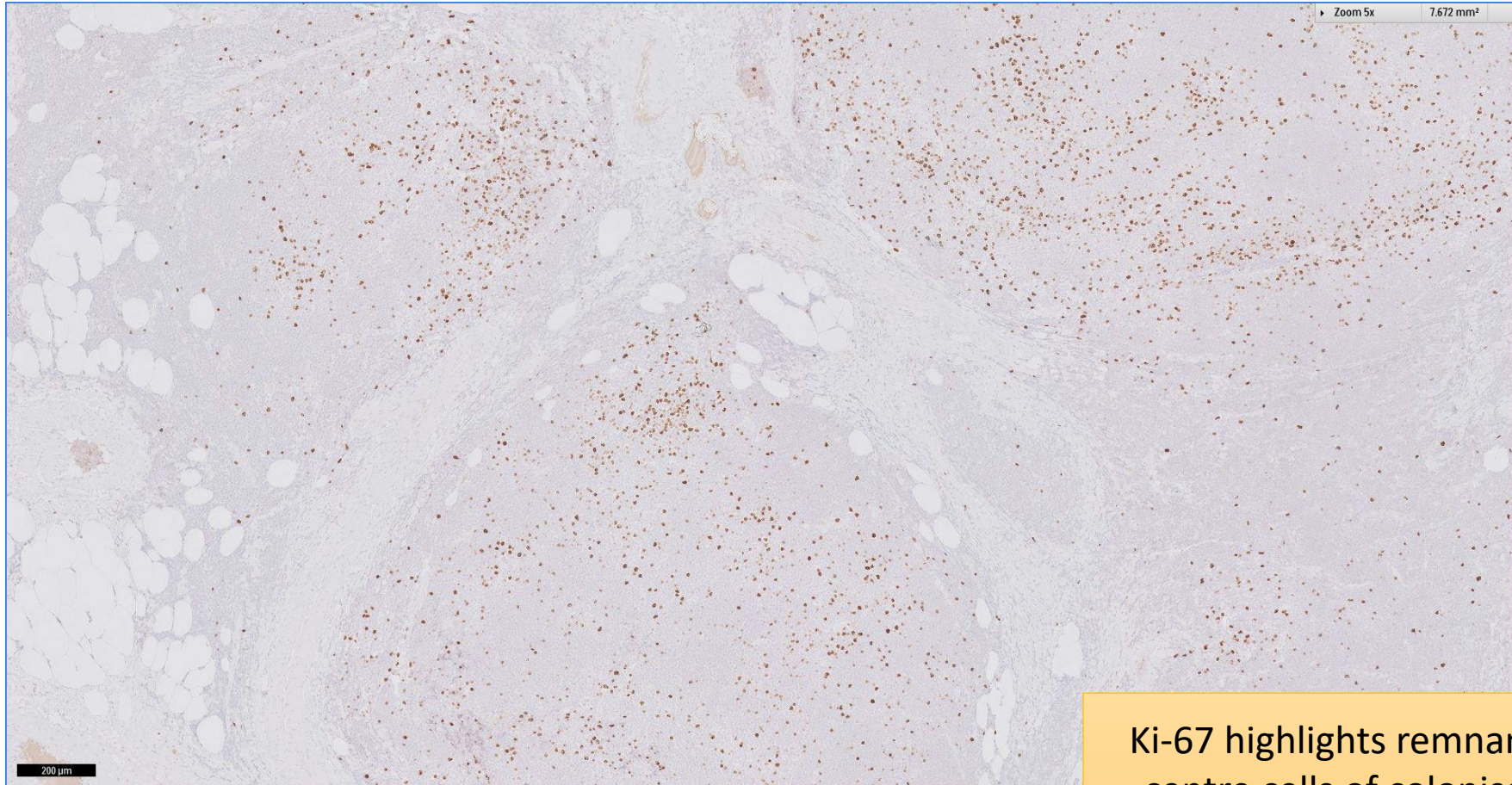
Pervasive, expanded and irregular  
follicular dendritic meshworks

# SGH CASE 39: 17RE163 LYMPH NODE CD23



Pervasive, expanded and irregular  
follicular dendritic meshworks

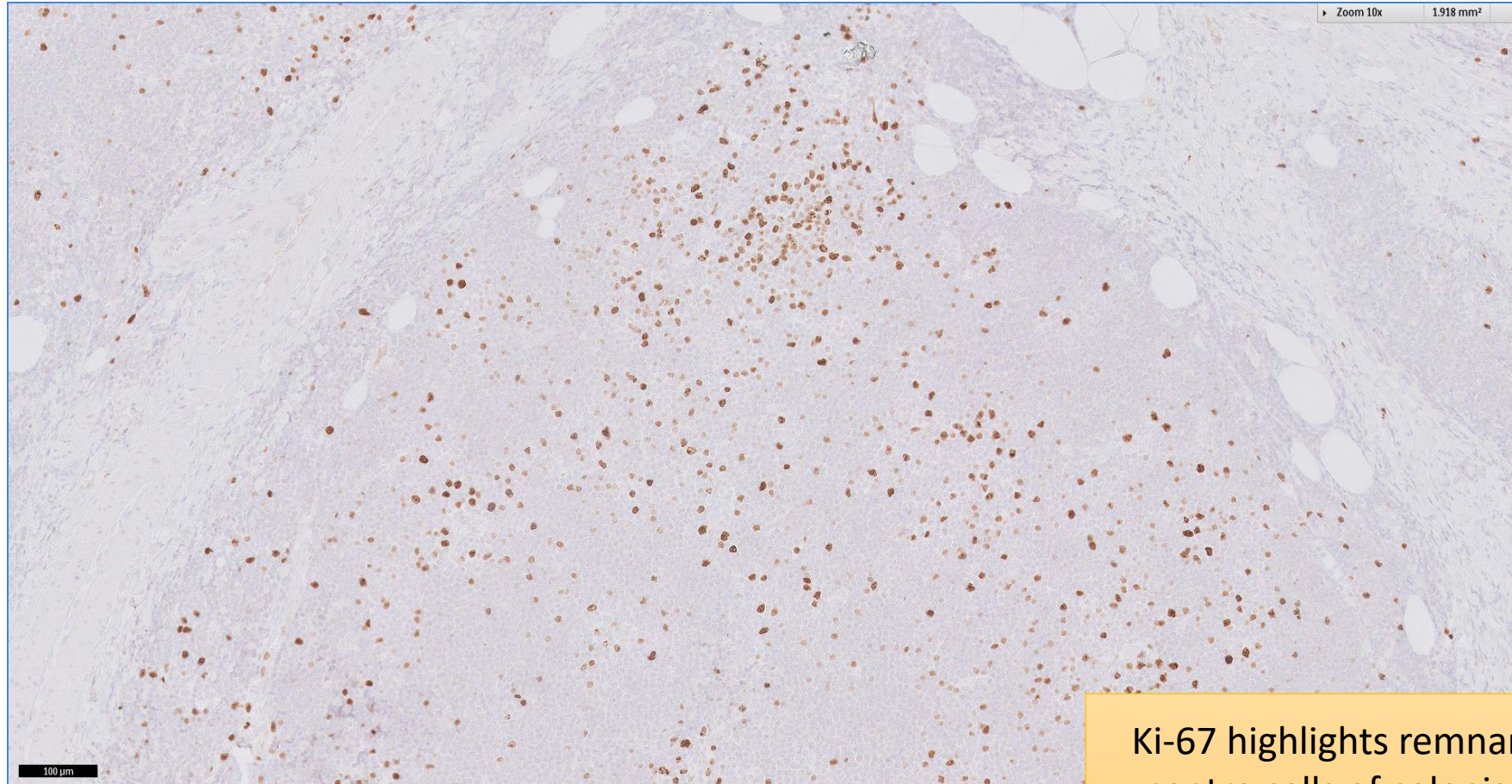
# SGH CASE 39: 17RE163 LYMPH NODE KI67



Ki-67 highlights remnant germinal centre cells of colonised follicles within the nodules

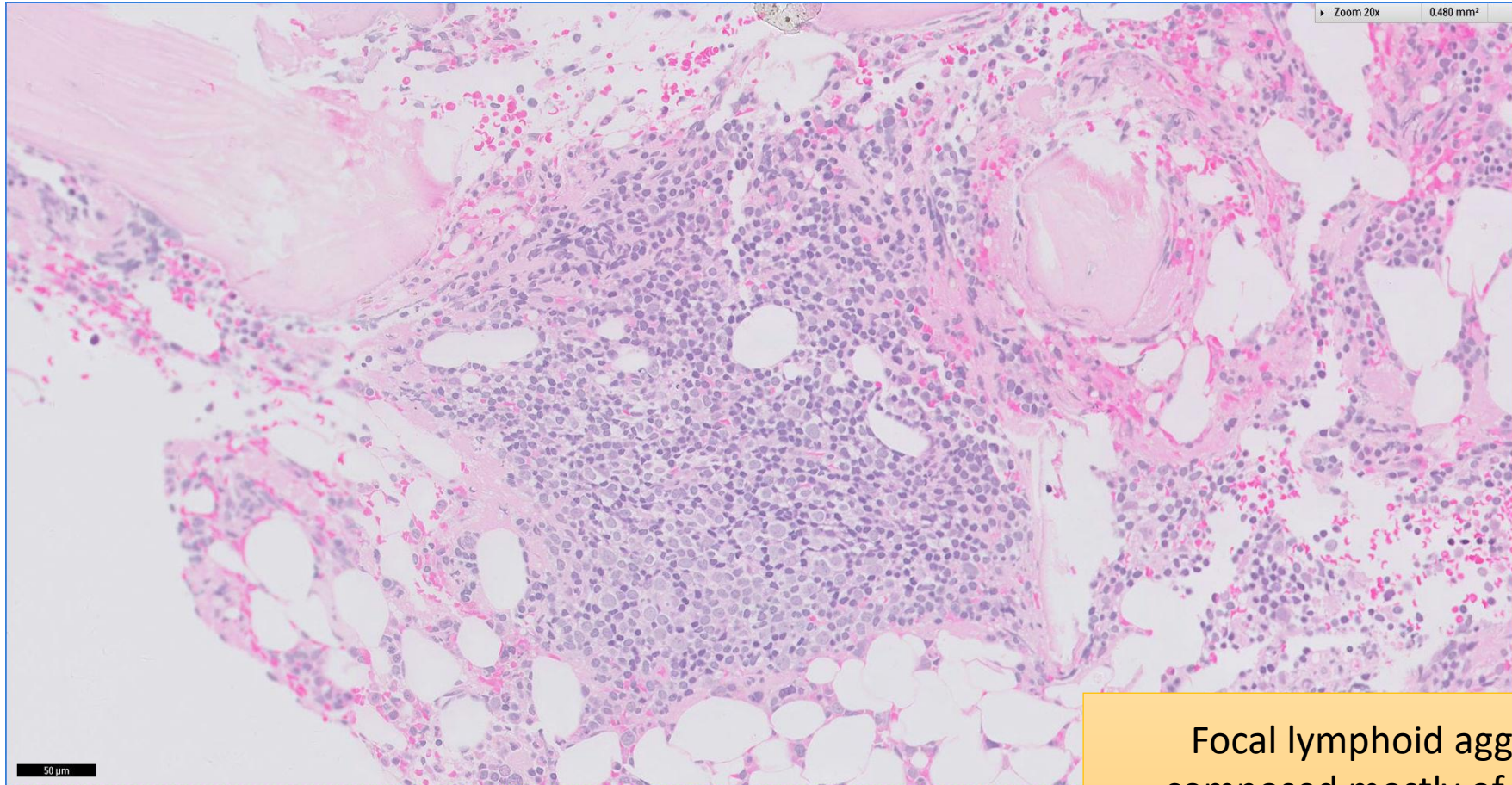


# SGH CASE 39: 17RE163 LYMPH NODE KI67



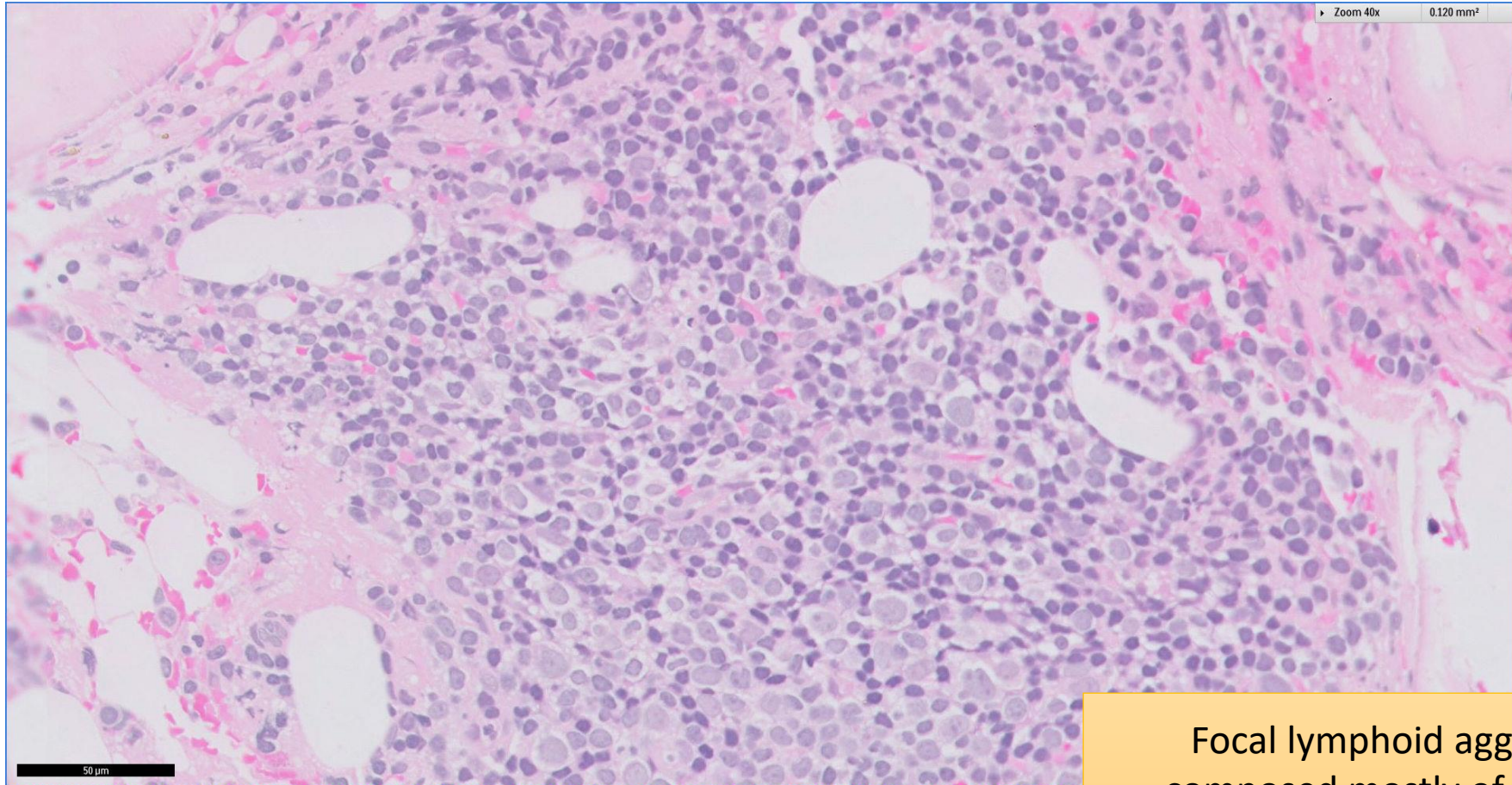
Ki-67 highlights remnant germinal  
centre cells of colonised follicles  
within the nodules

# SGH CASE 39: 17RE164 BONE MARROW H&E



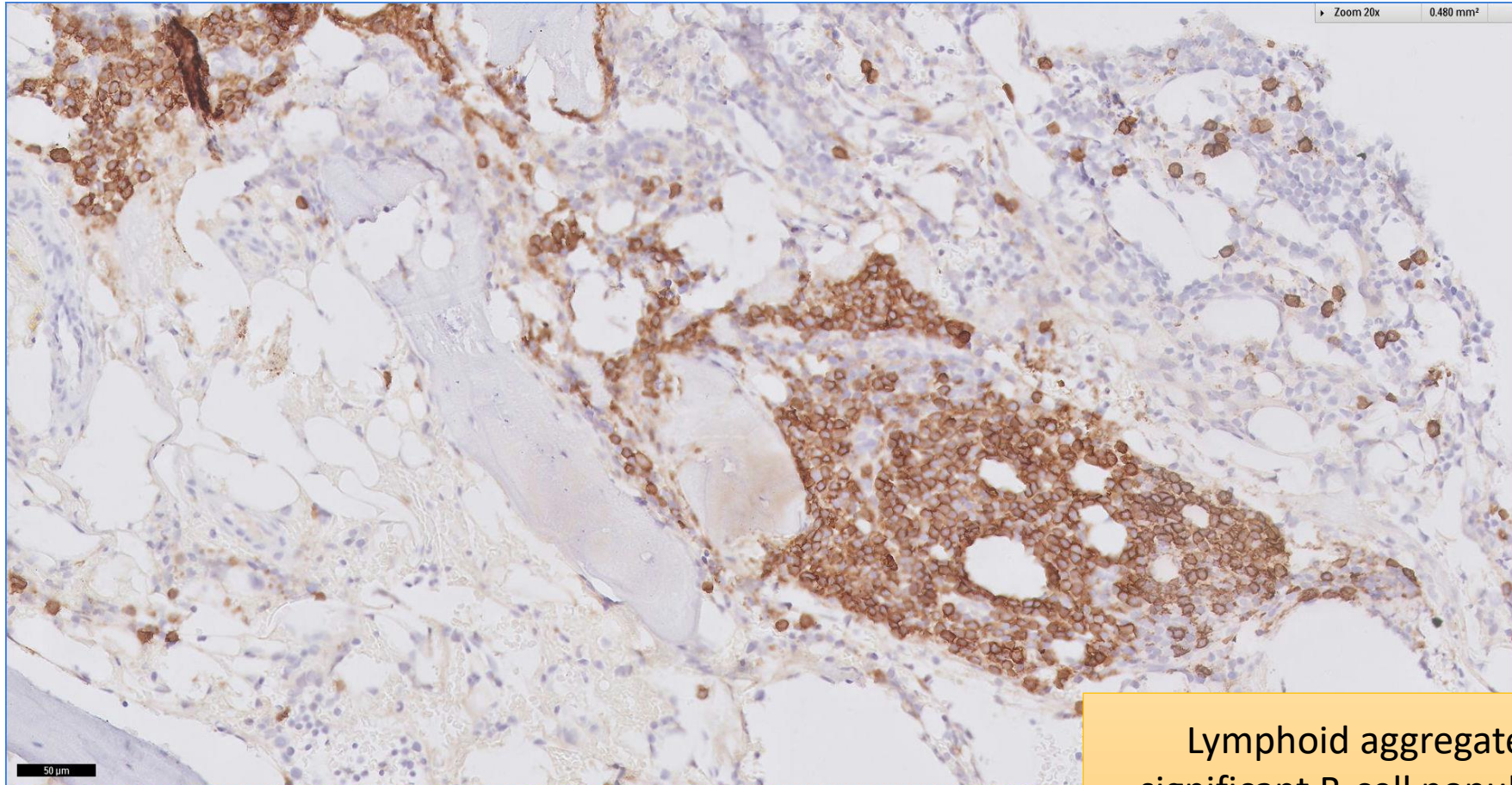
Focal lymphoid aggregates  
composed mostly of small-to-  
medium sized lymphocytes

# SGH CASE 39: 17RE164 BONE MARROW H&E



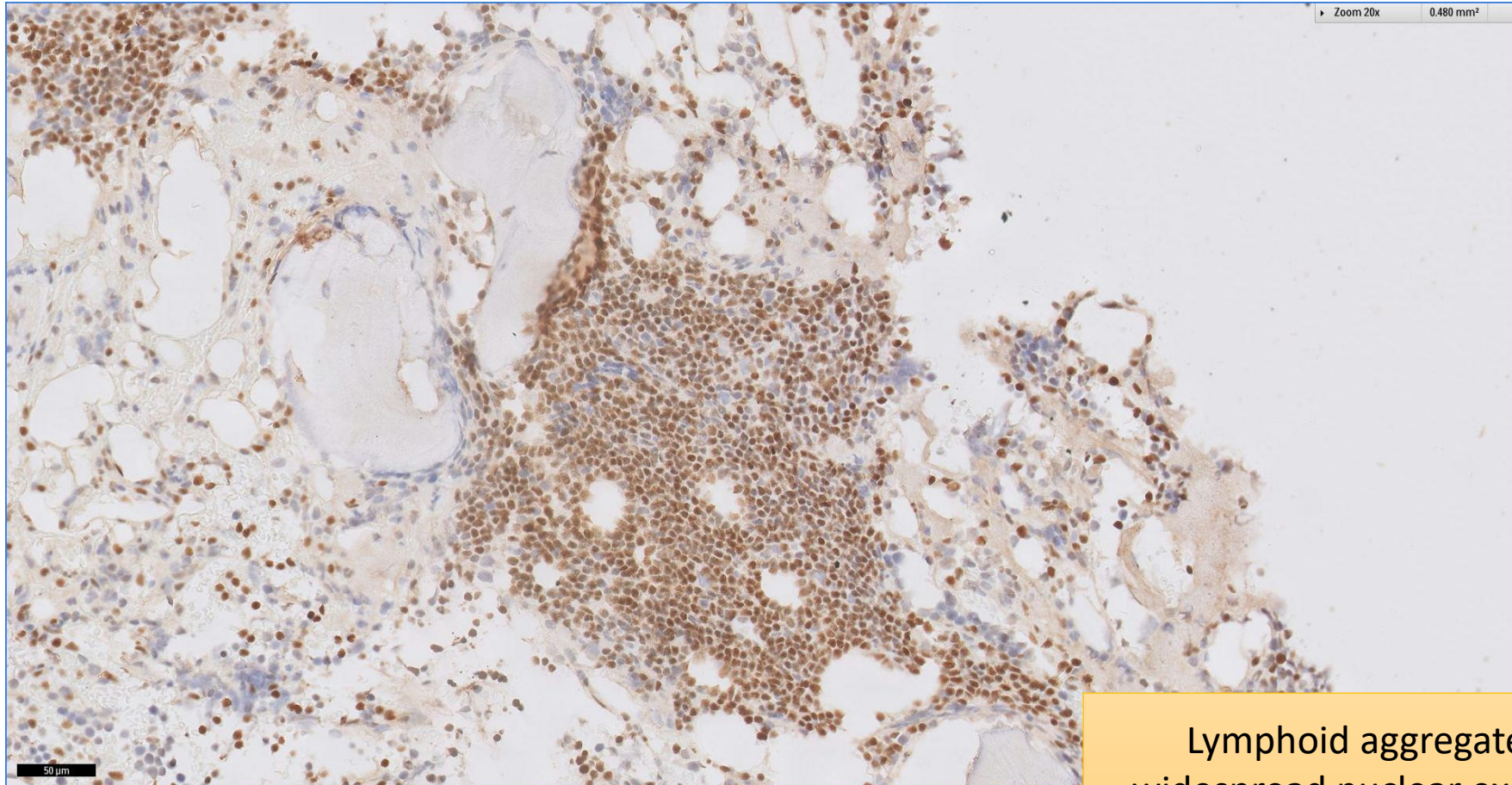
Focal lymphoid aggregates  
composed mostly of small-to-  
medium sized lymphocytes

# SGH CASE 39: 17RE164 BONE MARROW CD20



Lymphoid aggregate shows significant B-cell population with paratrabecular localisation

# SGH CASE 39: 17RE164 BONE MARROW P27



Lymphoid aggregate shows  
widespread nuclear expression of  
p27

# SGH CASE 39: 17RE163 & 17RE164

- Diagnosis
  - 17RE163: Nodal marginal zone lymphoma in lymph node
  - 17RE164: Bone marrow involved by marginal zone lymphoma.