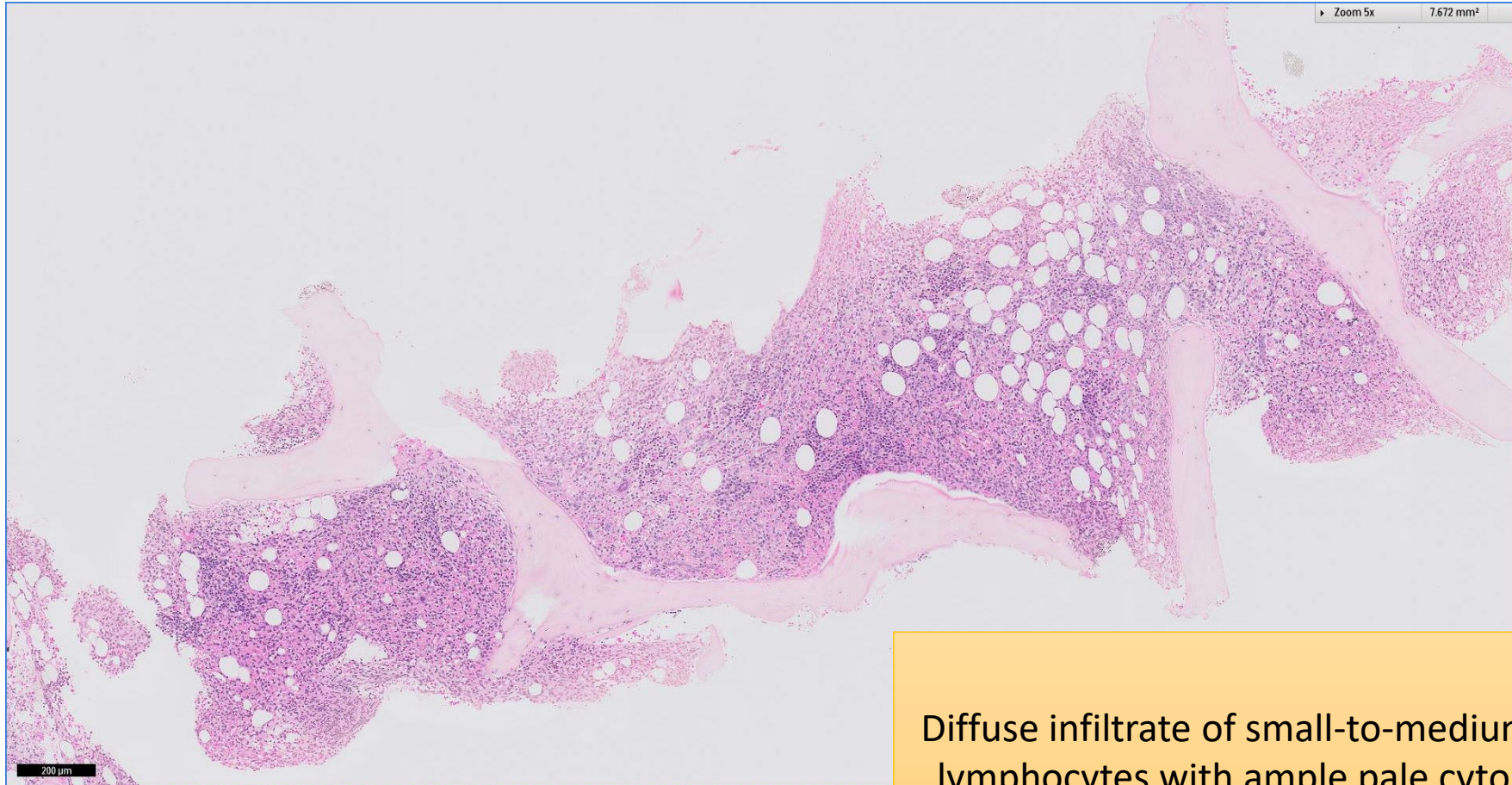


SGH CASE 30: 17RE149

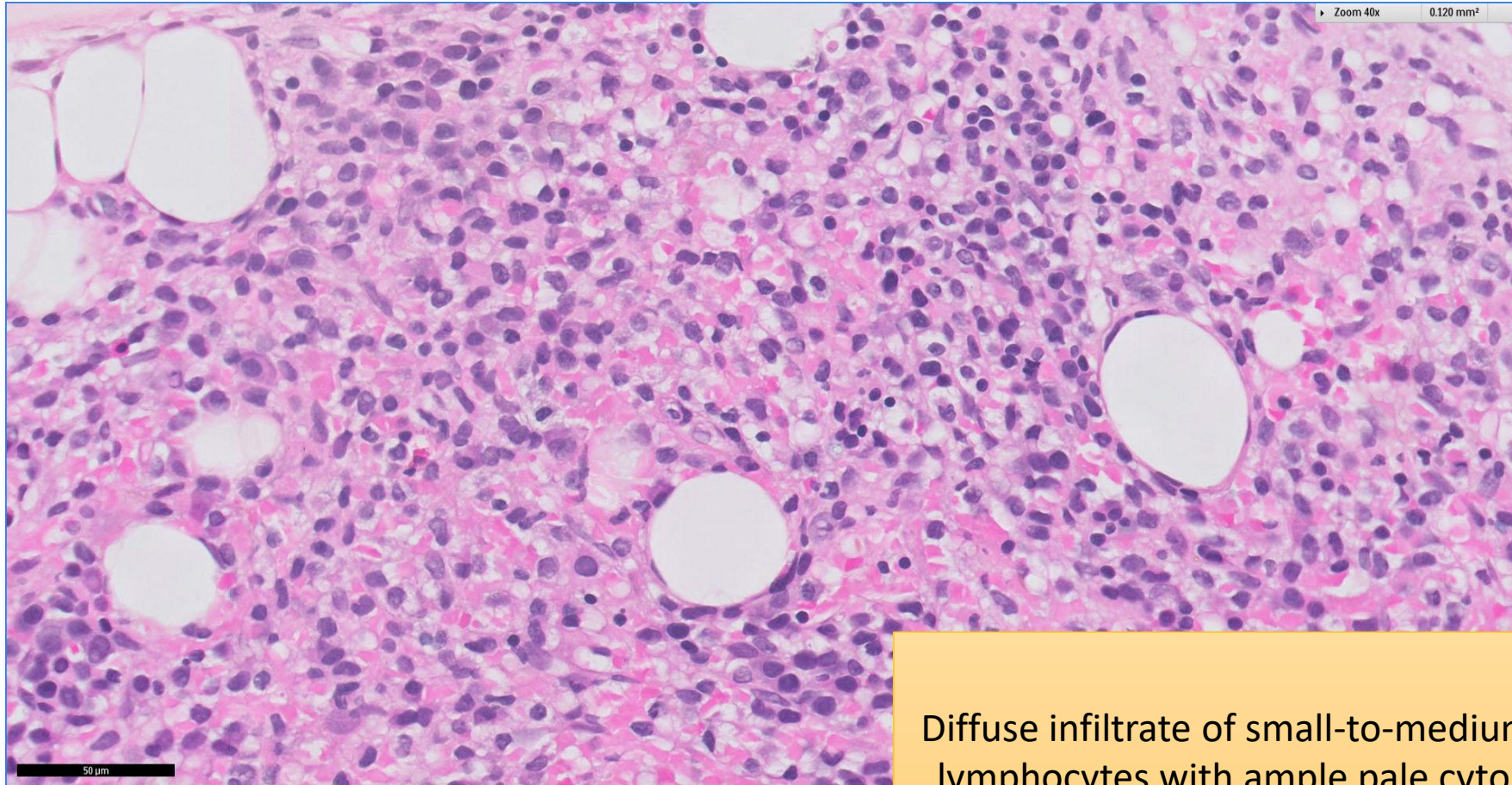
- Clinical History:
 - 50+ years old, Female. Pancytopenia. Dry tap on bone marrow aspirate.
- Specimen:
 - Bone marrow trephine biopsy

SGH CASE 30: 17RE149 H&E



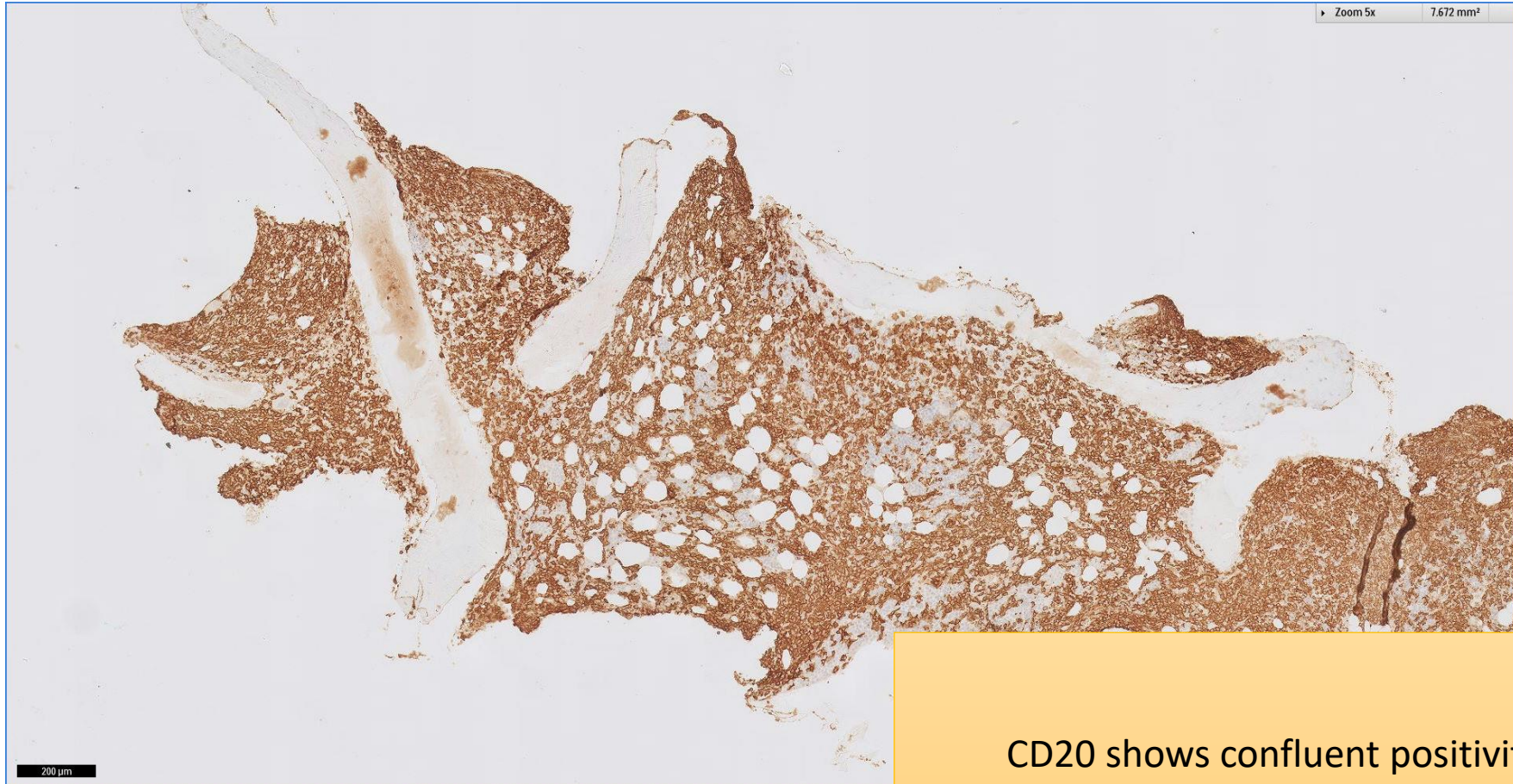
Diffuse infiltrate of small-to-medium sized lymphocytes with ample pale cytoplasm

SGH CASE 30: 17RE149 H&E



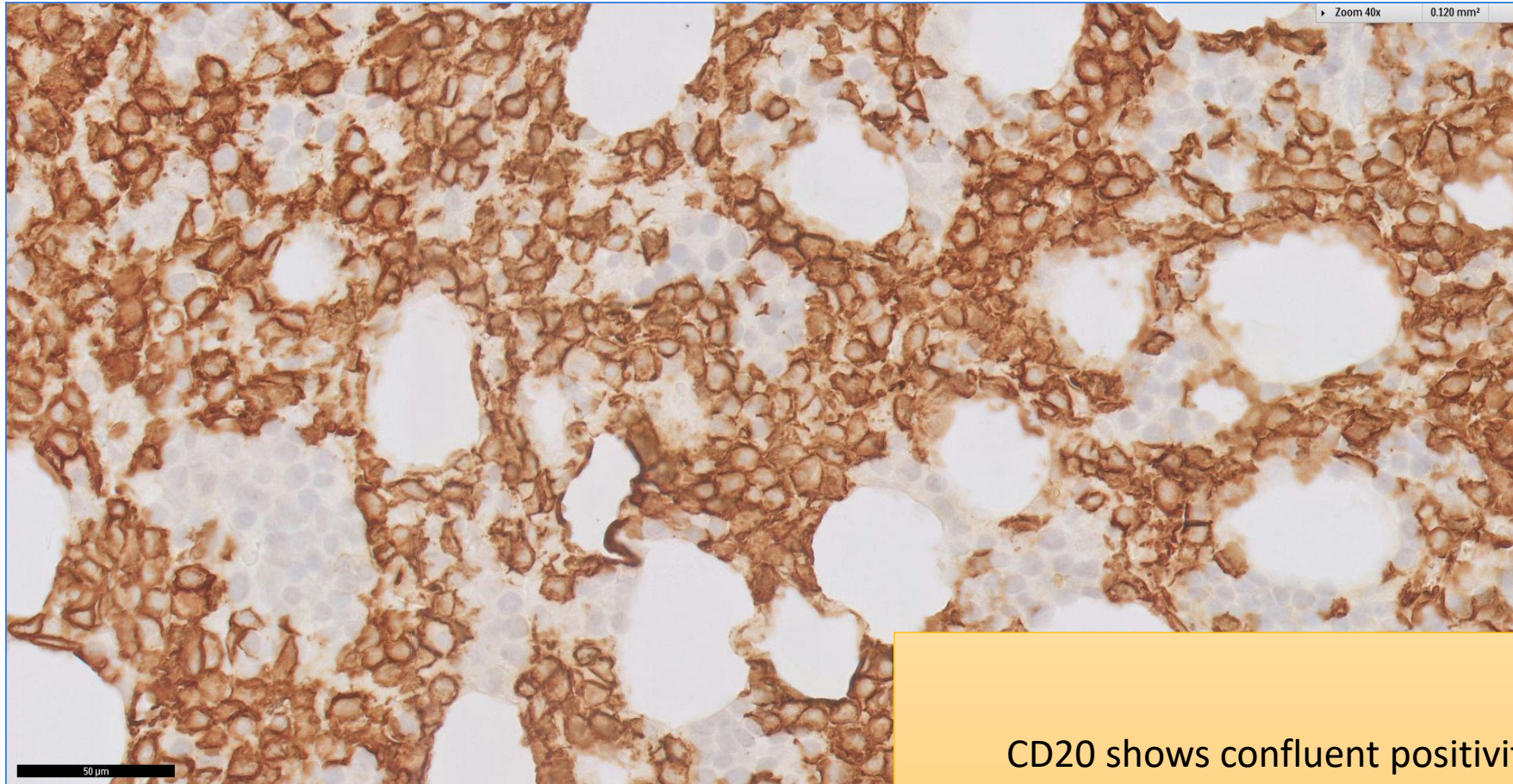
Diffuse infiltrate of small-to-medium sized lymphocytes with ample pale cytoplasm

SGH CASE 30: 17RE149 CD20



CD20 shows confluent positivity

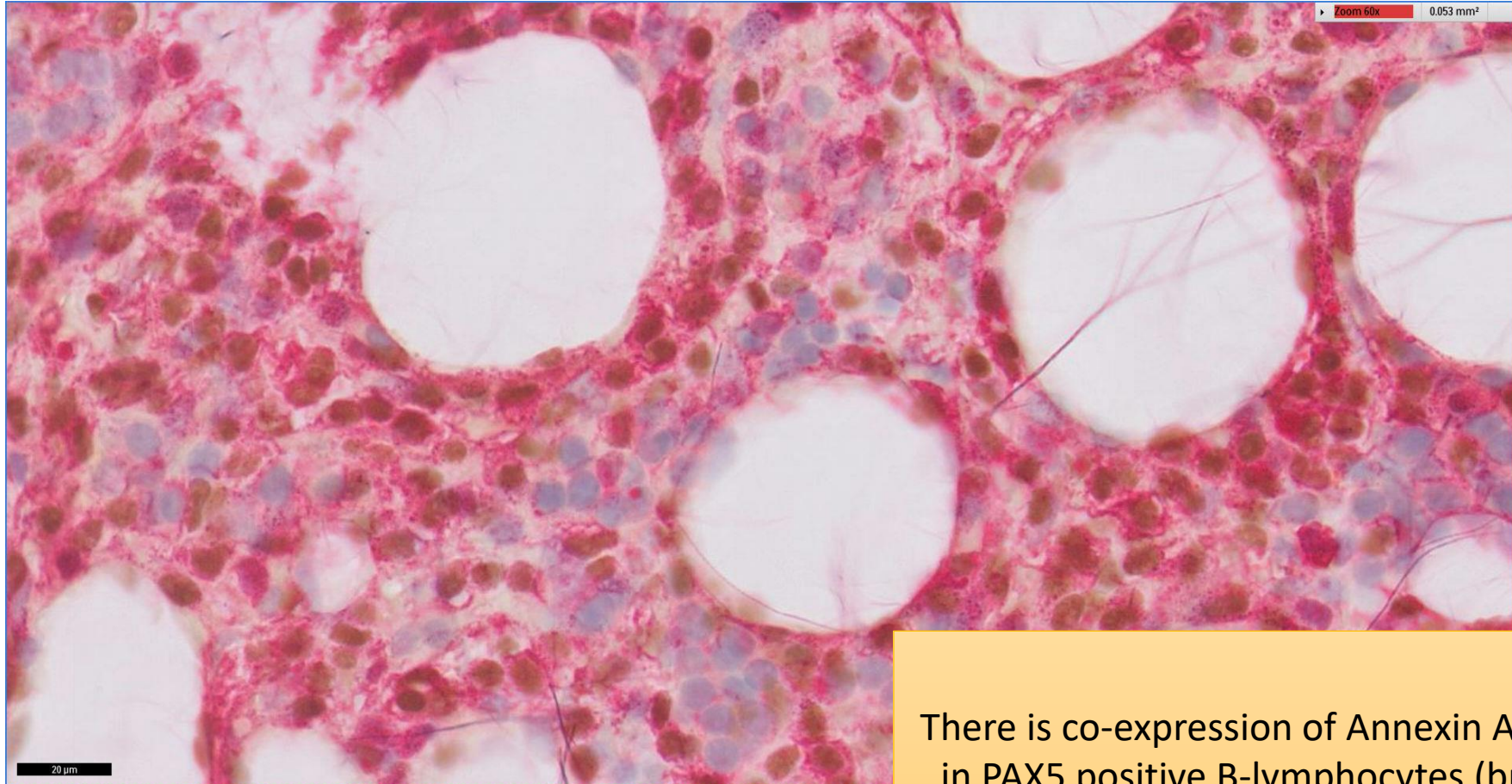
SGH CASE 30: 17RE149 CD20



CD20 shows confluent positivity

SGH CASE 30: 17RE149

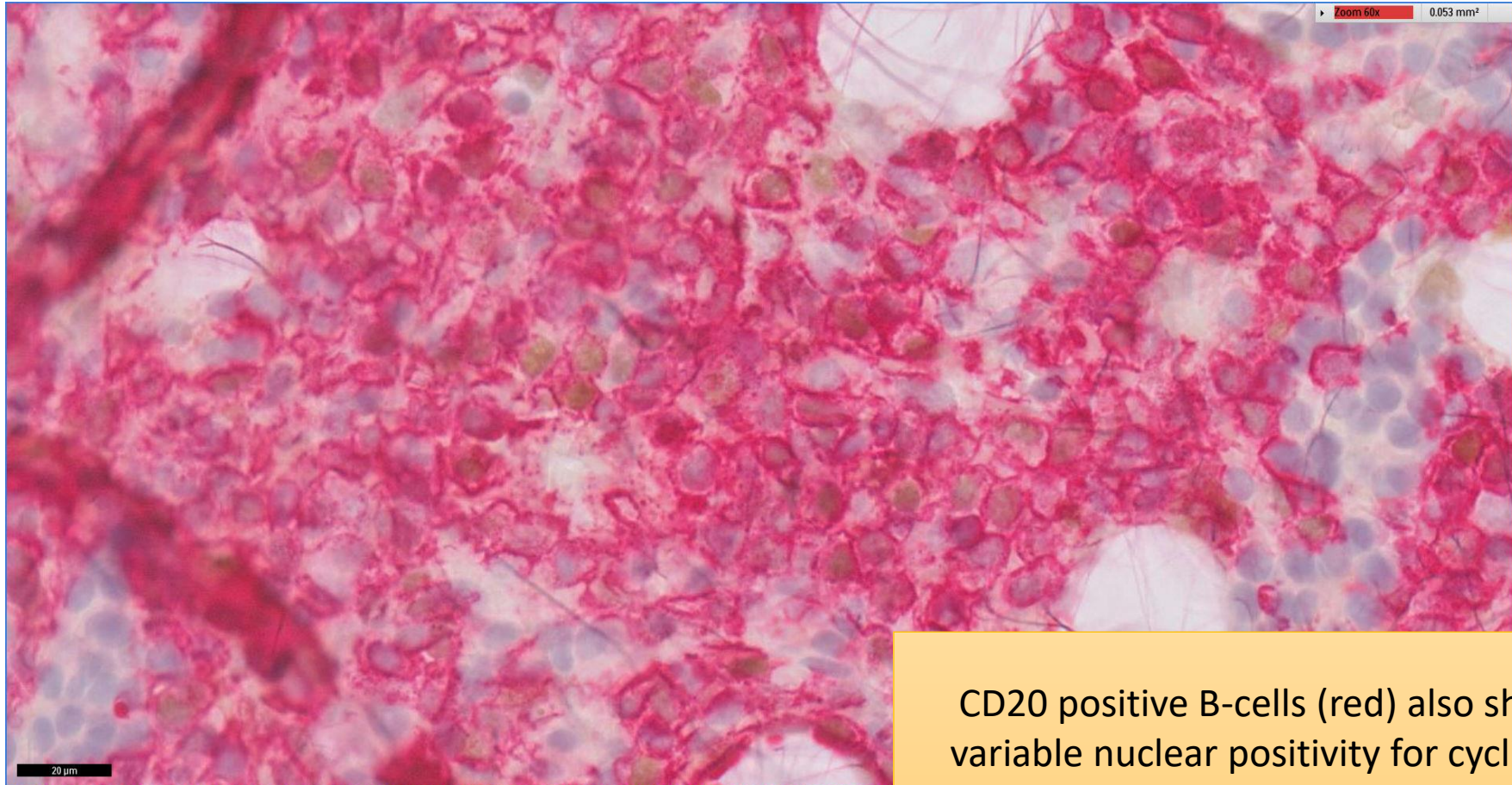
ANNEXIN A1 (RED) PAX5 (BROWN)



There is co-expression of Annexin A1 (red)
in PAX5 positive B-lymphocytes (brown)

SGH CASE 30: 17RE149

CYCLIN D1 (BROWN) CD20 (RED)



CD20 positive B-cells (red) also shows variable nuclear positivity for cyclin D1 (brown)

SGH CASE 30: 17RE149

- Diagnosis
 - Hairy Cell Leukaemia