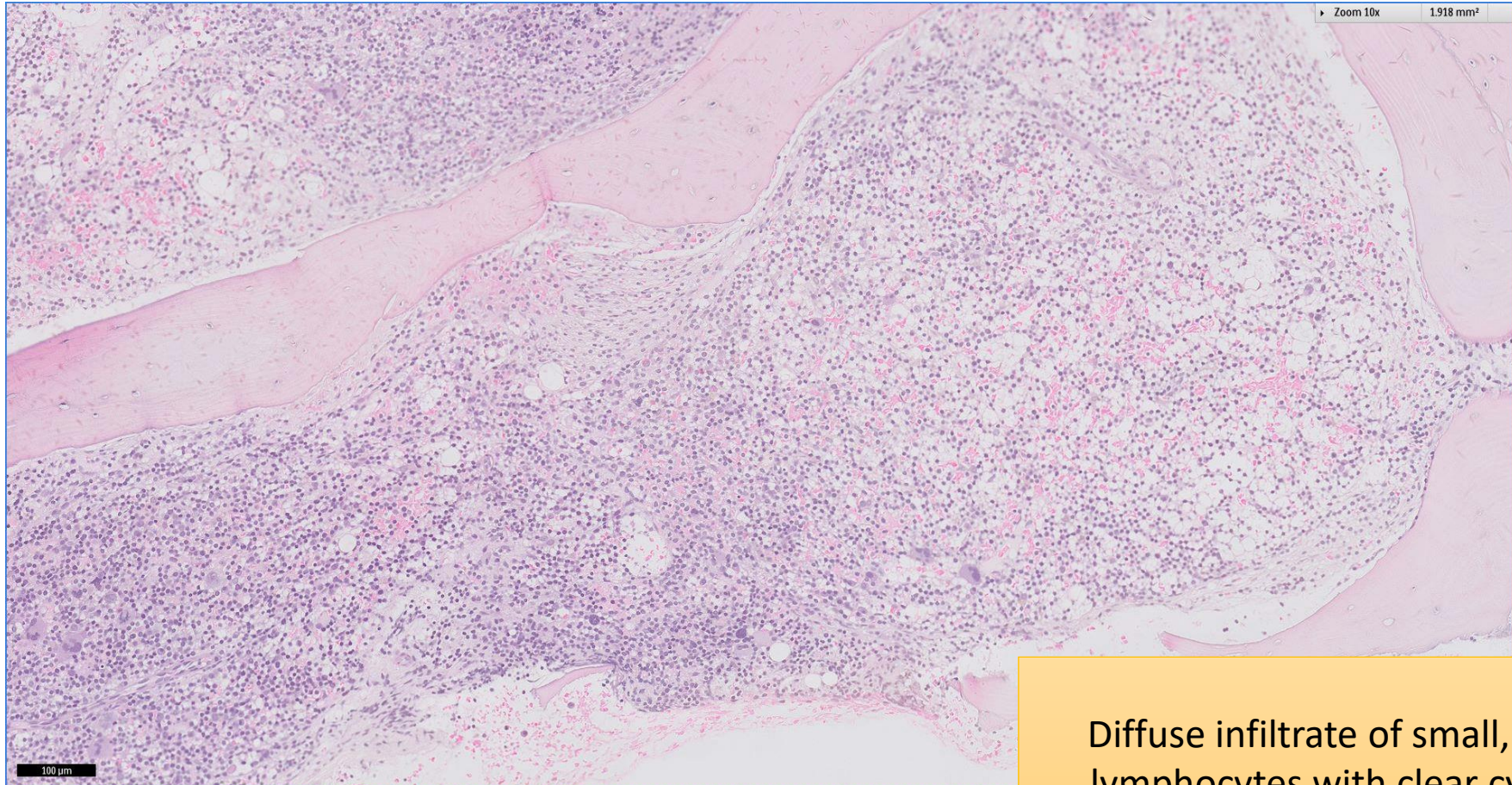


# SGH CASE 23: 17RE140

- Clinical History:
  - 60+ years old, Male. Atypical lymphocytes (29%) on peripheral blood smear.
- Specimen:
  - Bone marrow trephine biopsy

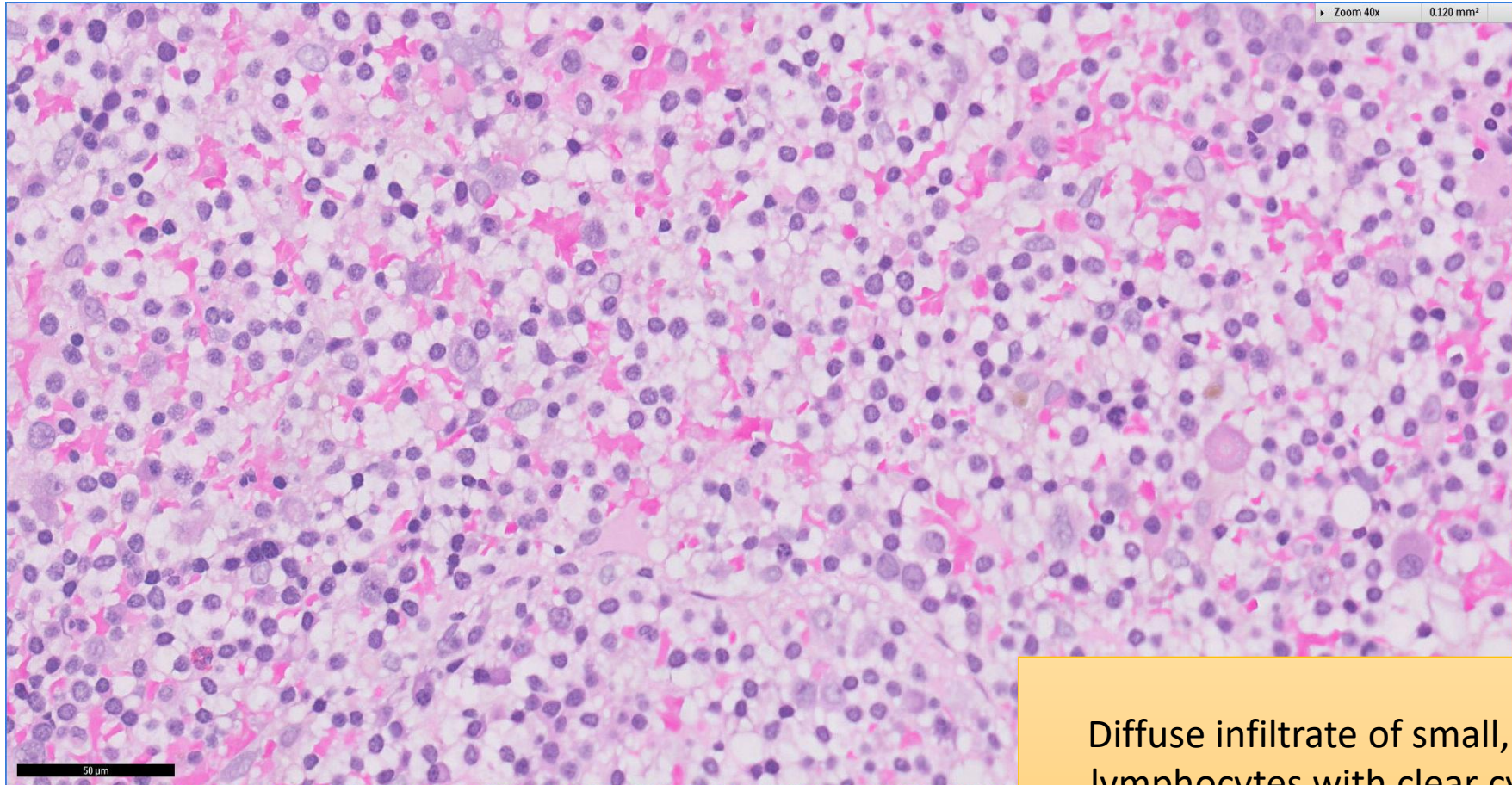
# SGH CASE 23: 17RE140 H&E



Diffuse infiltrate of small, irregular lymphocytes with clear cytoplasm

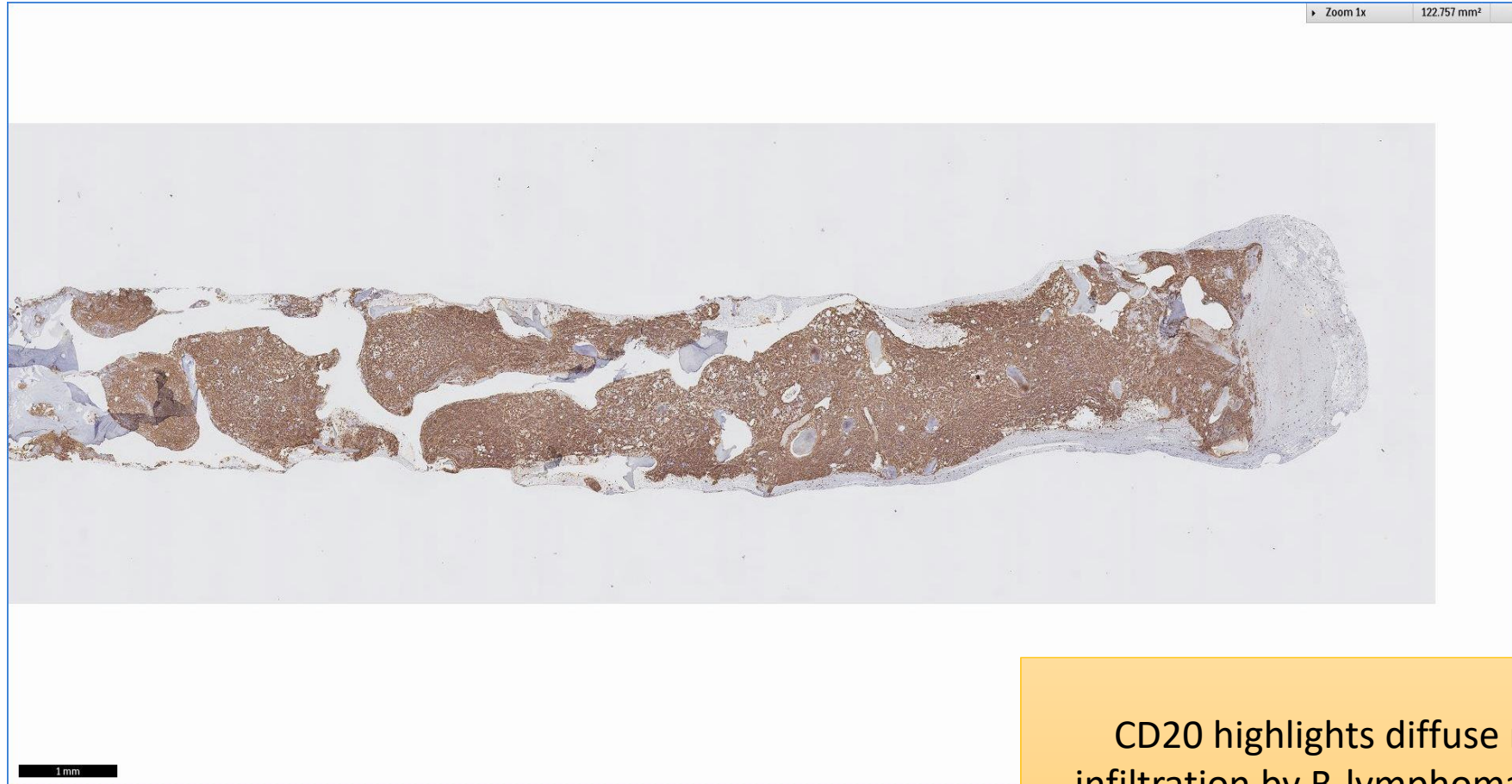

# SGH CASE 23: 17RE140 H&E



Diffuse infiltrate of small, irregular lymphocytes with clear cytoplasm

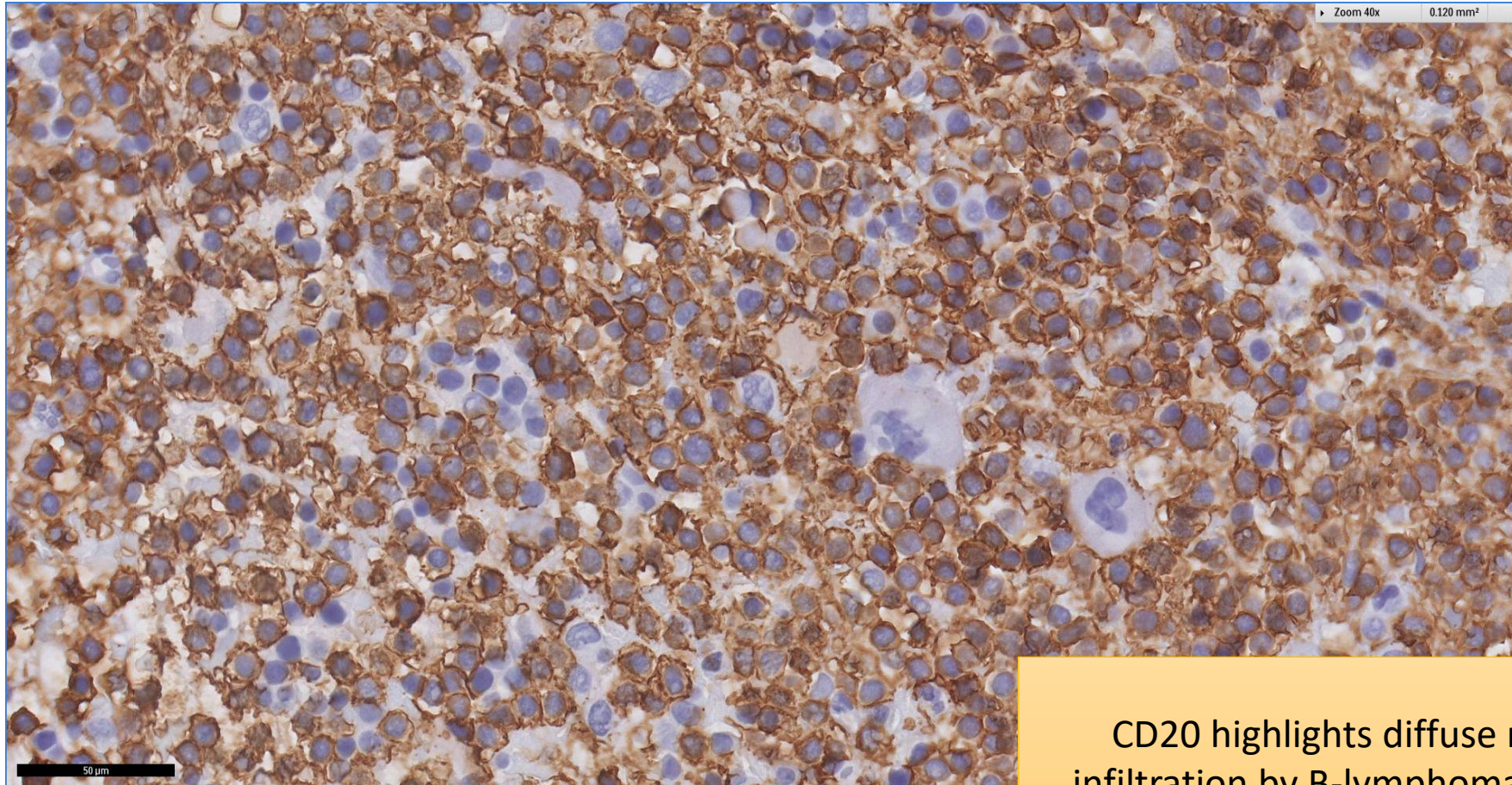
# SGH CASE 23: 17RE140 CD20



CD20 highlights diffuse marrow infiltration by B-lymphomatous cells



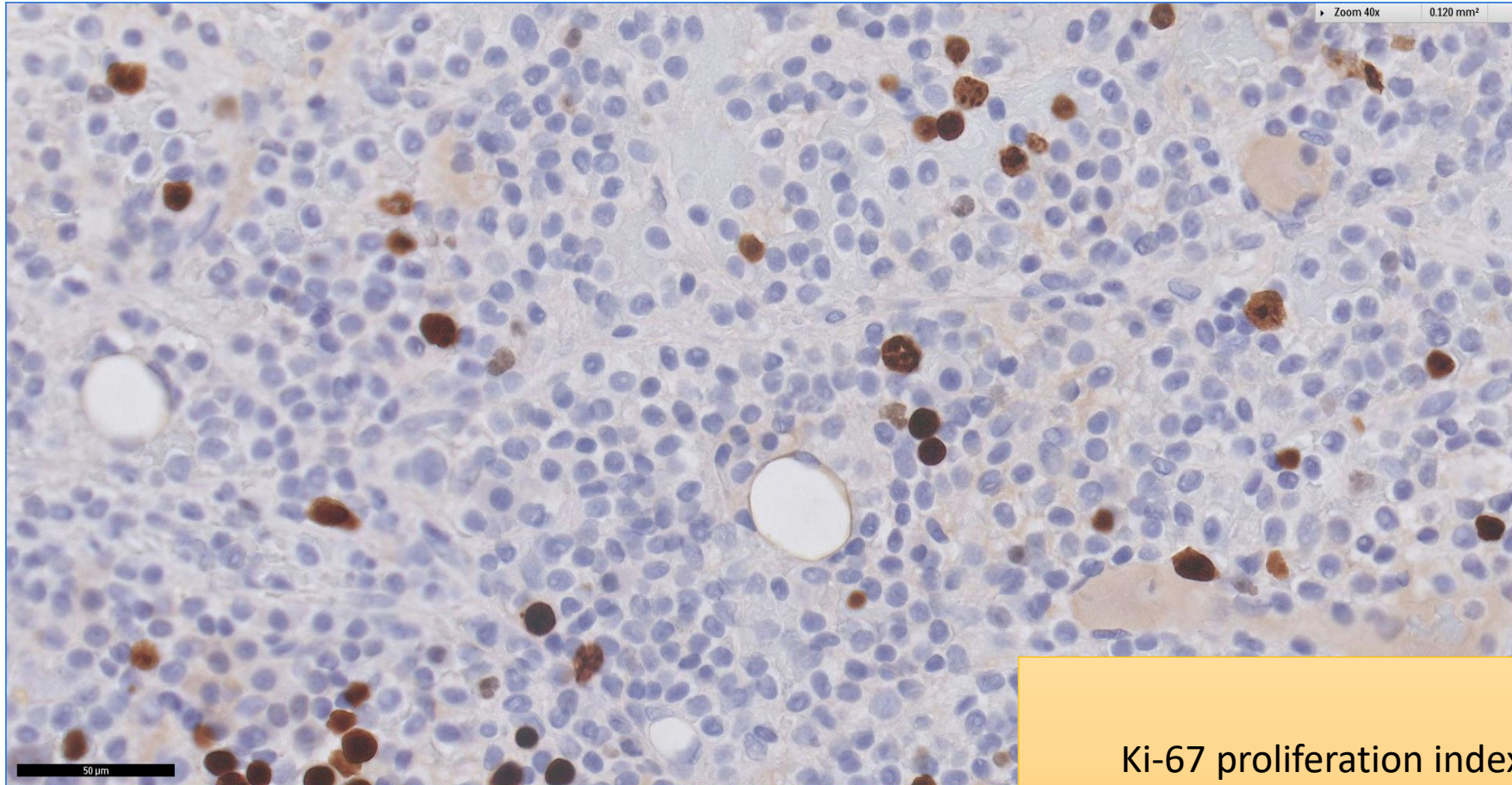
# SGH CASE 23: 17RE140 CD20



CD20 highlights diffuse marrow infiltration by B-lymphomatous cells



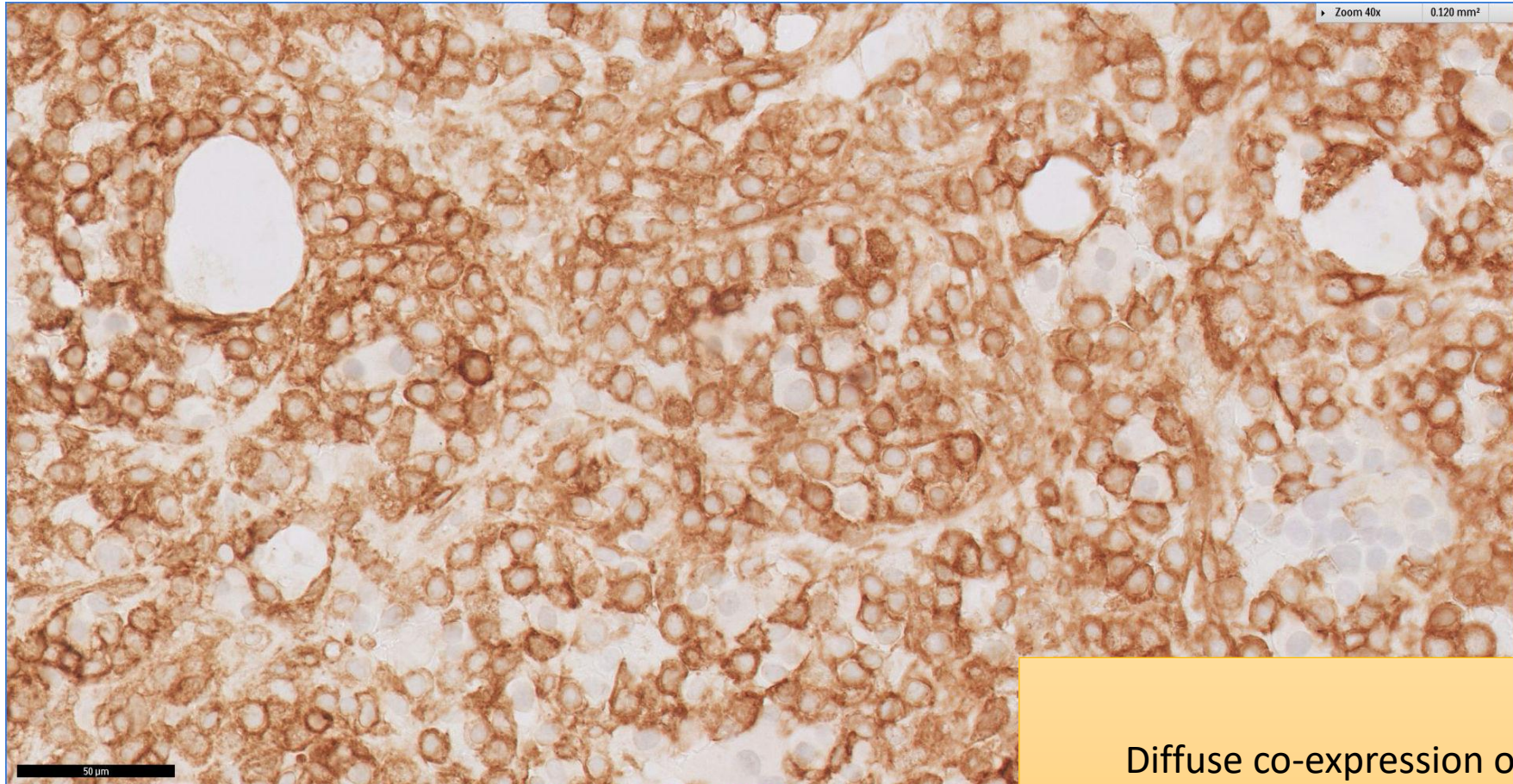
# SGH CASE 23: 17RE140 KI67



Ki-67 proliferation index is low



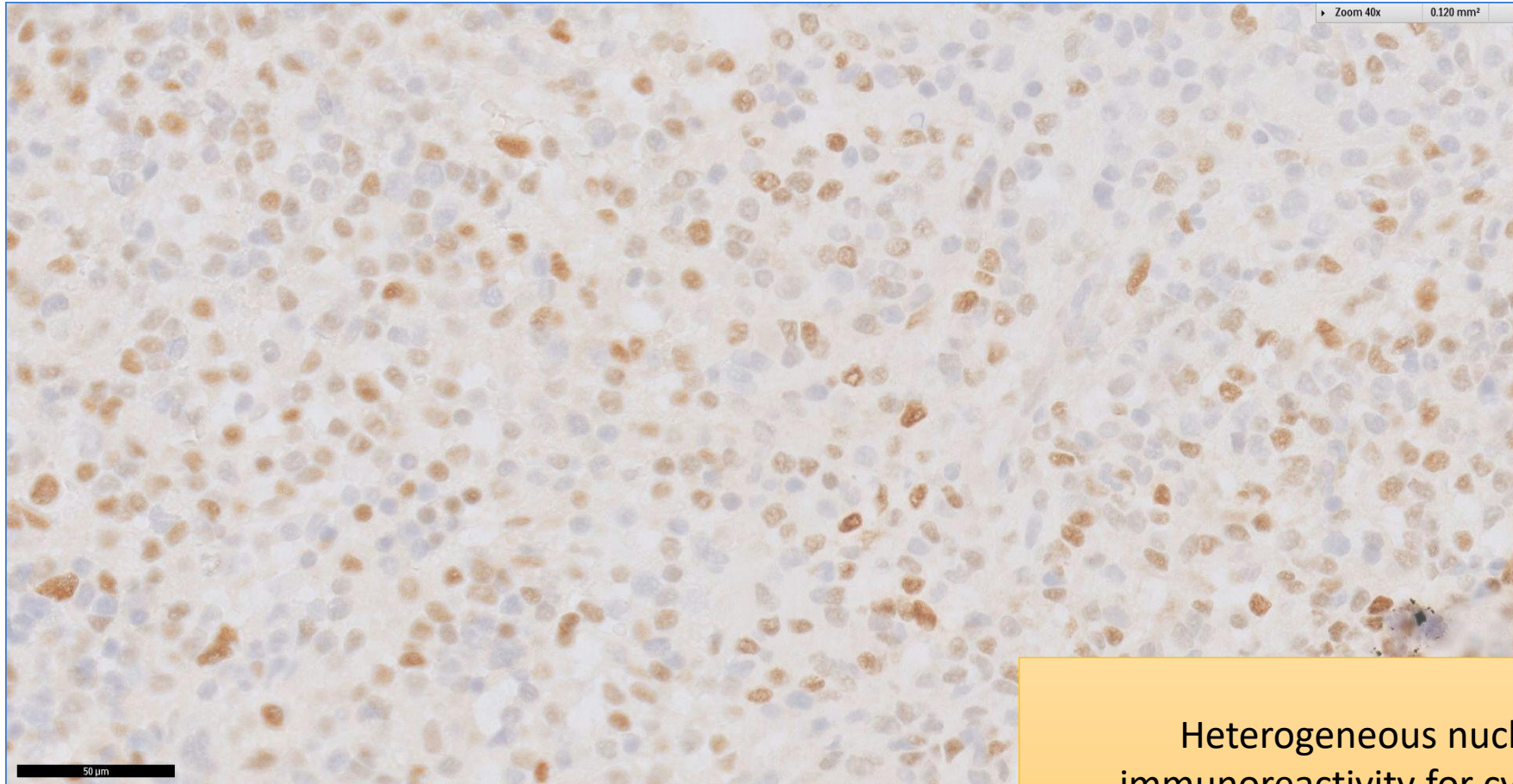
# SGH CASE 23: 17RE140 CD10



Diffuse co-expression of CD10



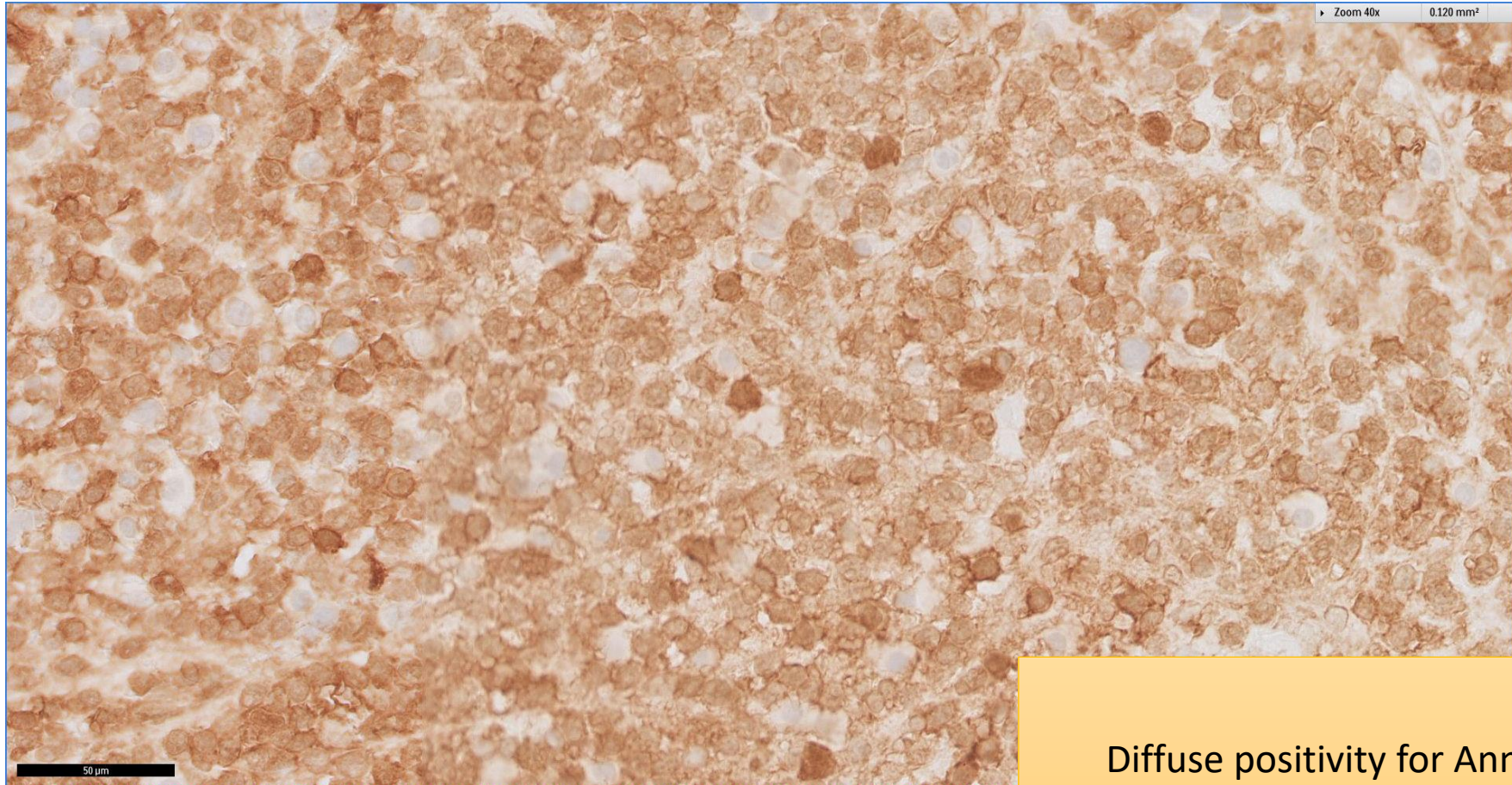
# SGH CASE 23: 17RE140 CYCLIN D1



Heterogeneous nuclear  
immunoreactivity for cyclin D1



# SGH CASE 23: 17RE140 ANNEXIN A1



Diffuse positivity for Annexin A1

# SGH CASE 23: 17RE140

- Diagnosis
  - Hairy Cell Leukaemia
  - CD10 positive