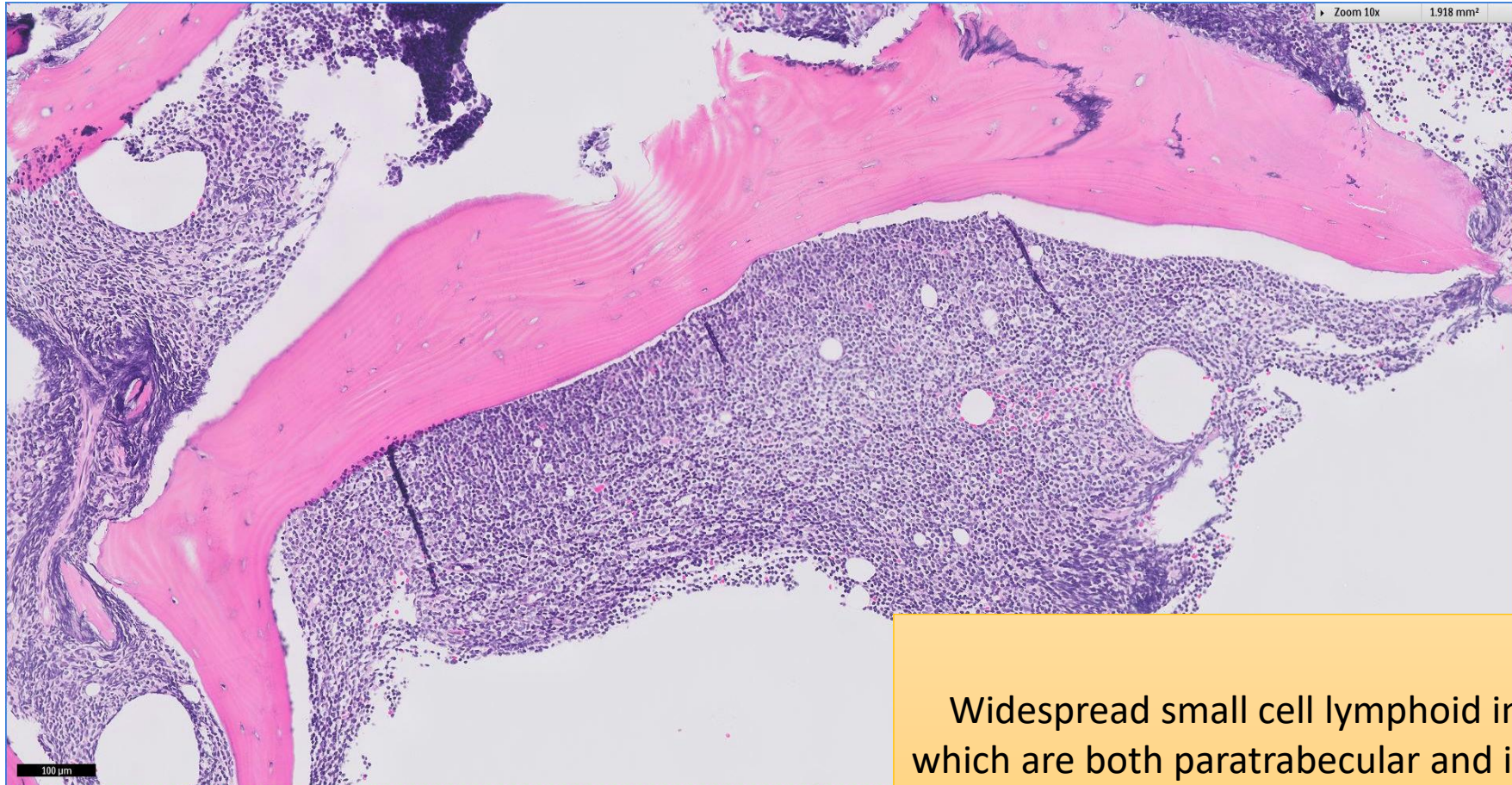


SGH CASE 14: 17RE120 & 17RE115

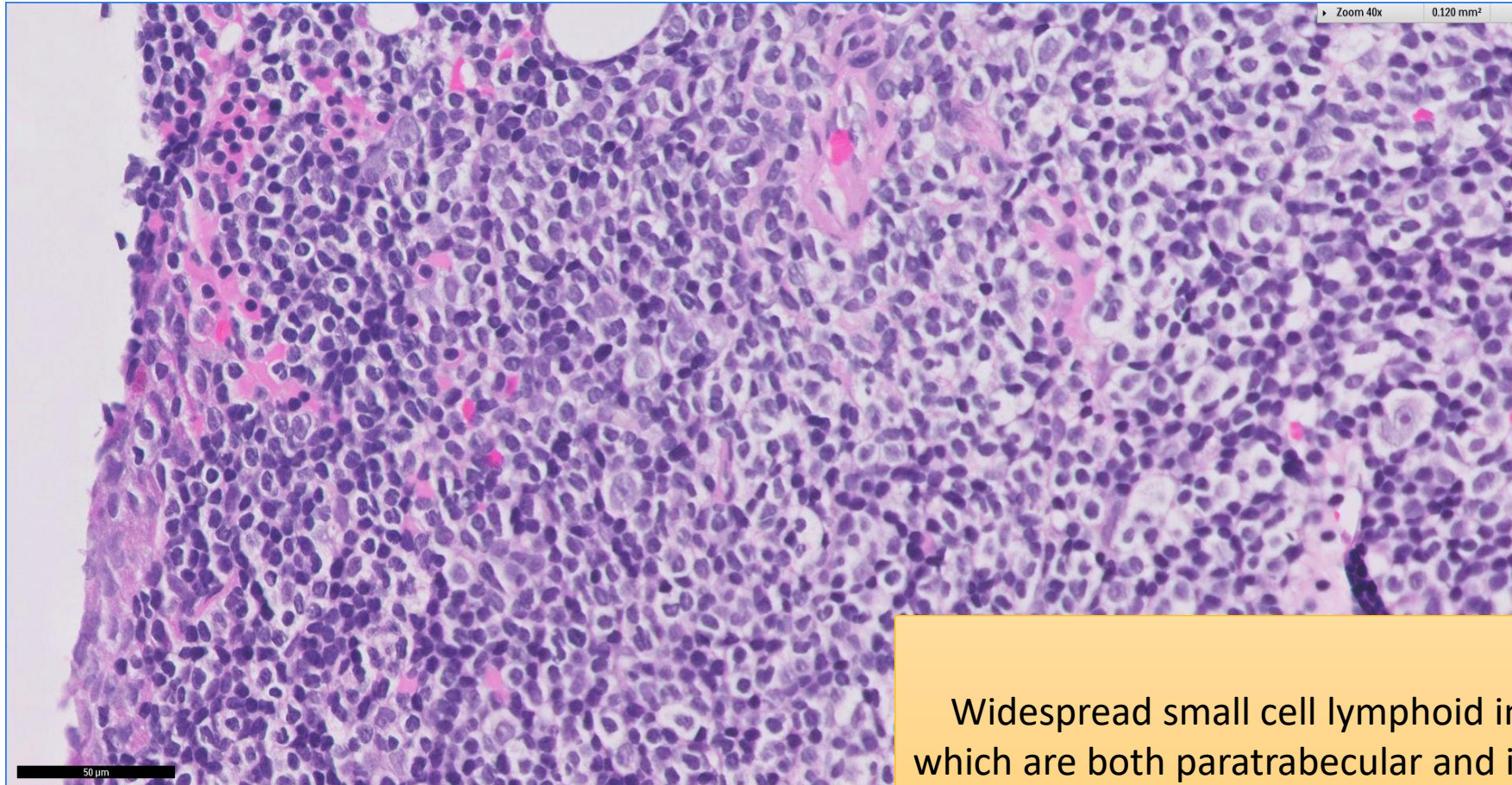
- Clinical History:
 - 60+ years old (late 60s). Male. Known history of lymphoma involving bone marrow diagnosed two years ago. Now with cervical lymphadenopathy.
- Specimen:
 - (17:RE120): Bone marrow trephine biopsy (4 months prior to lymph node biopsy)
 - (17:RE115): Right cervical lymph node excision biopsy

SGH CASE 14: 17RE120 BONE MARROW H&E



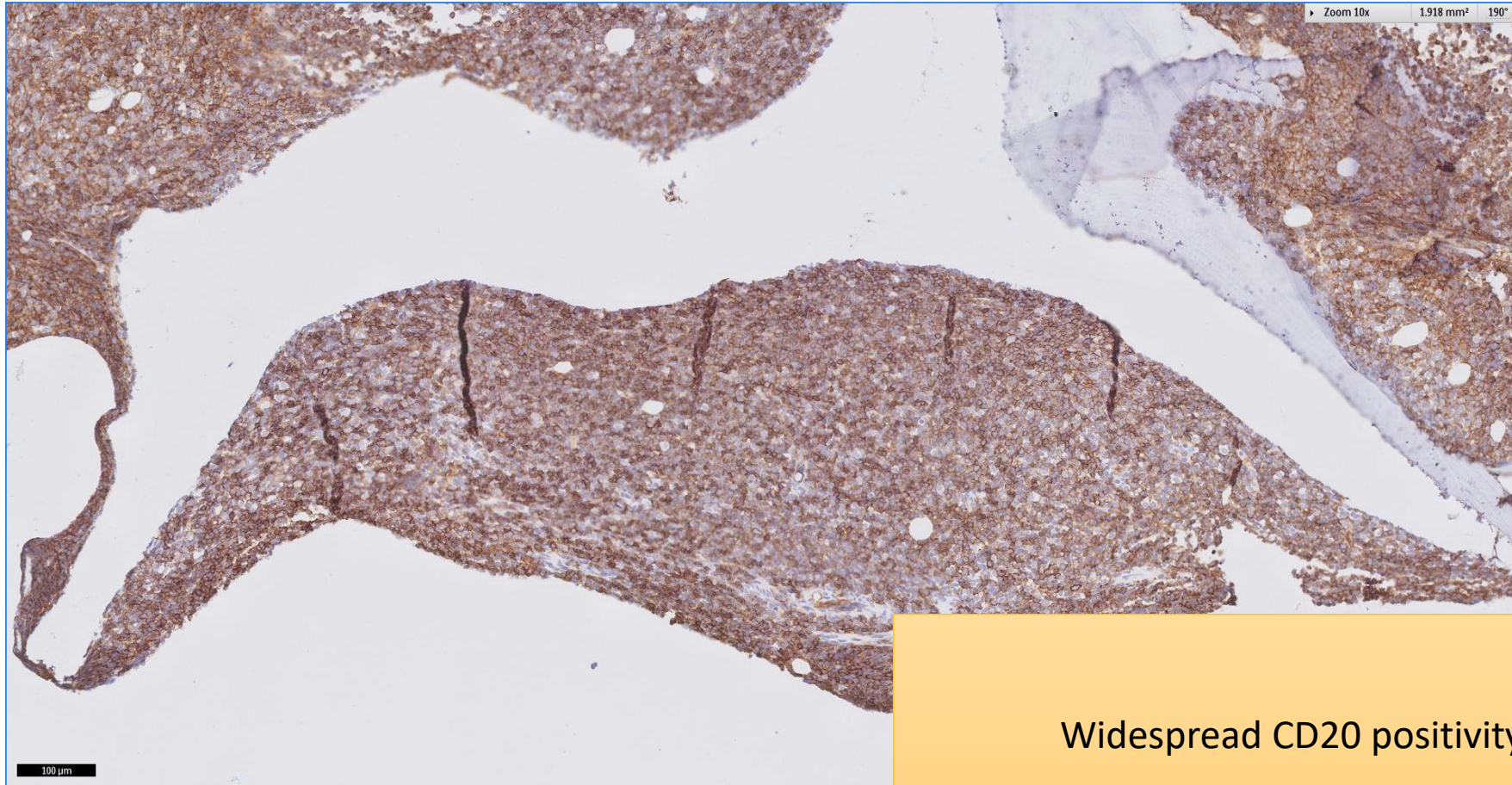
Widespread small cell lymphoid infiltrate
which are both paratrabecular and interstitial

SGH CASE 14: 17RE120 BONE MARROW H&E



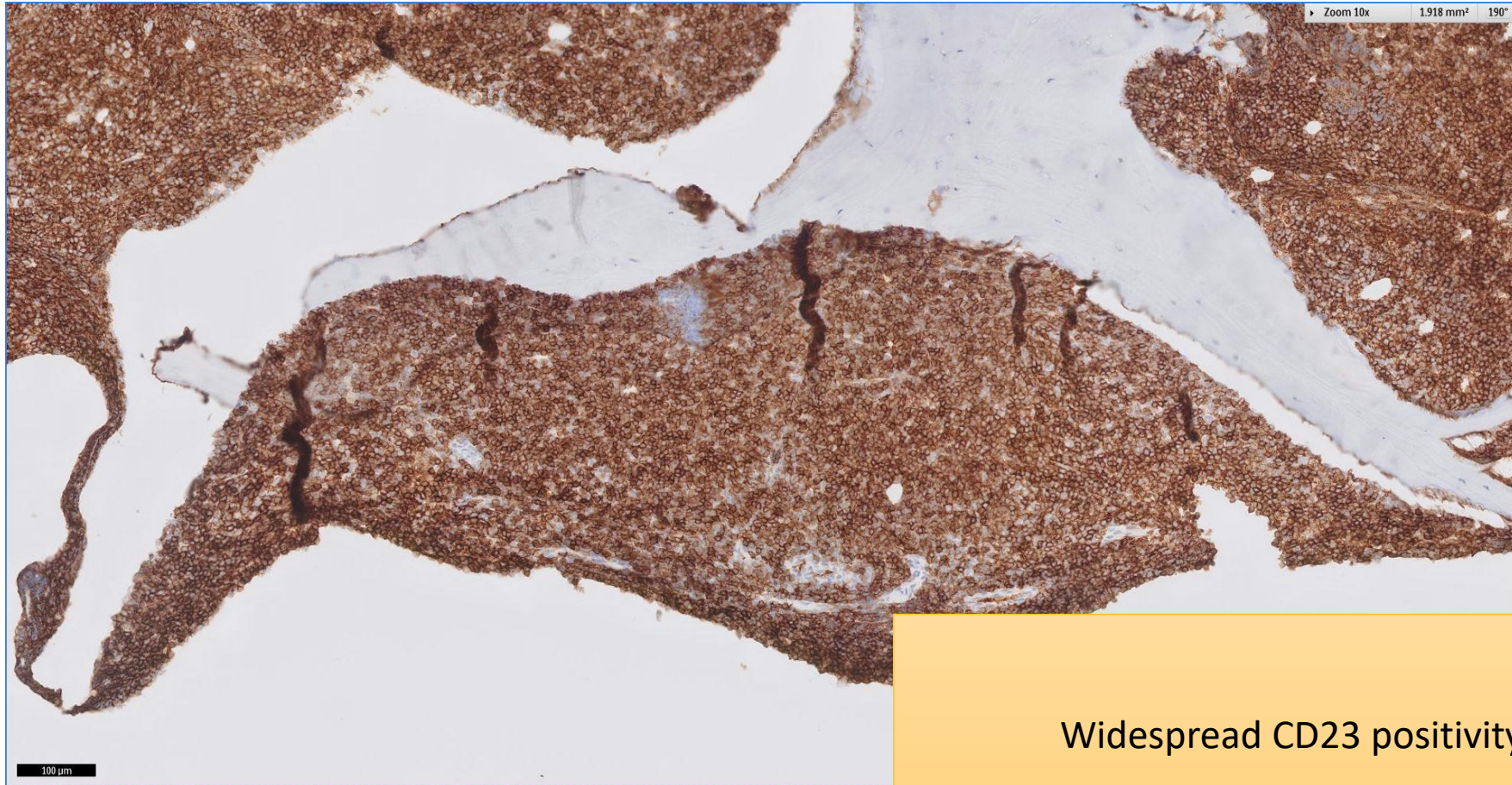
Widespread small cell lymphoid infiltrate
which are both paratrabecular and interstitial

SGH CASE 14: 17RE120 BONE MARROW CD20



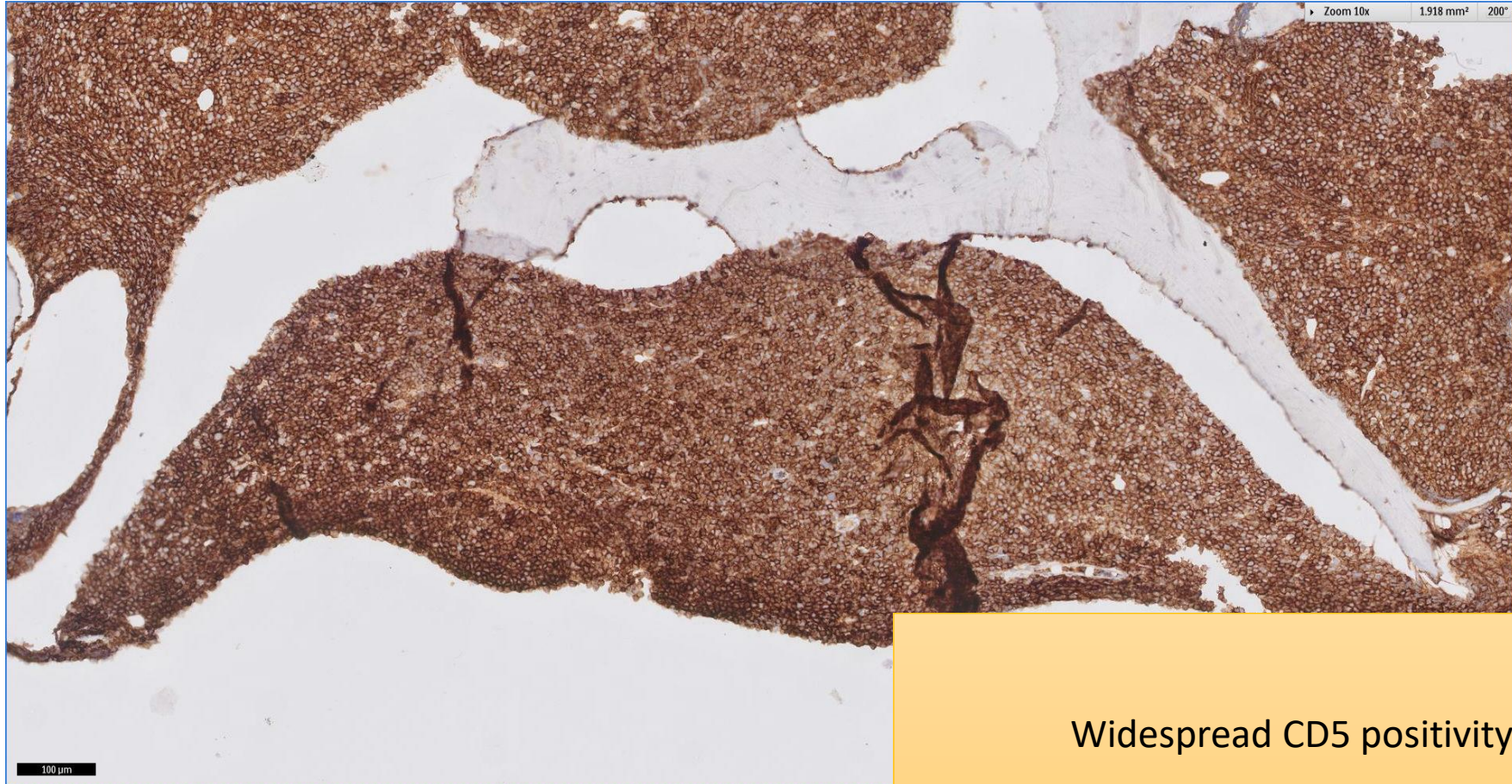
Widespread CD20 positivity

SGH CASE 14: 17RE120 BONE MARROW CD23



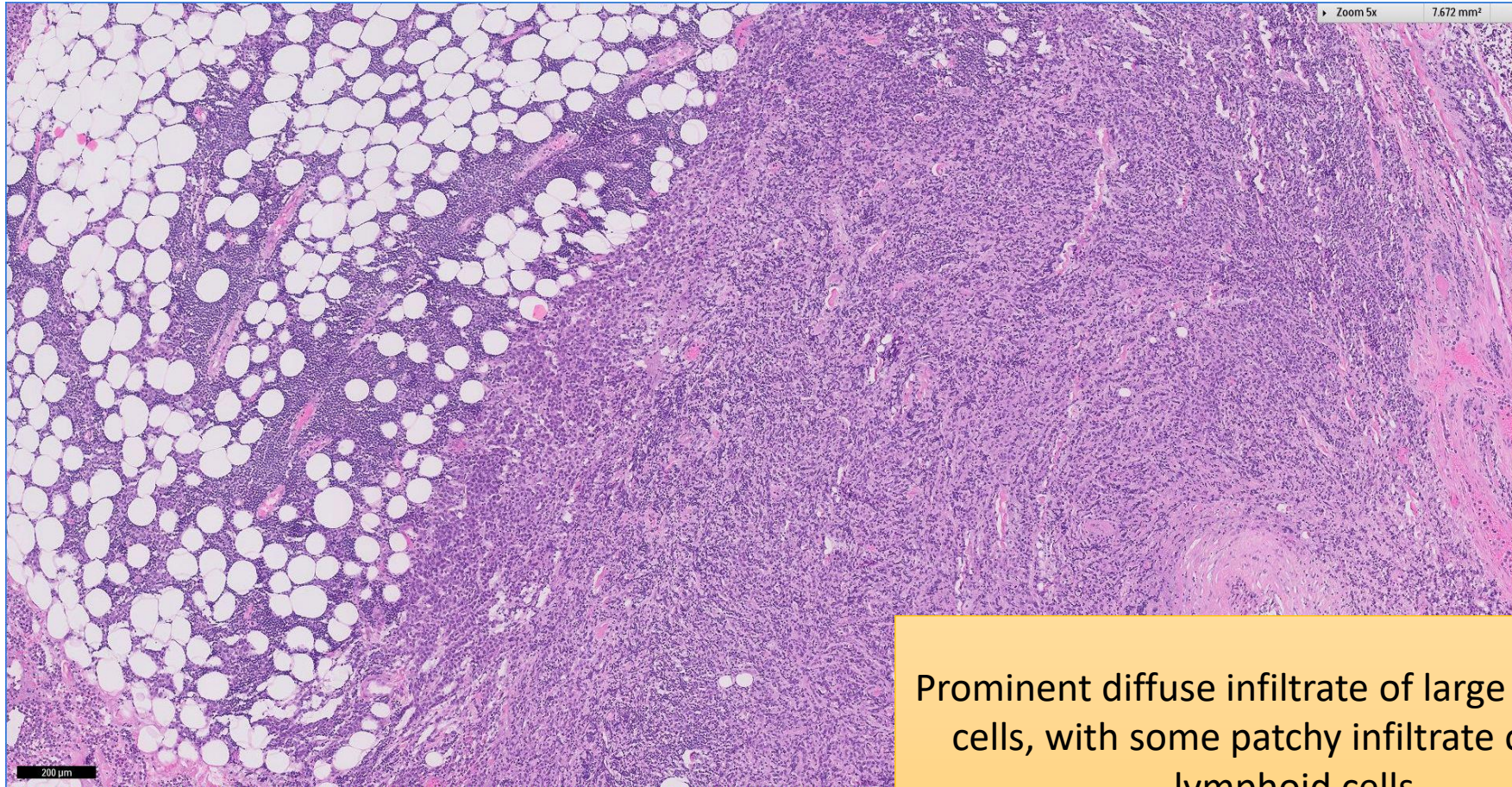
Widespread CD23 positivity

SGH CASE 14: 17RE120 BONE MARROW CD5



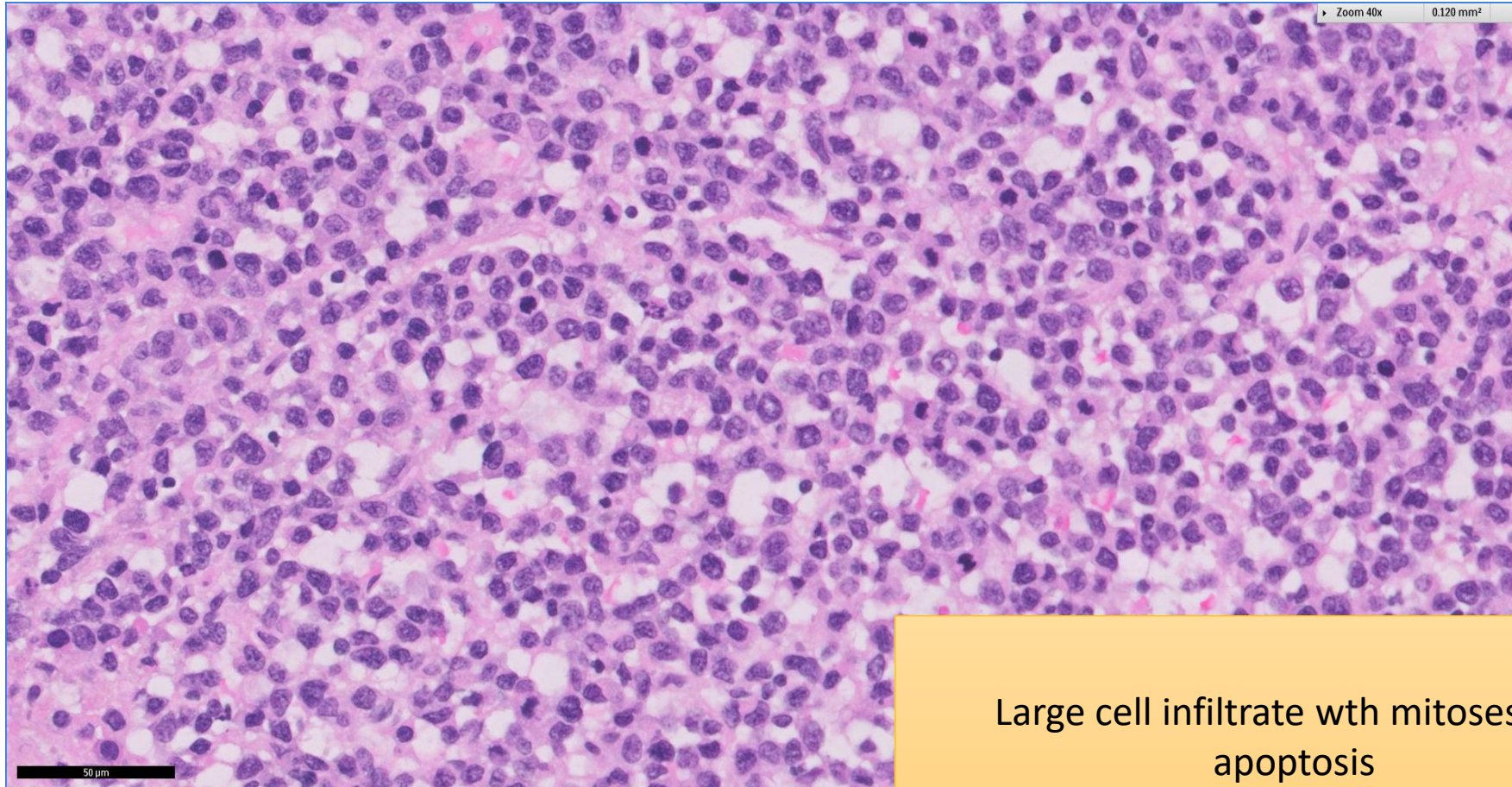
Widespread CD5 positivity

SGH CASE 14: 17RE115 LYMPH NODE H&E



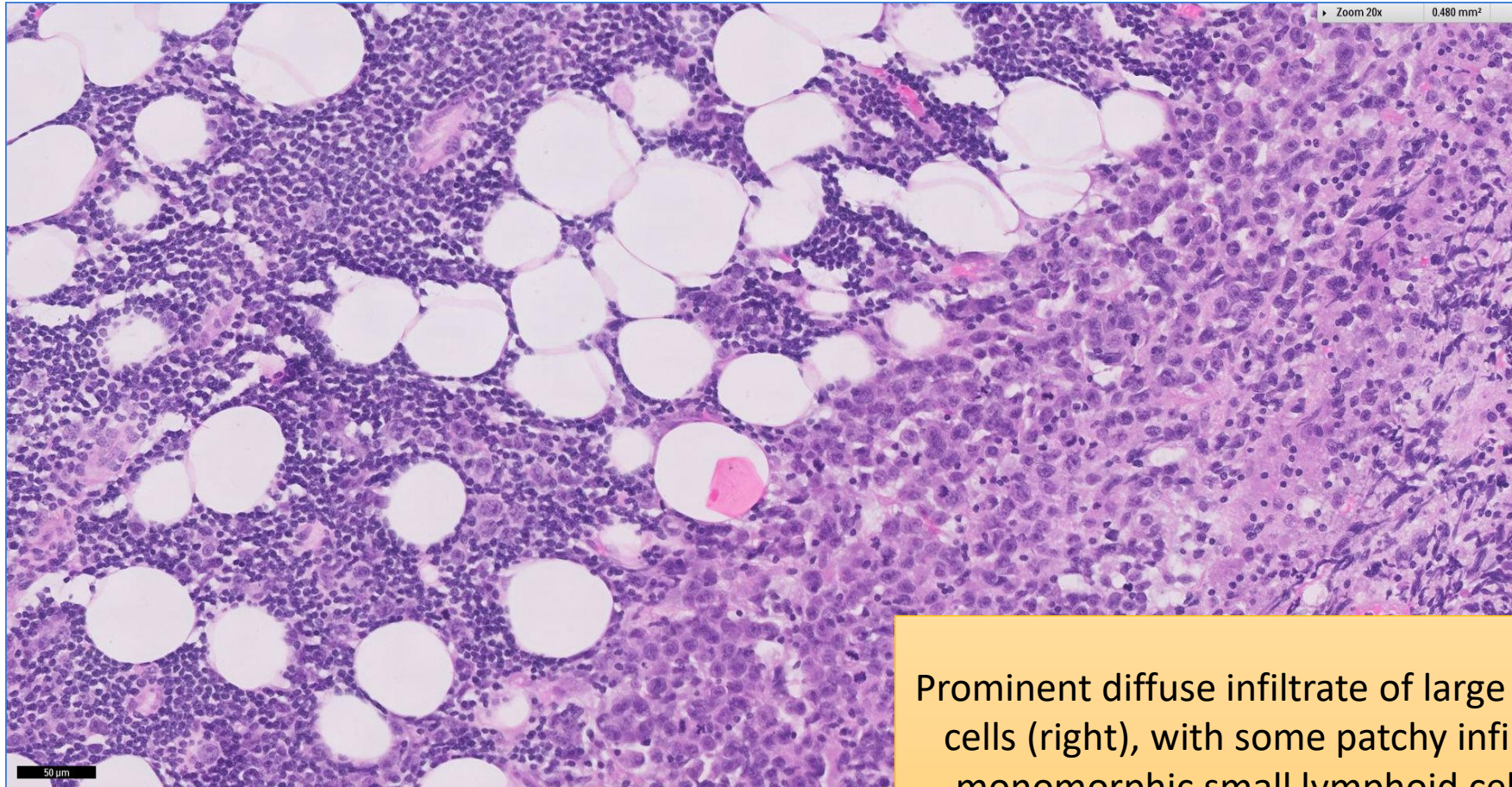
Prominent diffuse infiltrate of large lymphoid cells, with some patchy infiltrate of small lymphoid cells

SGH CASE 14: 17RE115 LYMPH NODE H&E



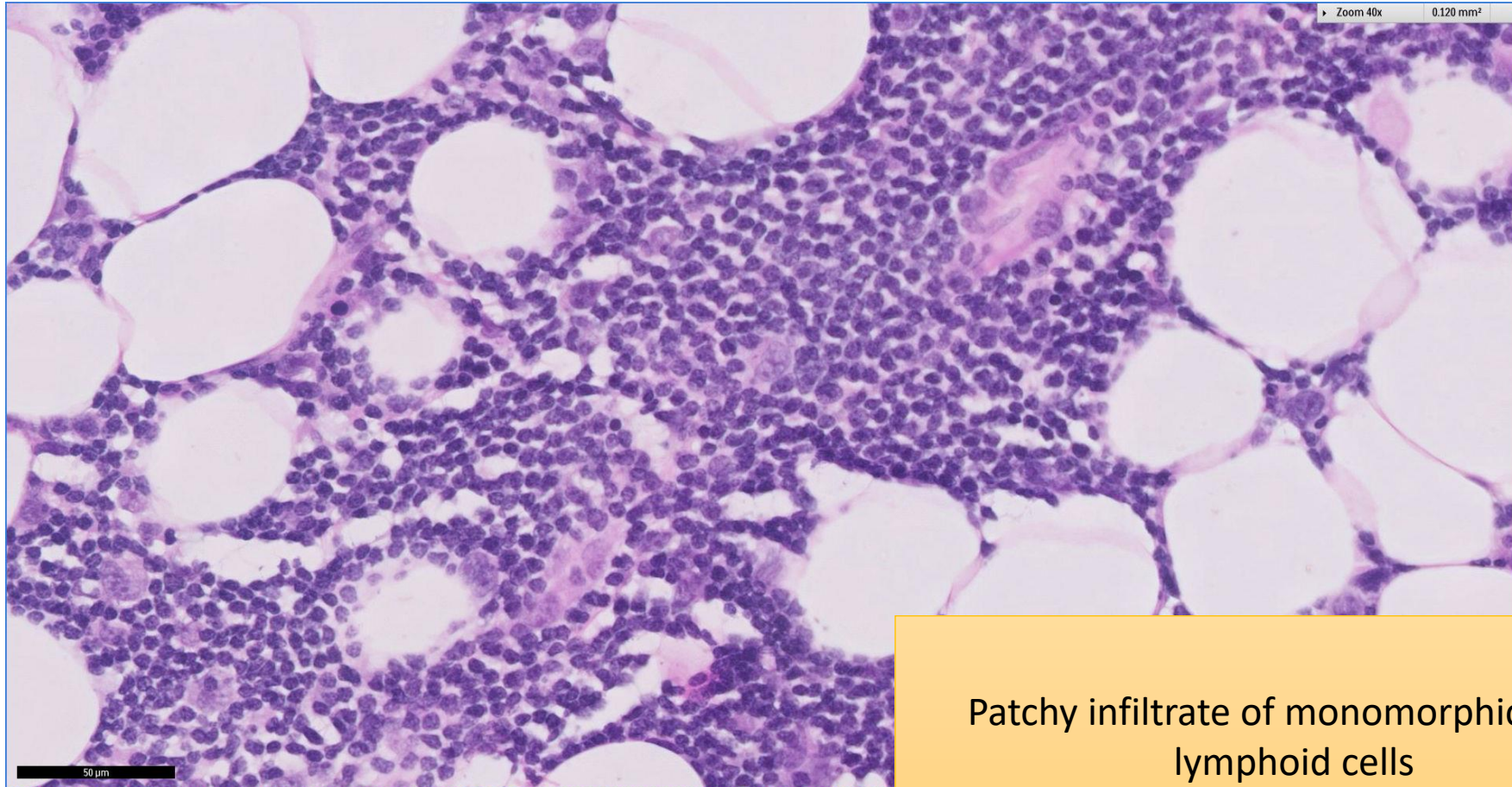
Large cell infiltrate with mitoses and apoptosis

SGH CASE 14: 17RE115 LYMPH NODE H&E



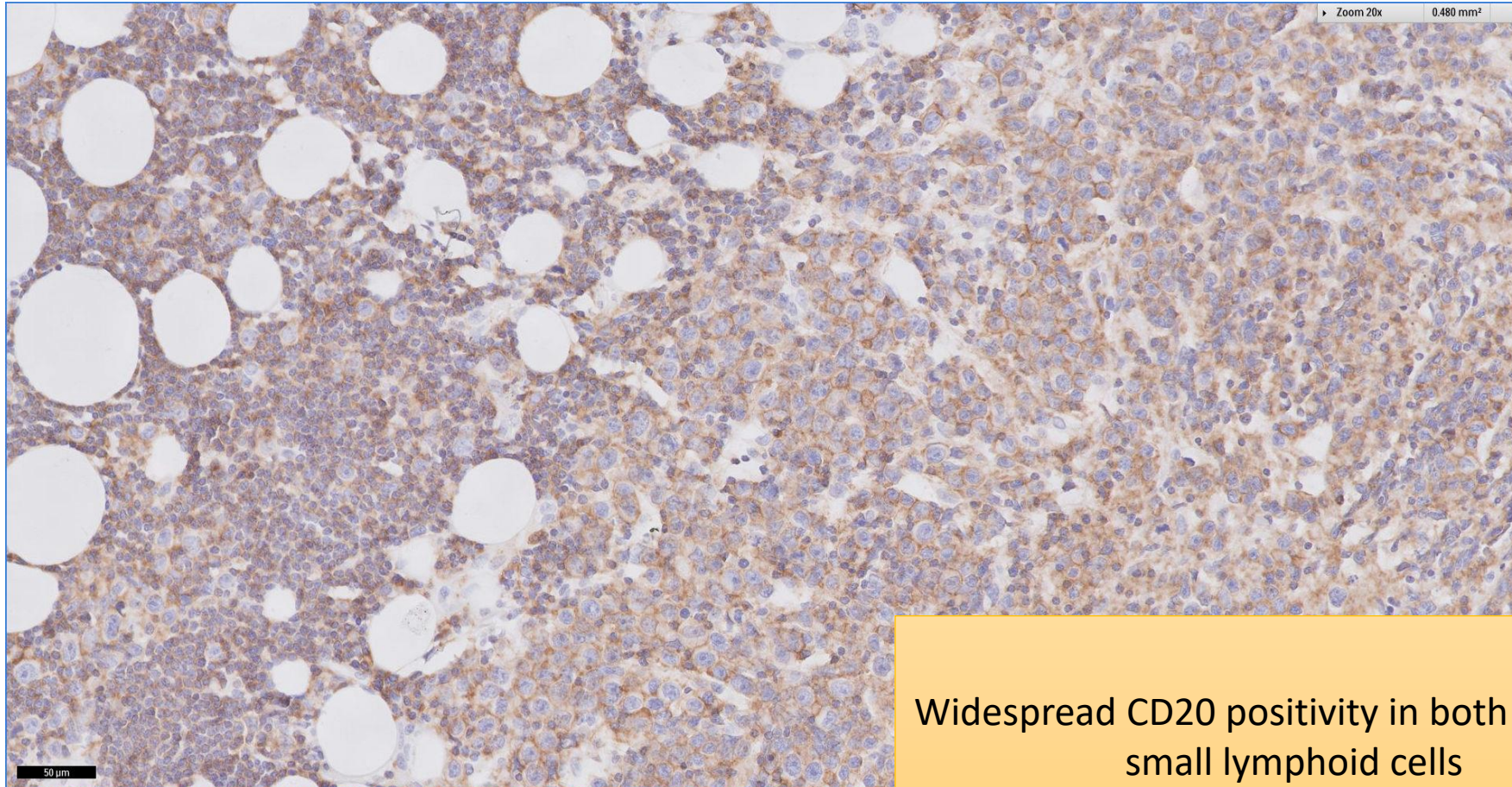
Prominent diffuse infiltrate of large lymphoid cells (right), with some patchy infiltrate of monomorphic small lymphoid cells (left)

SGH CASE 14: 17RE115 LYMPH NODE H&E



Patchy infiltrate of monomorphic small lymphoid cells

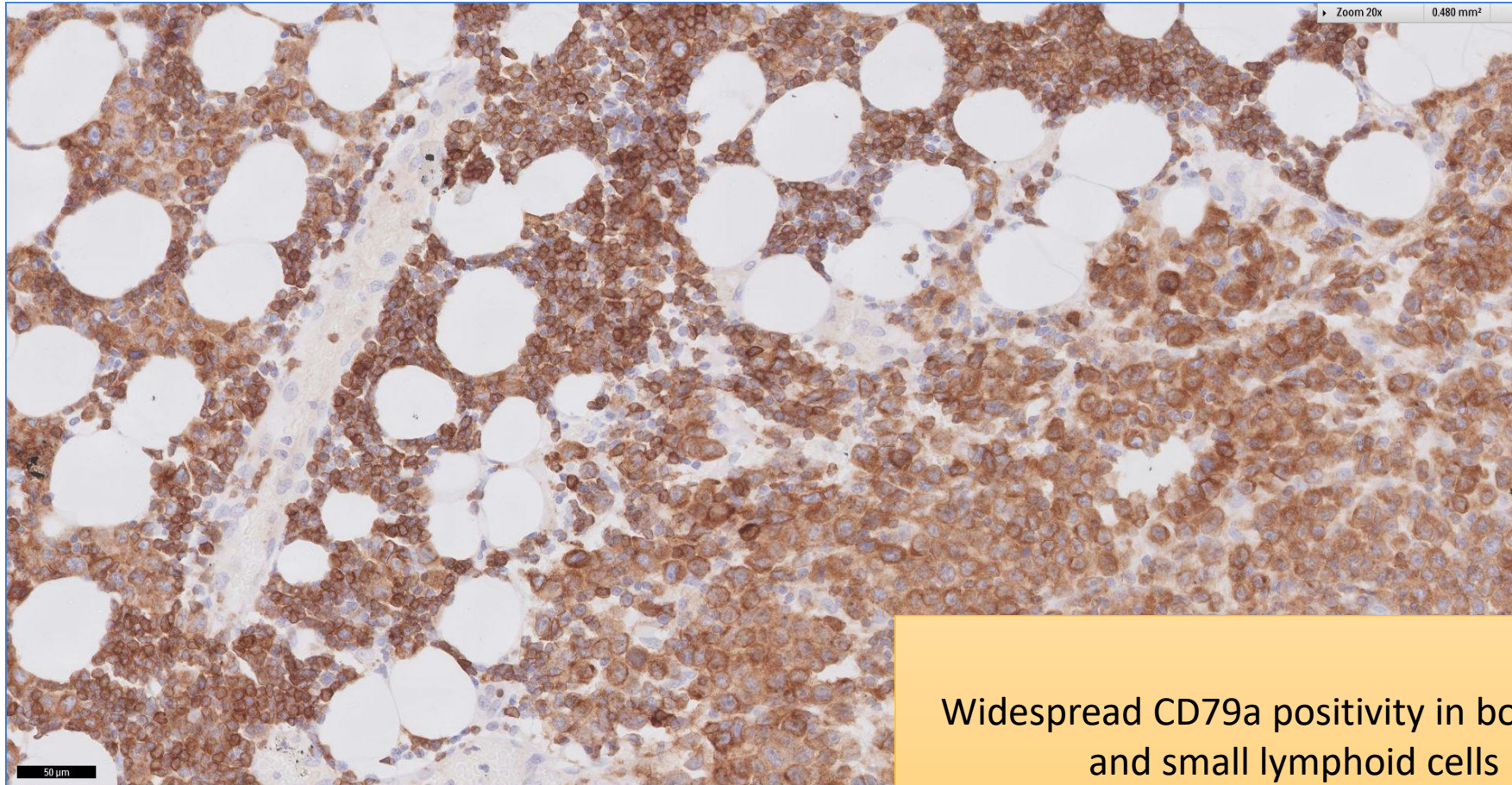
SGH CASE 14: 17RE115 LYMPH NODE CD20



Widespread CD20 positivity in both large and small lymphoid cells

SGH CASE 14: 17RE115 LYMPH NODE

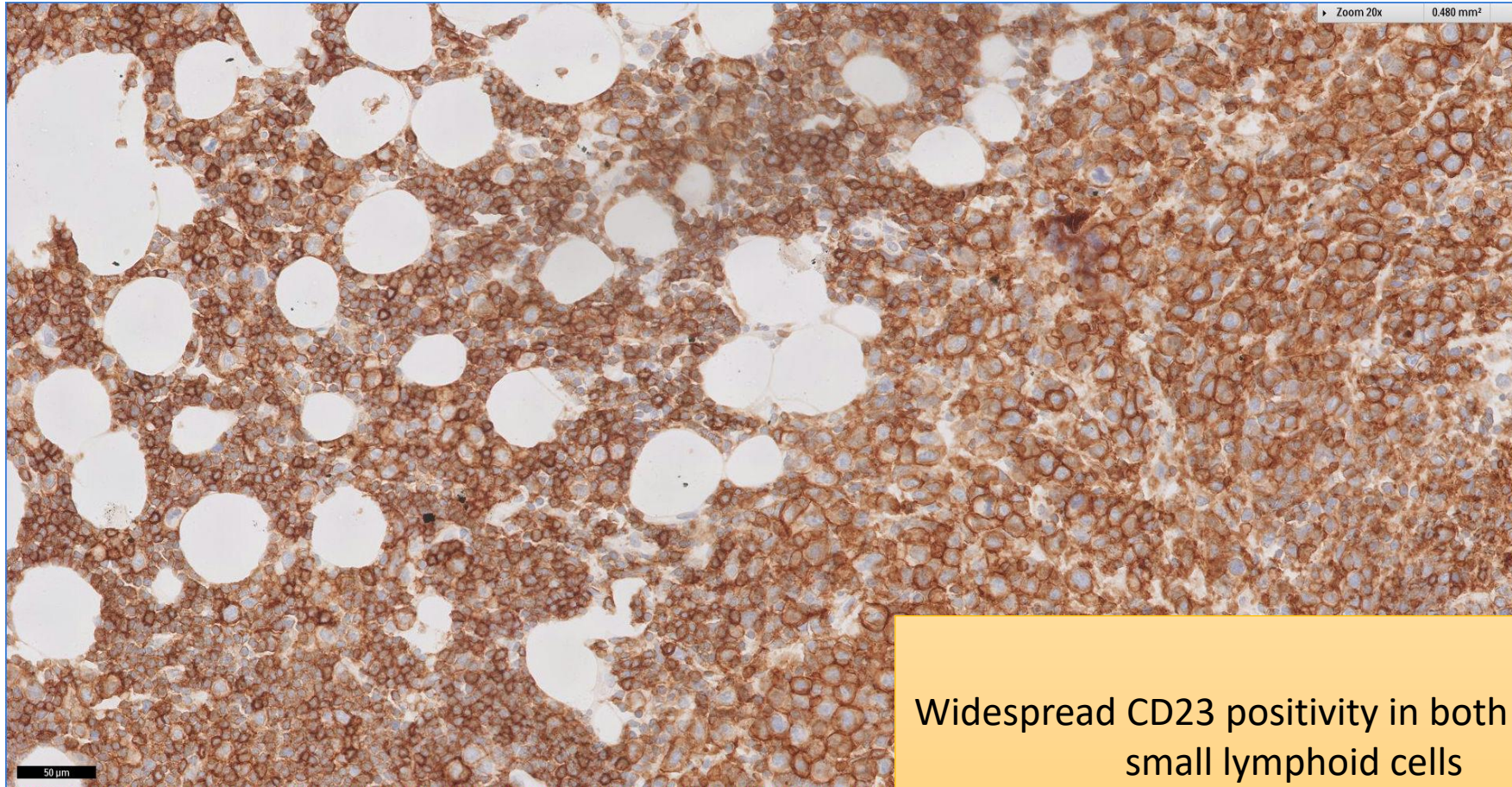
CD79A



Widespread CD79a positivity in both large and small lymphoid cells

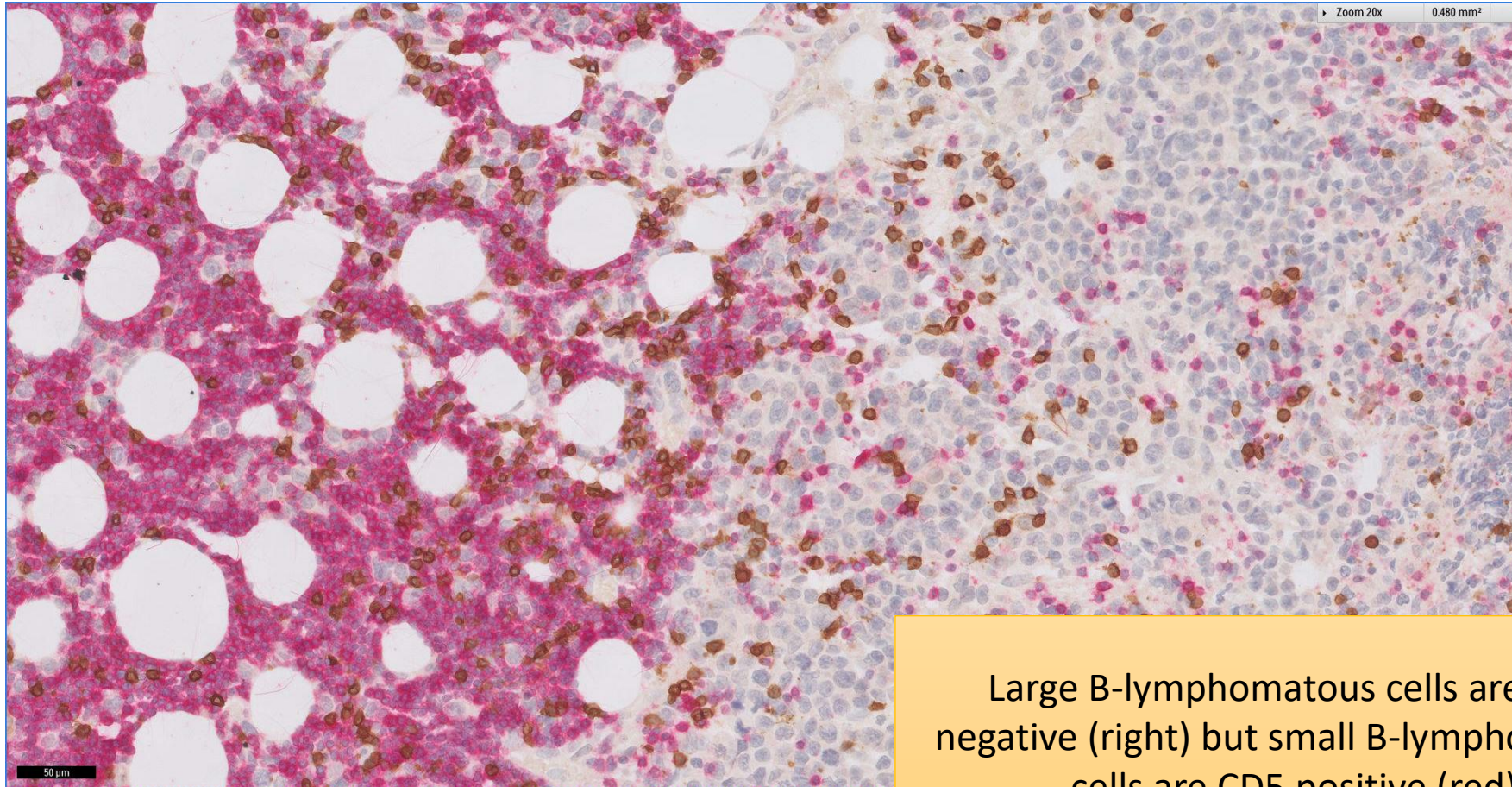
SGH CASE 14: 17RE115 LYMPH NODE

CD23



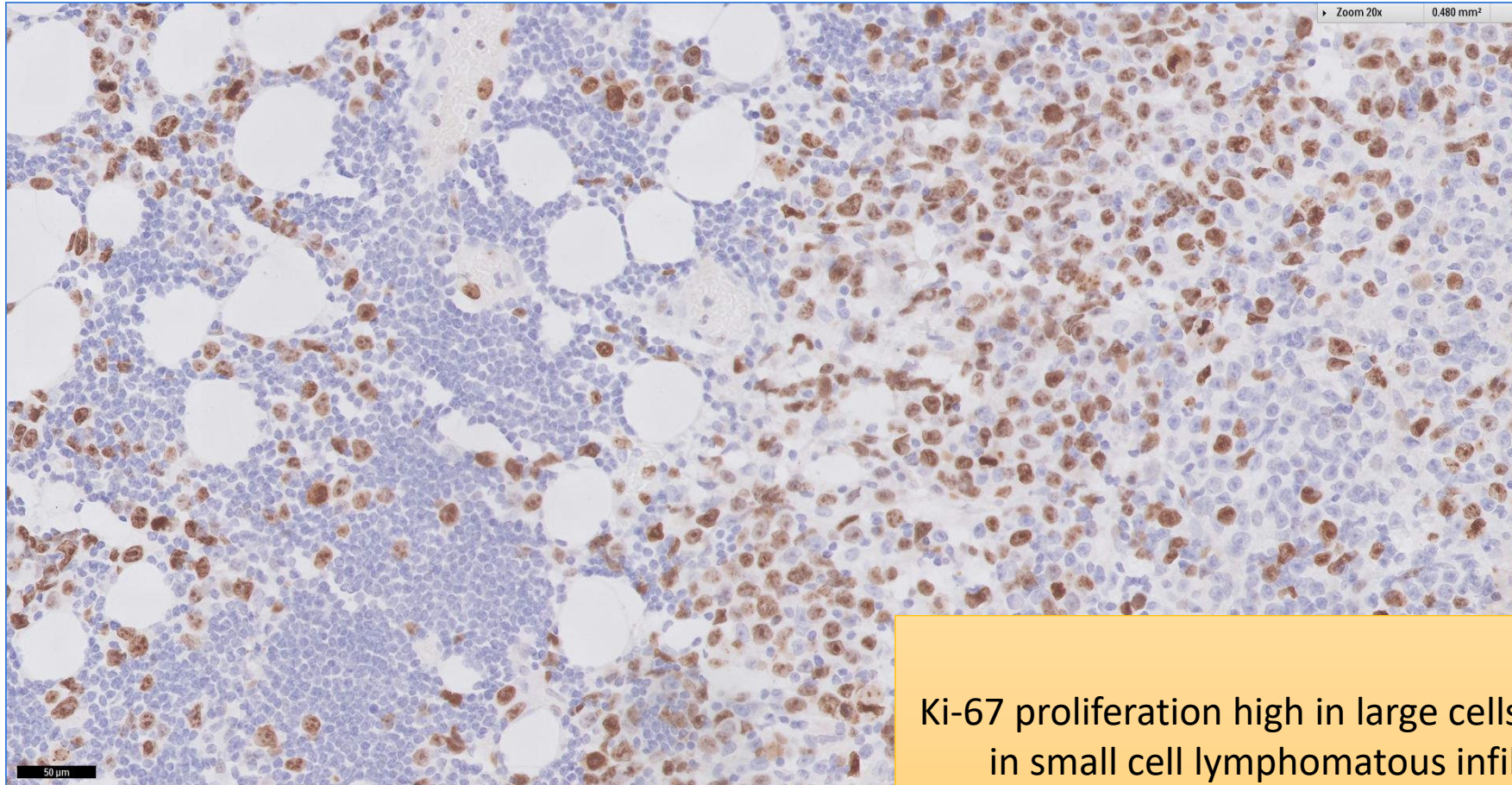
Widespread CD23 positivity in both large and small lymphoid cells

SGH CASE 14: 17RE115 LYMPH NODE CD5(RED) CD3(BROWN)



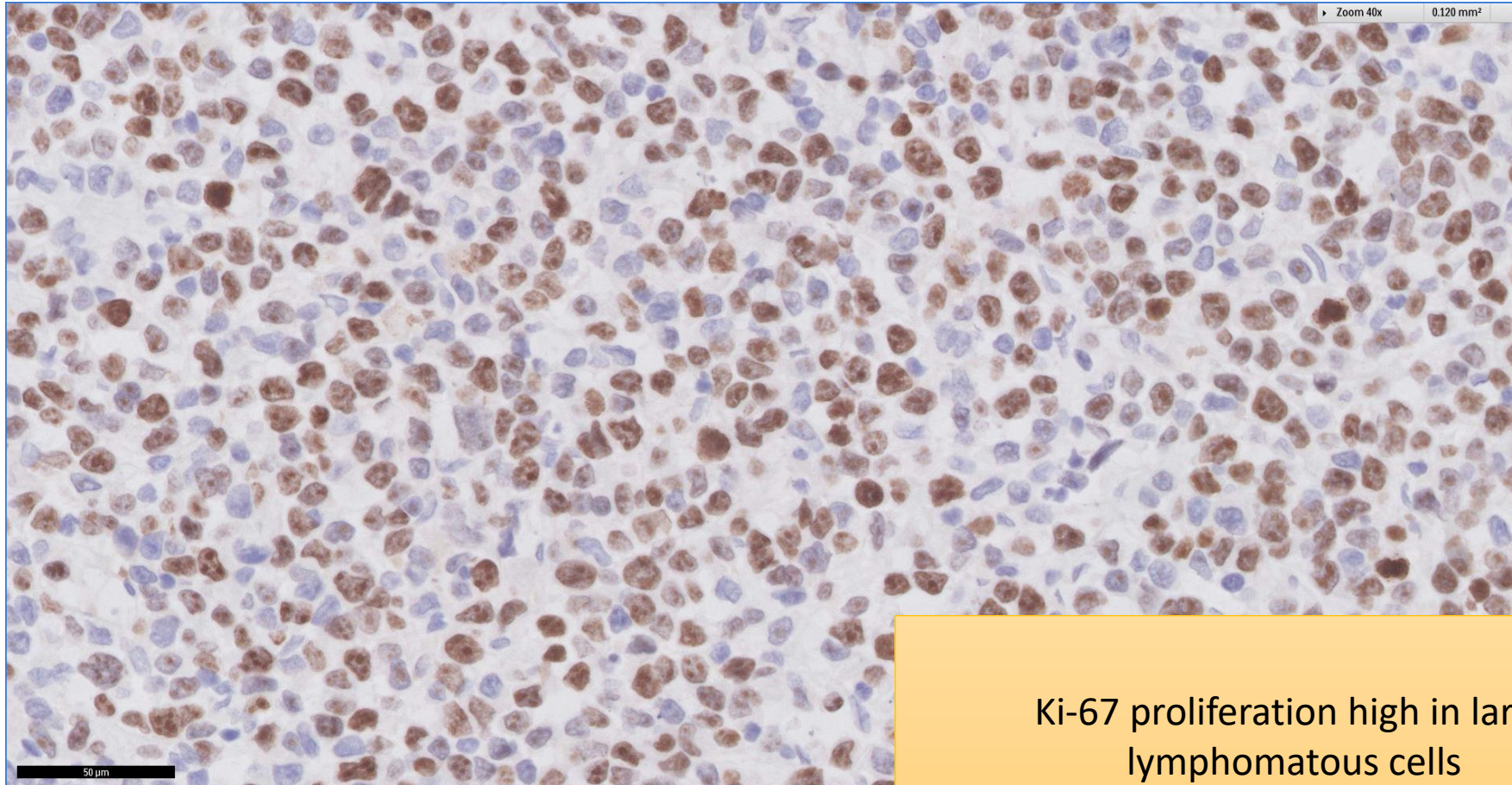
Large B-lymphomatous cells are CD5 negative (right) but small B-lymphomatous cells are CD5 positive (red)

SGH CASE 14: 17RE115 LYMPH NODE KI67



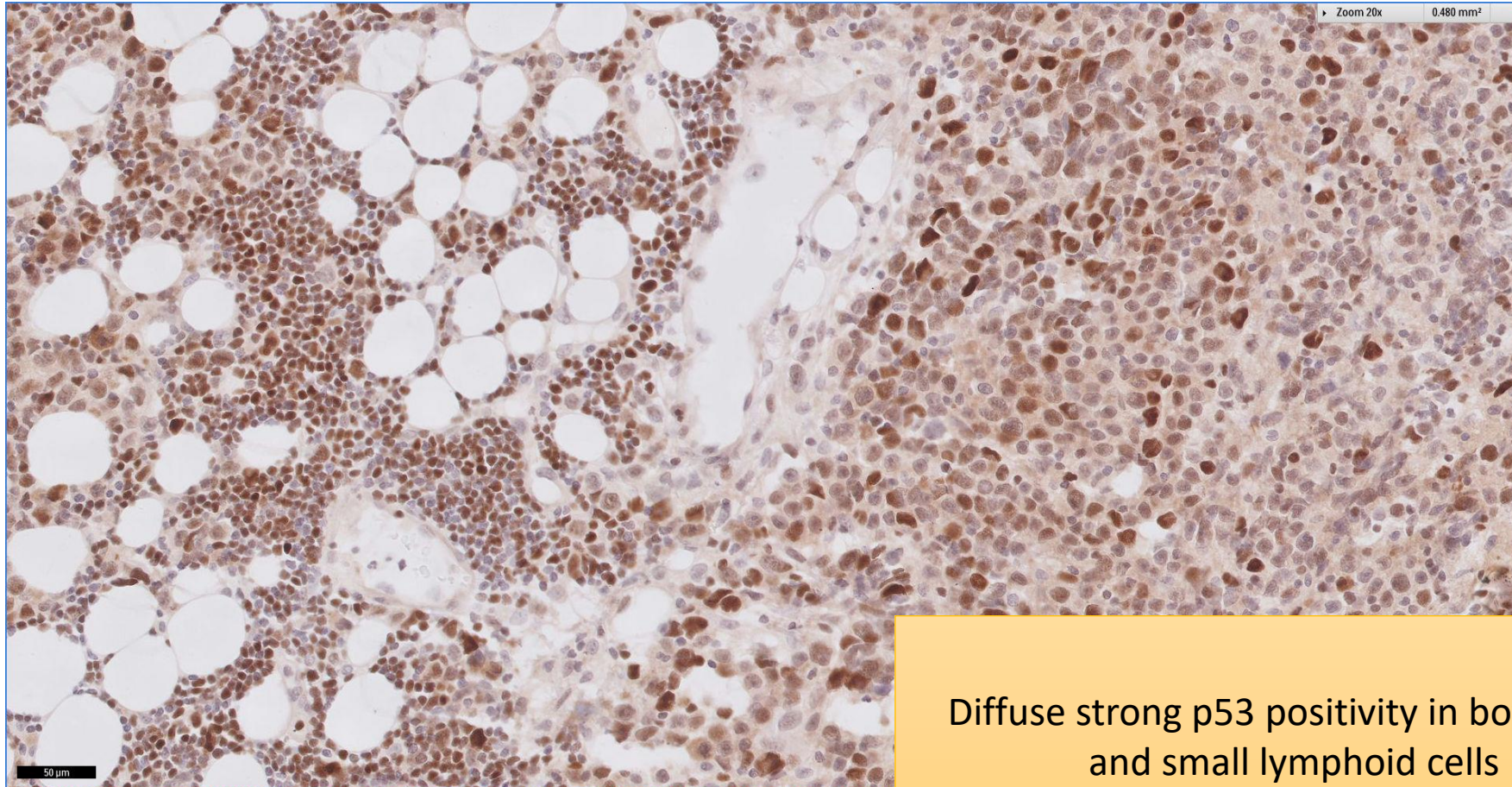
Ki-67 proliferation high in large cells, but low in small cell lymphomatous infiltrate

SGH CASE 14: 17RE115 LYMPH NODE KI67



Ki-67 proliferation high in large lymphomatous cells

SGH CASE 14: 17RE115 LYMPH NODE P53



Diffuse strong p53 positivity in both large and small lymphoid cells

SGH CASE 14: 17RE120 & 17RE115

- 17RE120
 - Diagnosis: Chronic Lymphocytic Leukaemia
- 17RE115
 - Diagnosis: Diffuse Large B-cell Lymphoma in background of Chronic Lymphocytic Leukaemia (Richter Syndrome)