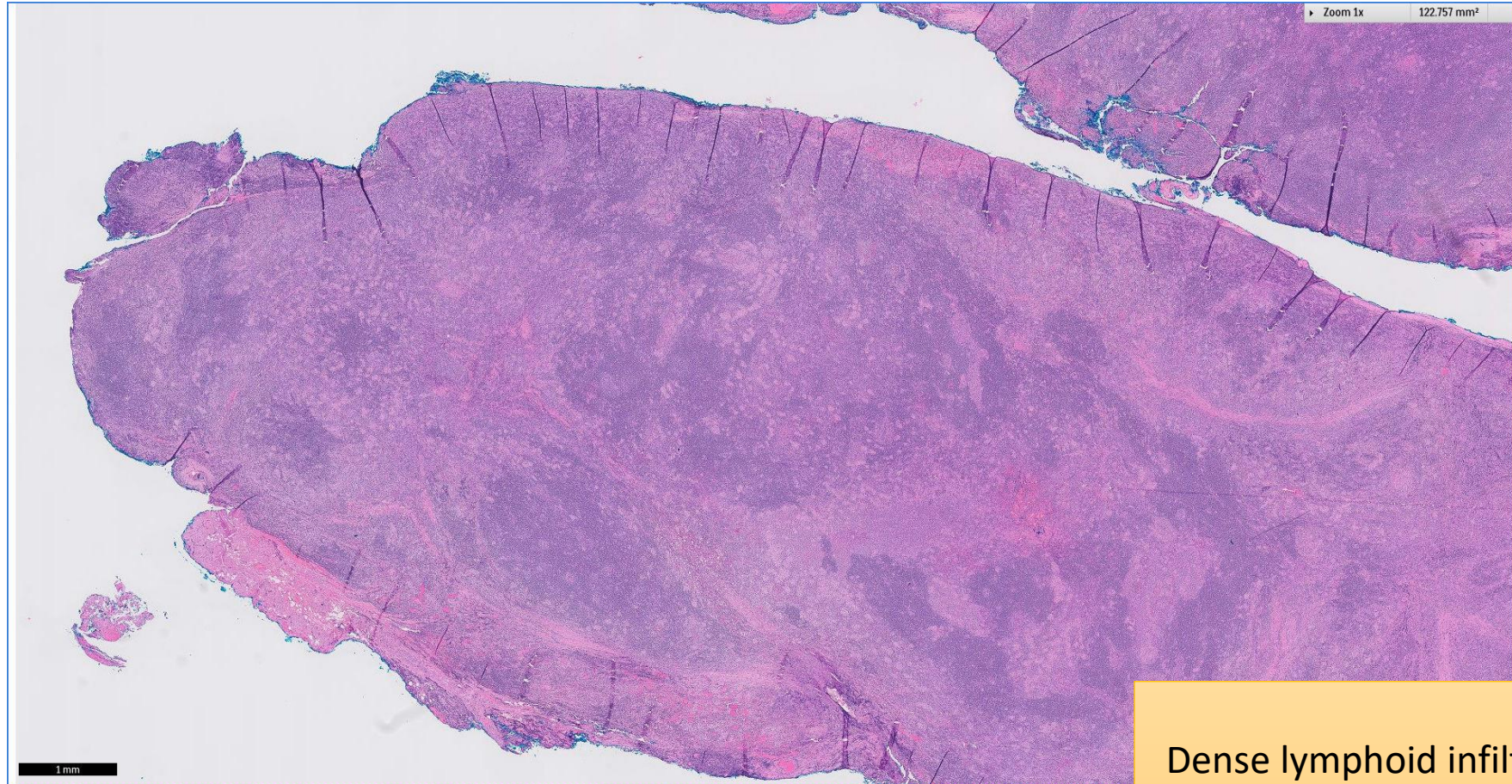


# SGH CASE 12: 17RE116

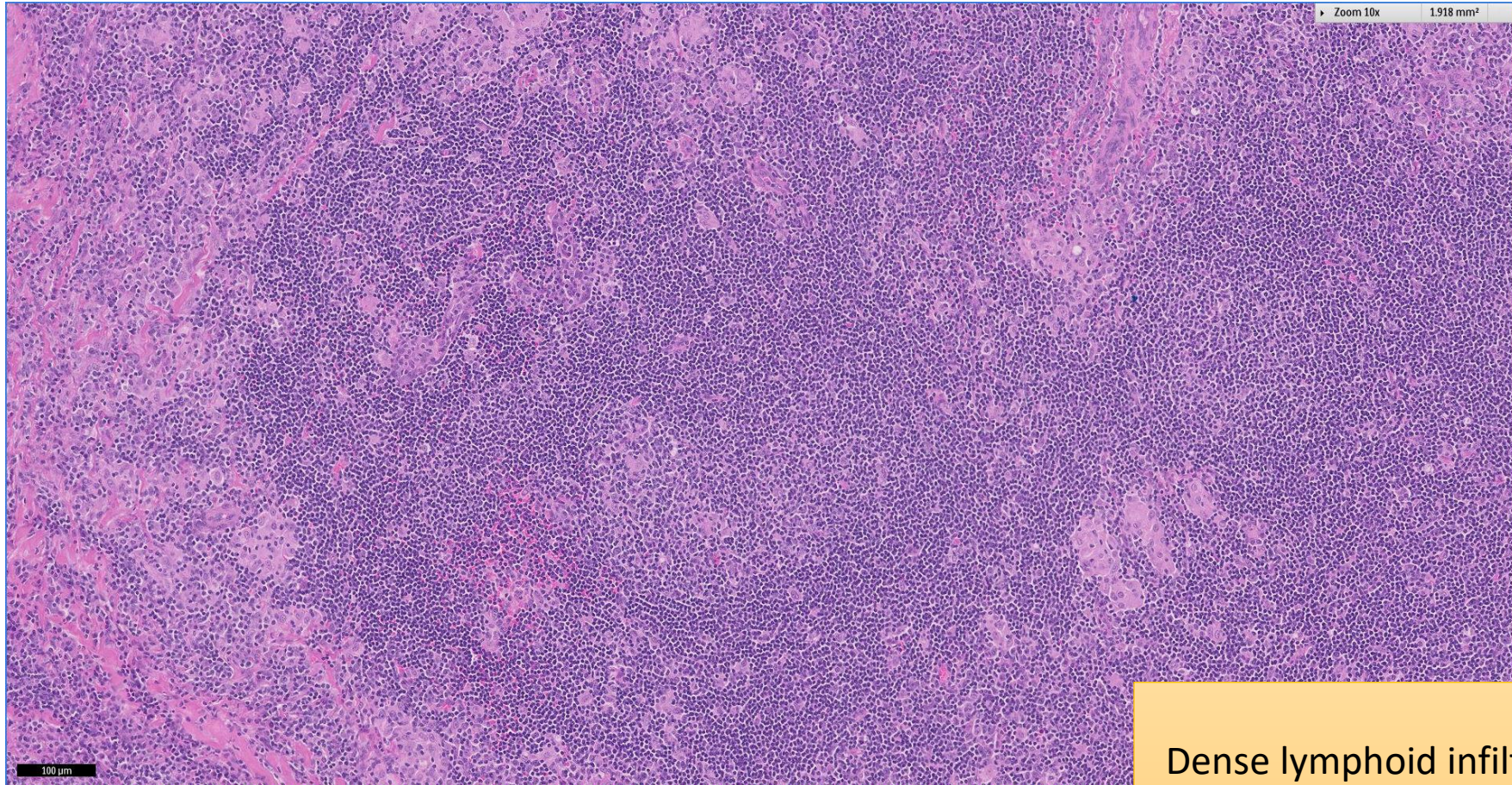
- Clinical History:
  - 30+ years old (late 30s). Female. Right eye swelling for a few years. Radiological scan show right lacrimal gland tumour.
- Specimen:
  - Excision biopsy of right lacrimal gland tumour.

# SGH CASE 12: 17RE116 H&E



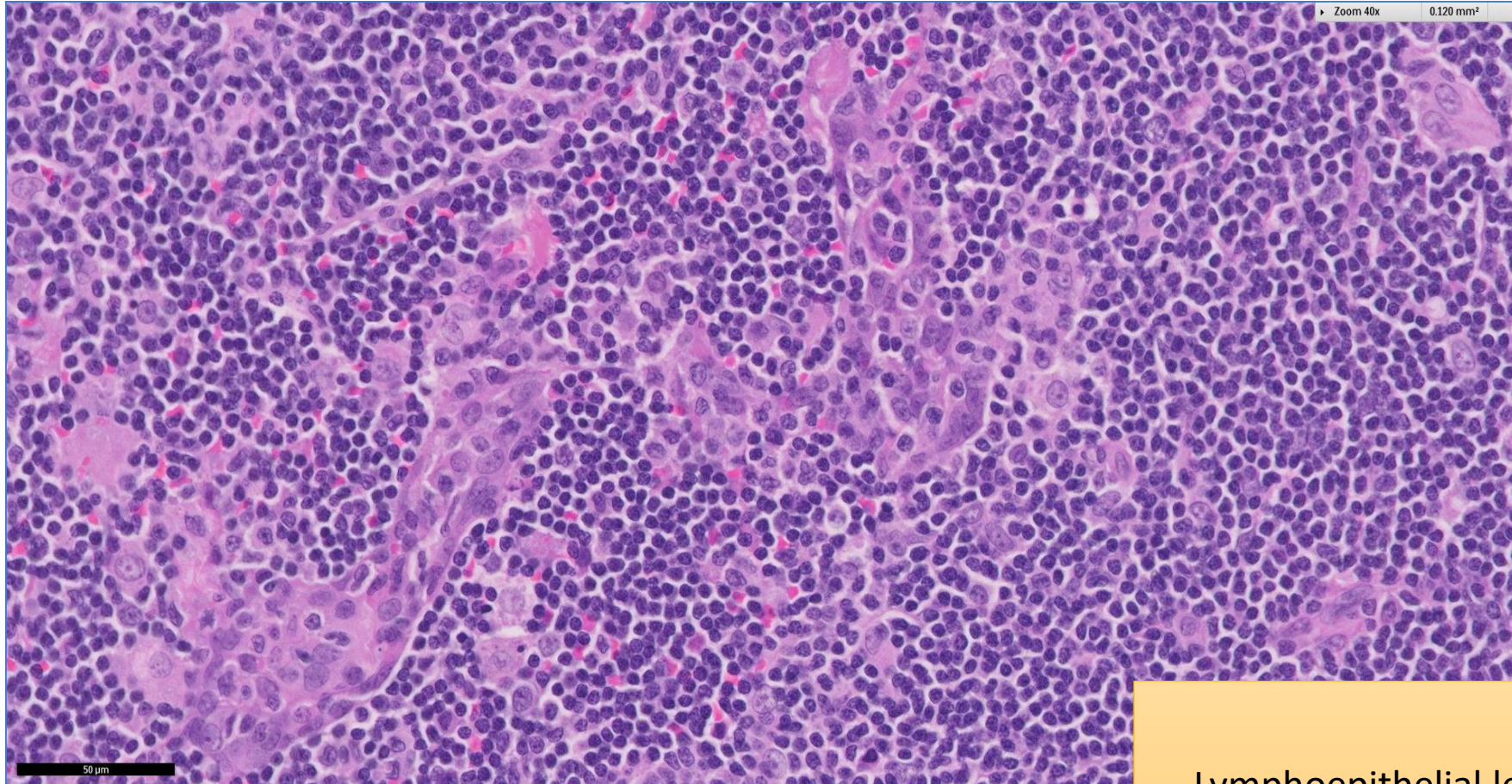
Dense lymphoid infiltrate in lacrimal gland effacing normal architecture

# SGH CASE 12: 17RE116 H&E



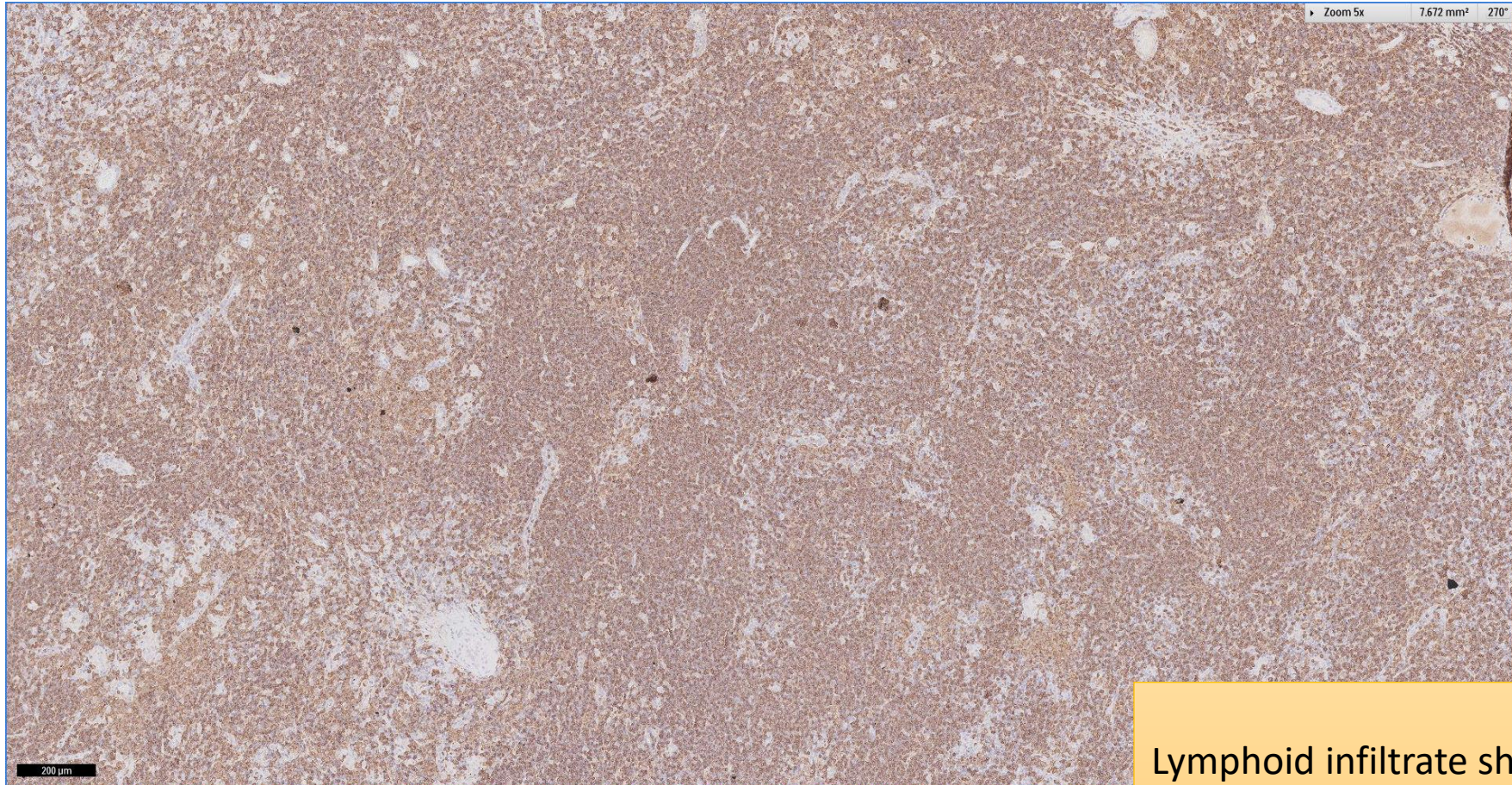
Dense lymphoid infiltrate in lacrimal gland effacing normal architecture

# SGH CASE 12: 17RE116 H&E



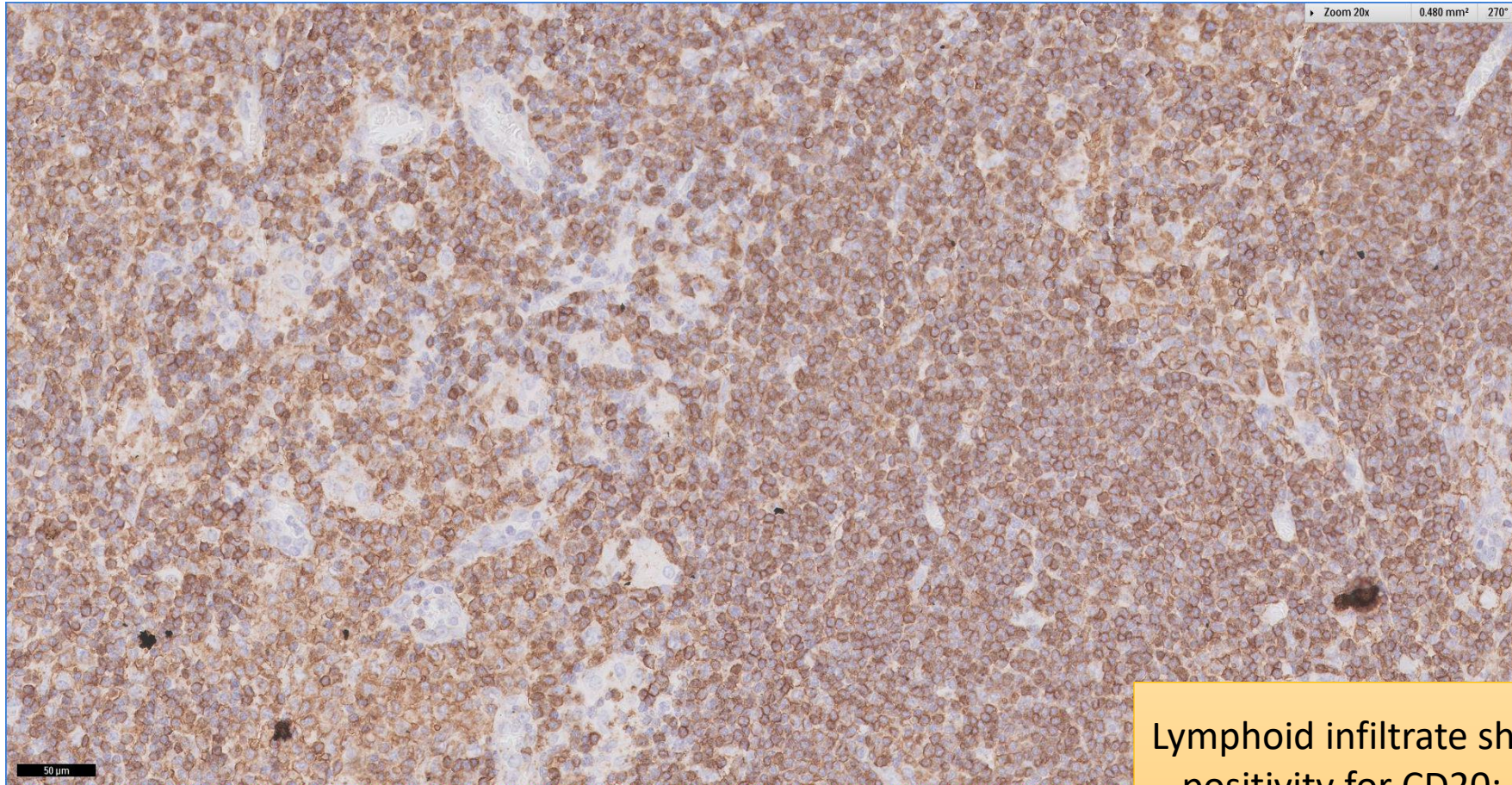
Lymphoepithelial lesions present

# SGH CASE 12: 17RE116 CD20



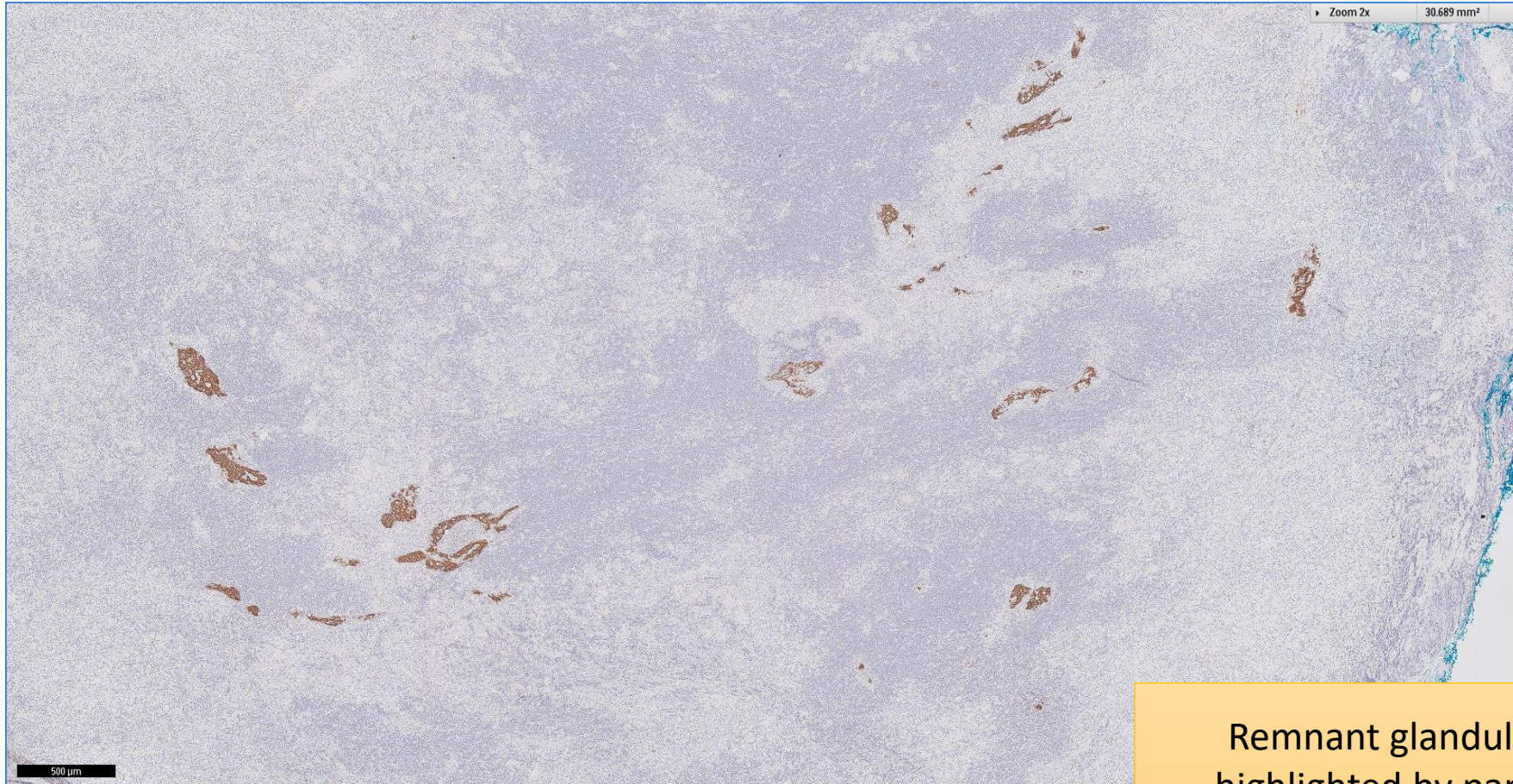
Lymphoid infiltrate shows widespread positivity for CD20

# SGH CASE 12: 17RE116 CD20



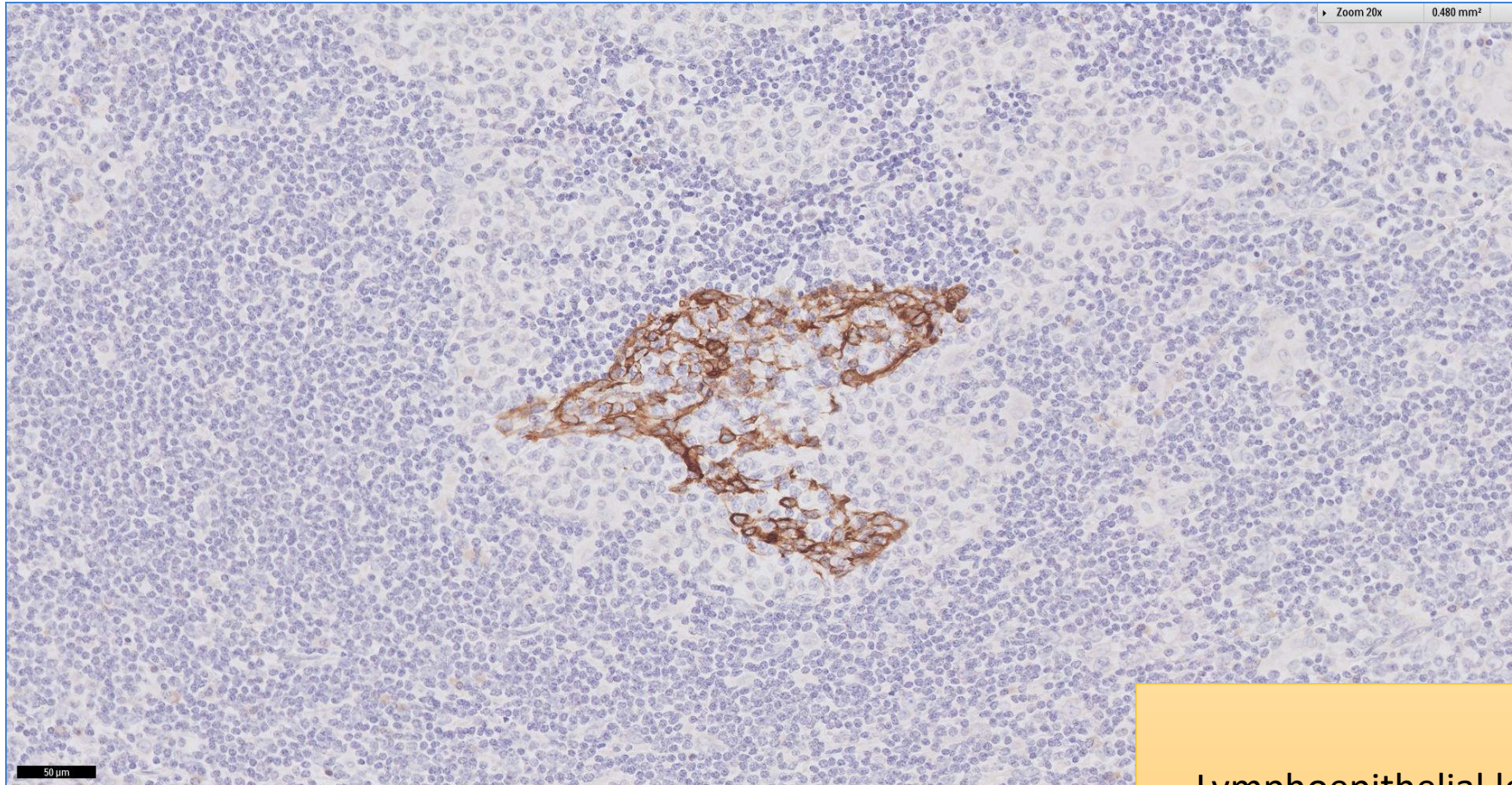
Lymphoid infiltrate shows widespread positivity for CD20; some remnant glandular elements in negative relief

# SGH CASE 12: 17RE116 AE1/3



Remnant glandular elements  
highlighted by pan-cytokeratin  
marker AE1/3

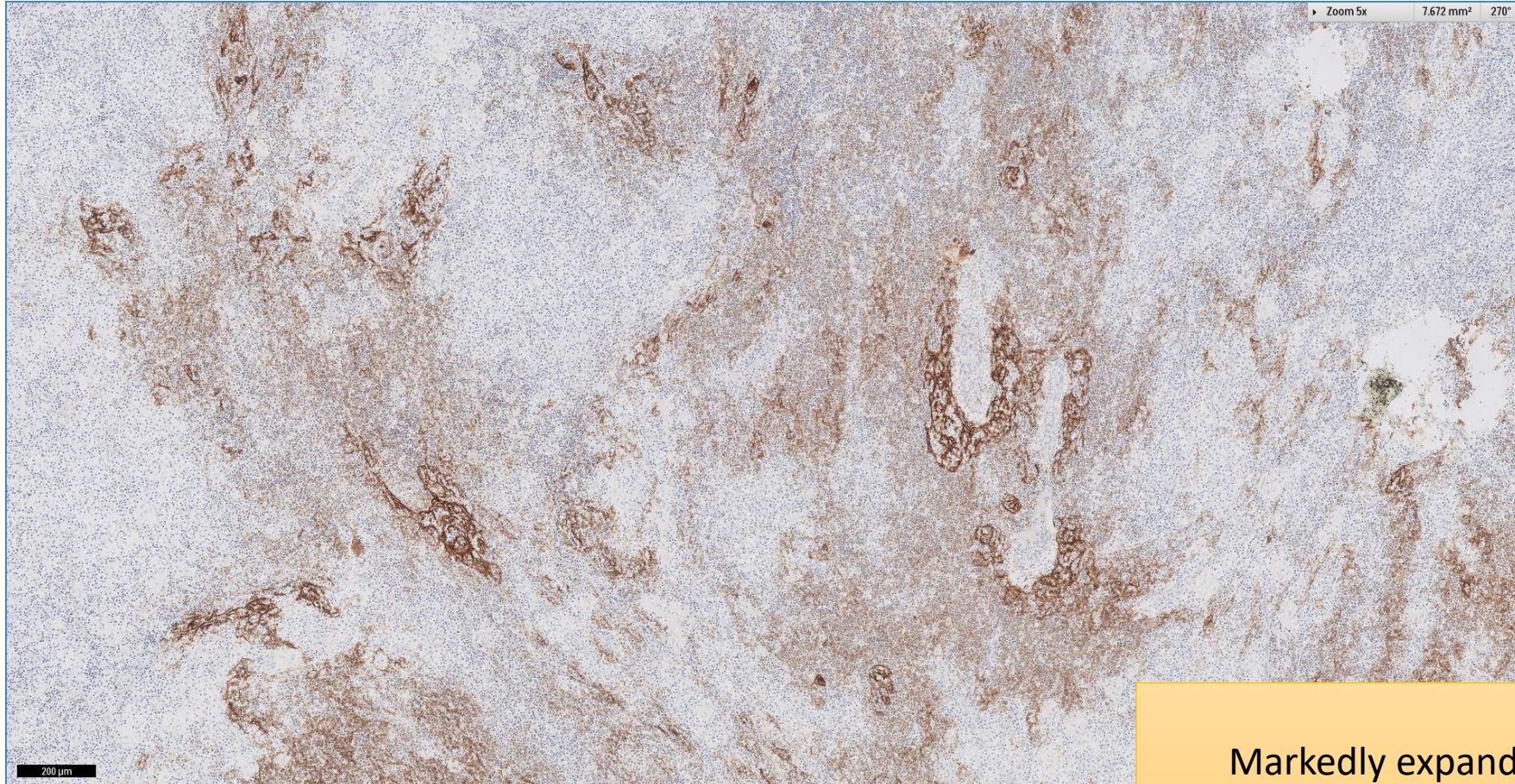
# SGH CASE 12: 17RE116 AE1/3



Lymphoepithelial lesions present

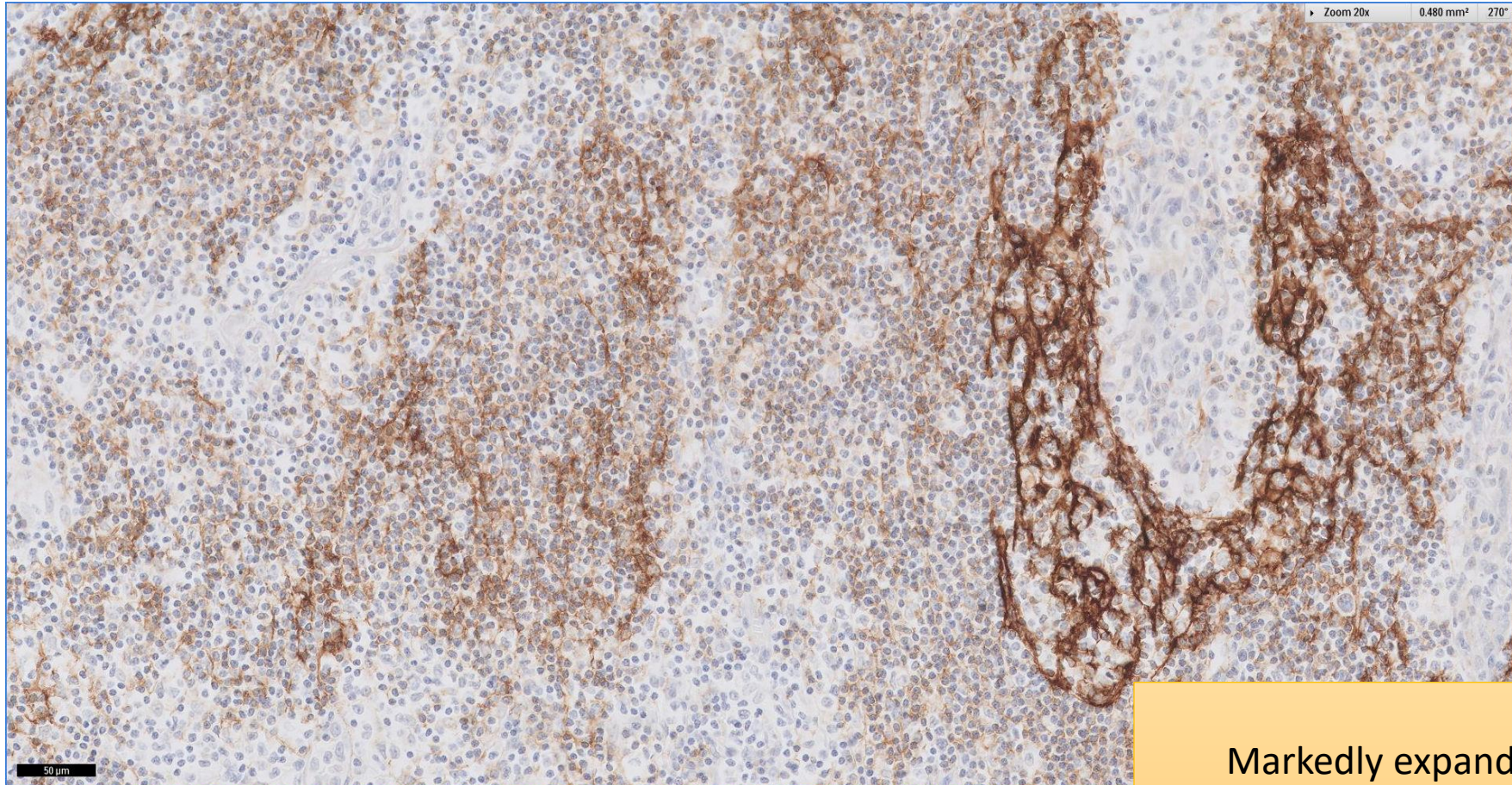


# SGH CASE 12: 17RE116 CD21



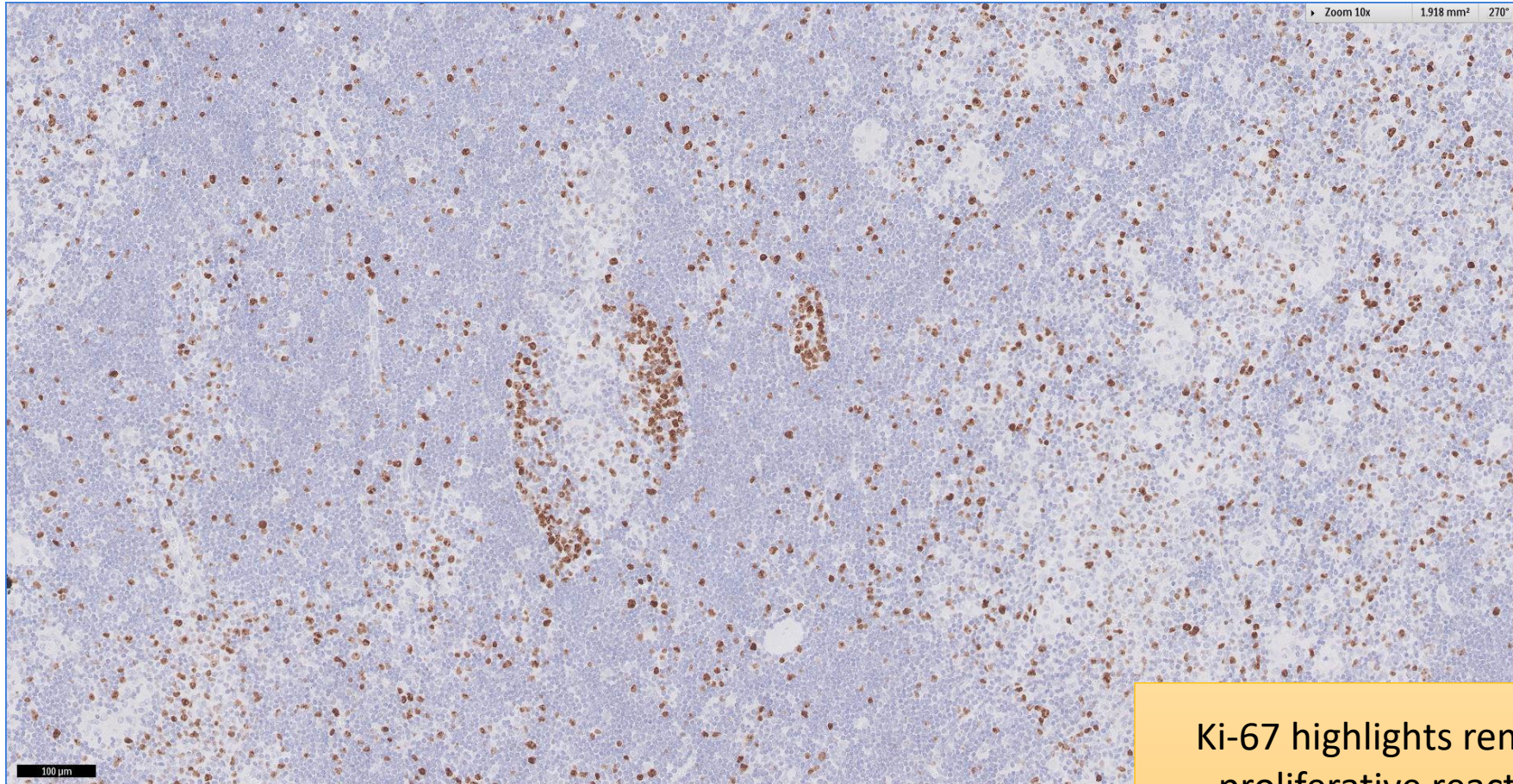
Markedly expanded follicular  
dendritic meshworks

# SGH CASE 12: 17RE116 CD21



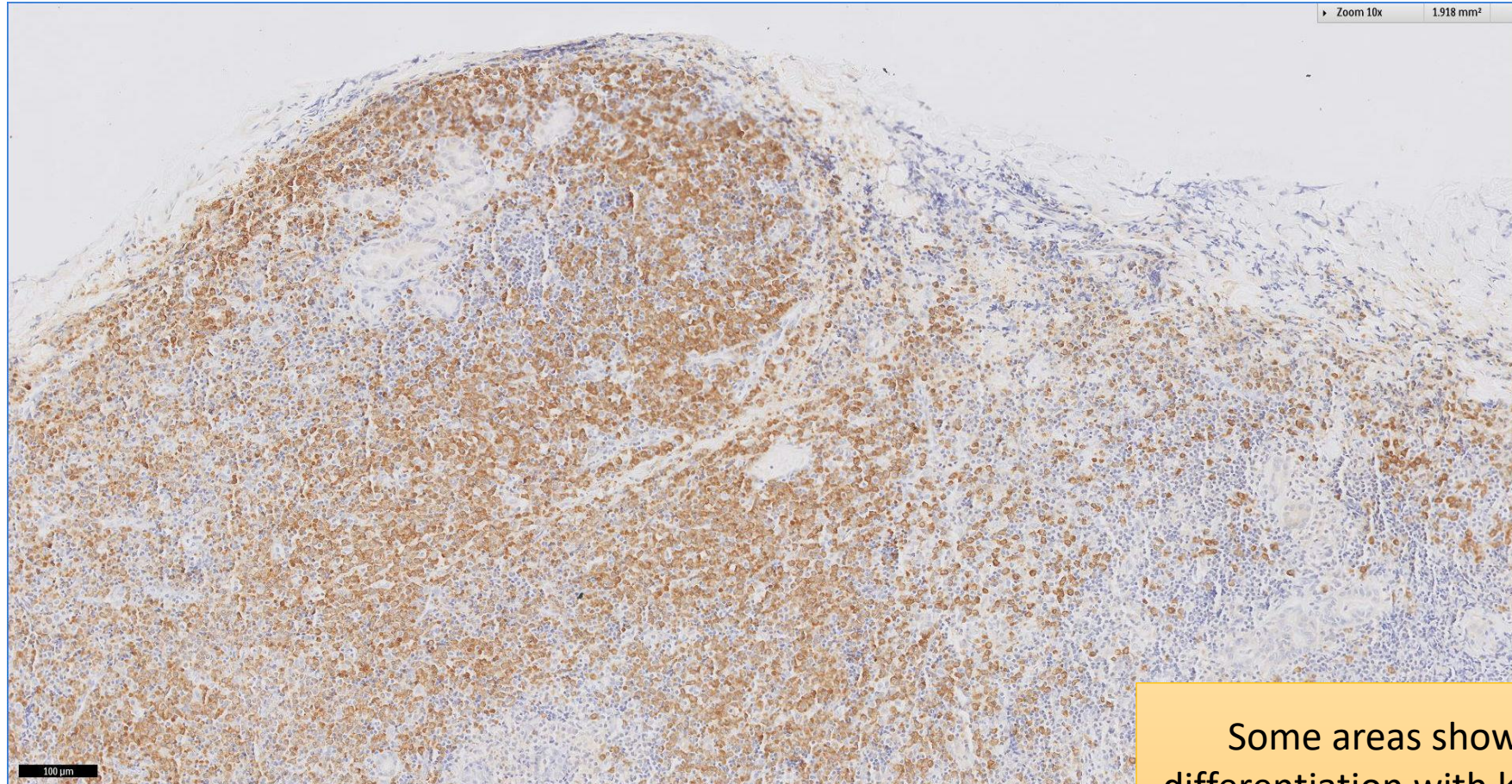
**Markedly expanded follicular dendritic meshworks**

# SGH CASE 12: 17RE116 KI67



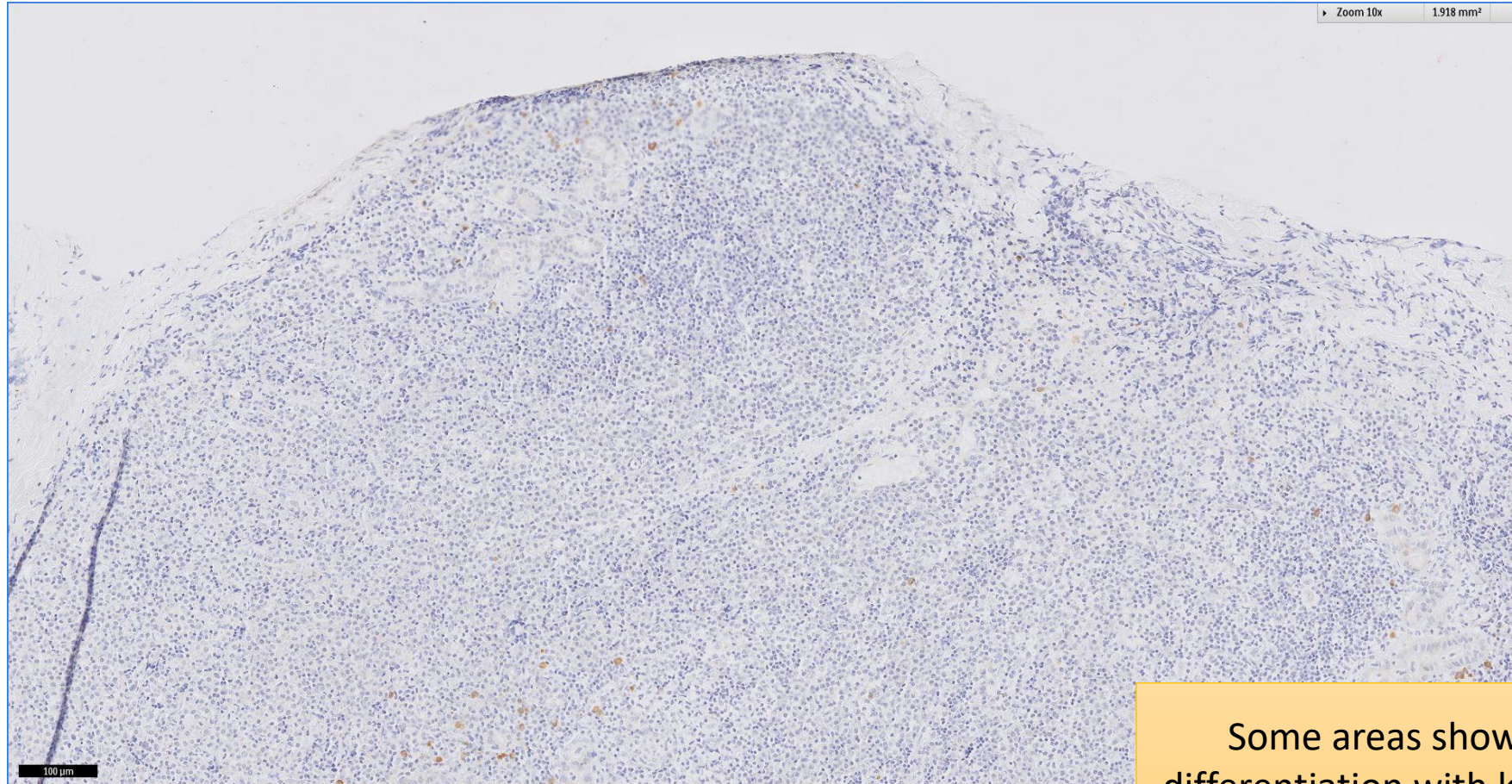
Ki-67 highlights remnant densely proliferative reactive germinal centres (centre)

# SGH CASE 12: 17RE116 KAPPA-ISH



Some areas show plasma cell differentiation with kappa light chain restriction

# SGH CASE 12: 17RE116 LAMBDA-ISH



Some areas show plasma cell  
differentiation with kappa light chain  
restriction

# SGH CASE 12: 17RE116

- Extranodal Marginal Zone Lymphoma of Mucosa-associated Lymphoid Tissue