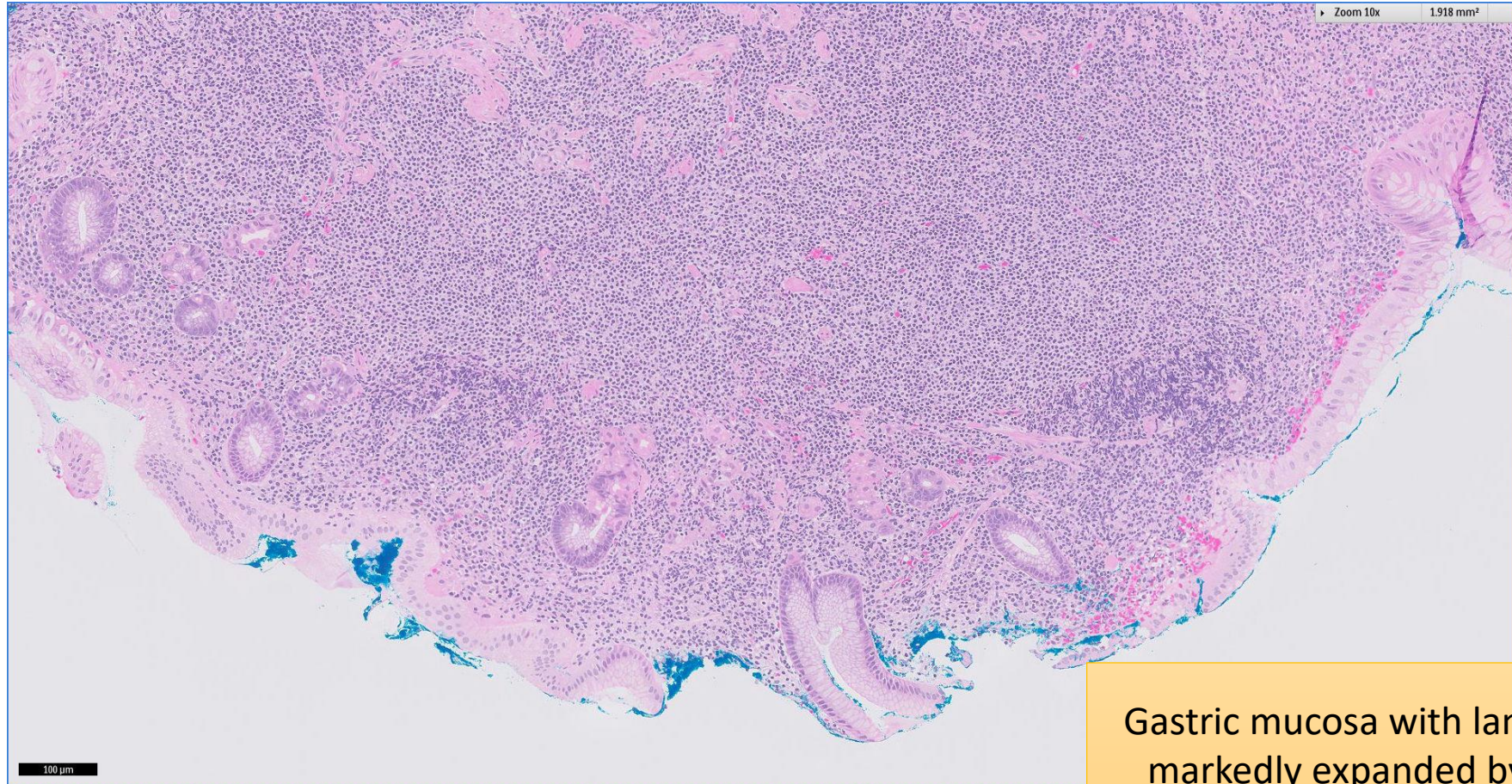


SGH CASE 7: 17RE107

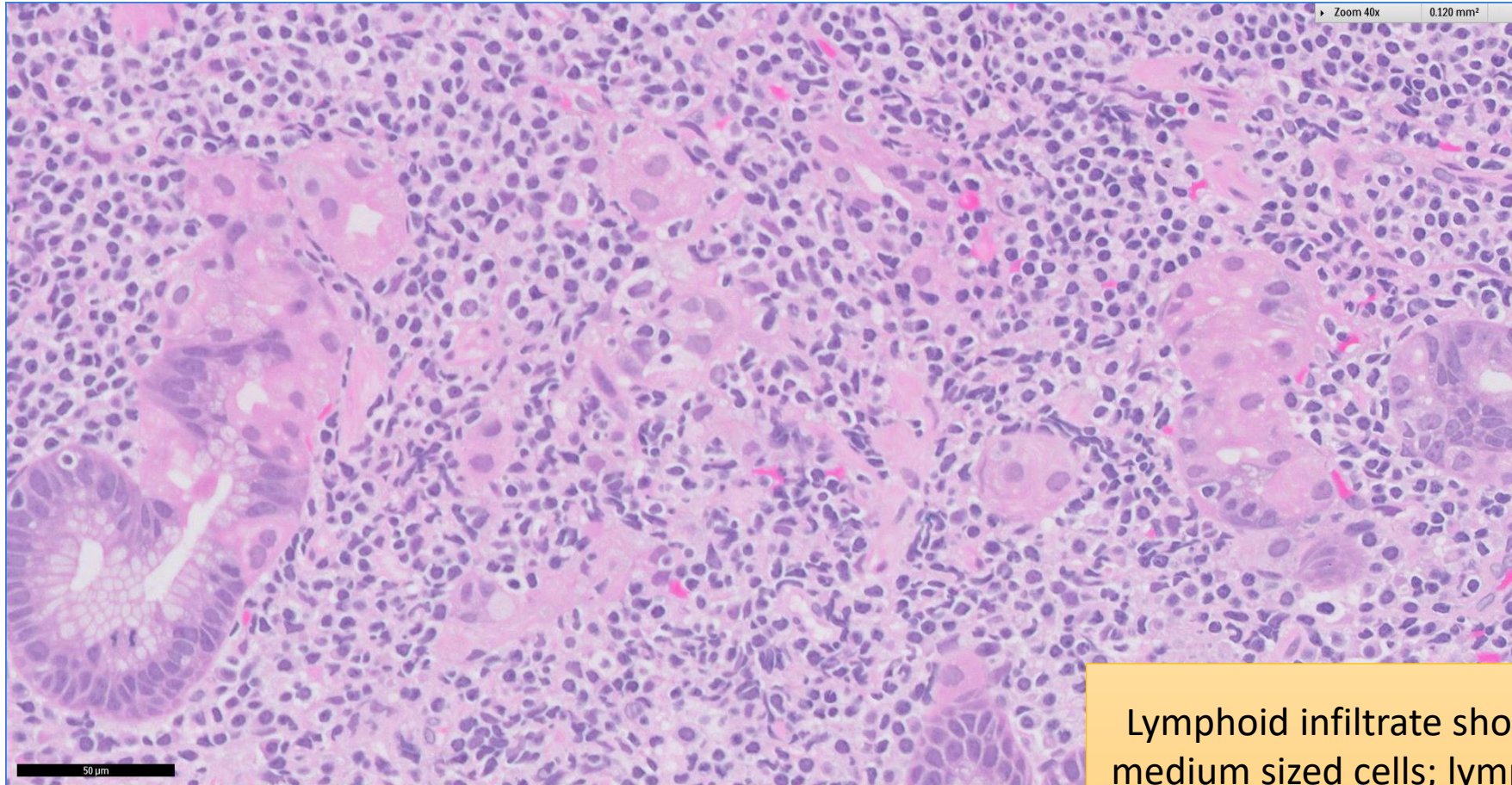
- Clinical History:
 - 50+ years old. Male.
- Specimen:
 - Endoscopic gastric biopsy.

SGH CASE 7: 17RE107 H&E



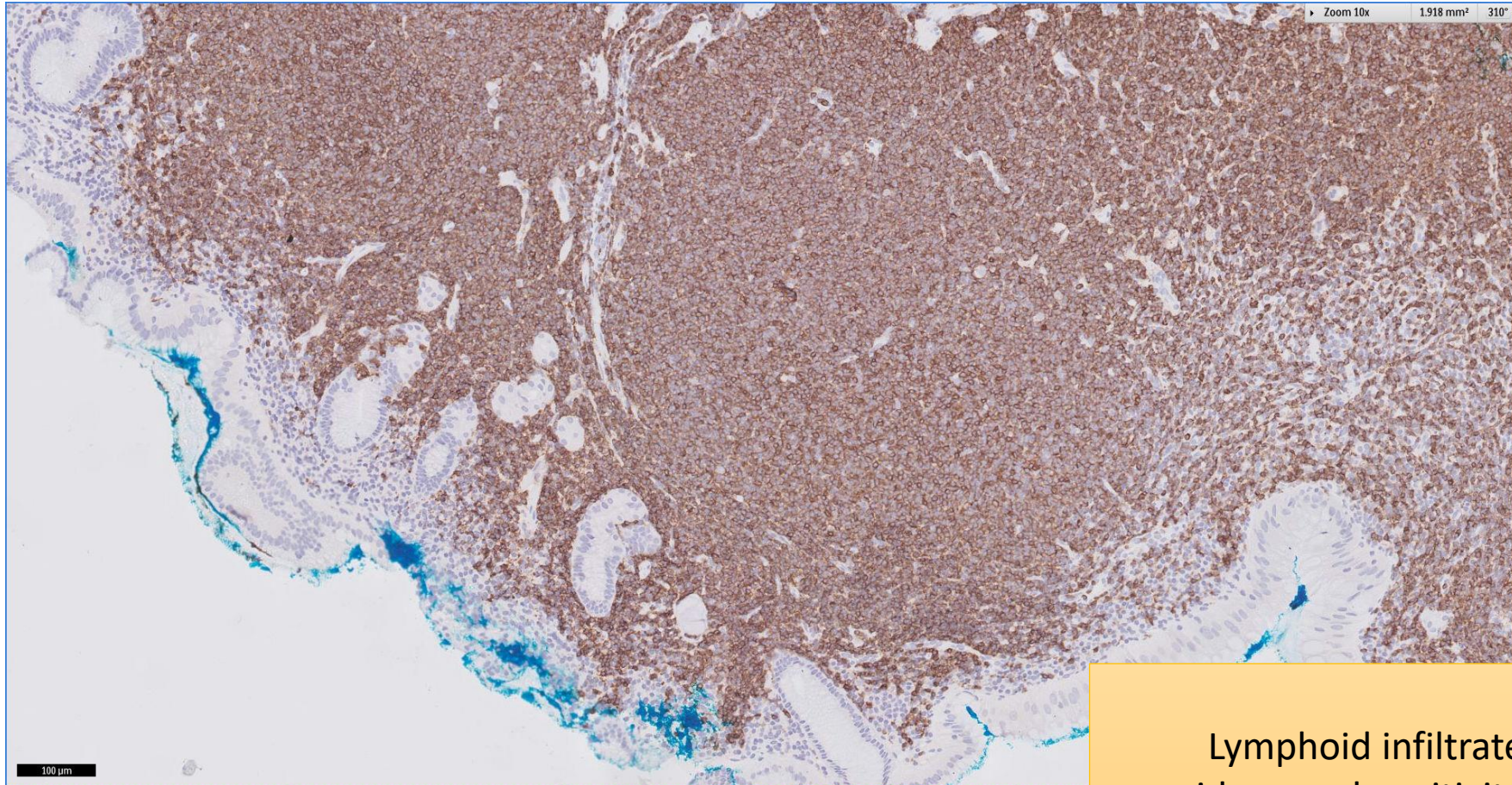
Gastric mucosa with lamina propria
markedly expanded by lymphoid
infiltrate

SGH CASE 7: 17RE107 H&E



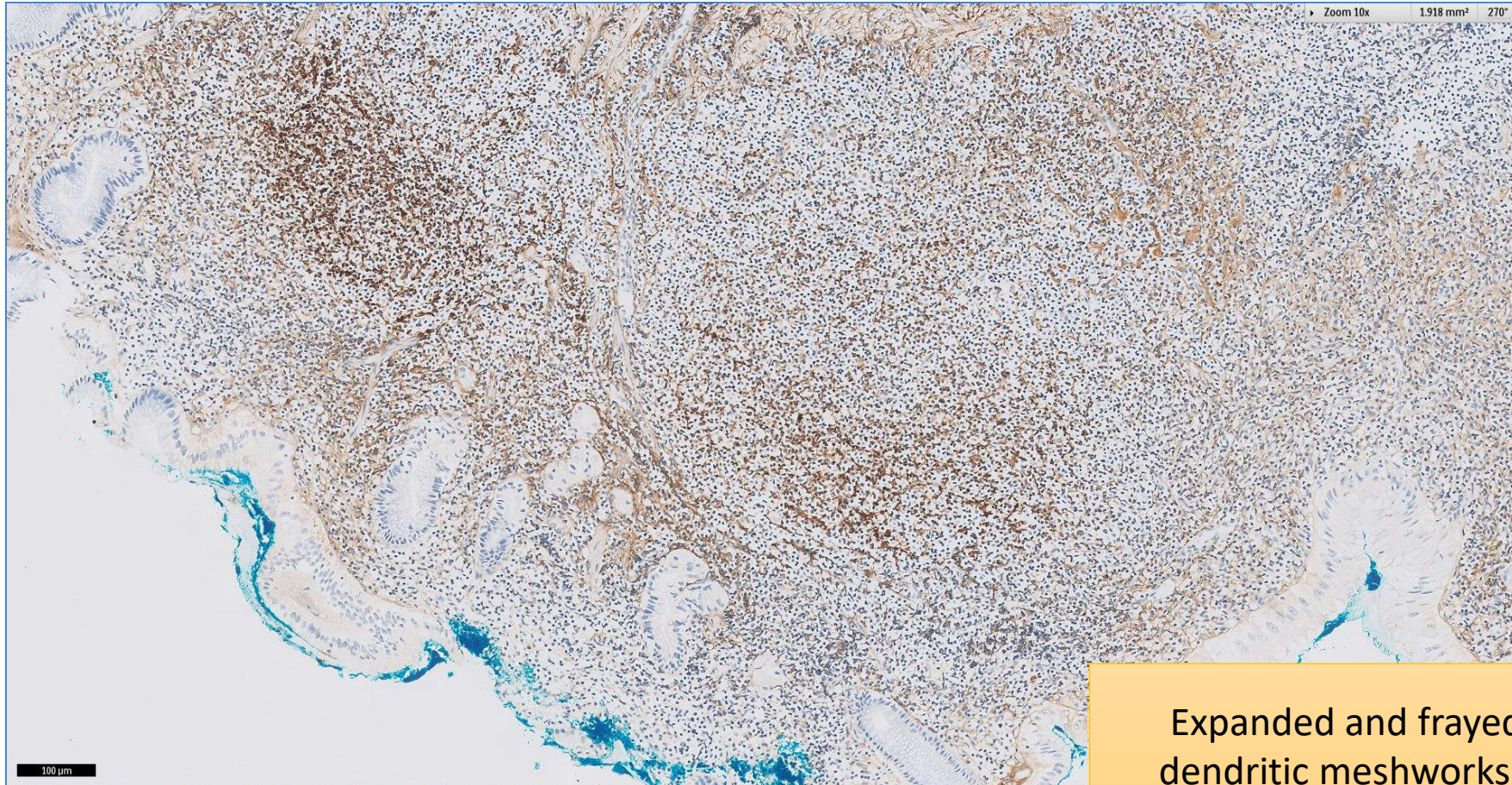
Lymphoid infiltrate shows small-to-medium sized cells; lymphoepithelial lesions present

SGH CASE 7: 17RE107 CD20



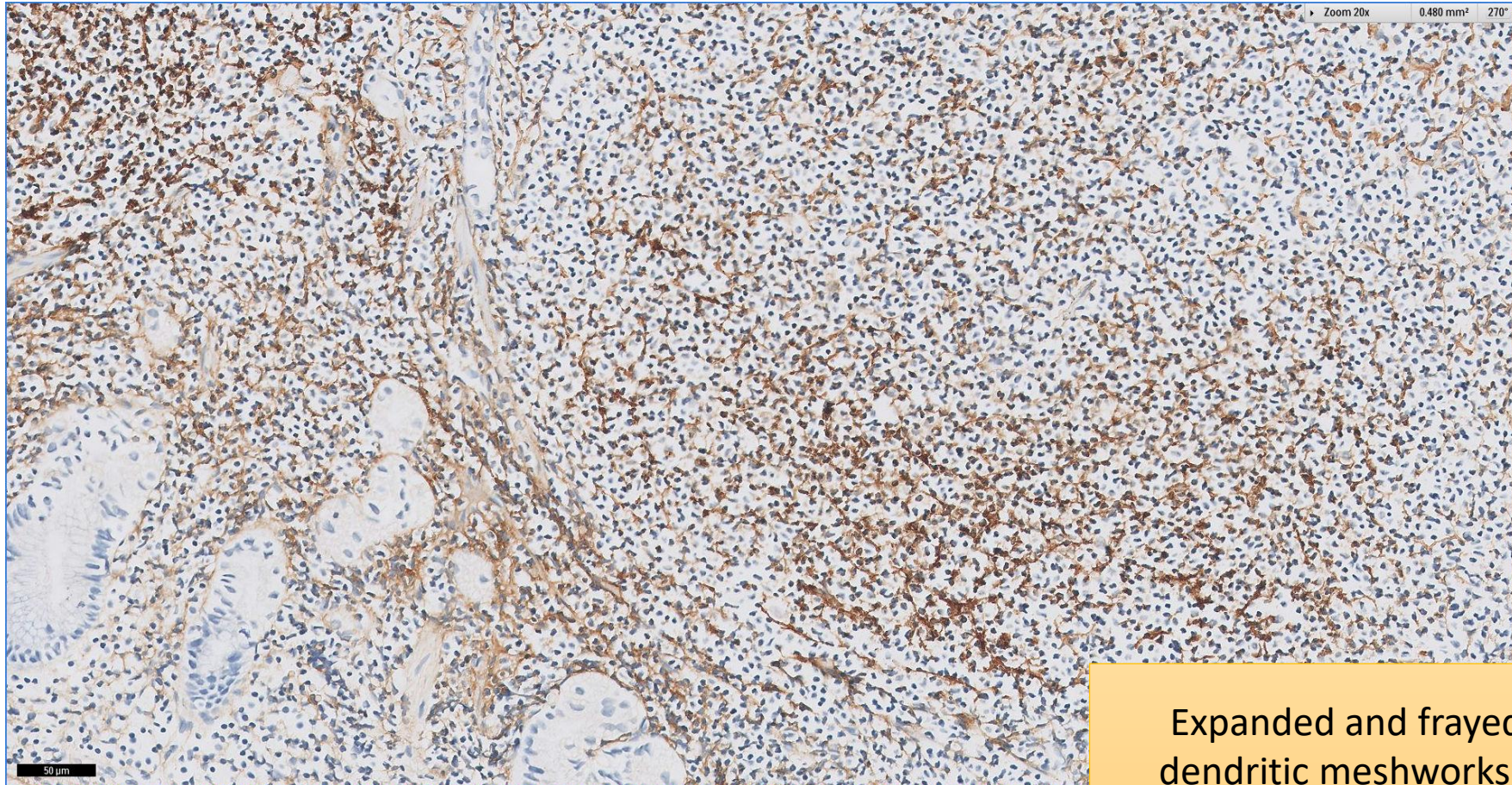
Lymphoid infiltrate shows
widespread positivity for CD20

SGH CASE 7: 17RE107 CD21



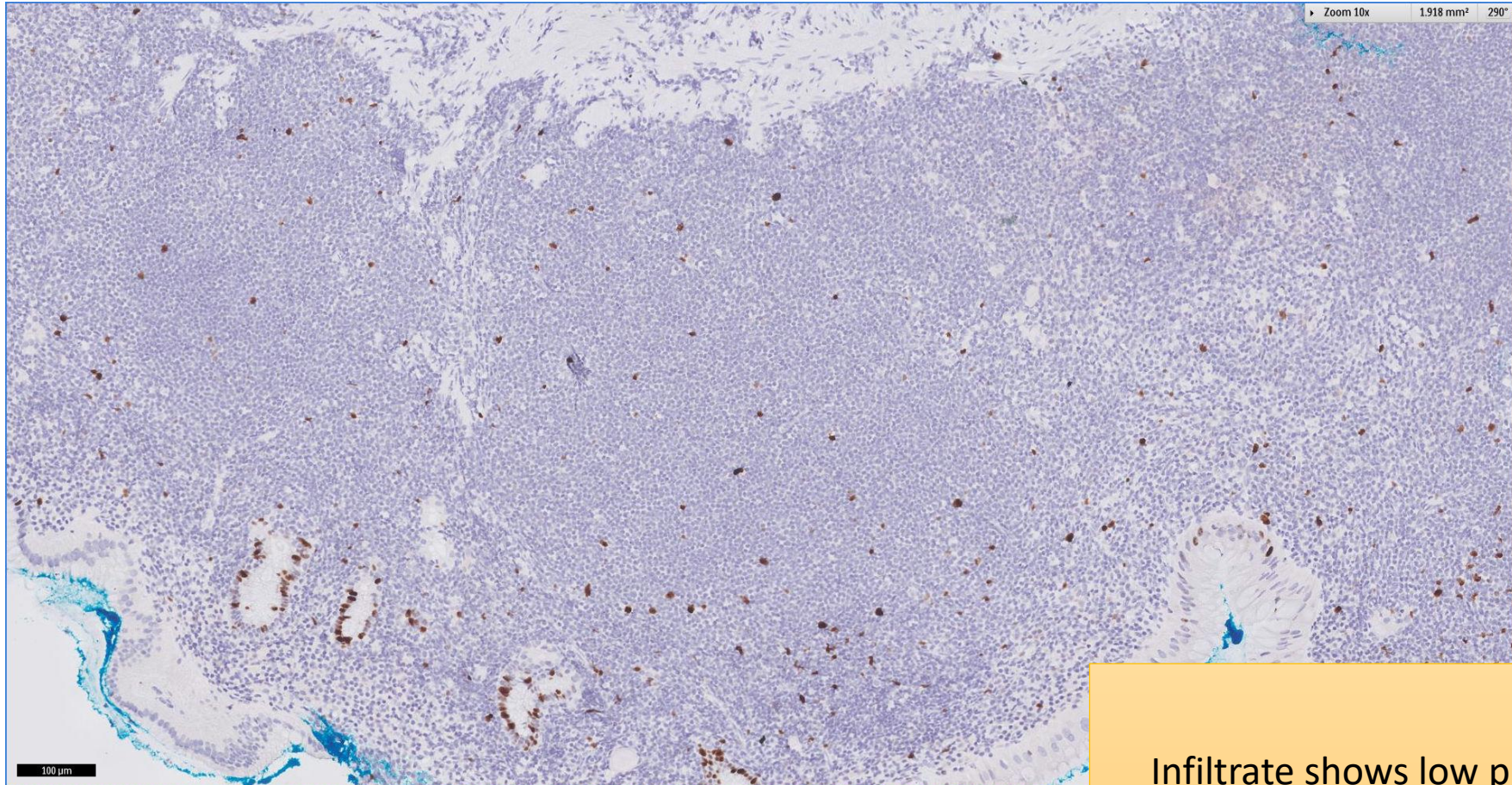
Expanded and frayed follicular
dendritic meshworks, reflecting
follicular colonisation

SGH CASE 7: 17RE107 CD21



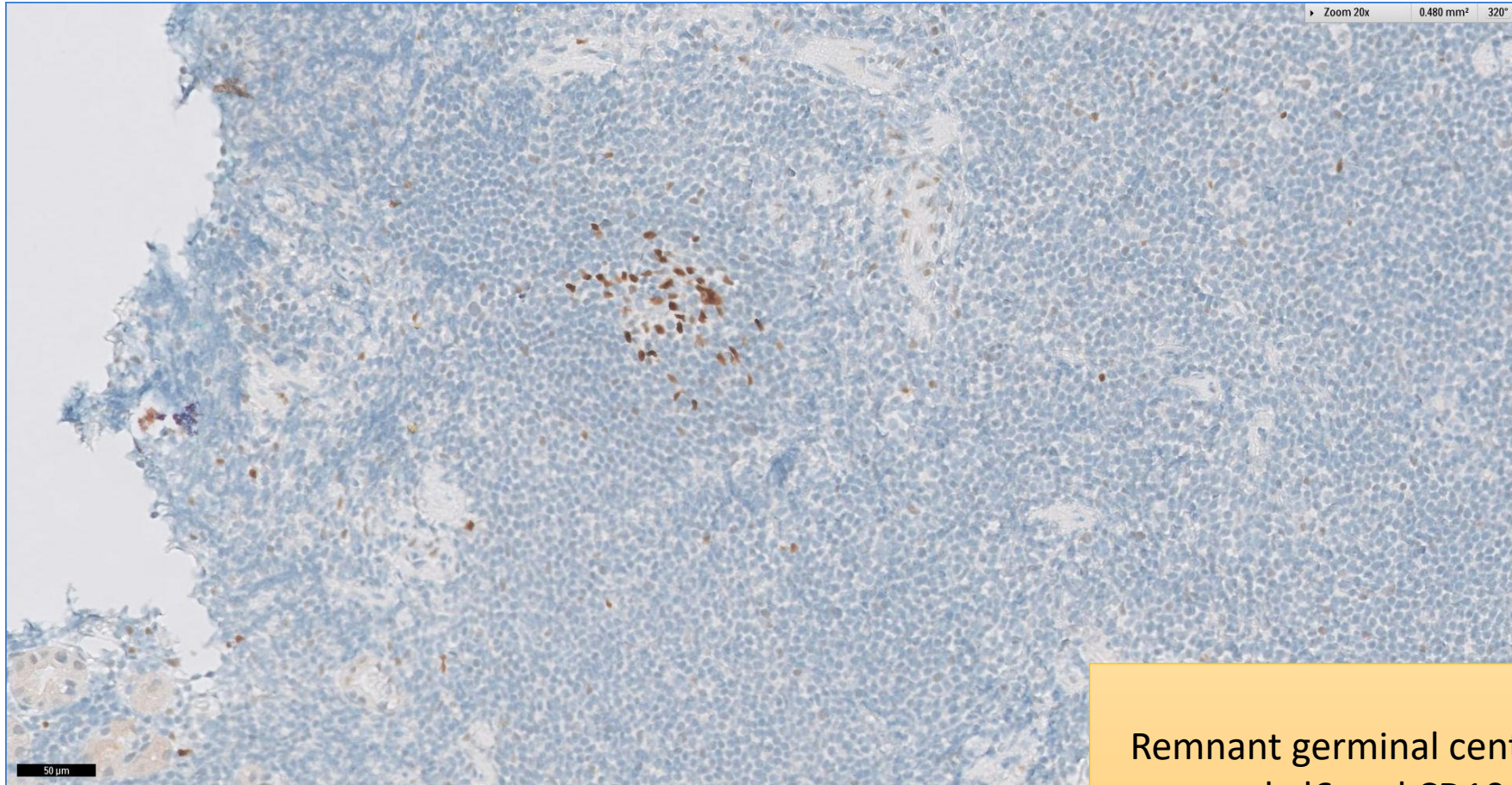
Expanded and frayed follicular dendritic meshworks, reflecting follicular colonisation

SGH CASE 7: 17RE107 KI67



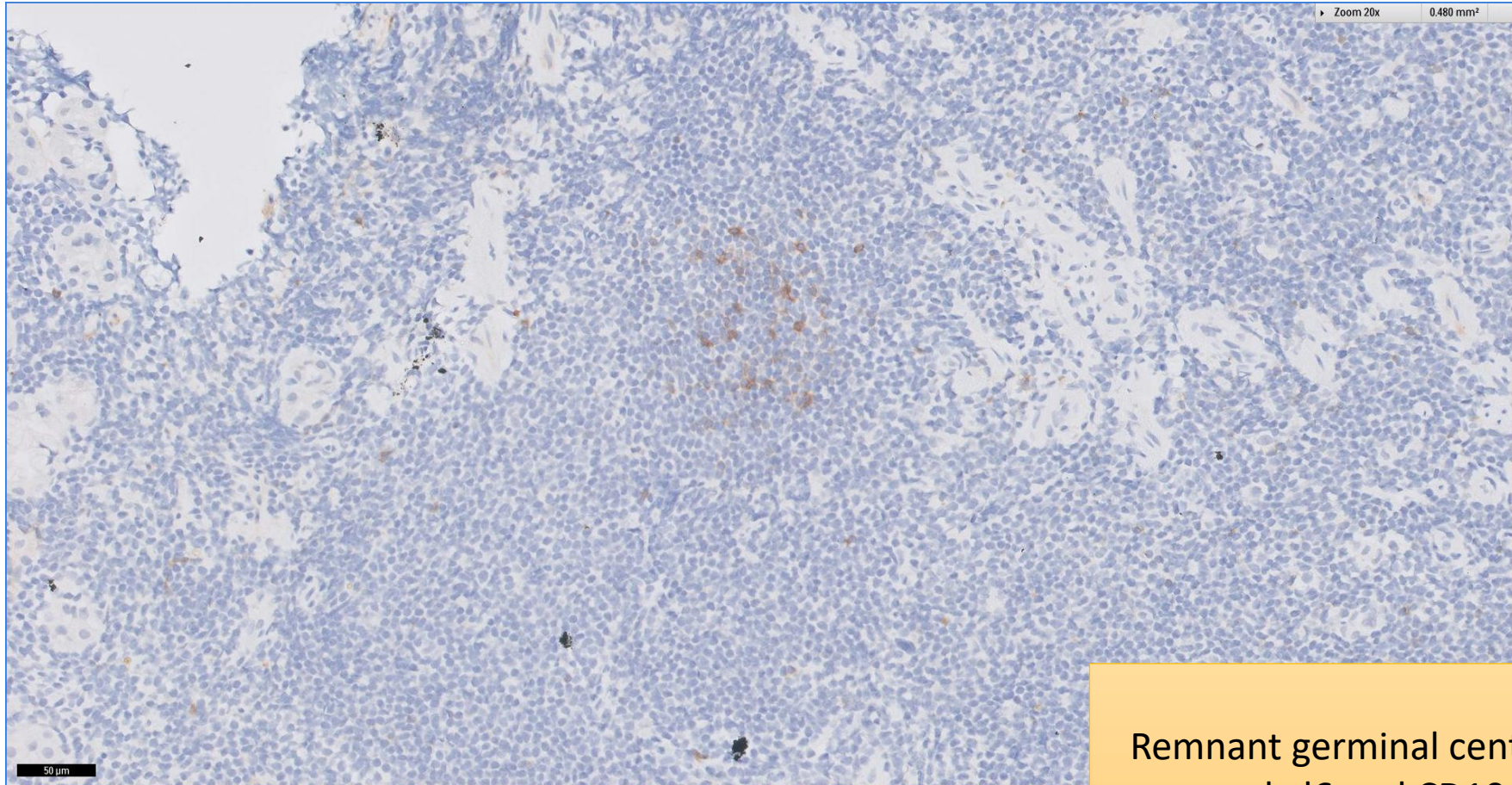
Infiltrate shows low proliferation

SGH CASE 7: 17RE107 BCL6



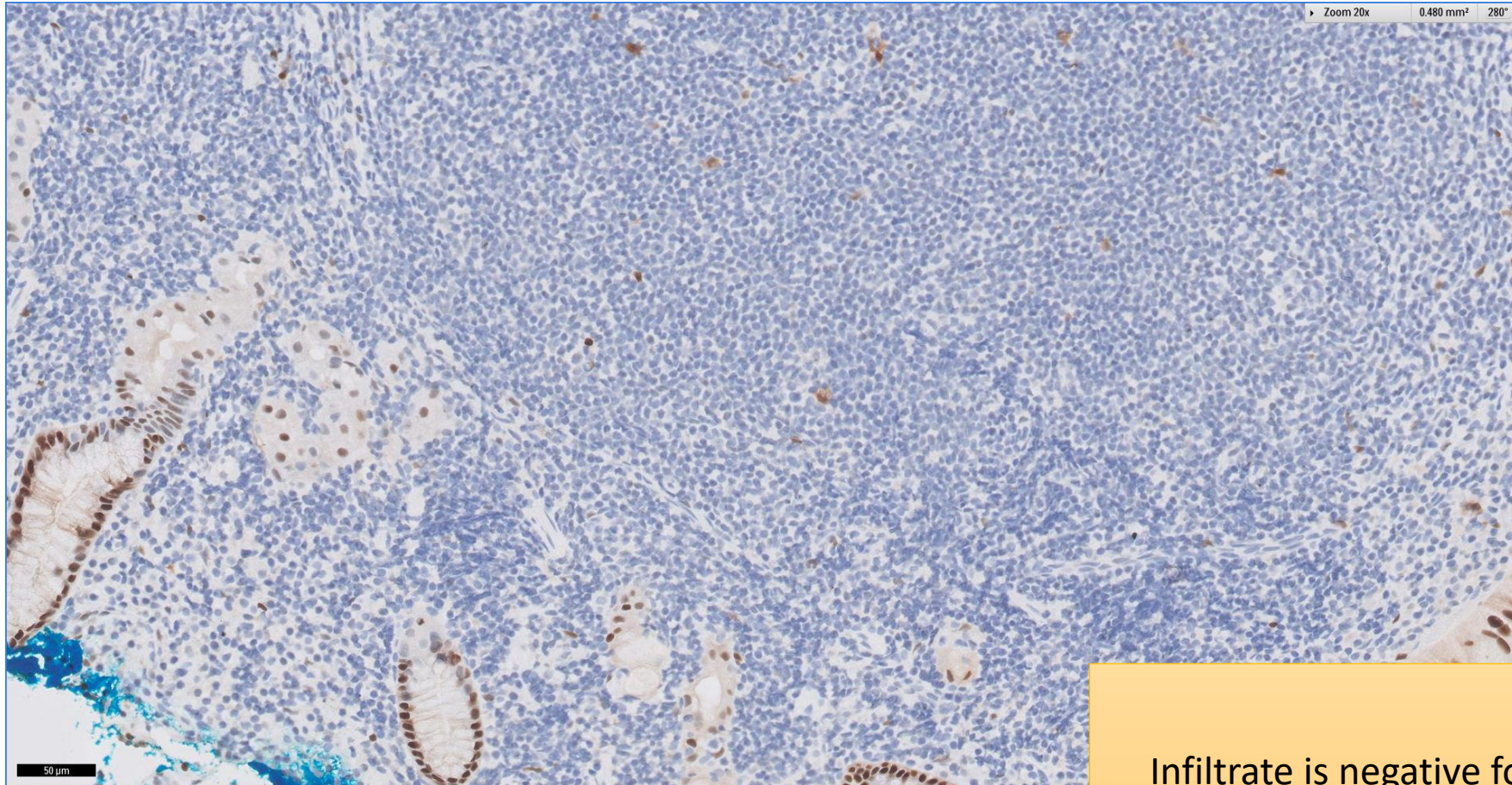
Remnant germinal centre cells that are bcl6 and CD10 positive

SGH CASE 7: 17RE107 CD10



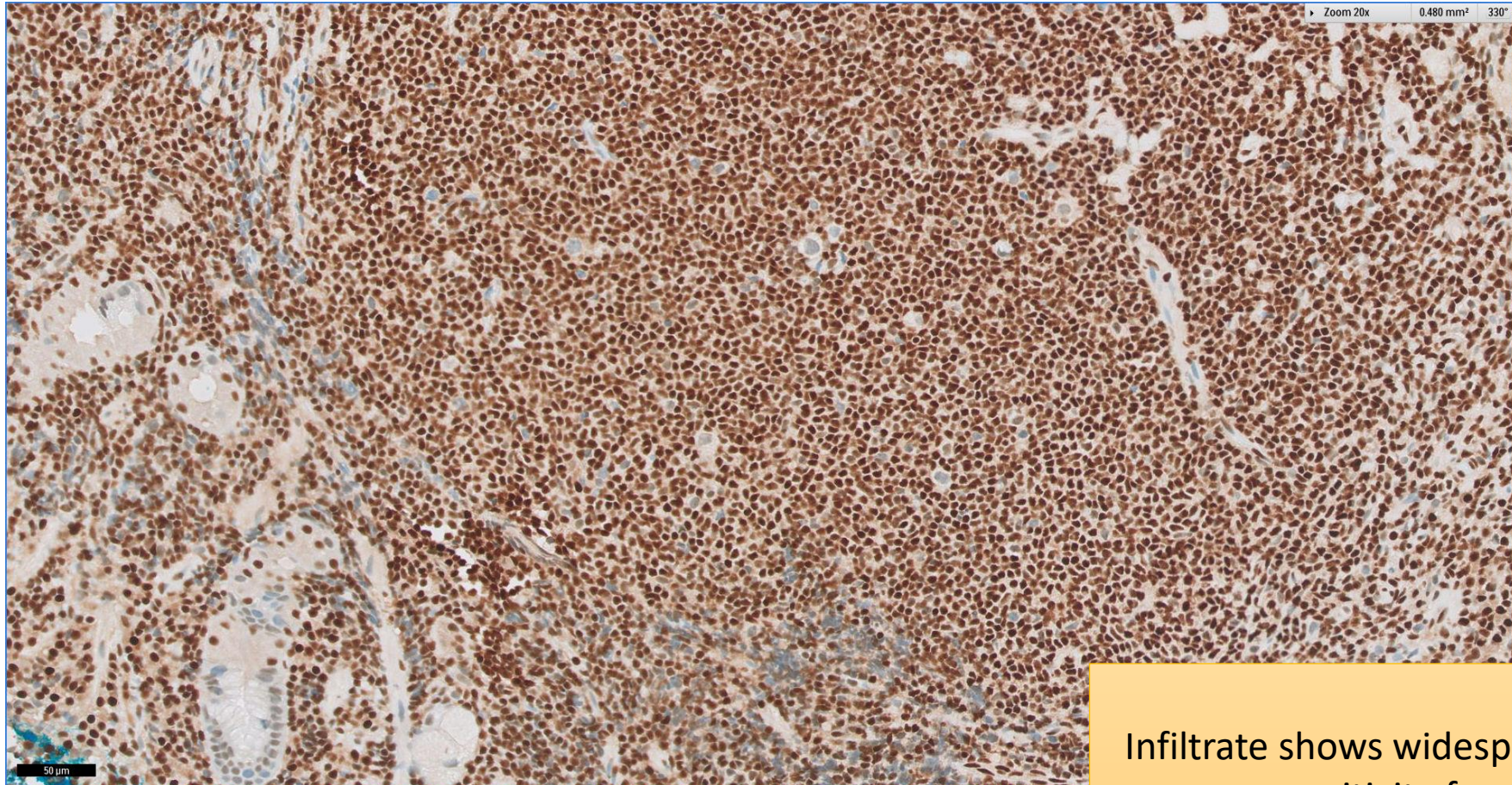
Remnant germinal centre cells that are bcl6 and CD10 positive

SGH CASE 7: 17RE107 CYCLIN D1



Infiltrate is negative for cyclin D1

SGH CASE 7: 17RE107 P27



Infiltrate shows widespread nuclear positivity for p27

SGH CASE 7: 17RE107

- Diagnosis
 - Extranodal Marginal Zone Lymphoma of Mucosa-associated Lymphoid Tissue