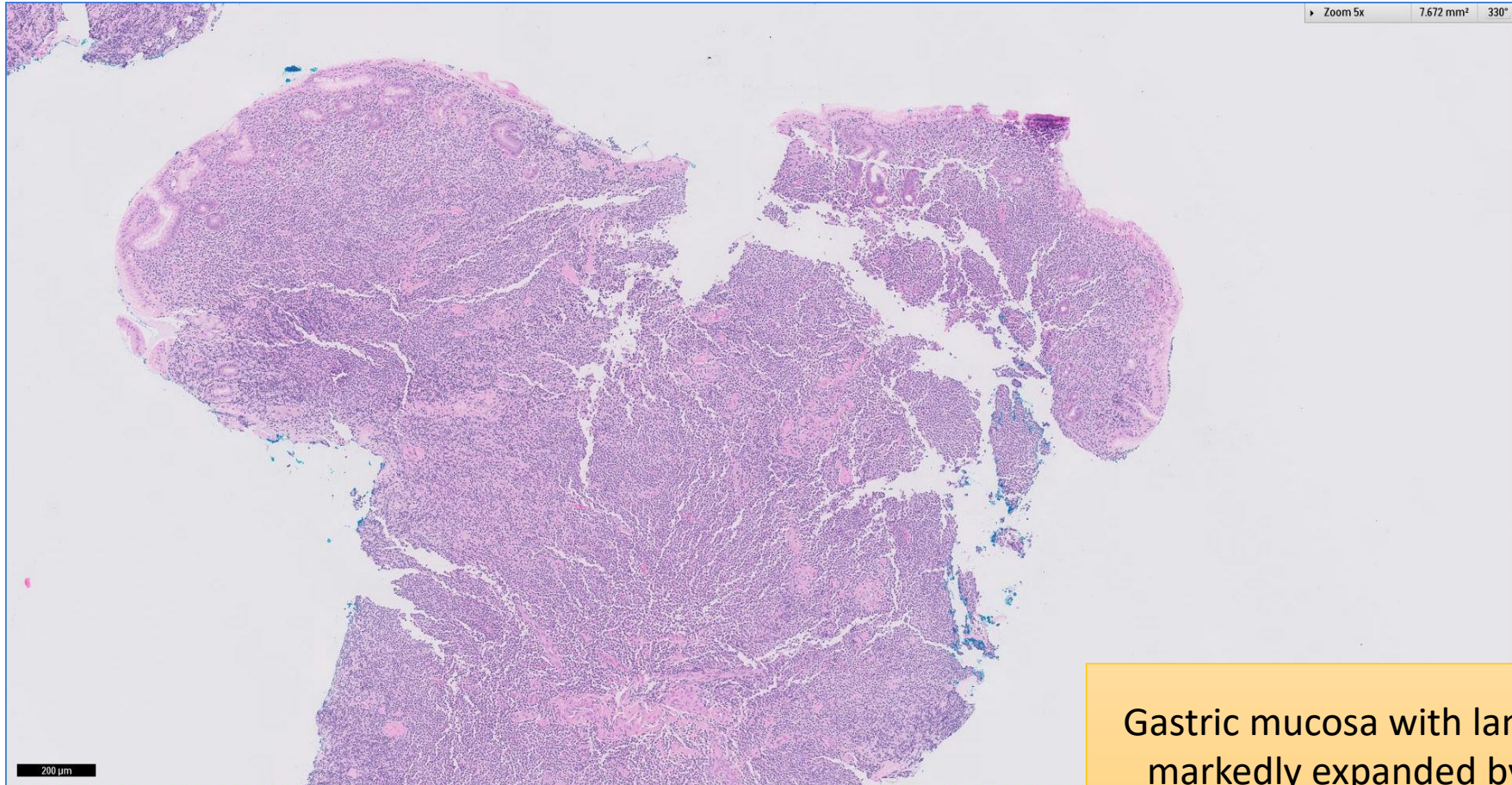


SGH CASE 6: 17RE106

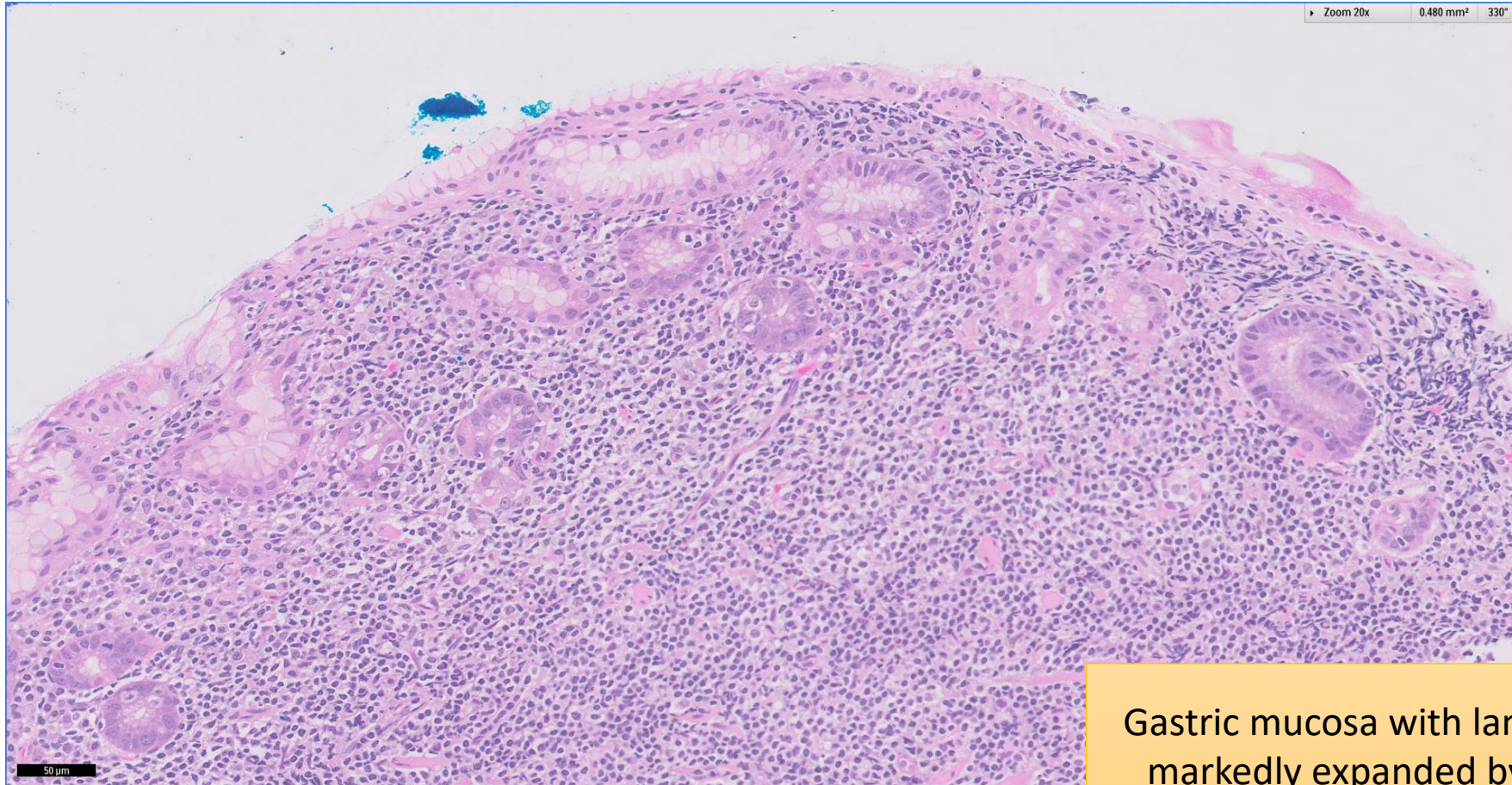
- Clinical History:
 - 50+ years old. Male.
- Specimen:
 - Endoscopic gastric biopsy

SGH CASE 6: 17RE106 H&E



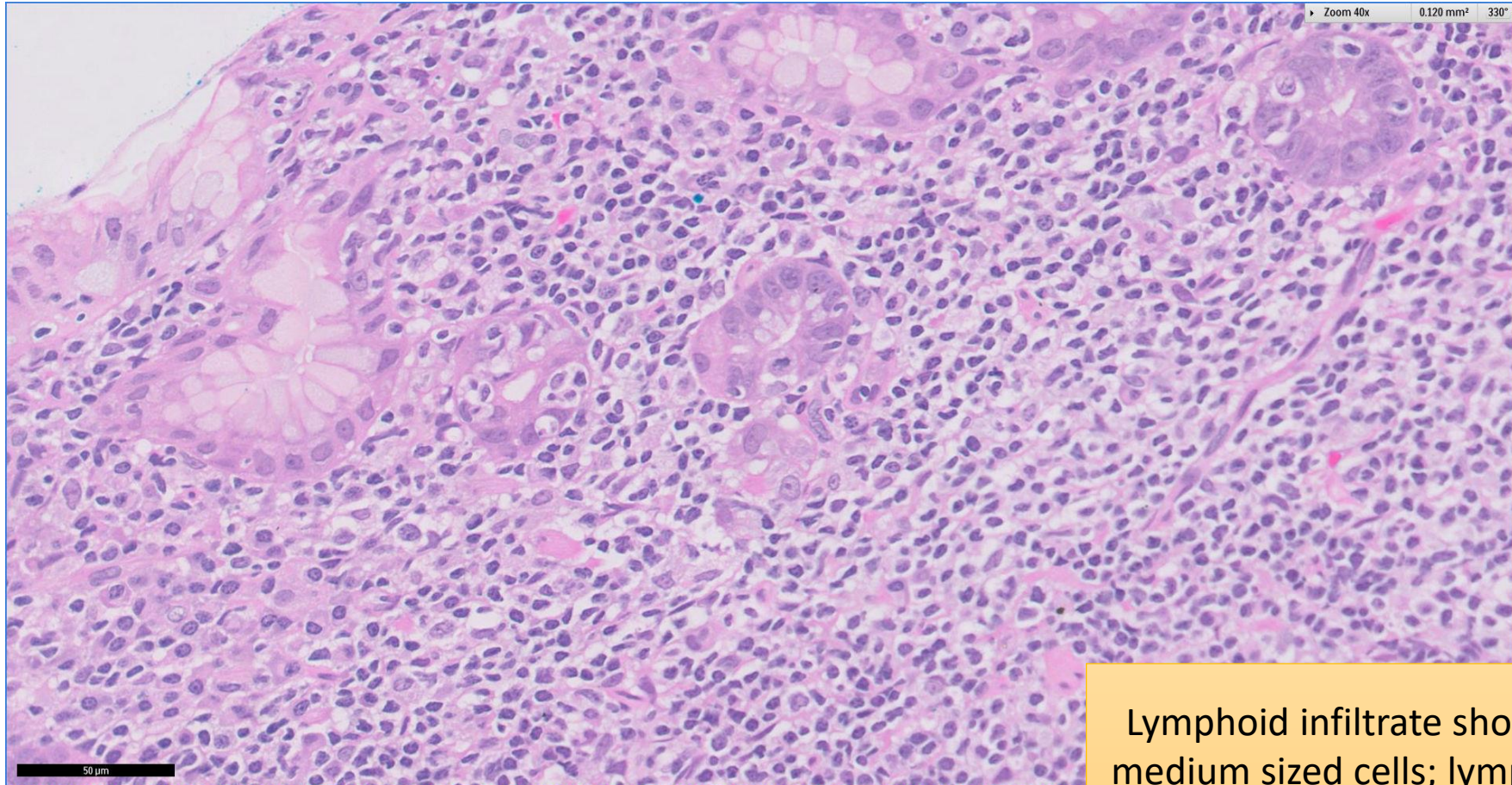
Gastric mucosa with lamina propria
markedly expanded by lymphoid
infiltrate

SGH CASE 6: 17RE106 H&E



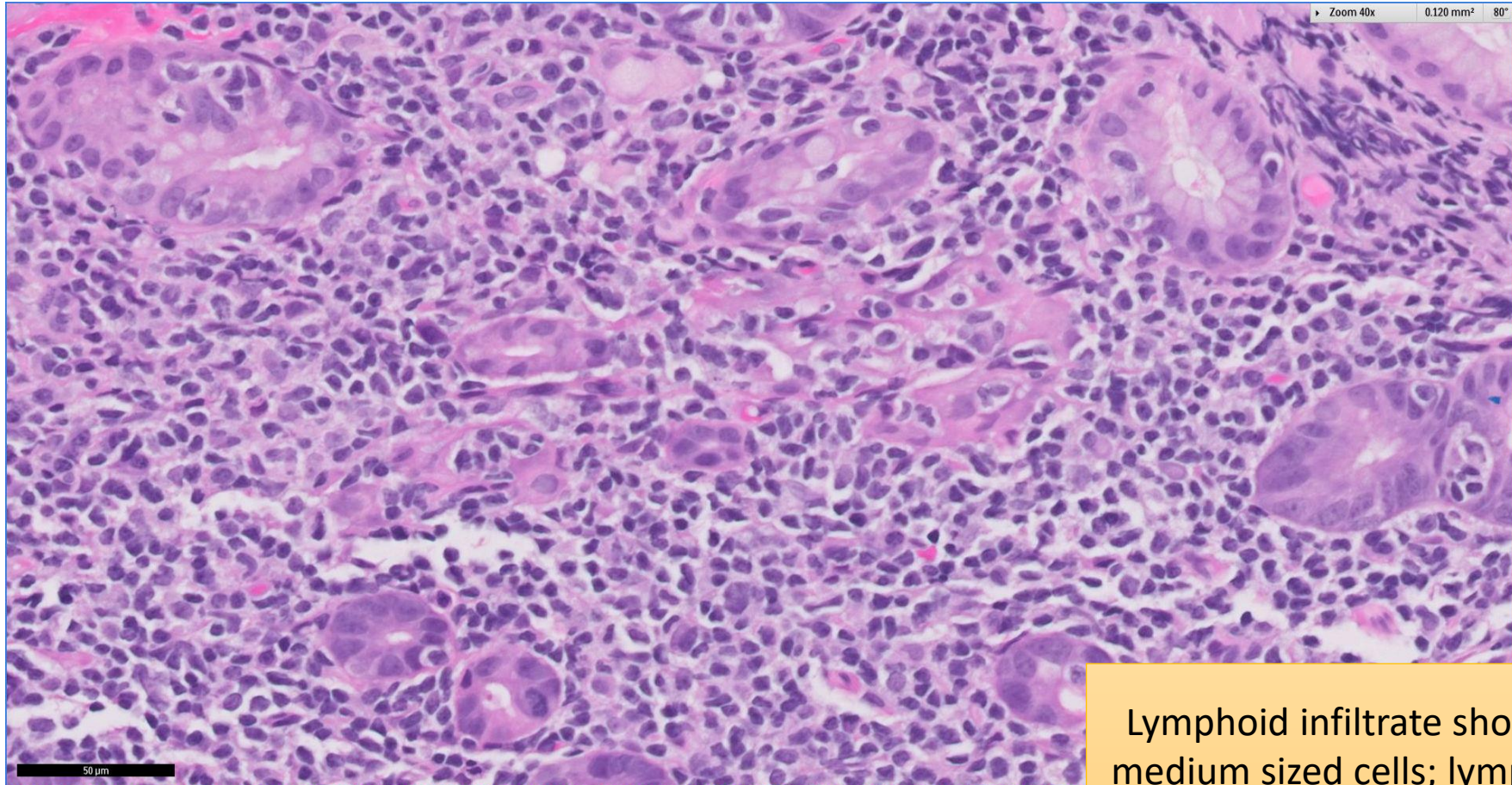
Gastric mucosa with lamina propria markedly expanded by lymphoid infiltrate

SGH CASE 6: 17RE106 H&E



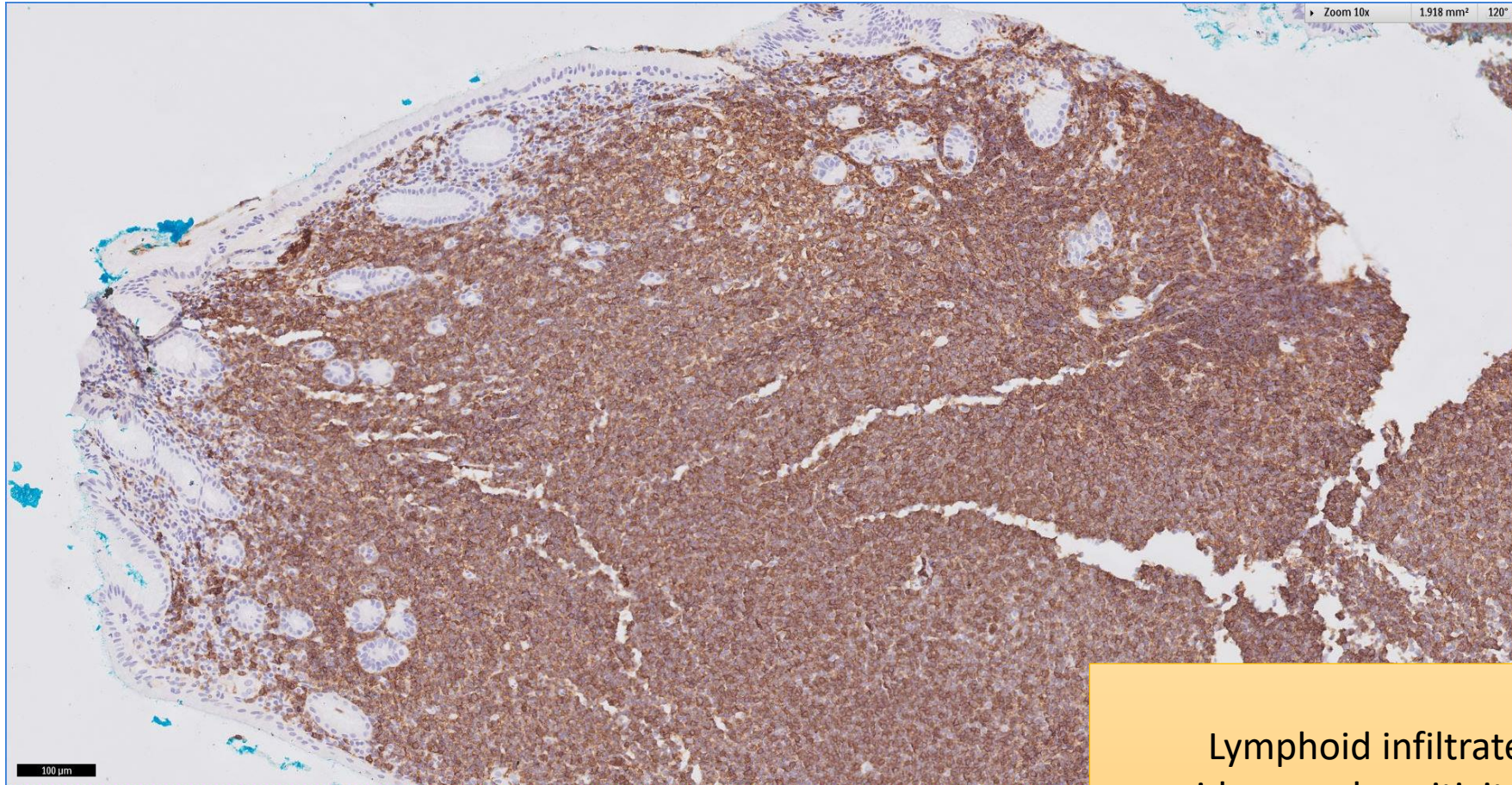
Lymphoid infiltrate shows small-to-medium sized cells; lymphoepithelial lesions present

SGH CASE 6: 17RE106 H&E



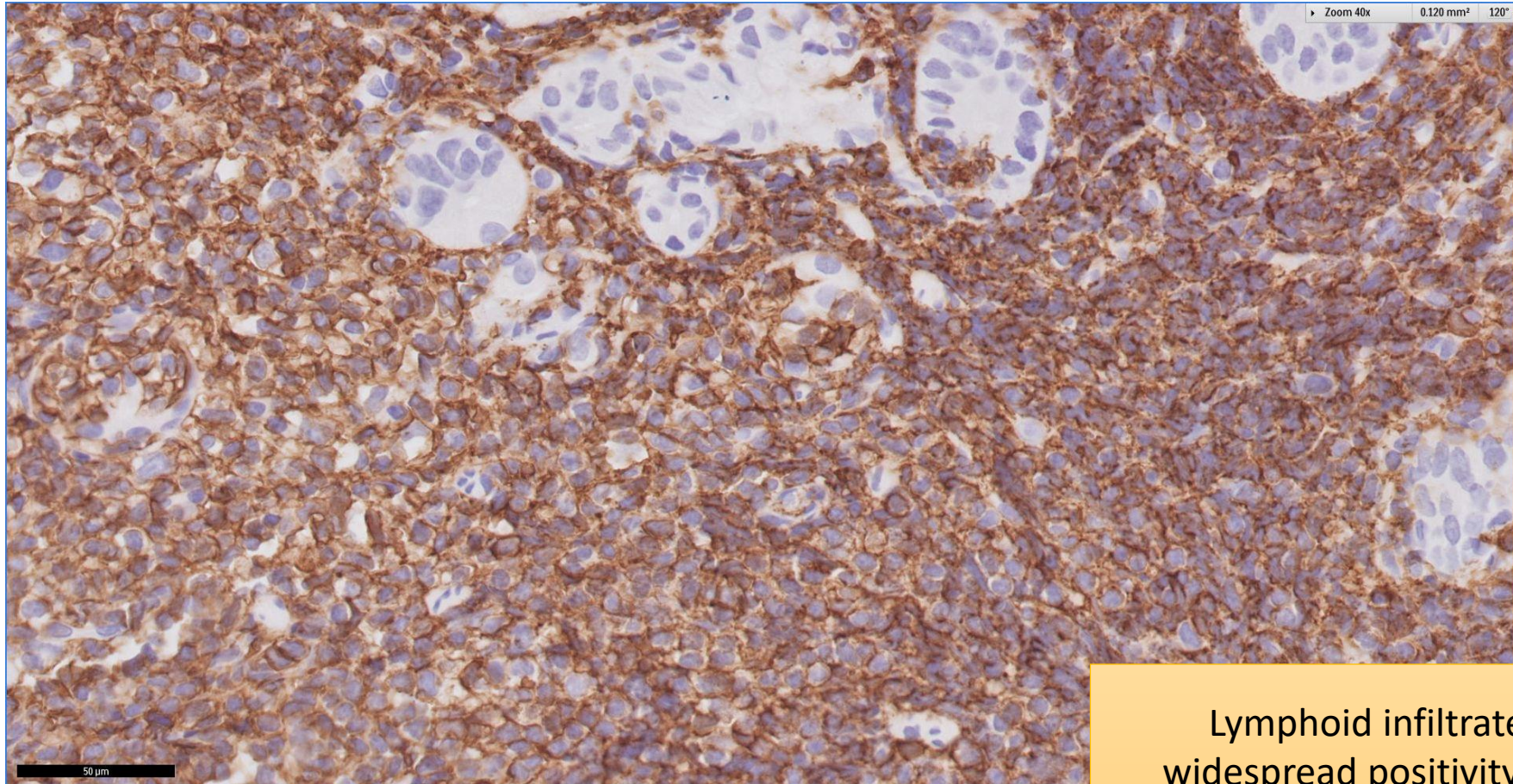
Lymphoid infiltrate shows small-to-medium sized cells; lymphoepithelial lesions present

SGH CASE 6: 17RE106 CD20



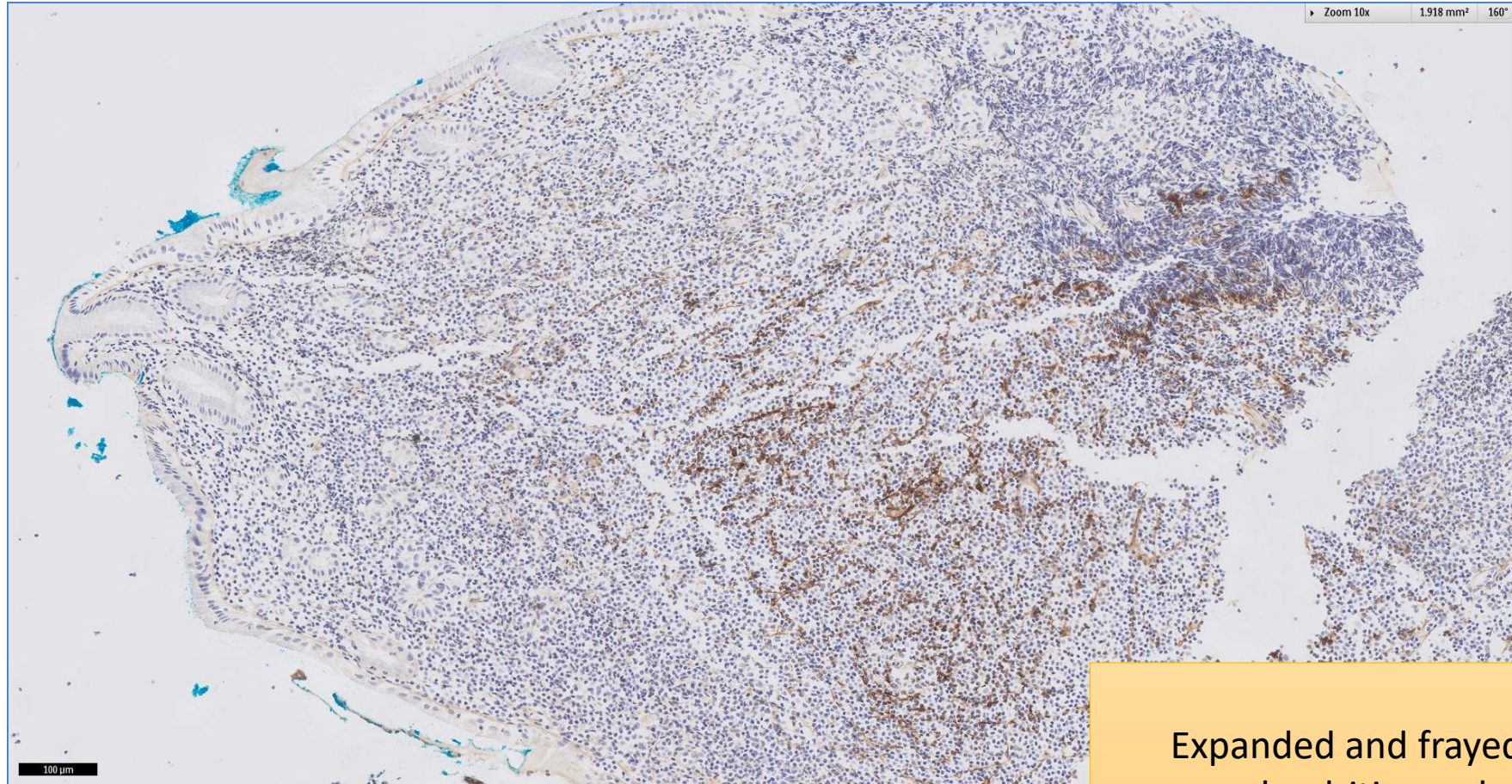
Lymphoid infiltrate shows
widespread positivity for CD20

SGH CASE 6: 17RE106 CD20



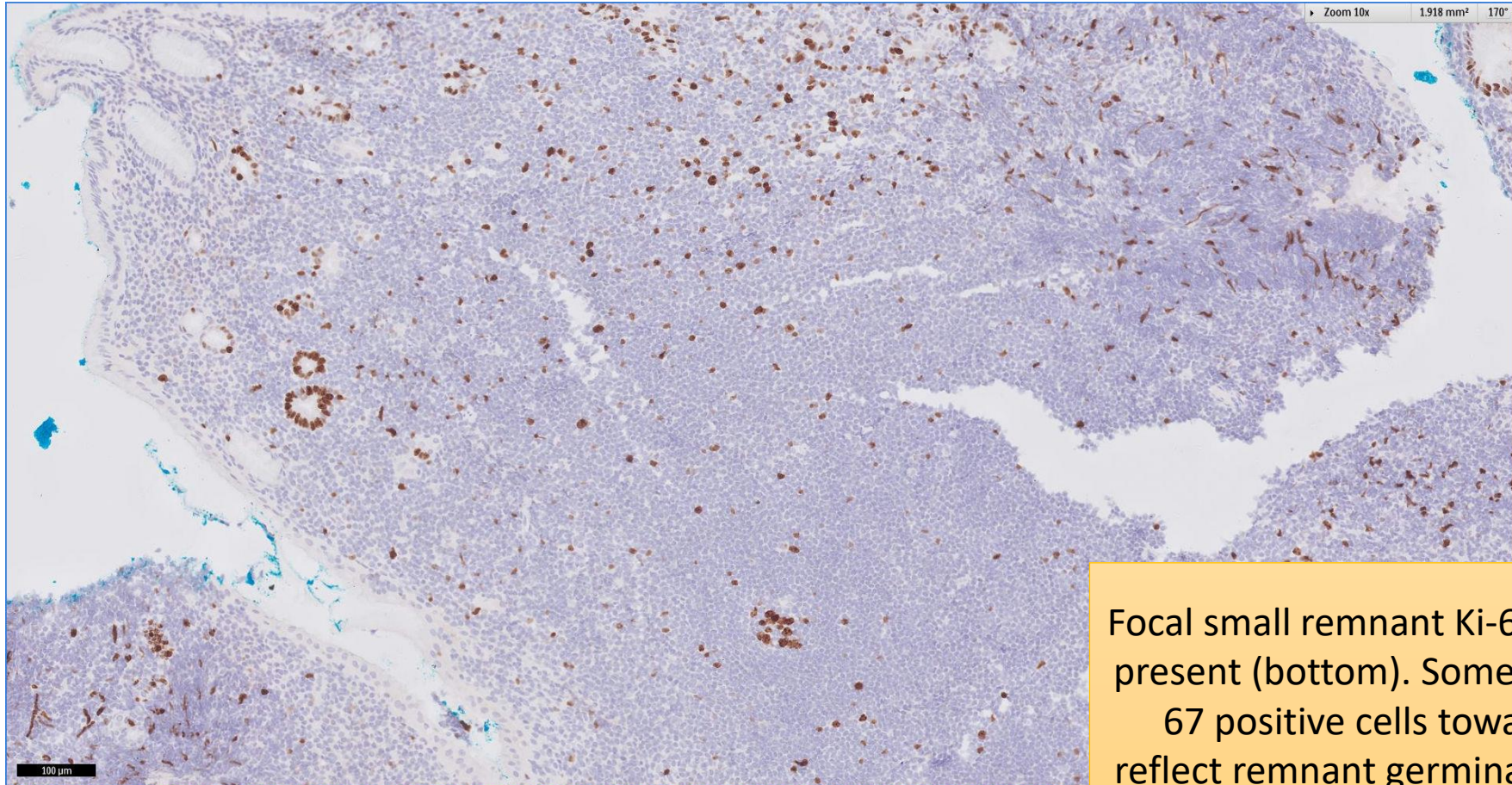
Lymphoid infiltrate shows
widespread positivity for CD20,
encroaching on epithelial elements

SGH CASE 6: 17RE106 CD21



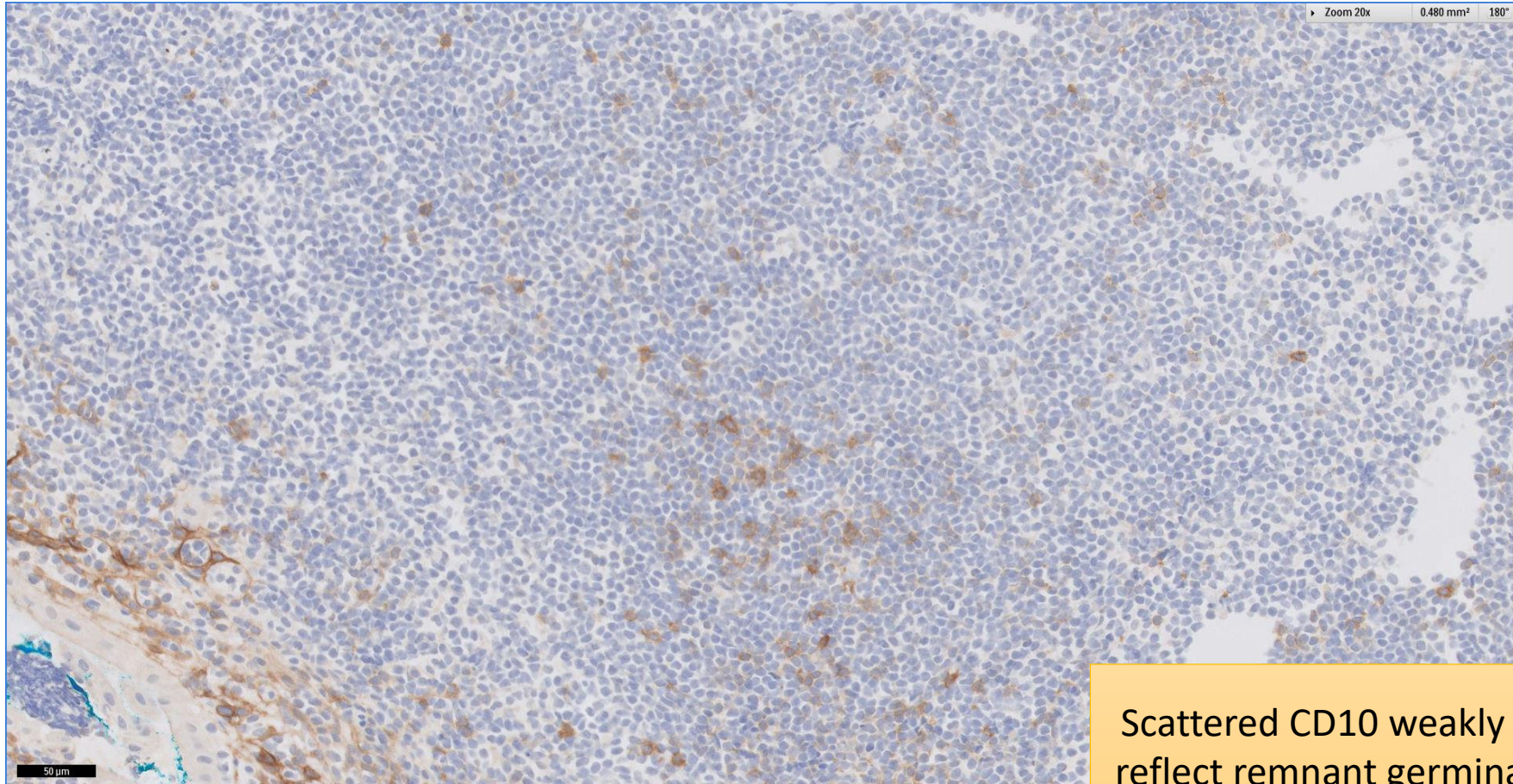
Expanded and frayed follicular
dendritic meshworks

SGH CASE 6: 17RE106 KI67



Focal small remnant Ki-67 high follicle present (bottom). Some scattered Ki-67 positive cells towards to top reflect remnant germinal centre cells of colonised follicles

SGH CASE 6: 17RE106 CD10



Scattered CD10 weakly positive cells
reflect remnant germinal centre cells
of colonised follicles

SGH CASE 6: 17RE106

- Diagnosis
 - Extranodal Marginal Zone Lymphoma of Mucosa-associated Lymphoid Tissue