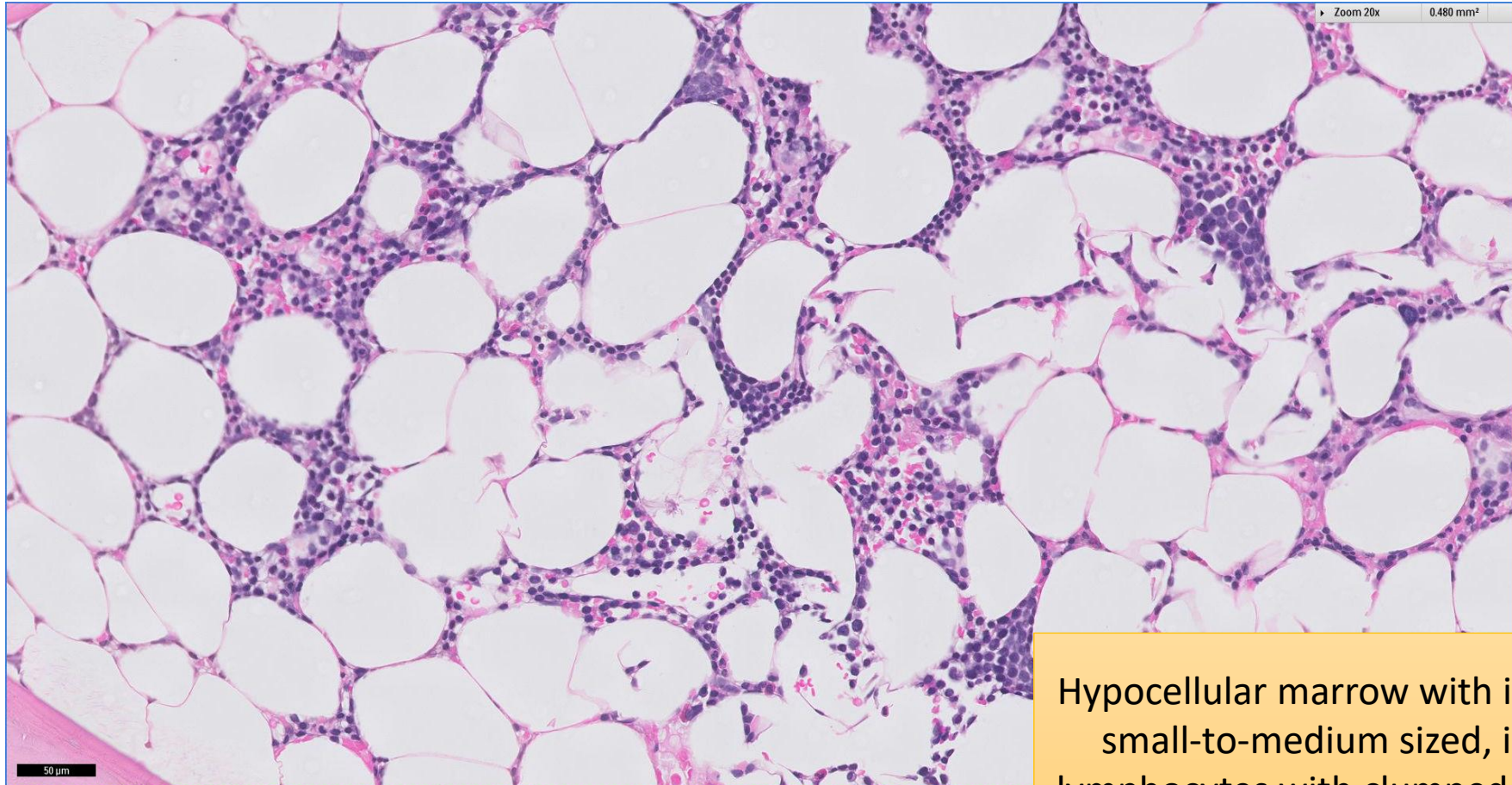


# SGH CASE 4: 17RE104

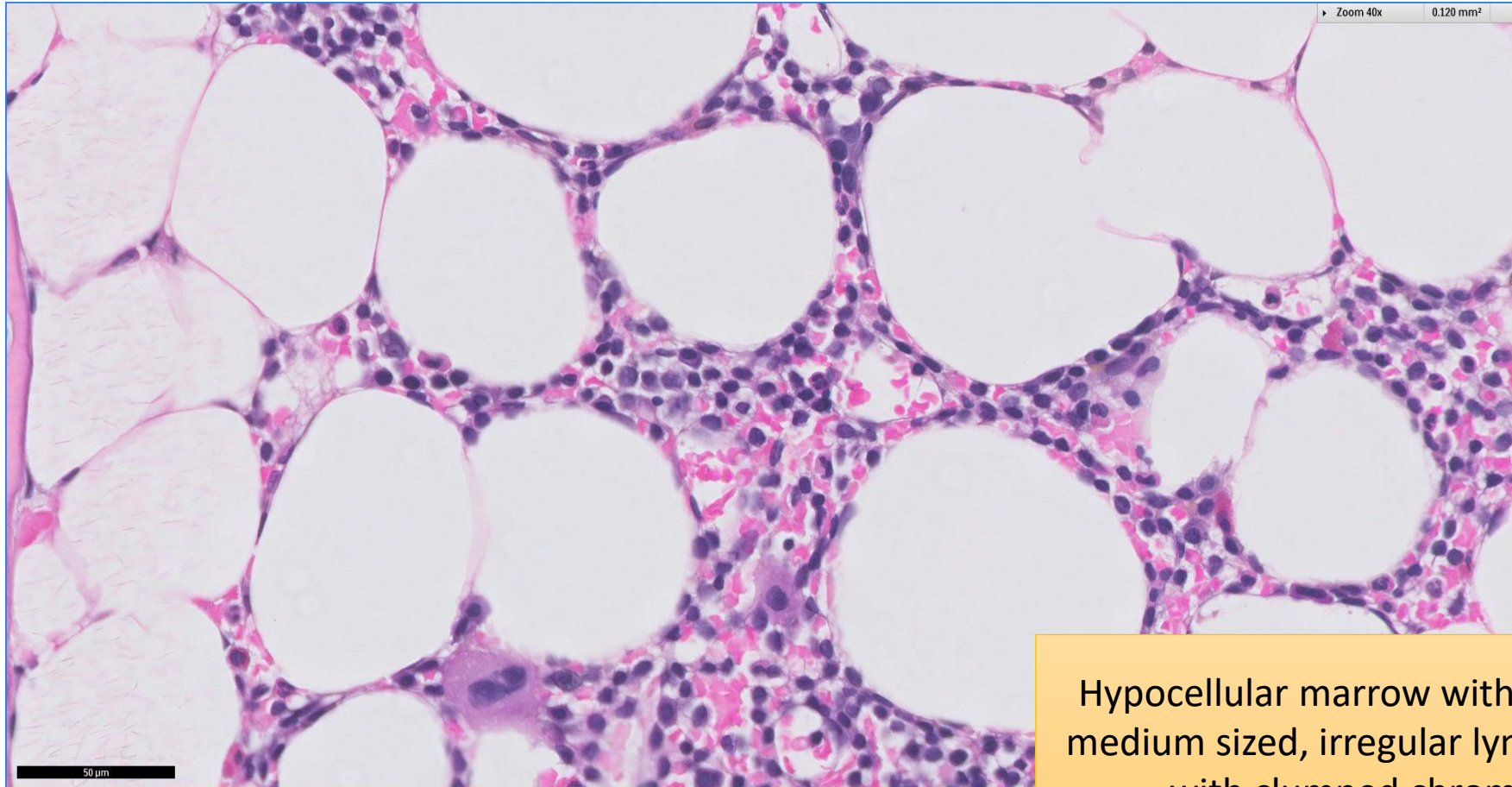
- Clinical History:
  - 60+ years old. Male. Mild lymphocytosis (absolute lymphocyte count  $4.95 \times 10^9/L$ )
- Specimen:
  - Bone marrow trephine biopsy.

# SGH CASE 4: 17RE104 H&E



Hypocellular marrow with infiltrate of small-to-medium sized, irregular lymphocytes with clumped chromatin

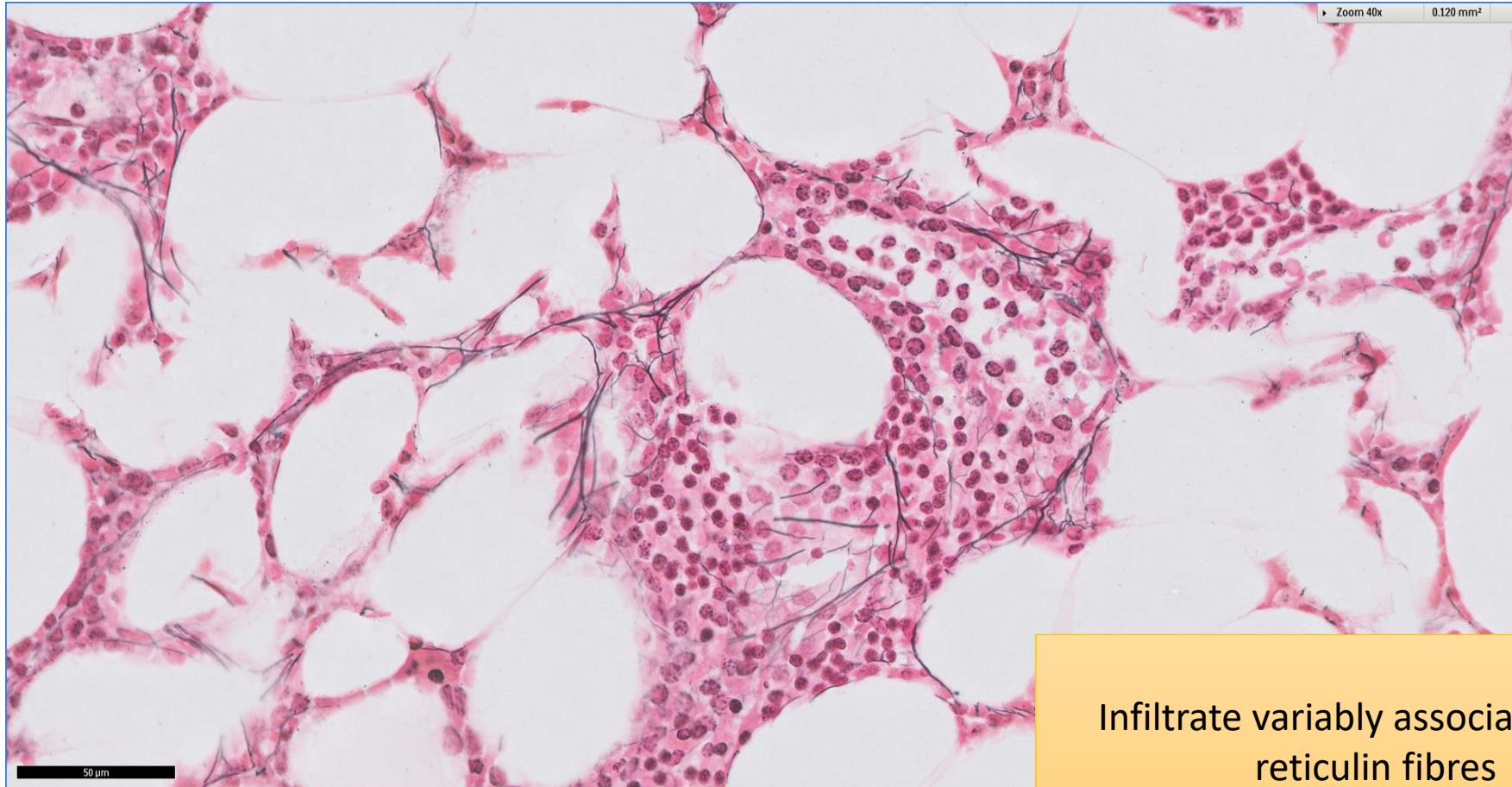
# SGH CASE 4: 17RE104 H&E



Hypocellular marrow with small-to-medium sized, irregular lymphocytes with clumped chromatin



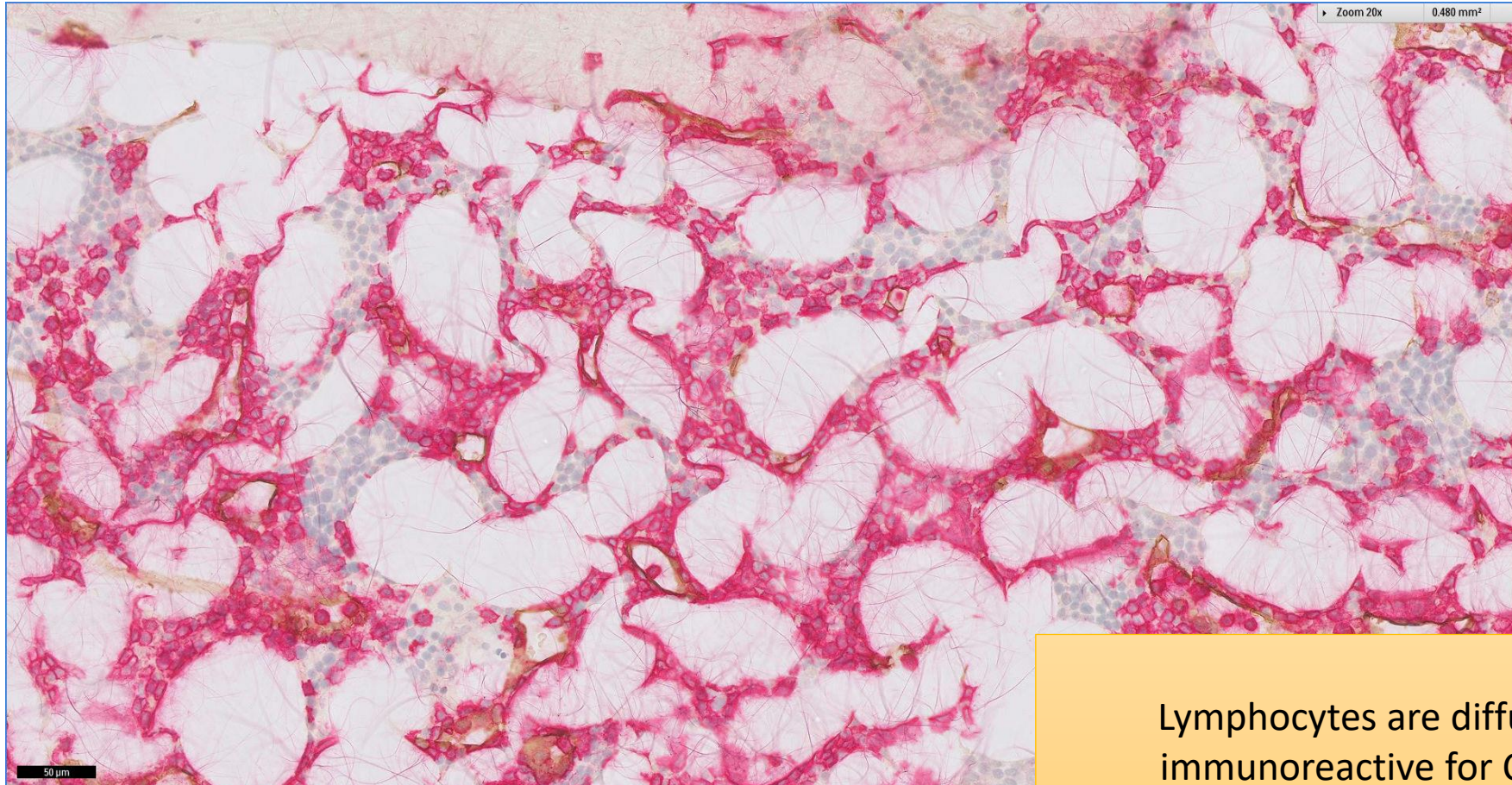
# SGH CASE 4: 17RE104 RETICULIN



Infiltrate variably associated with reticulin fibres



# SGH CASE 4: 17RE104 CD20(RED)

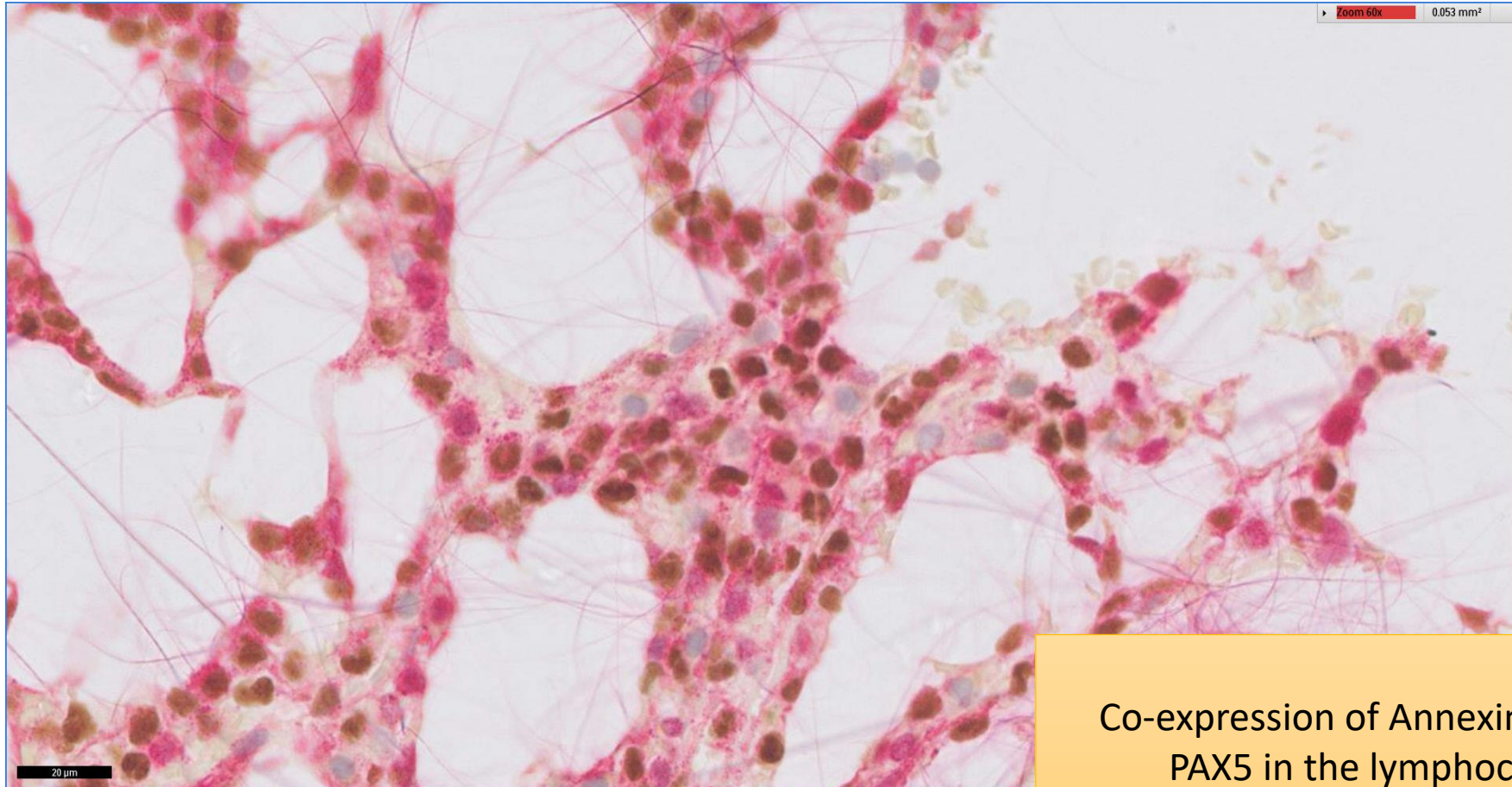


Lymphocytes are diffusely immunoreactive for CD20



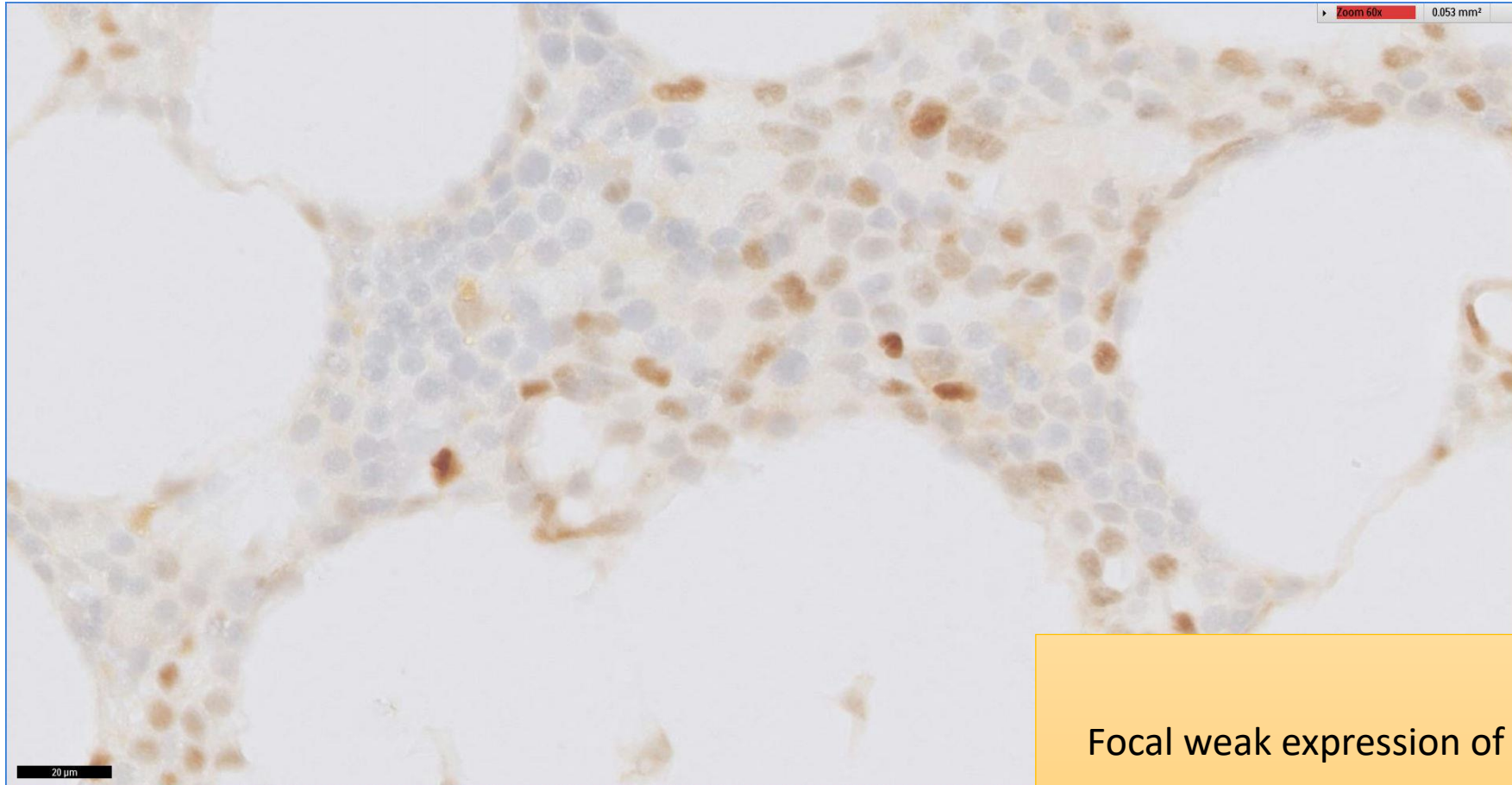
# SGH CASE 4: 17RE104

## PAX5(BROWN) ANNEXIN A1 (RED)



Co-expression of Annexin A1 and  
PAX5 in the lymphocytes

# SGH CASE 4: 17RE104 CYCLIN D1



Focal weak expression of cyclin D1

# SGH CASE 4: 17RE104

- Diagnosis
  - Hairy Cell Leukaemia
- Marrow aspirate parameters, including cytochemistry and flow cytometry, are corroborative.