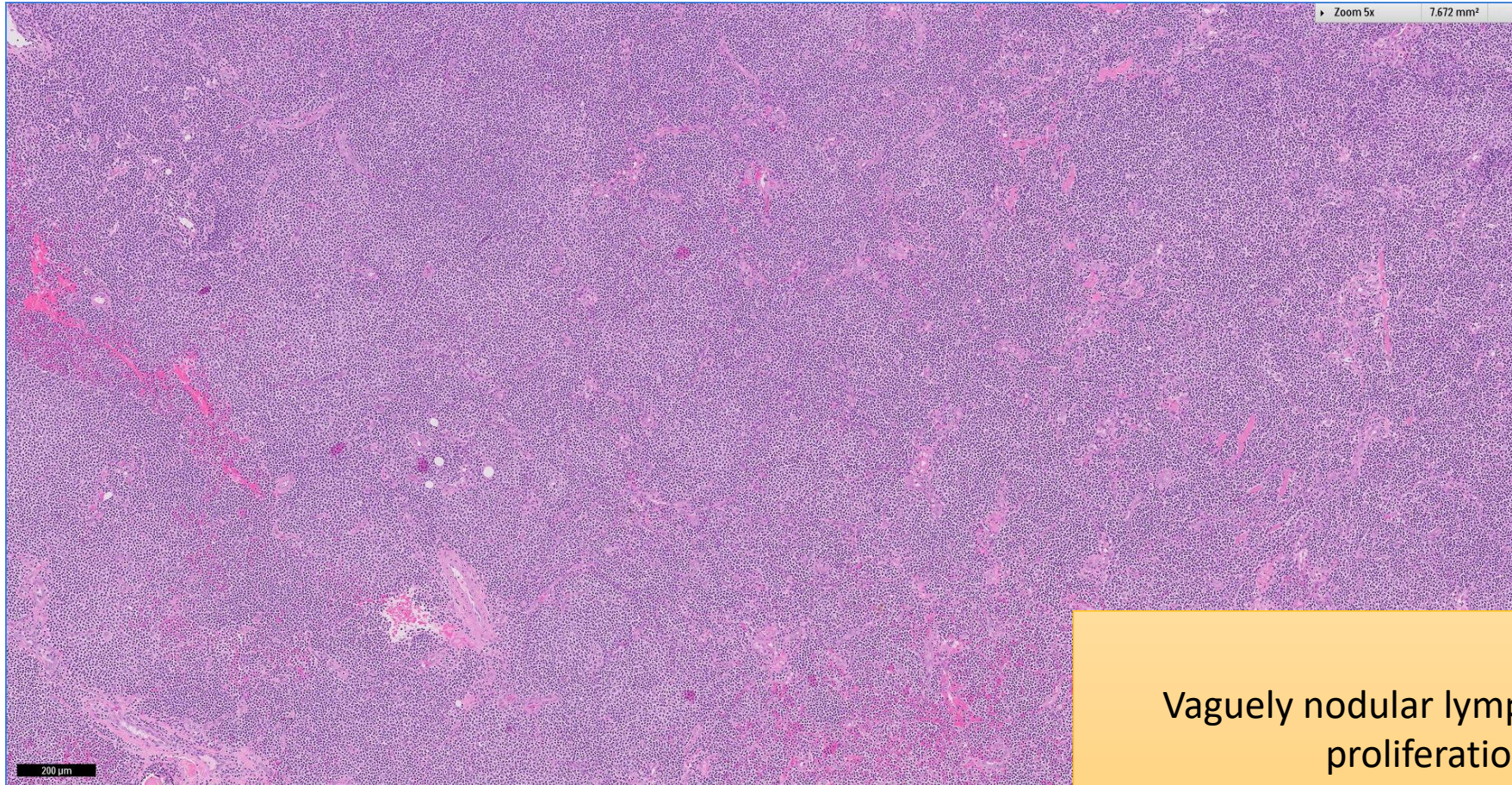


SGH CASE 3: 17RE92

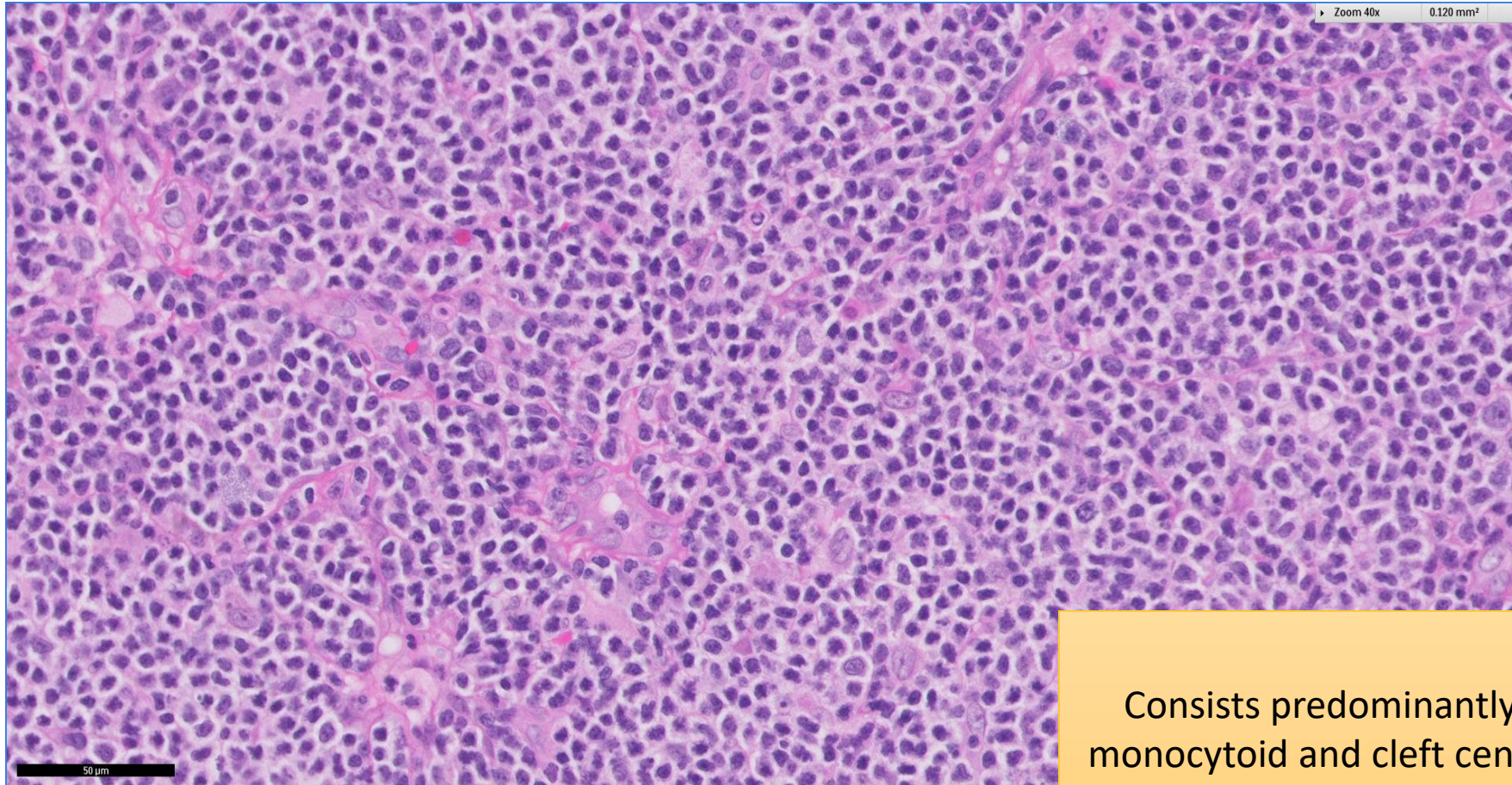
- Clinical History:
 - 60+ years old . Male.
- Specimen:
 - Left inguinal lymph node excision biopsy

SGH CASE 3: 17RE92 H&E



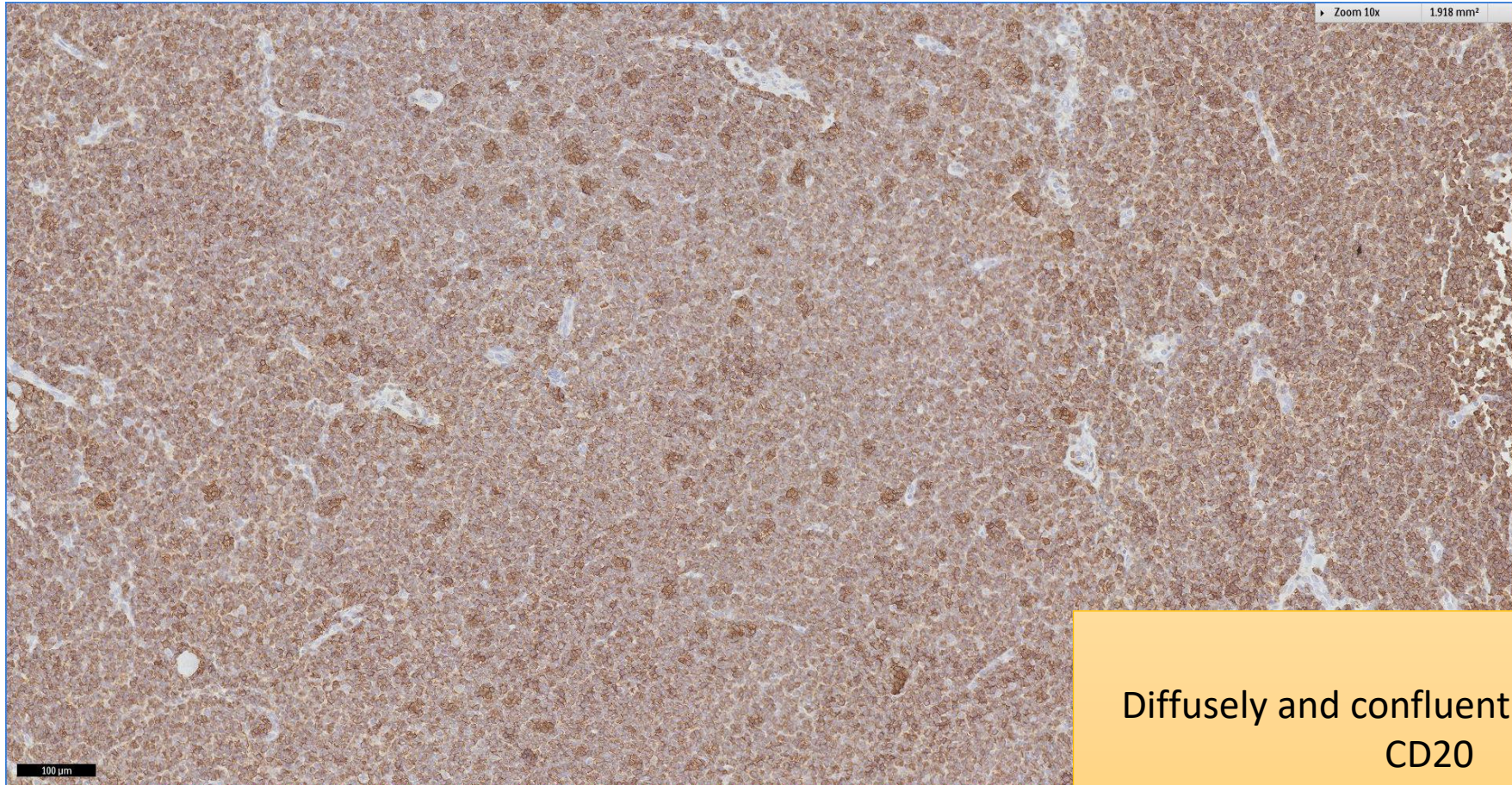
Vaguely nodular lymphomatous proliferation

SGH CASE 3: 17RE92 H&E



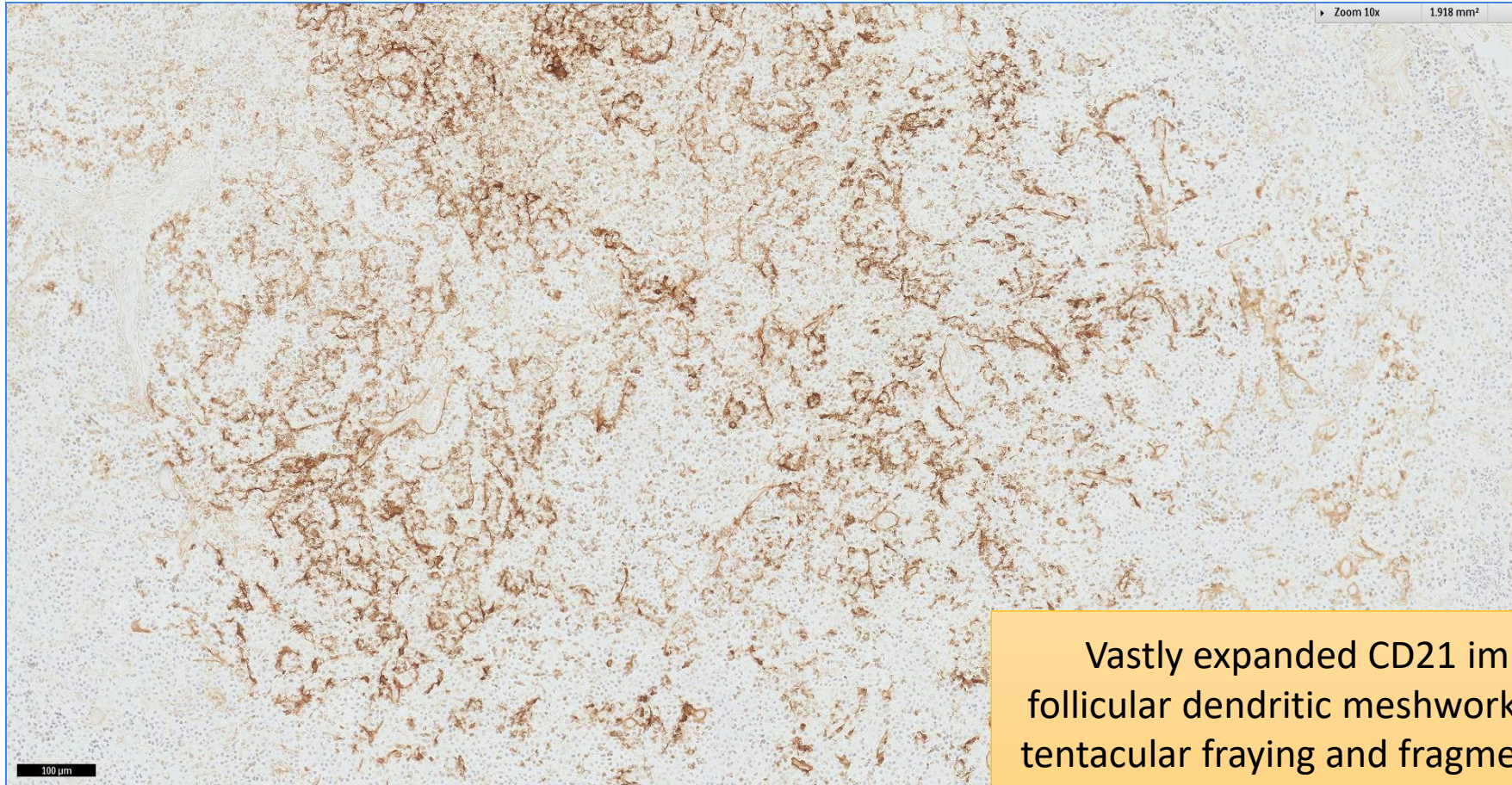
Consists predominantly of small, pale monocytyoid and cleft centrocyte-like cells

SGH CASE 3: 17RE92 CD20



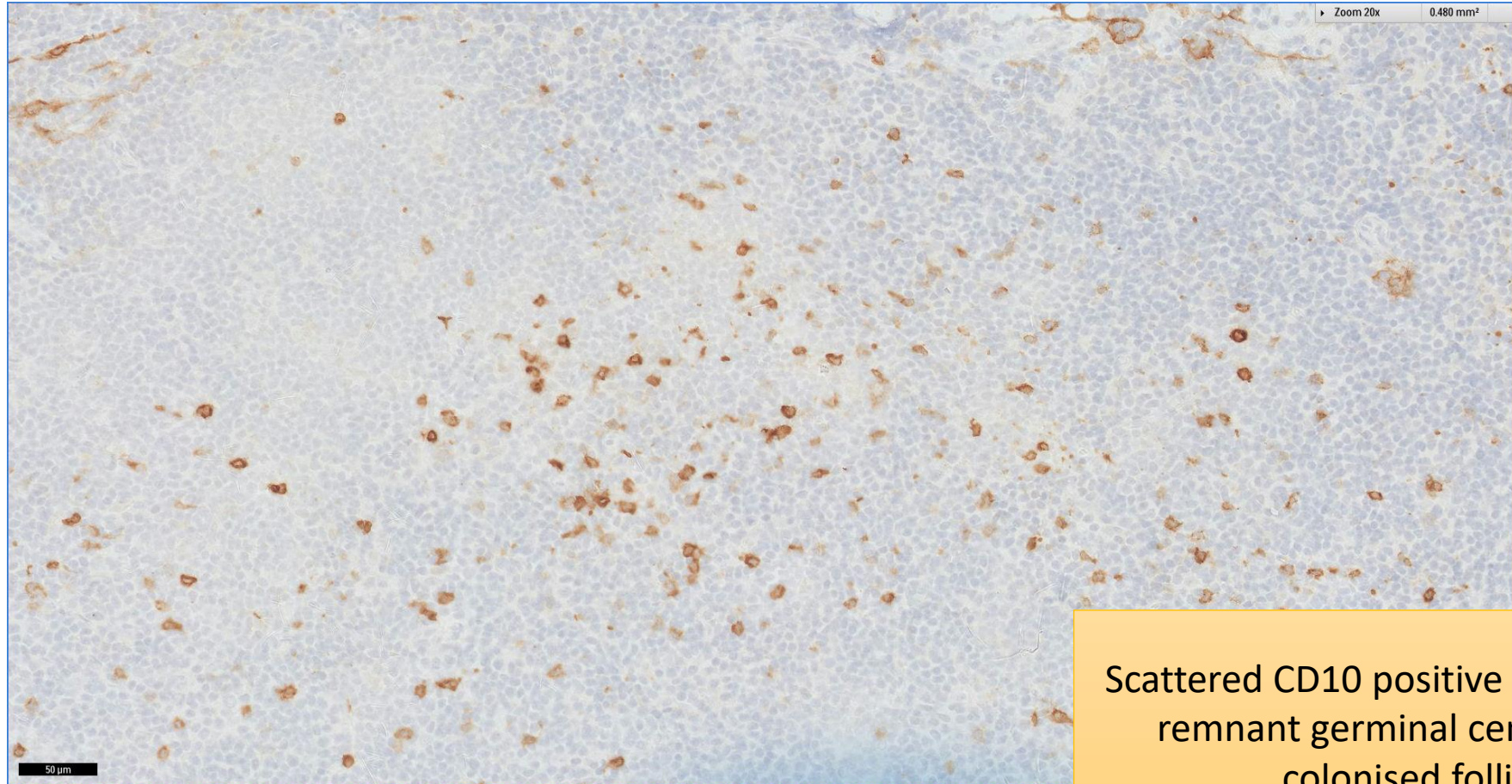
Diffusely and confluent positive for
CD20

SGH CASE 3: 17RE92 CD21



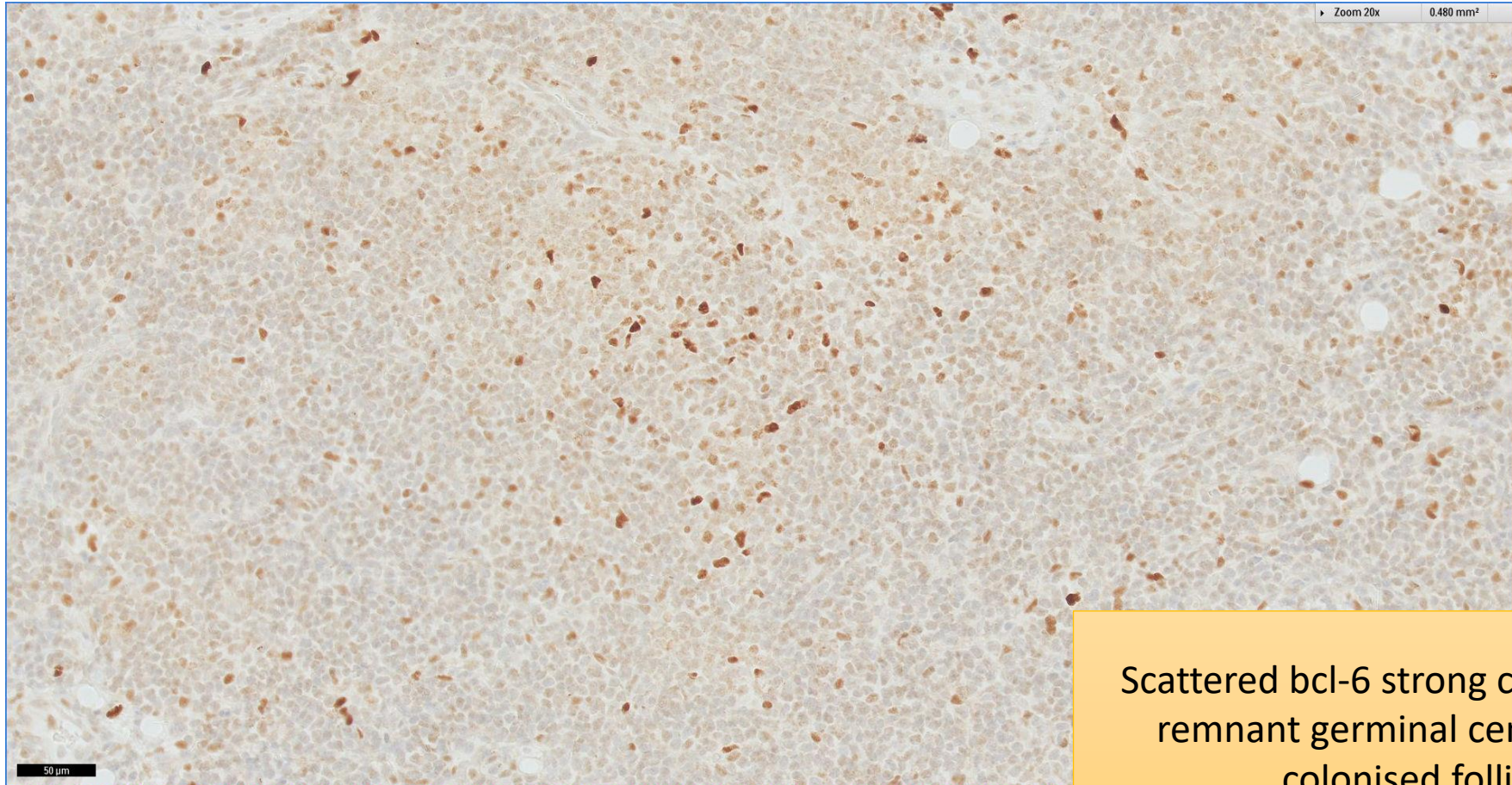
Vastly expanded CD21 immunoreactive follicular dendritic meshworks with peripheral tentacular fraying and fragmentation reflecting follicular colonization

SGH CASE 3: 17RE92 CD10



Scattered CD10 positive cells reflecting remnant germinal centre cells of colonised follicles

SGH CASE 3: 17RE92 BCL6



Scattered bcl-6 strong cells reflecting remnant germinal centre cells of colonised follicles

SGH CASE 3: 17RE92

- Diagnosis
 - Nodal Marginal Zone Lymphoma