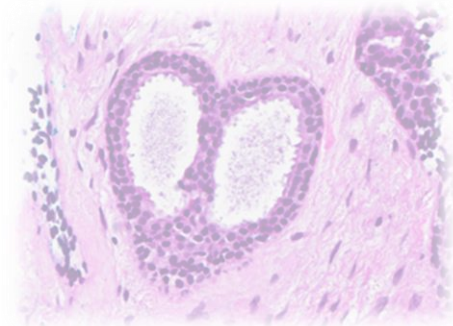
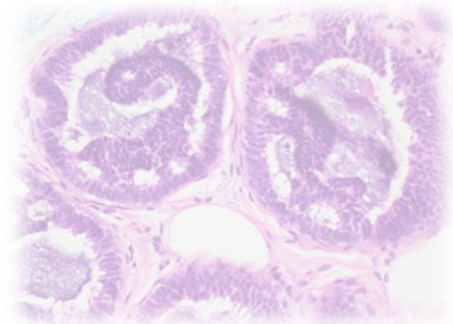
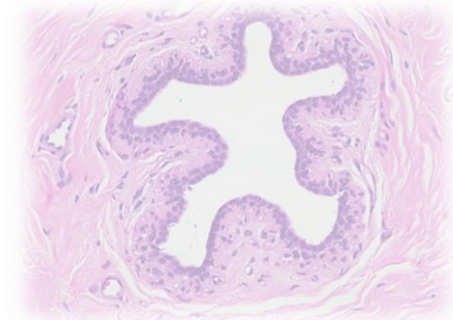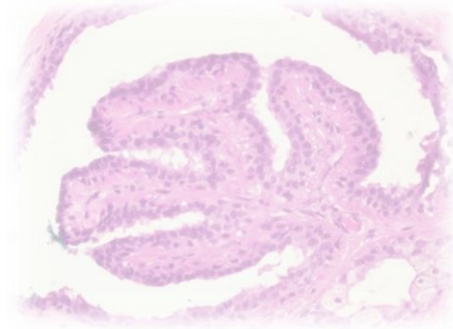


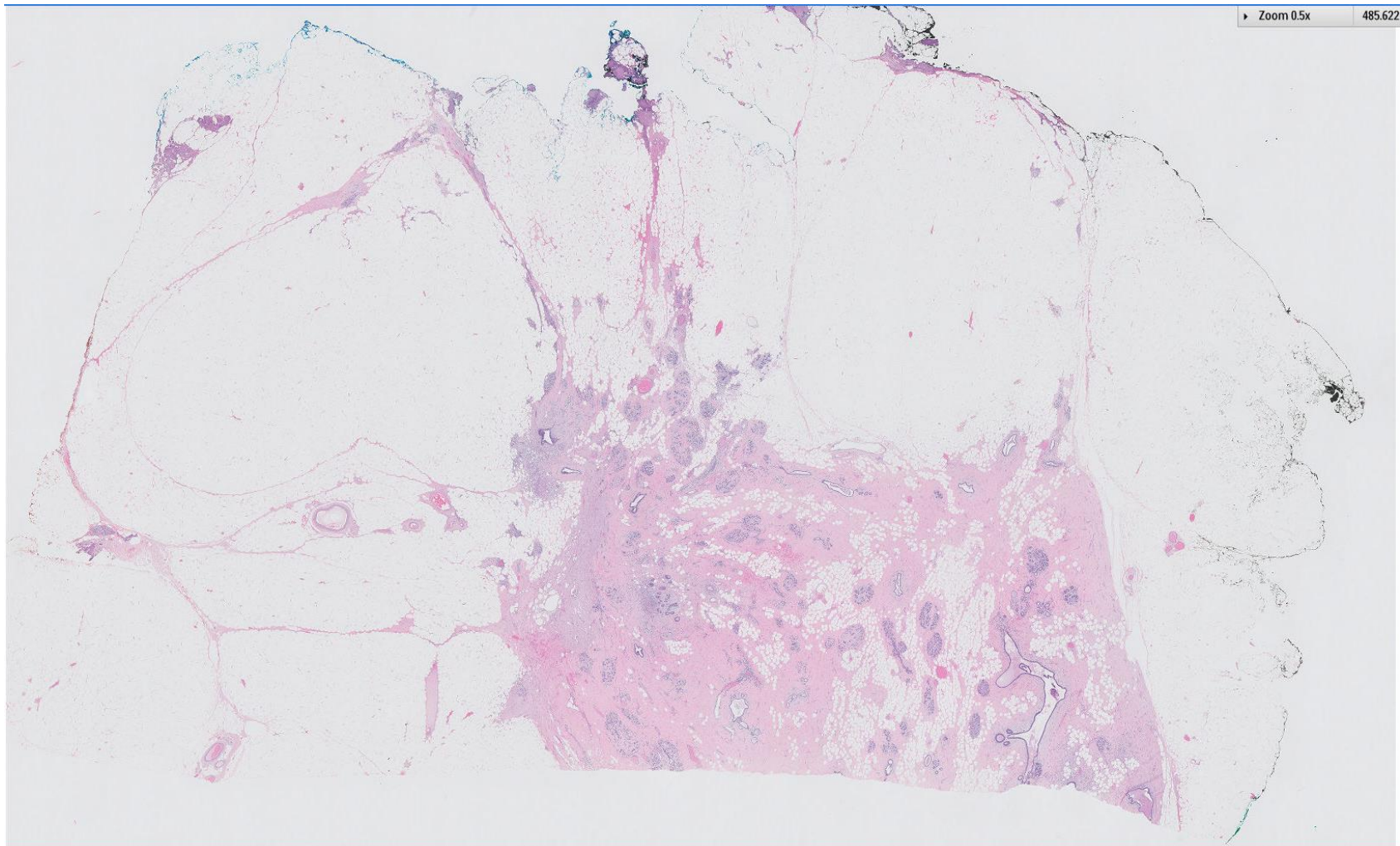
## Case 33

41 year old female.

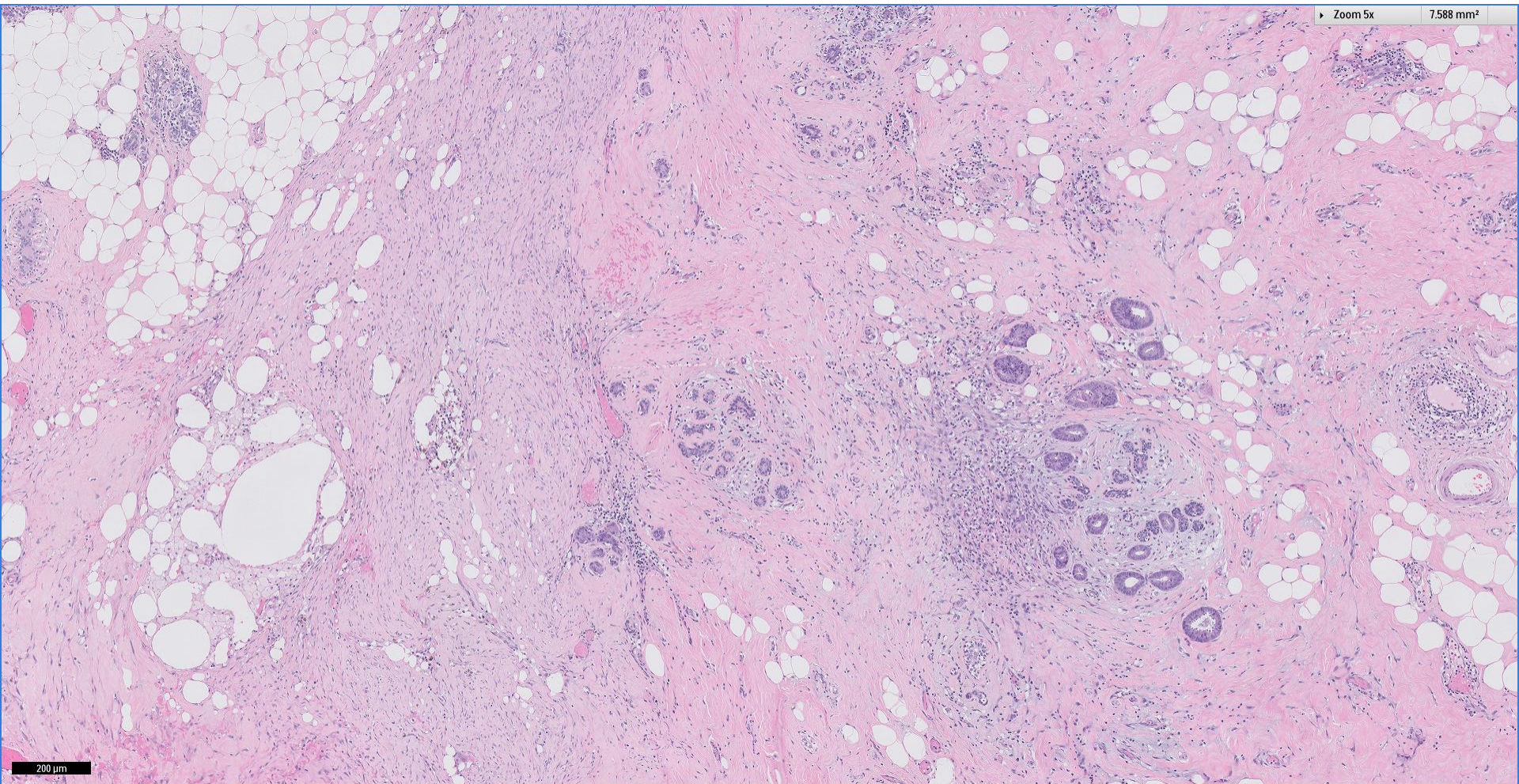
Right breast 12 o'clock tumour.

*Contributed by Dr Mihir Gudi, Kandang Kerbau  
Women's and Children's Hospital*

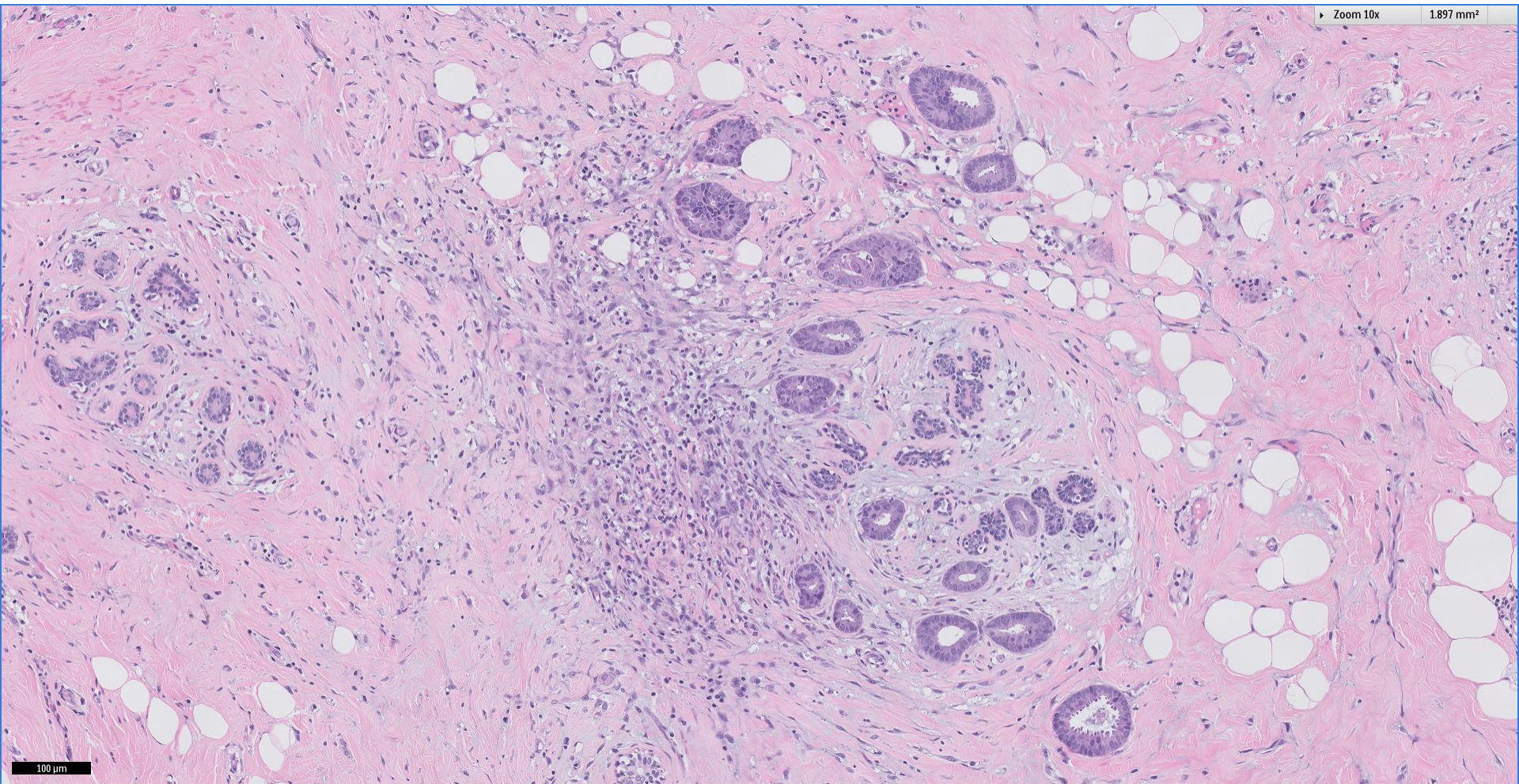




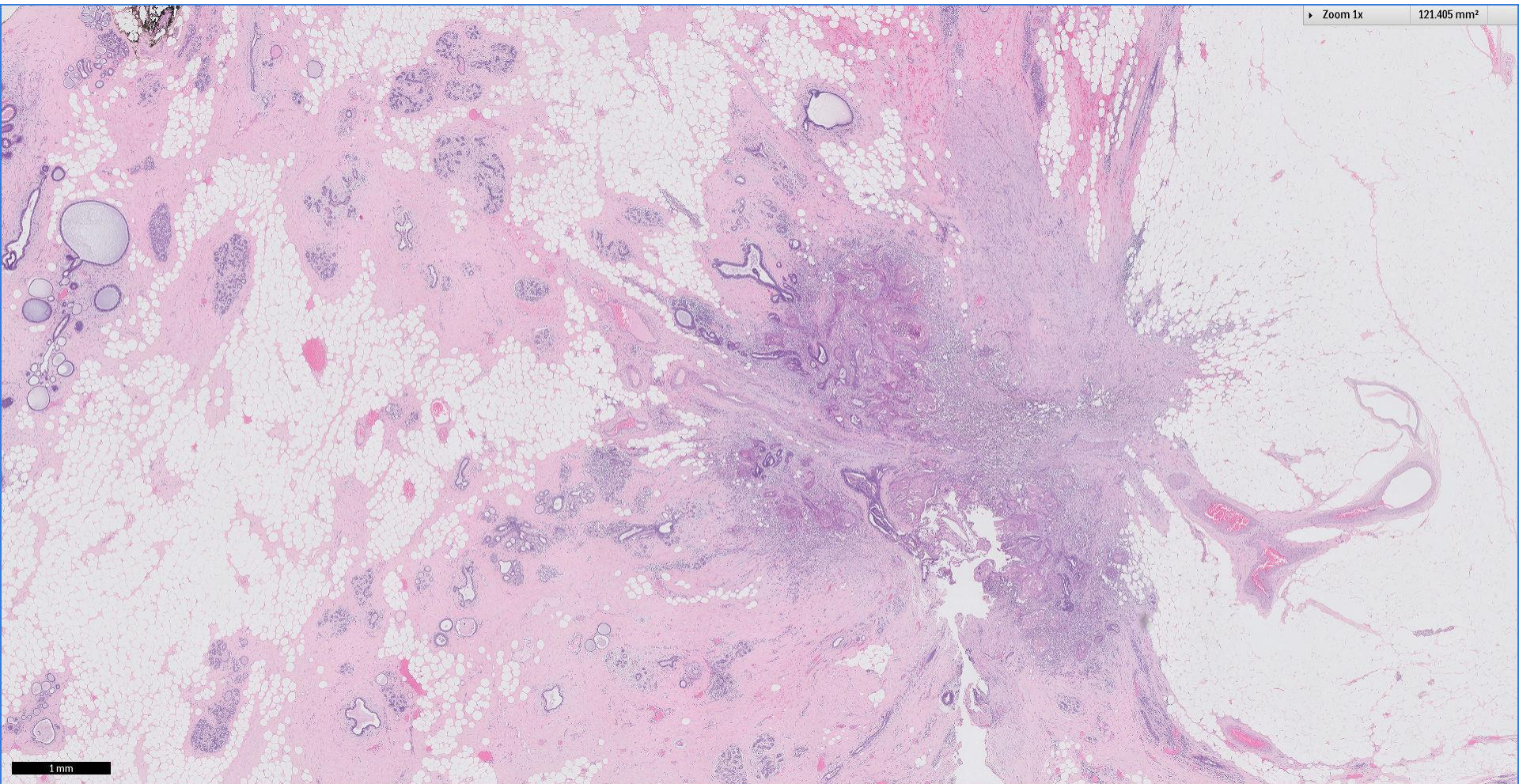




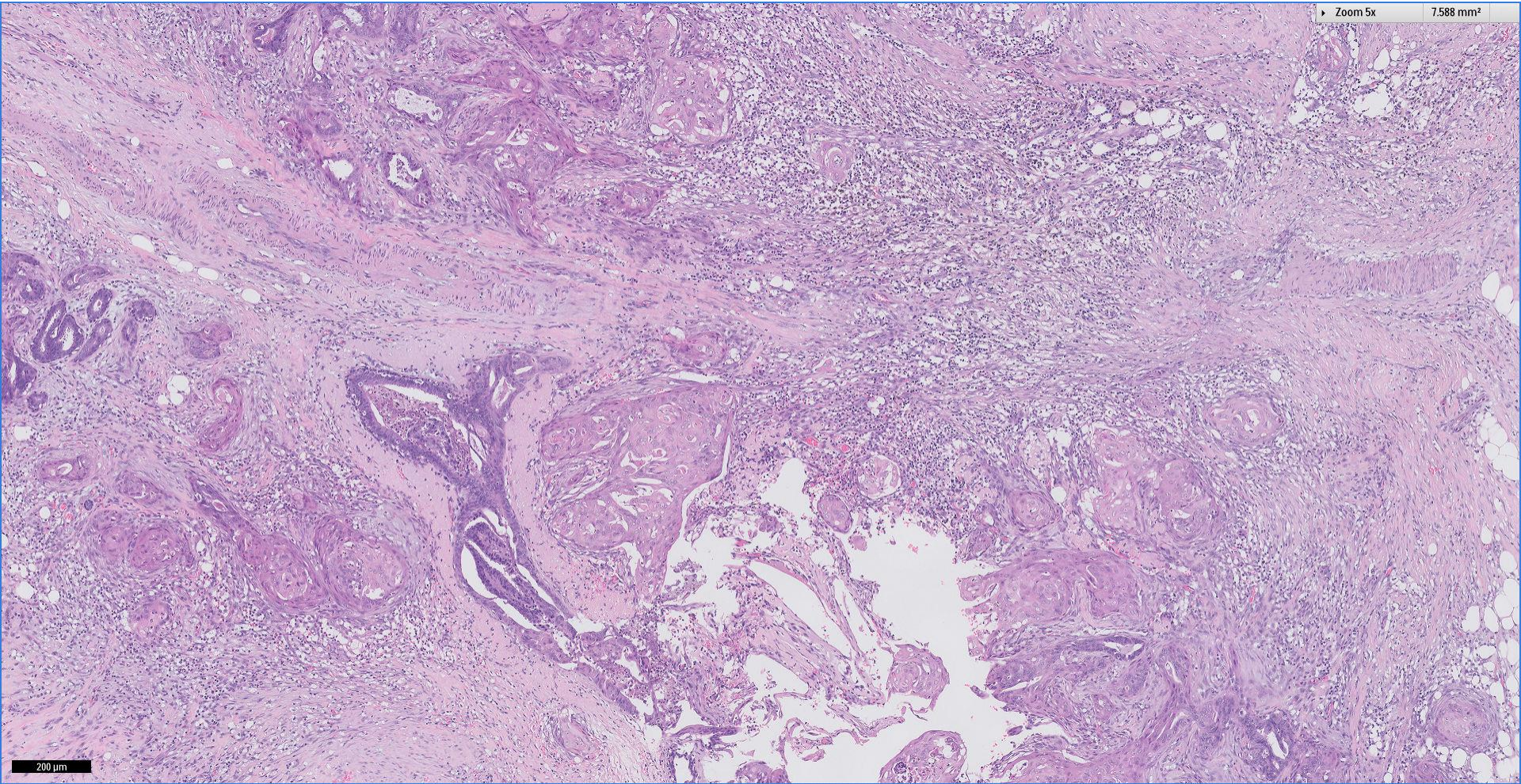












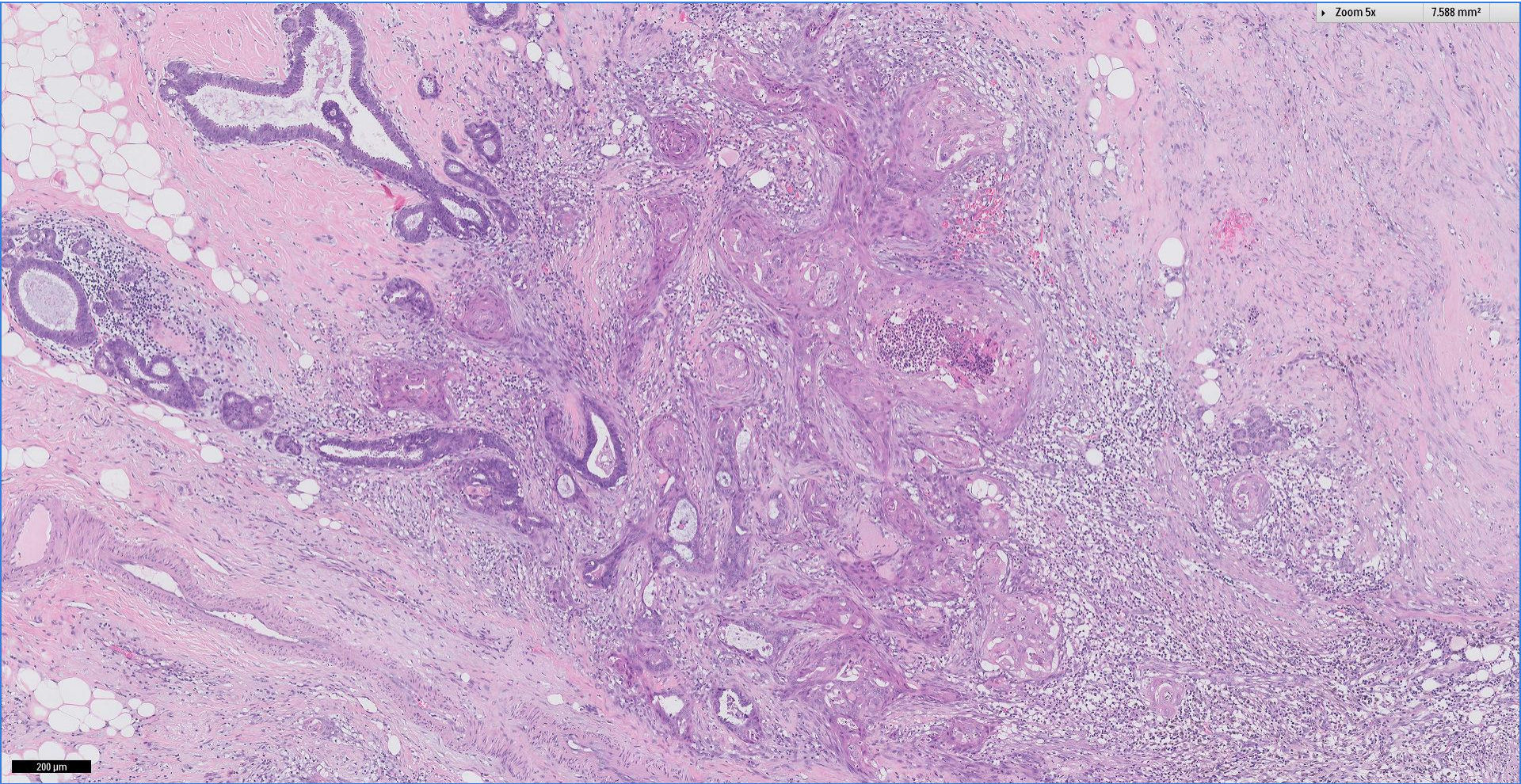
200 µm



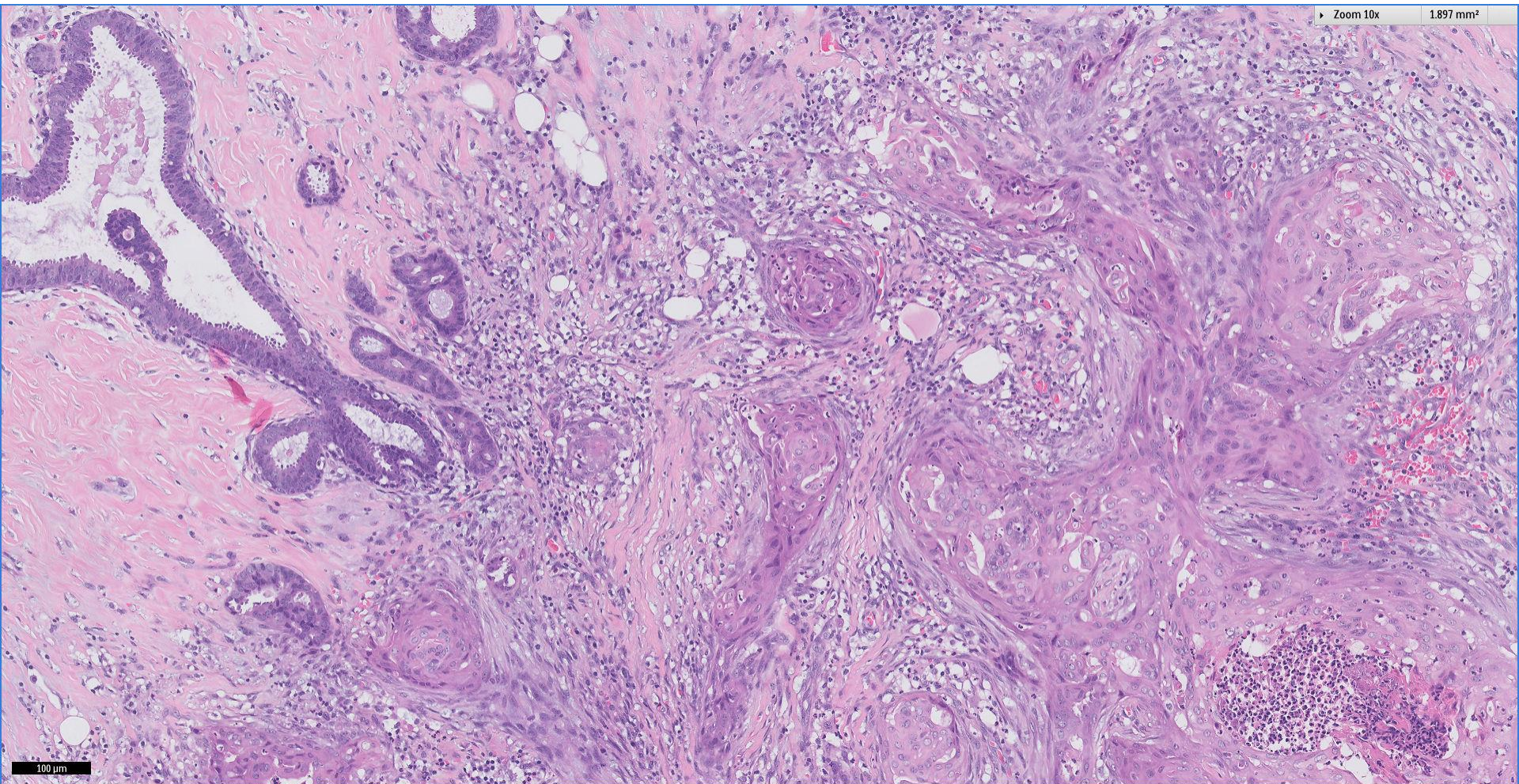
**Division of Pathology**  
**Singapore General Hospital**



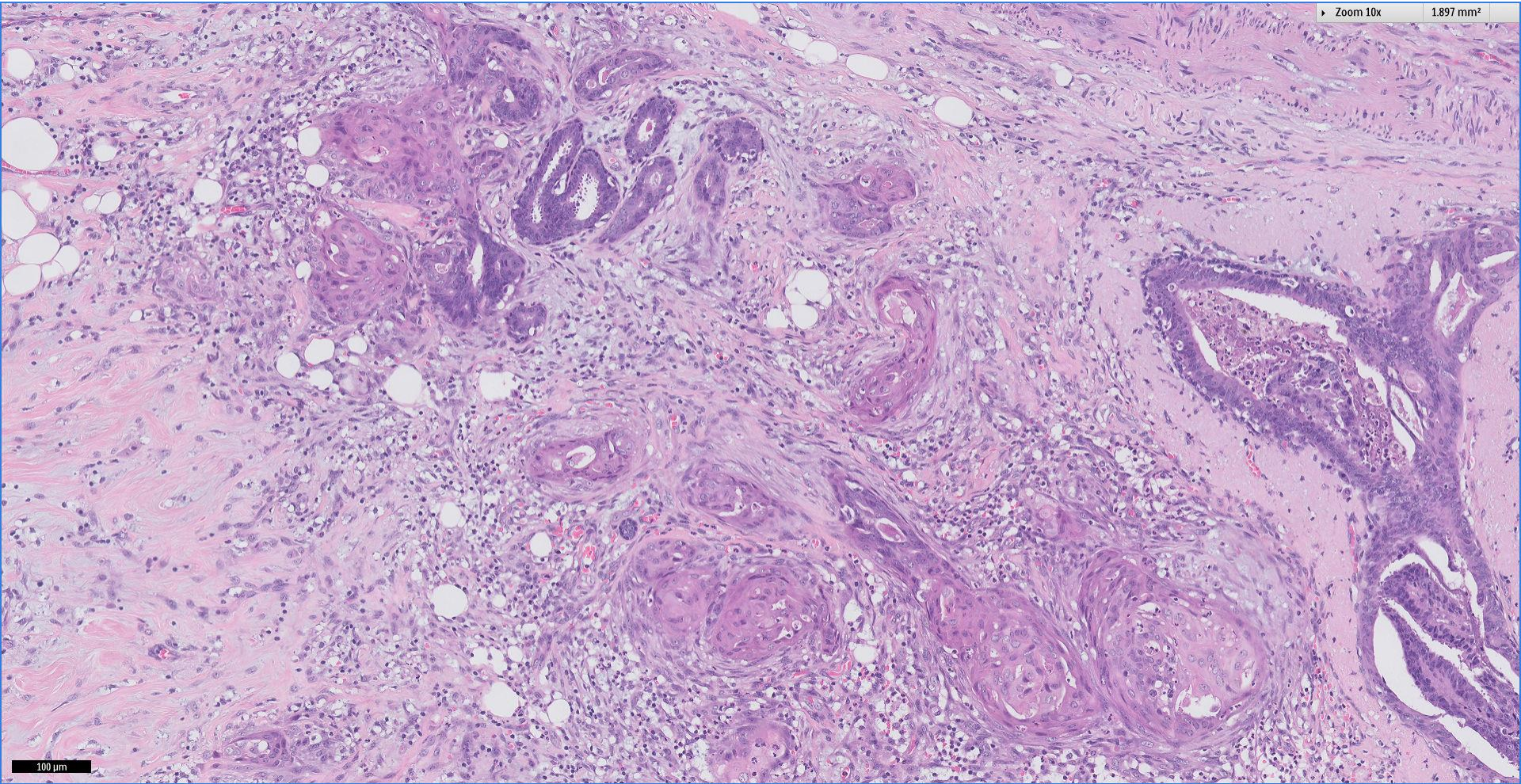














*Thank You*