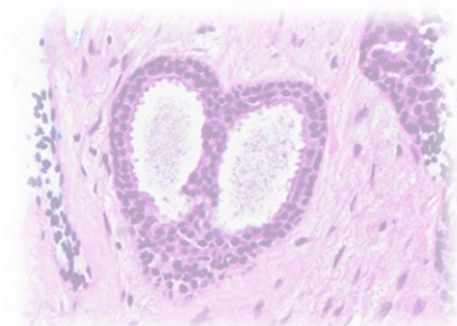
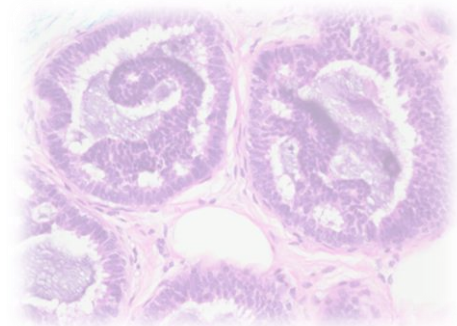
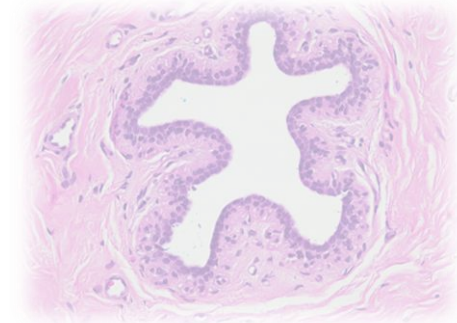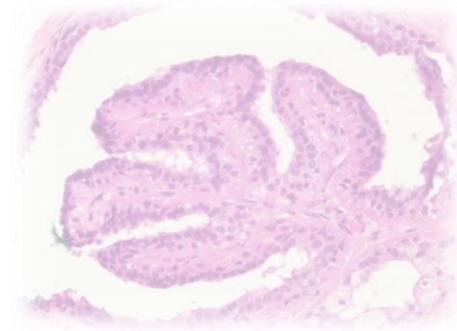


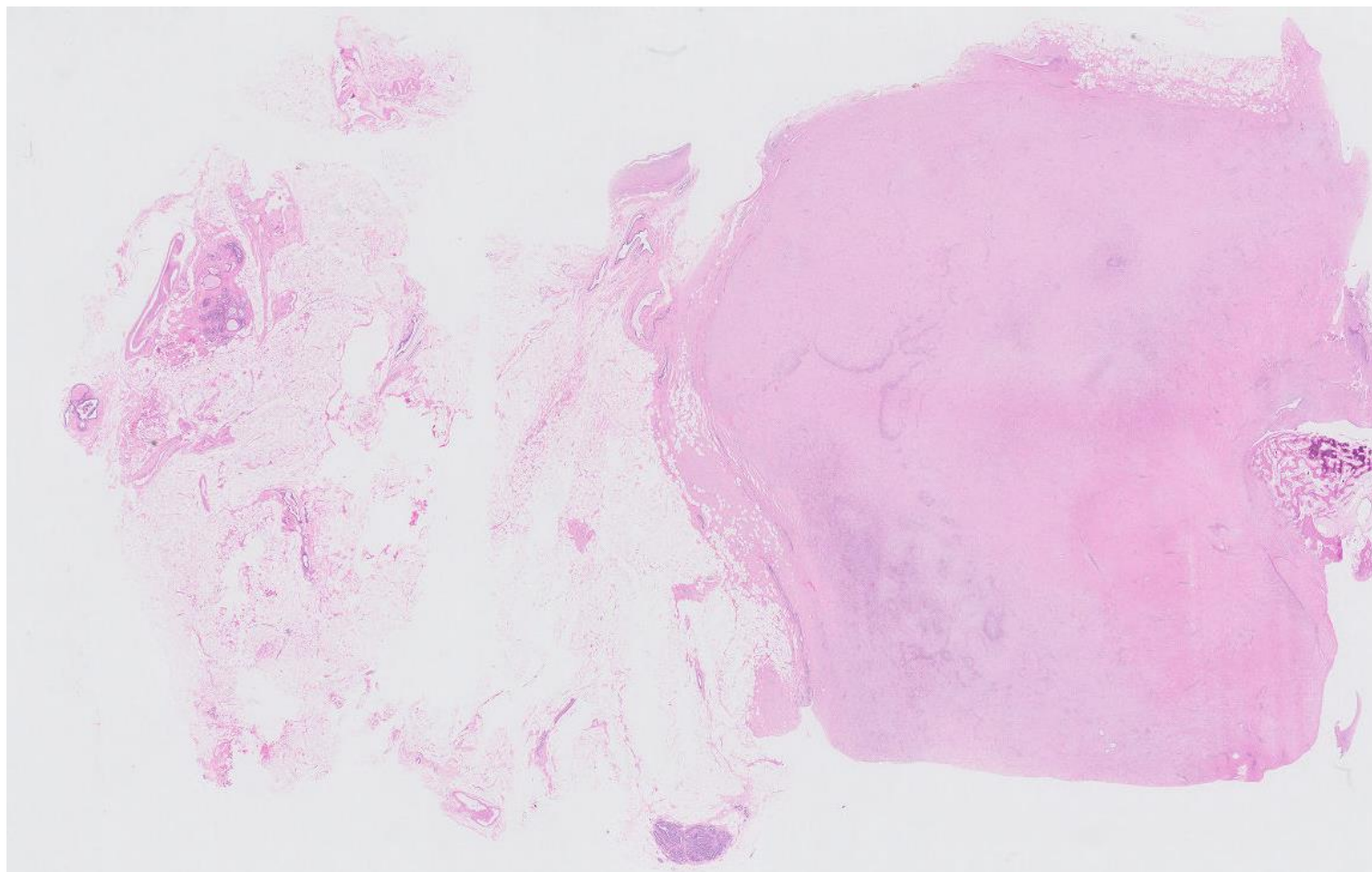
## Case 31

84 year old Chinese female.

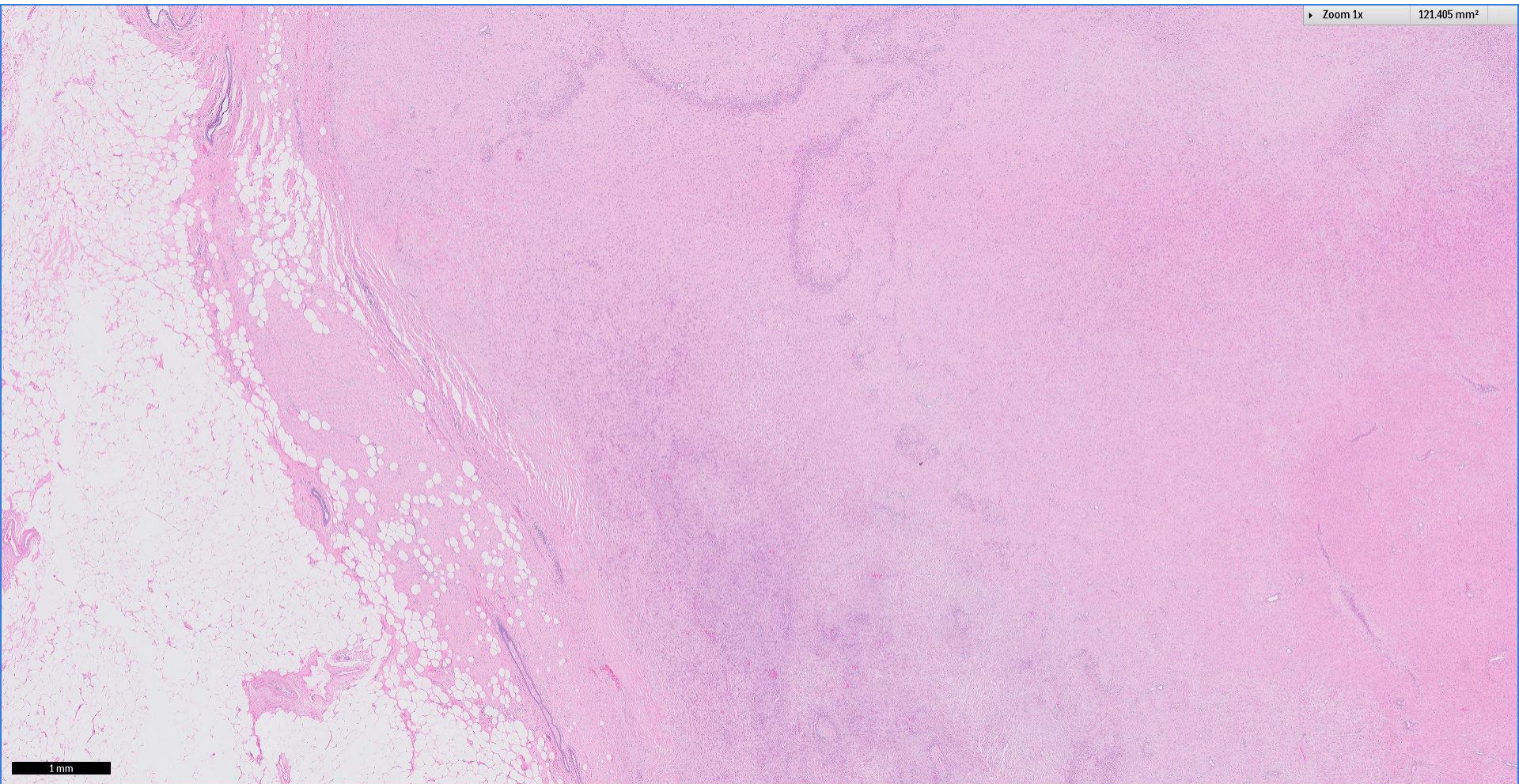
Left breast, simple mastectomy for a  
12cm mass.

Previous core biopsy showed a  
spindle cell proliferation.

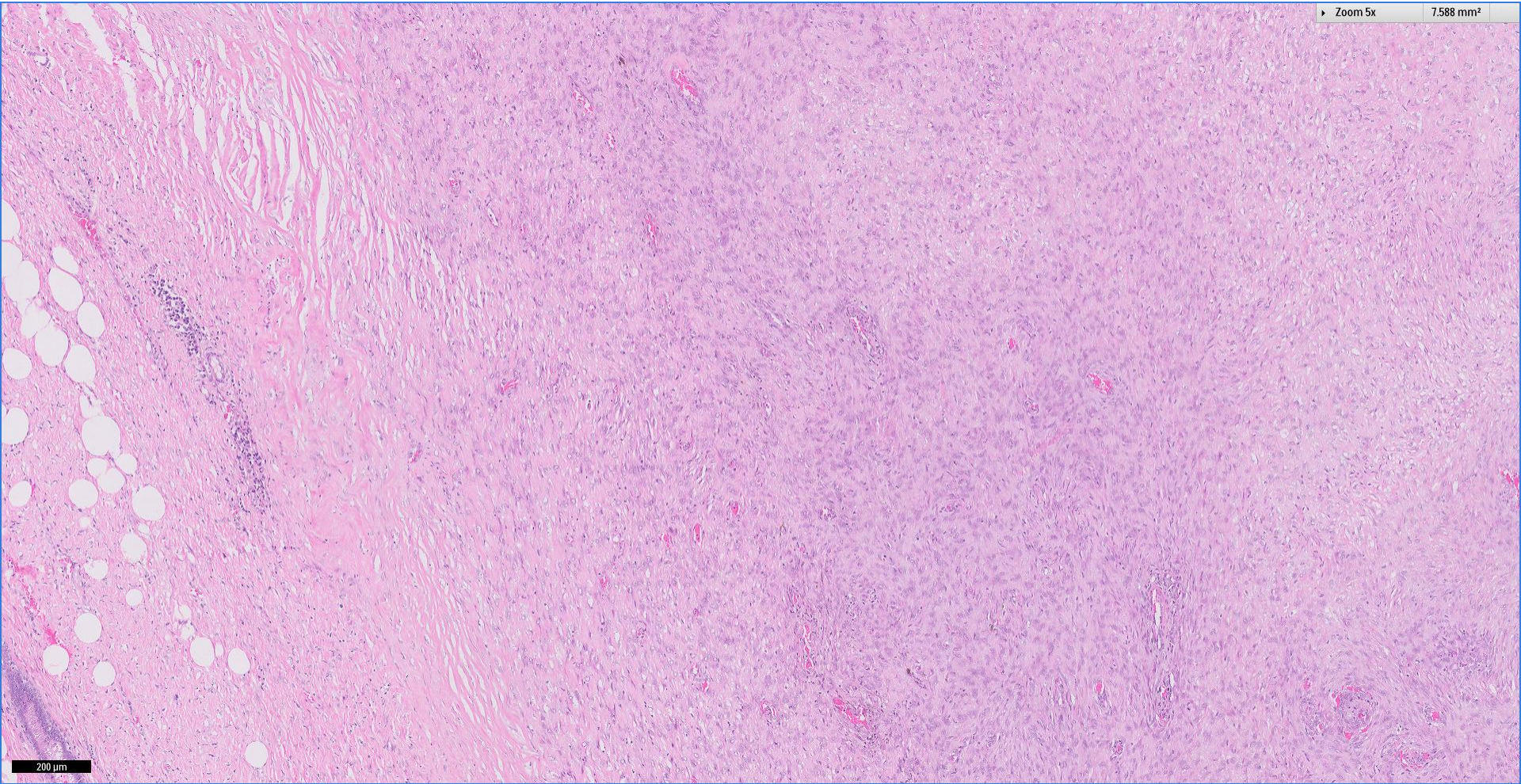




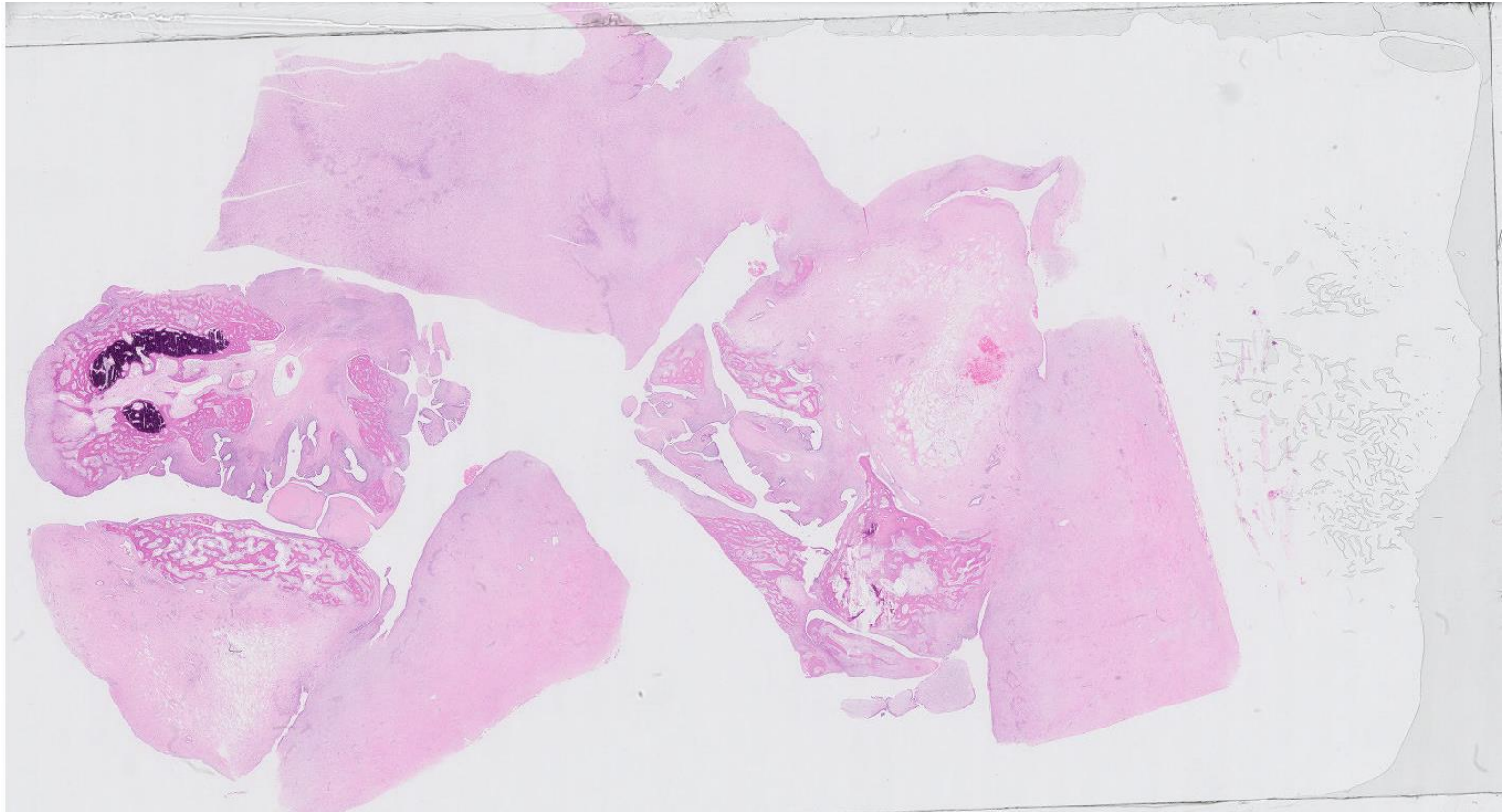








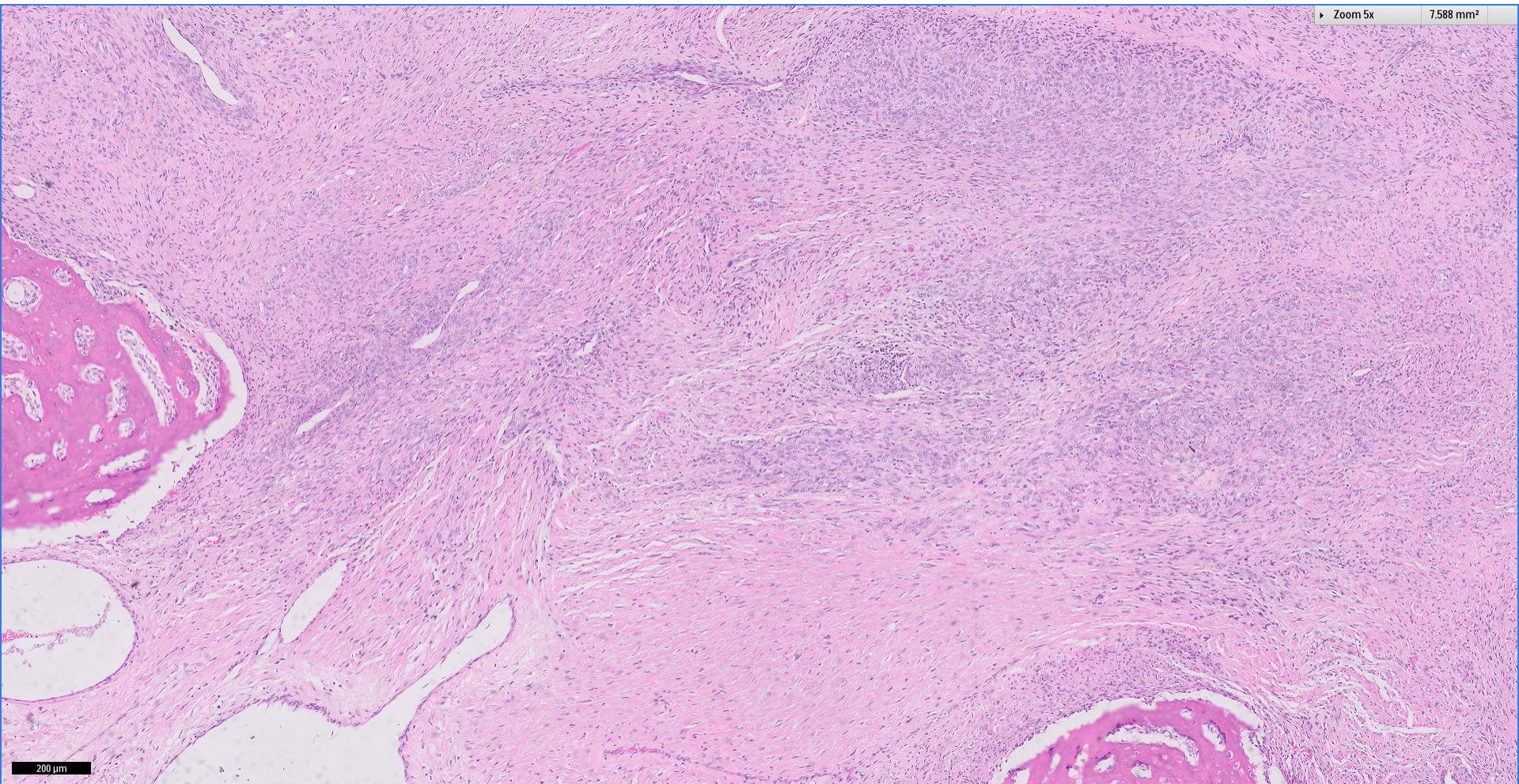




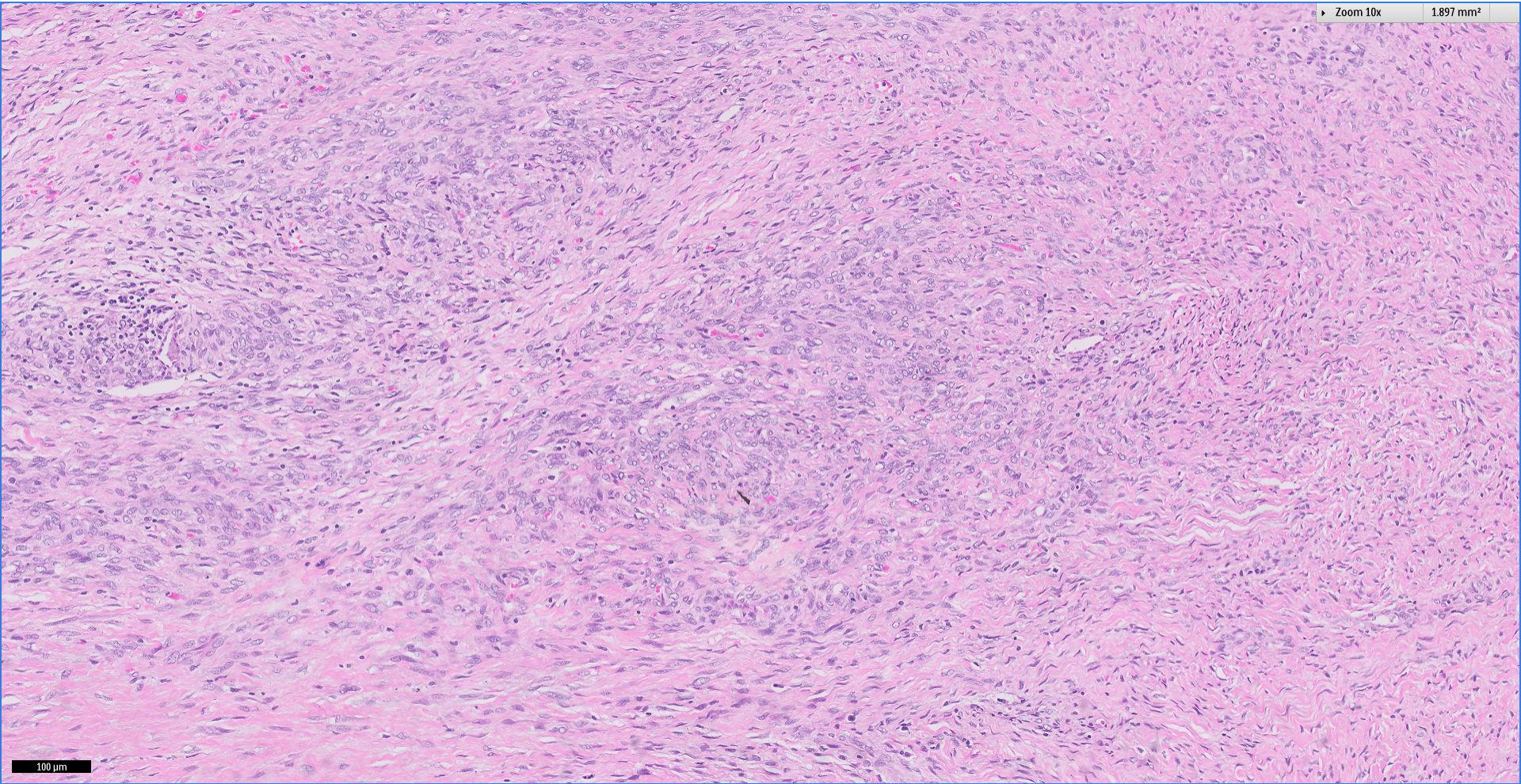
**Division of Pathology**  
**Singapore General Hospital**













*Thank You*