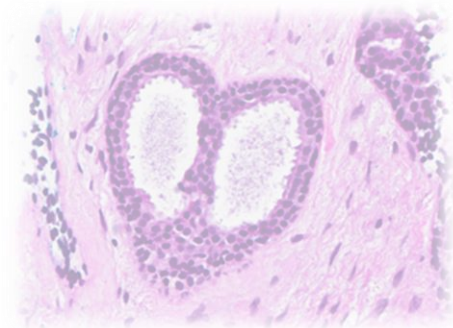
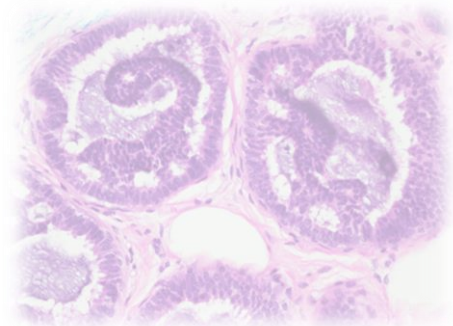
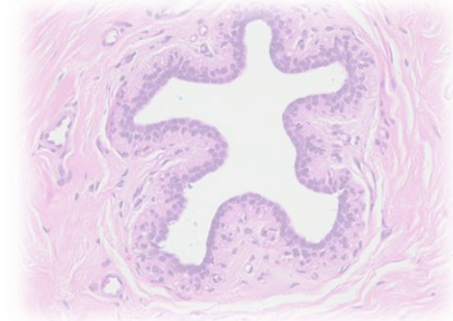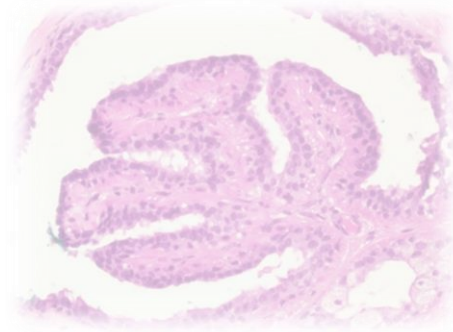
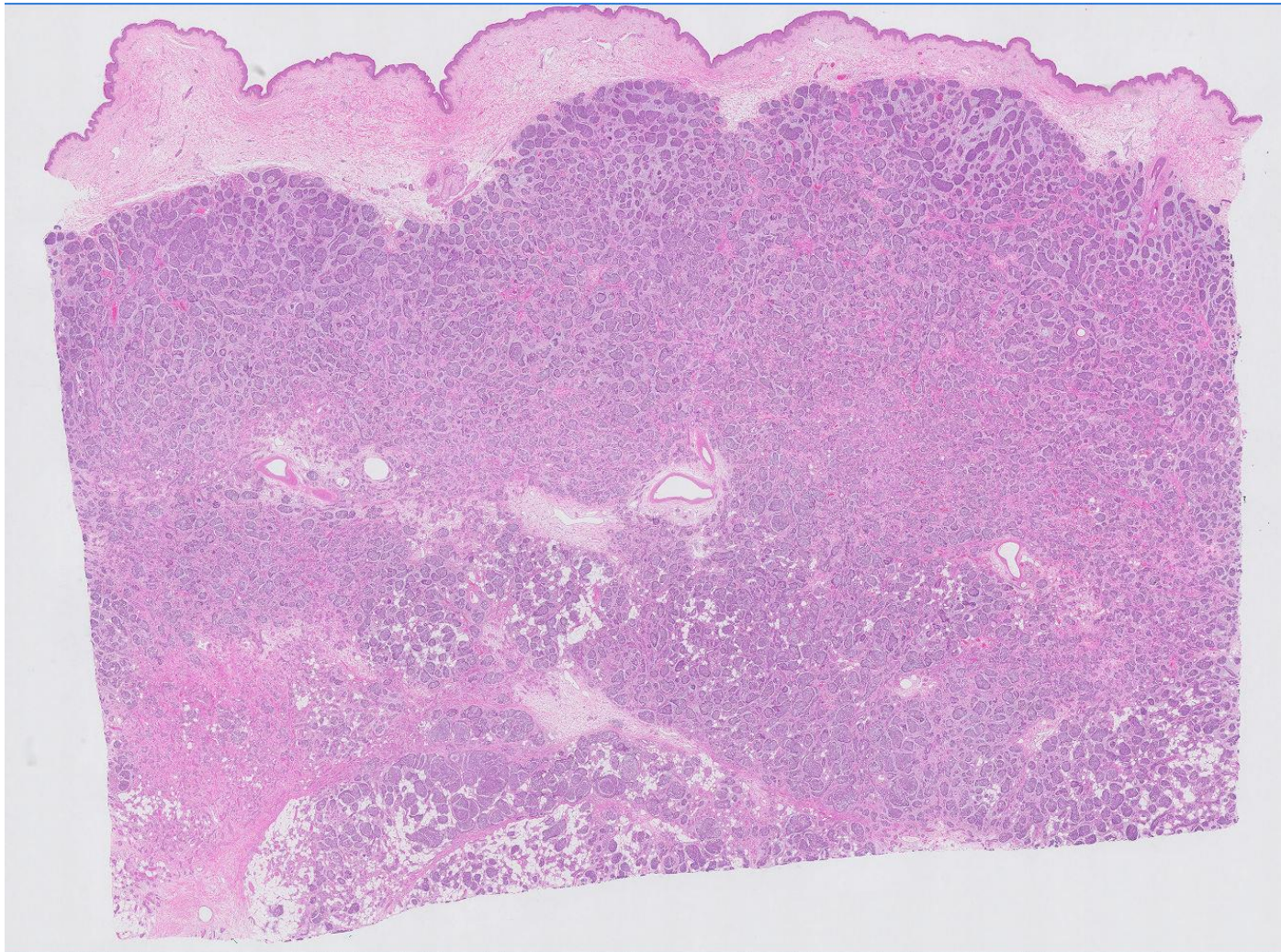


Case 30

46 year old Malay female.
Left mastectomy.

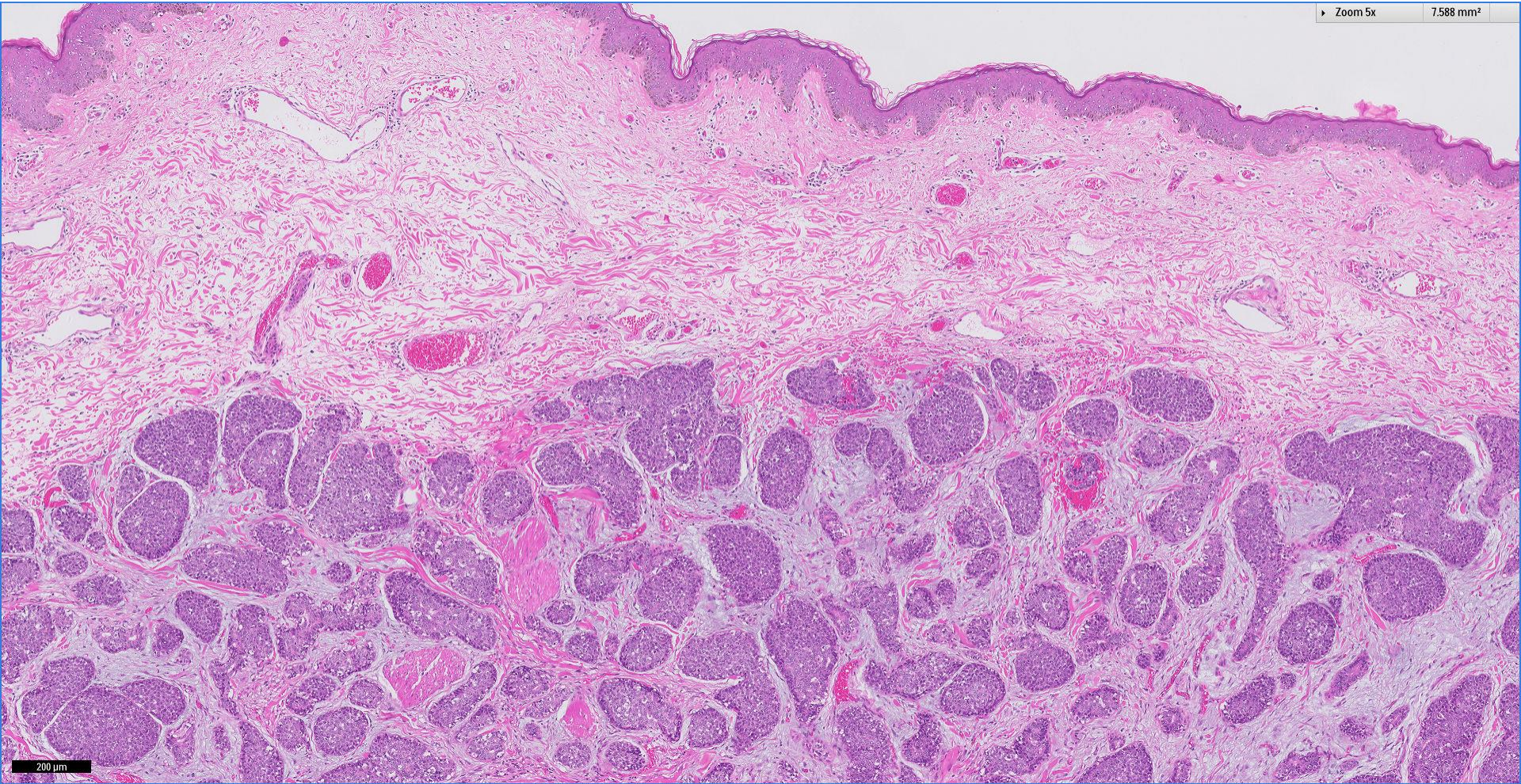
Contributed by Dr Victor Ng, Changi General Hospital

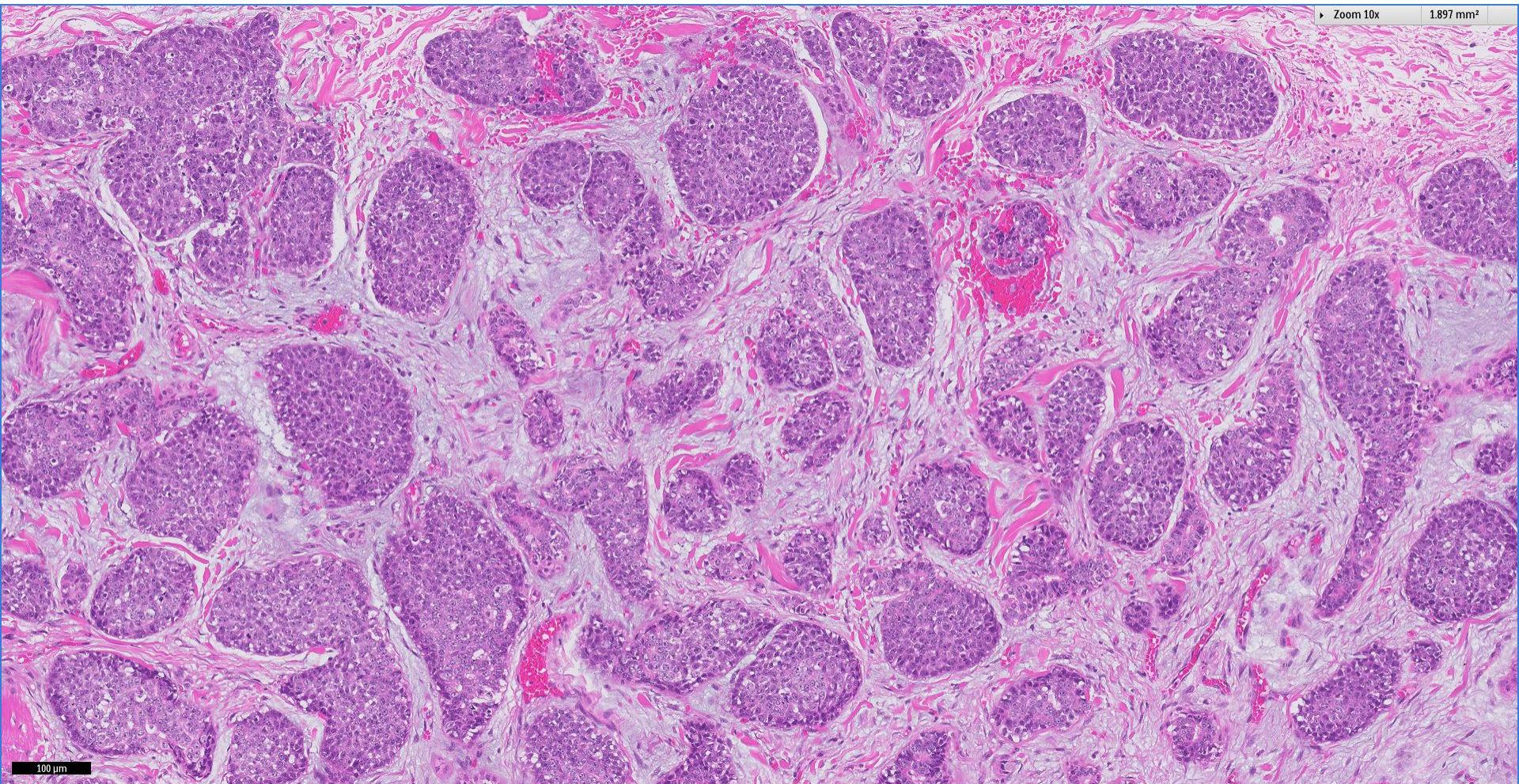


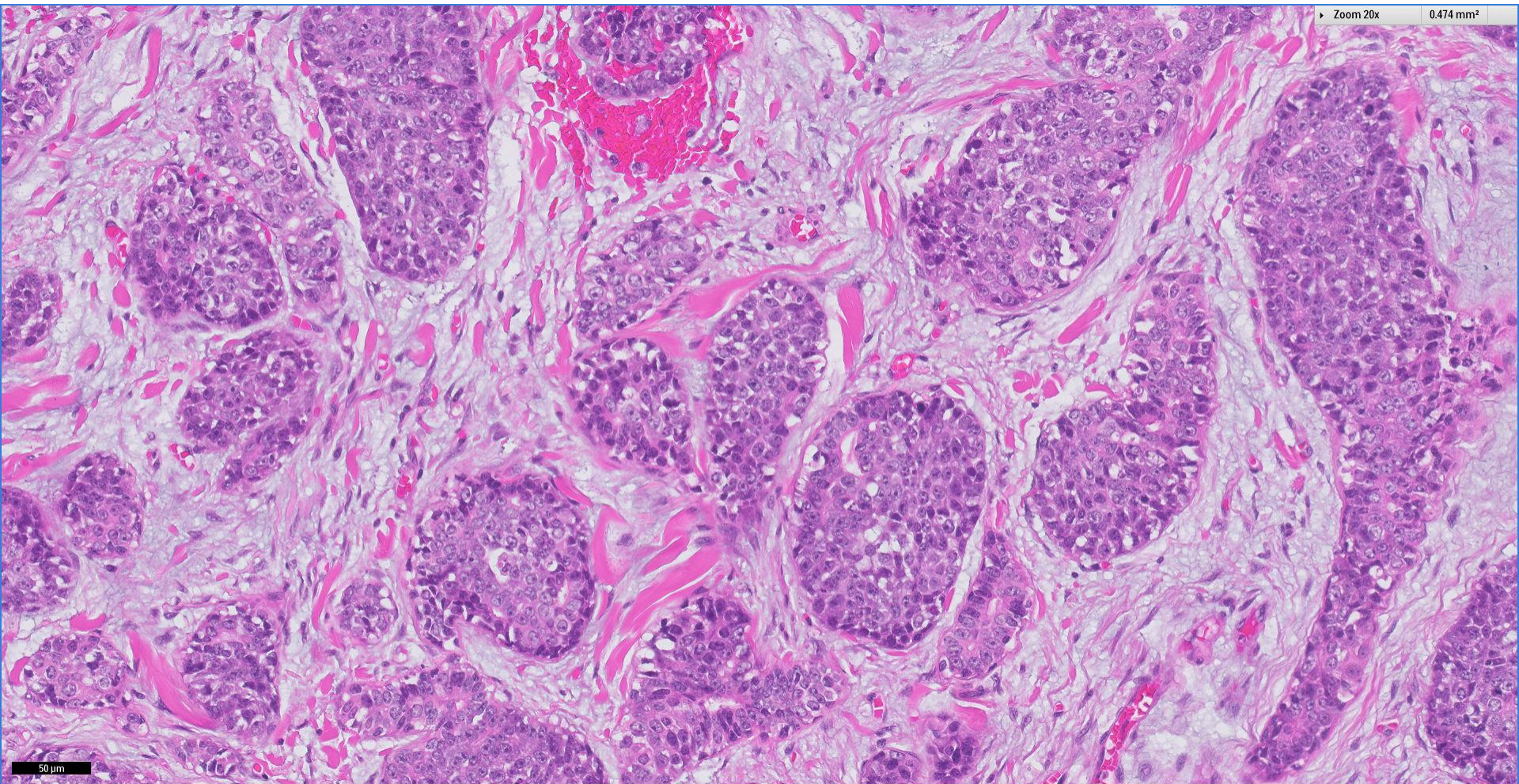


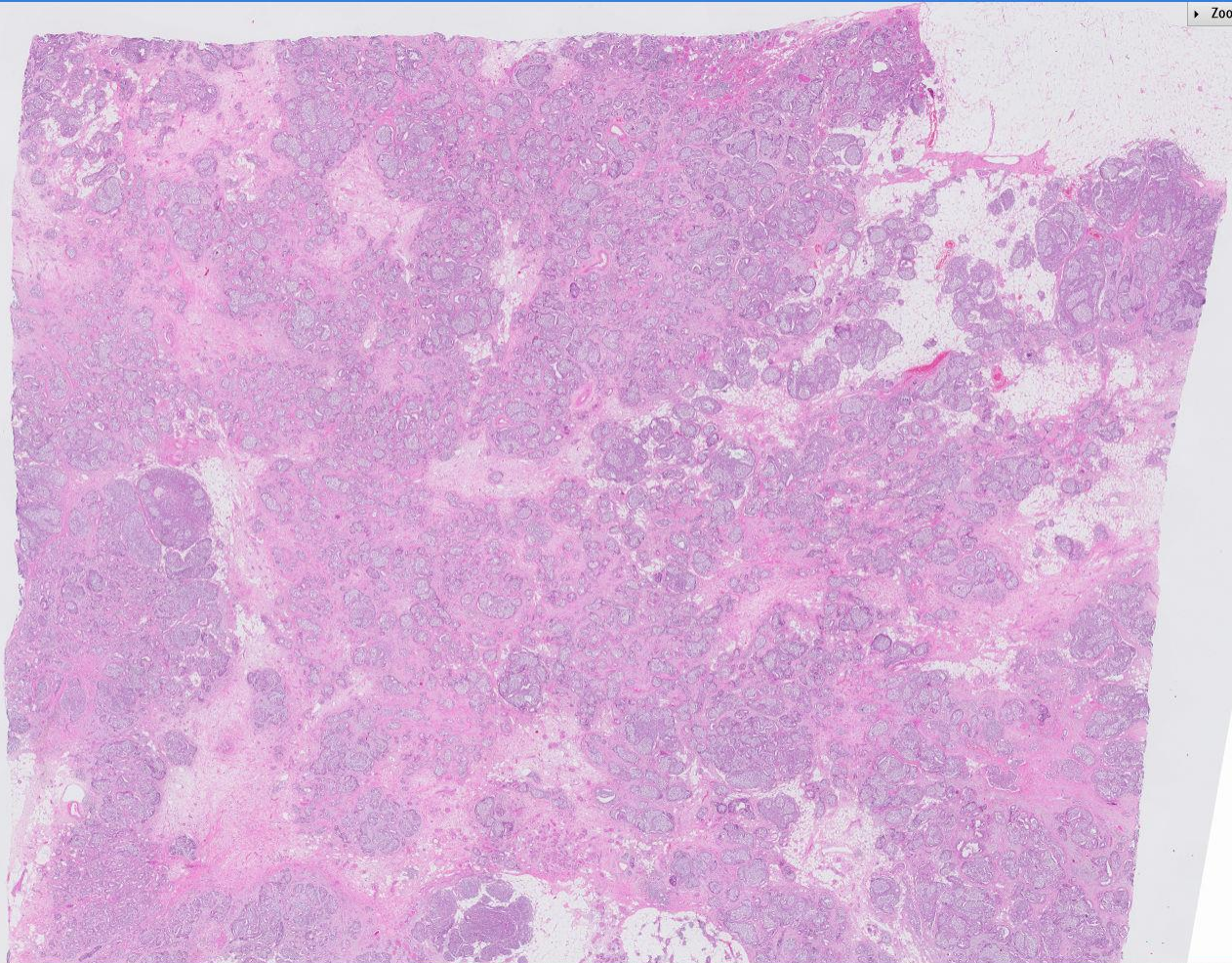
Division of Pathology
Singapore General Hospital









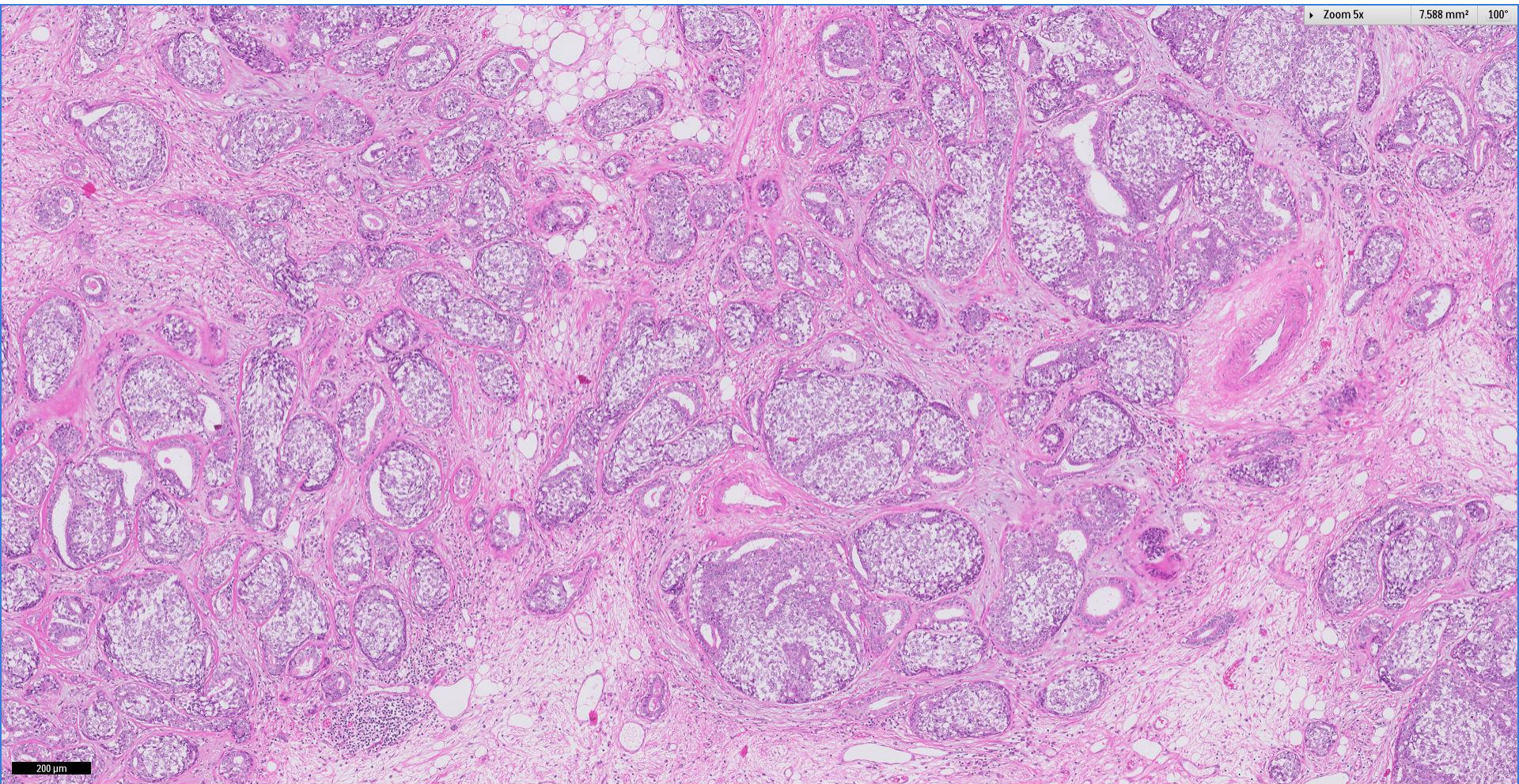


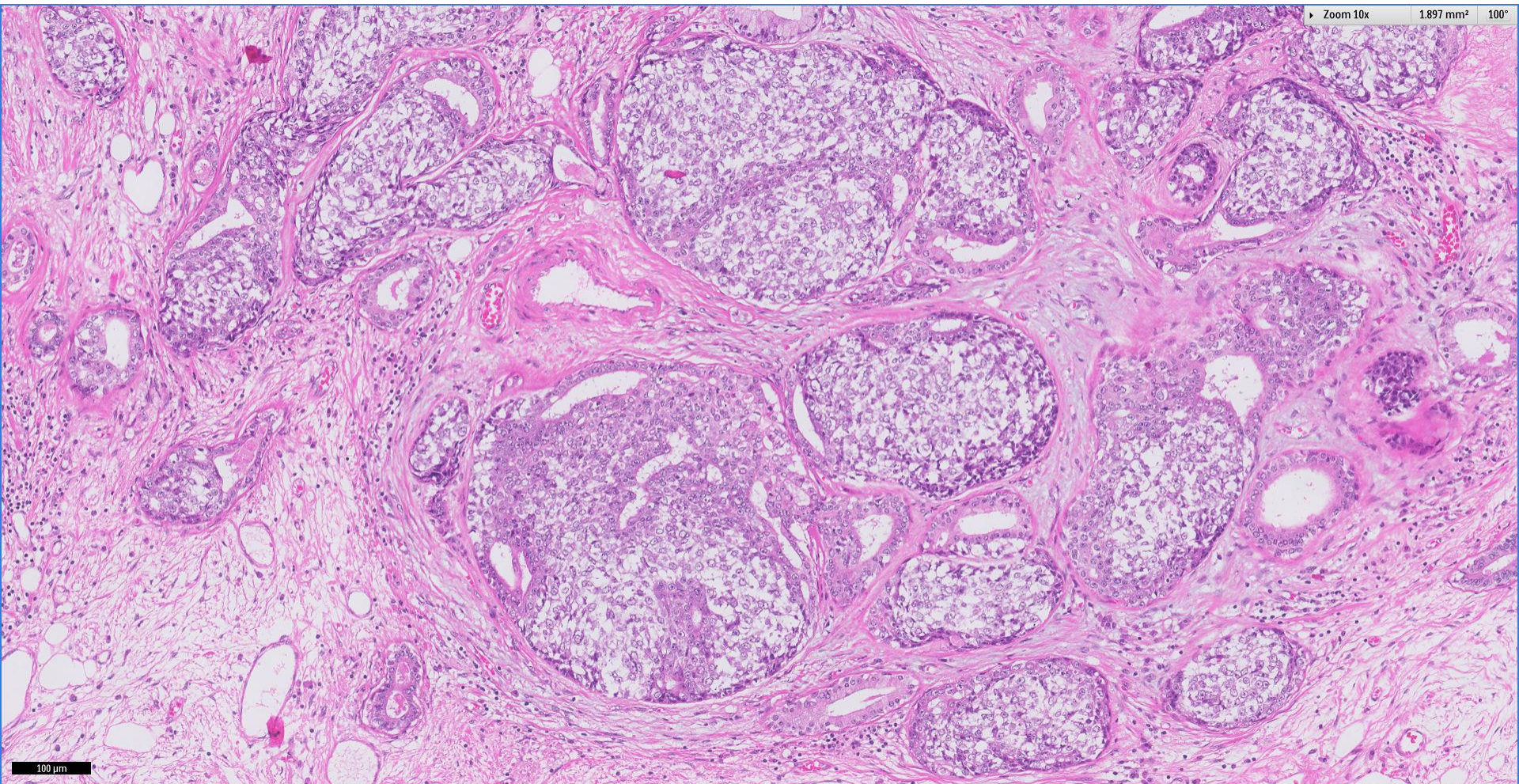
2 mm

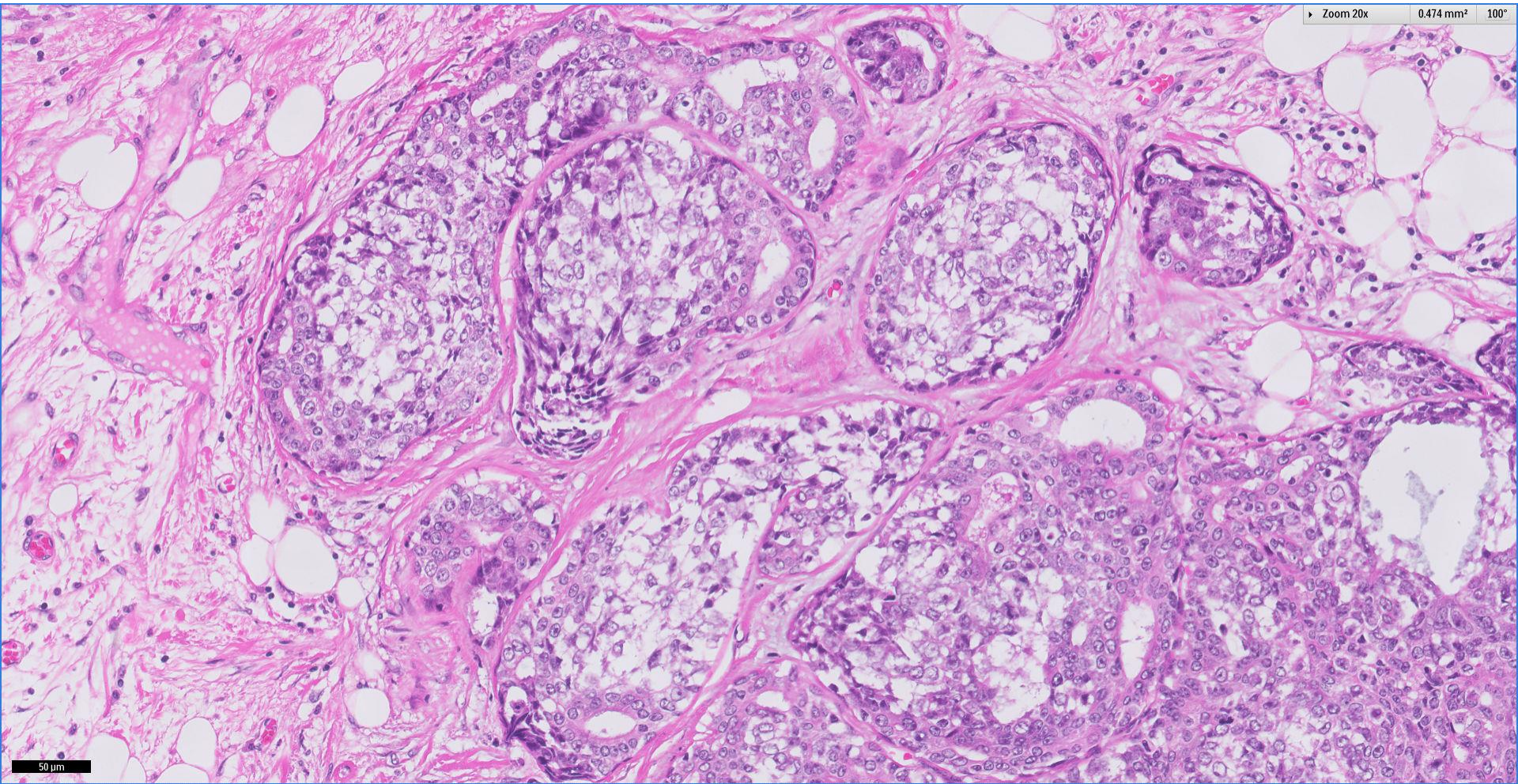


Division of Pathology
Singapore General Hospital









Division of Pathology
Singapore General Hospital



Thank You