

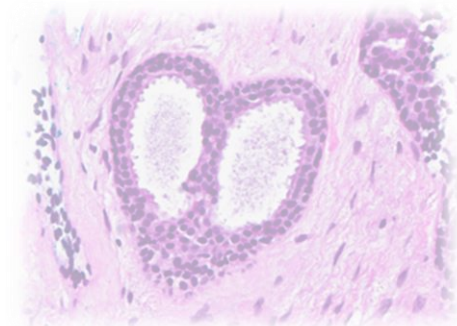
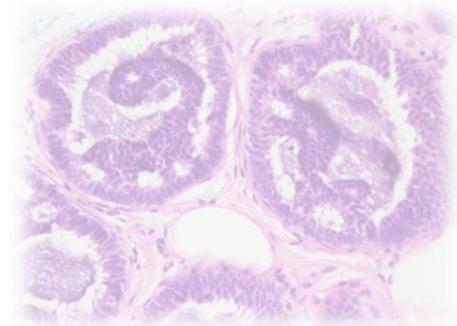
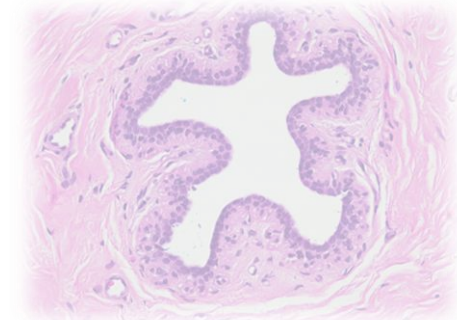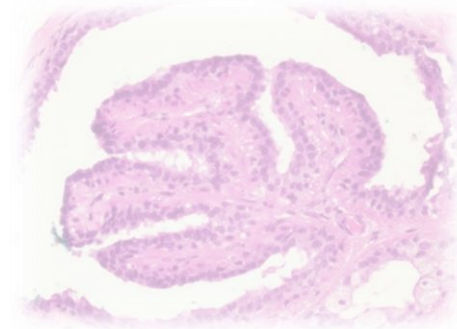
Case 29

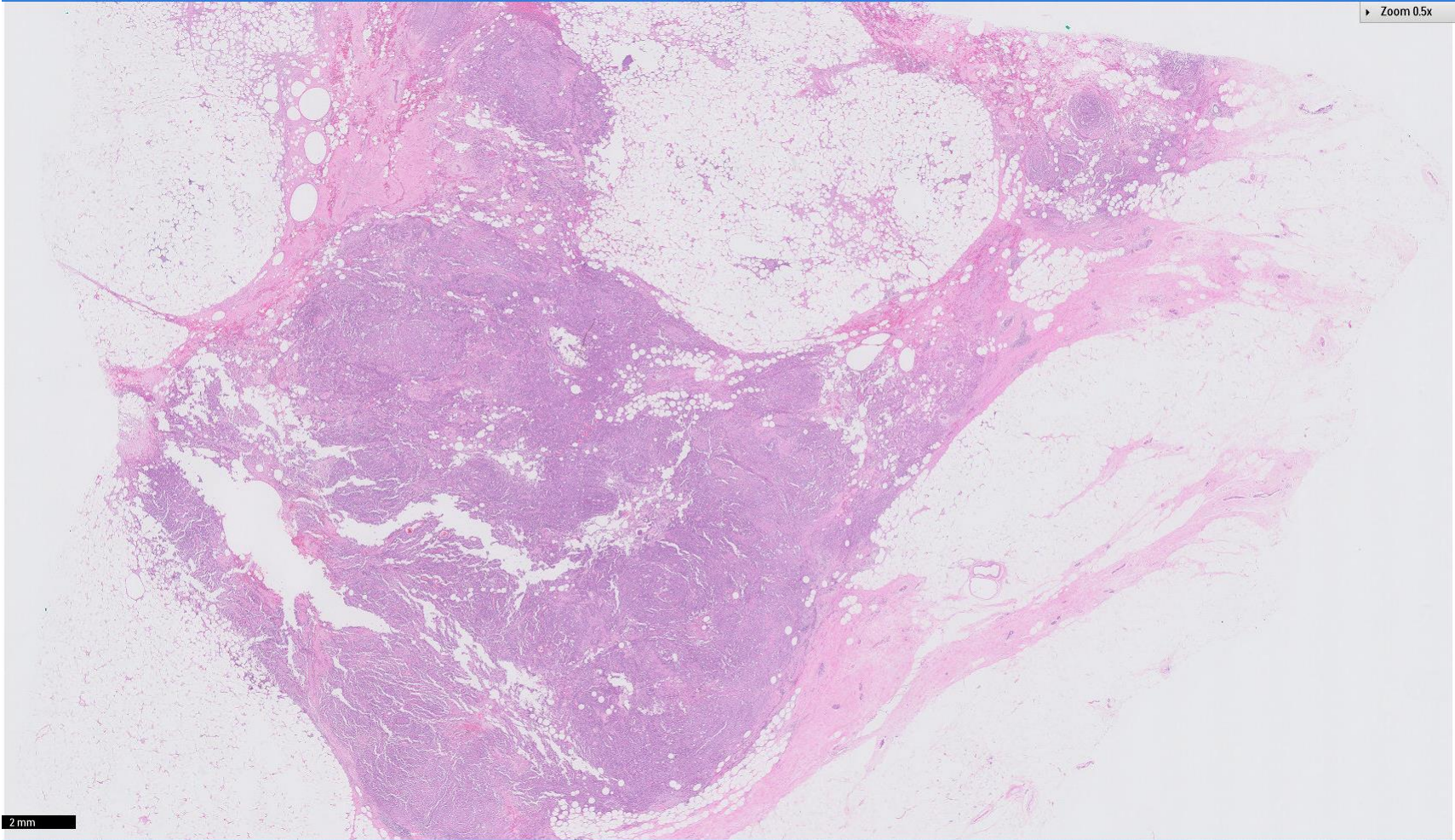
70 year old Indian female.

Wide excision and axillary dissection for right breast invasive ductal carcinoma 10 years ago.

Clinically right breast recurrence.

Section of the current right breast mass.





2 mm

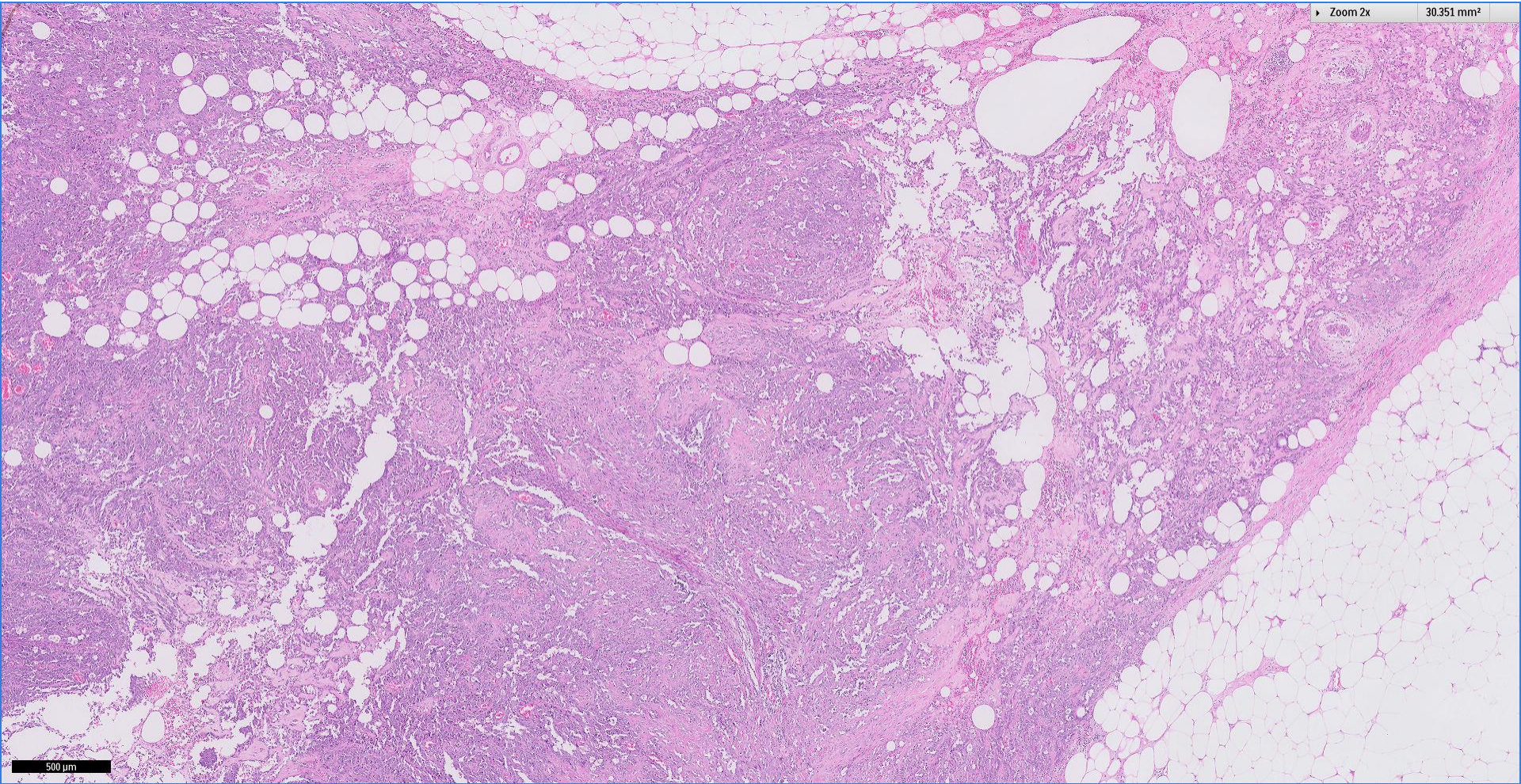


Division of Pathology
Singapore General Hospital



Zoom 2x

30.351 mm²



500 μ m

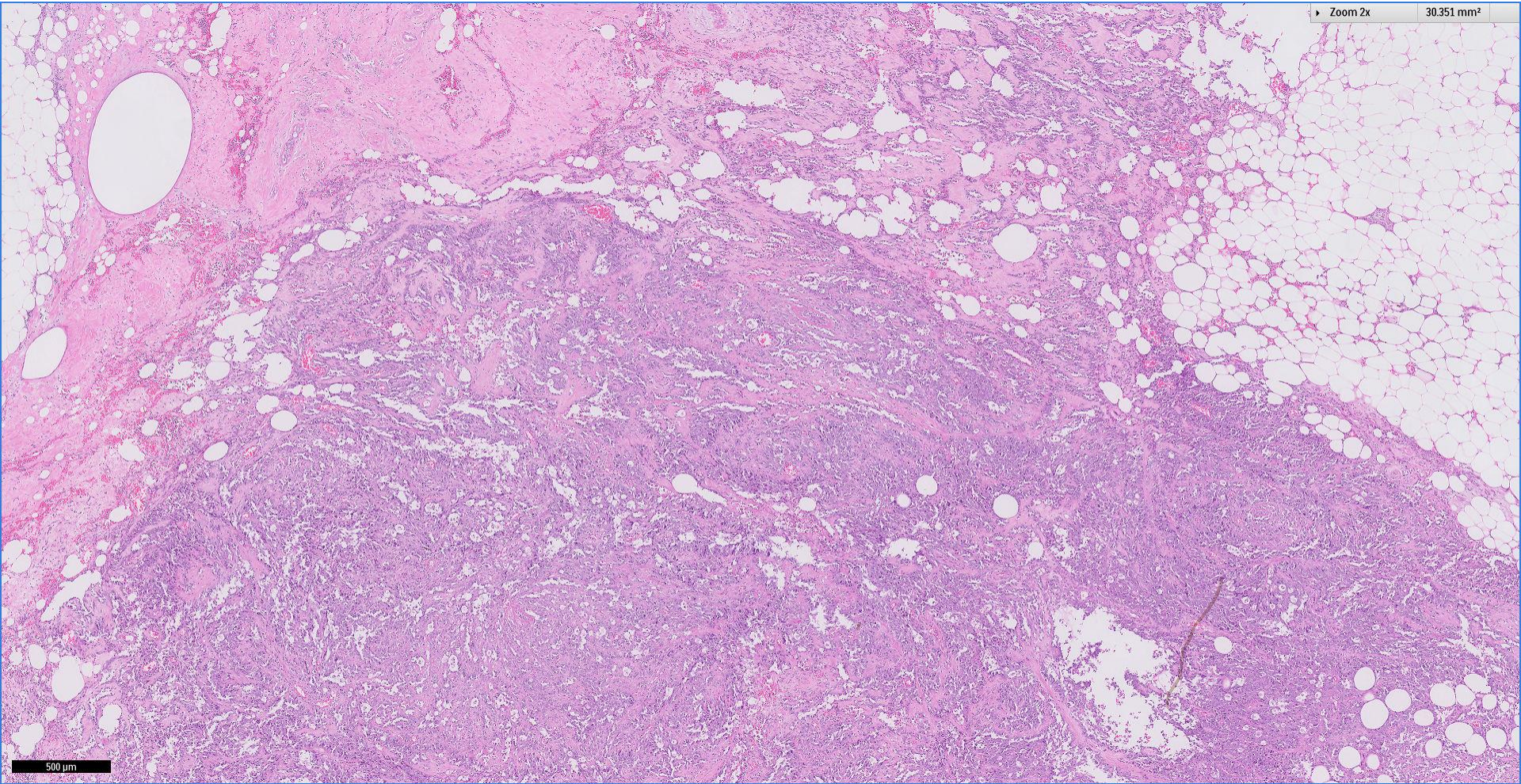


Division of Pathology
Singapore General Hospital



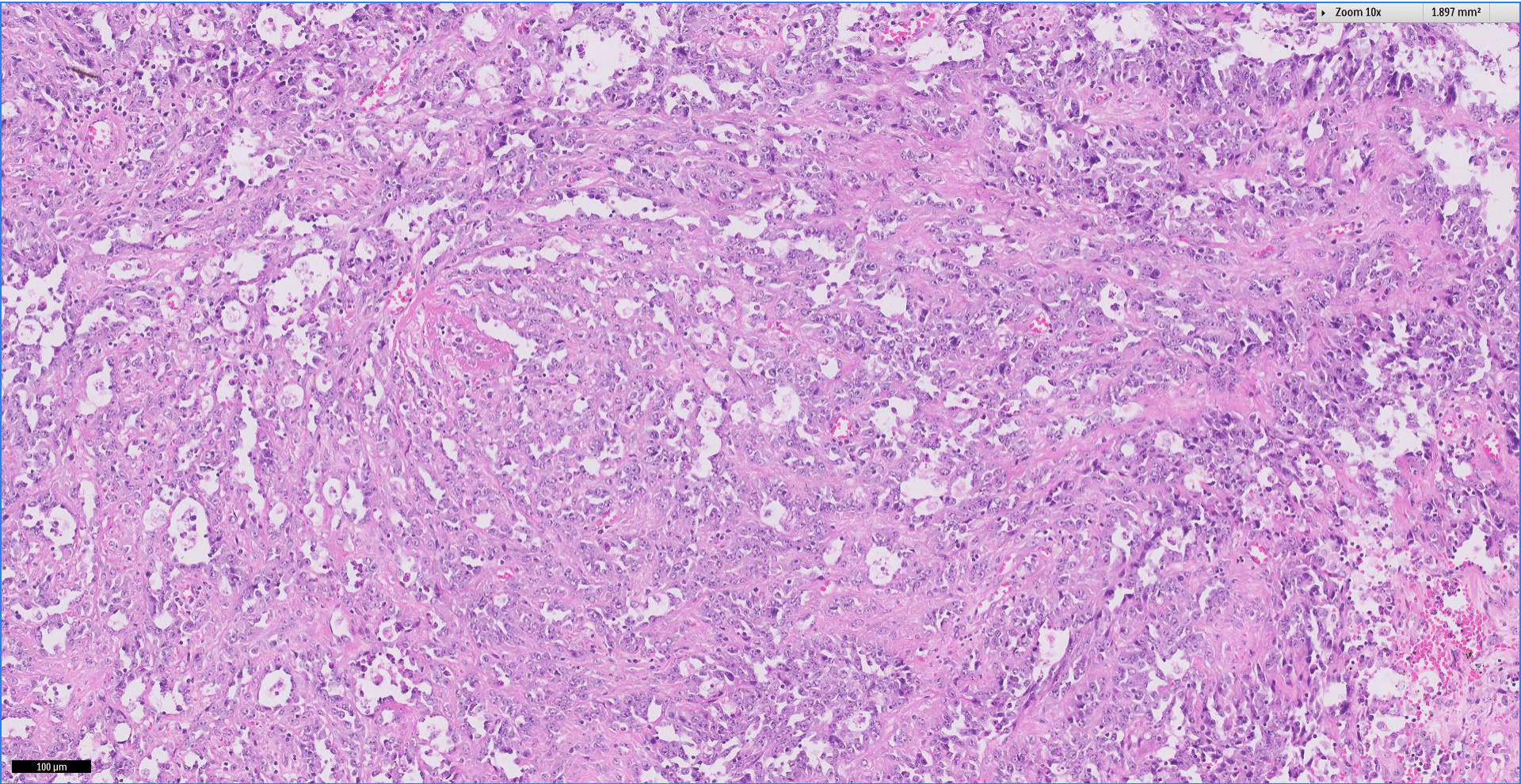
Zoom 2x

30.351 mm²



Division of Pathology
Singapore General Hospital



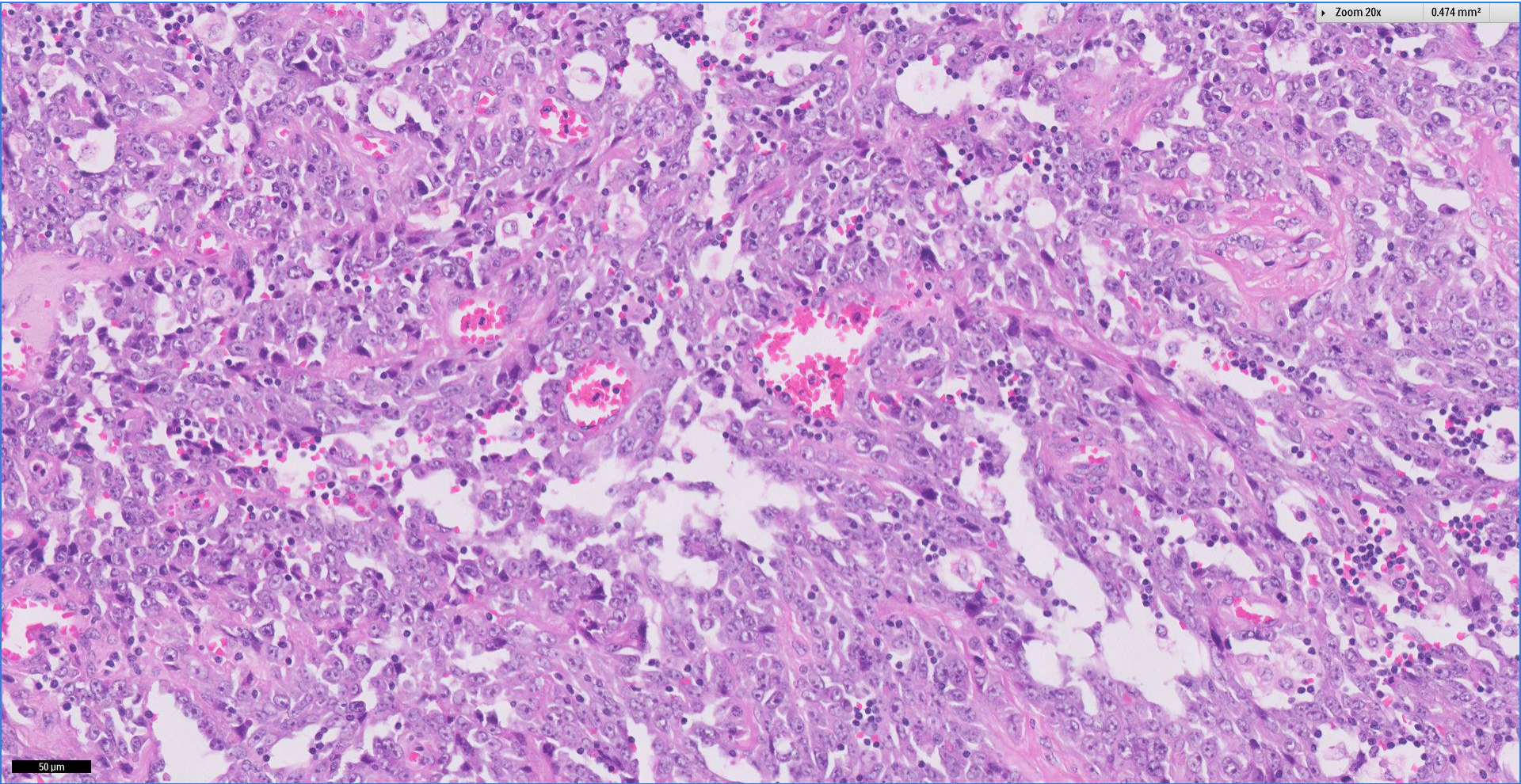


100 µm



Division of Pathology
Singapore General Hospital





Division of Pathology
Singapore General Hospital



Thank You