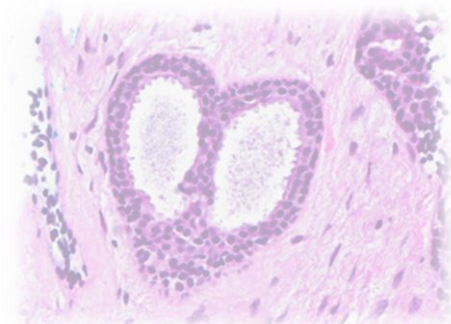
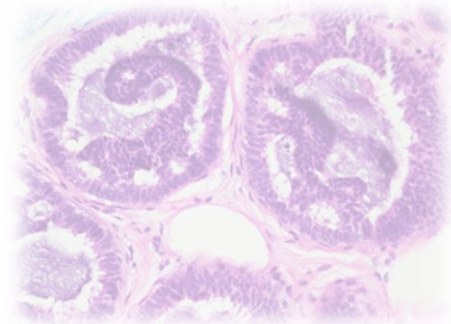
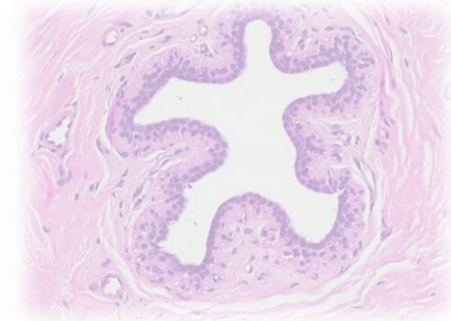
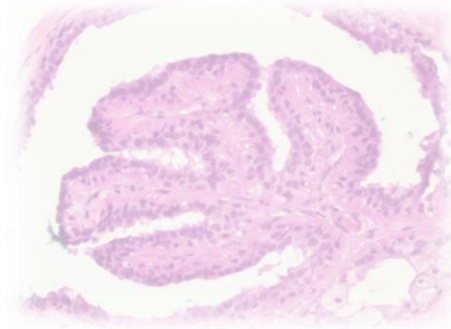
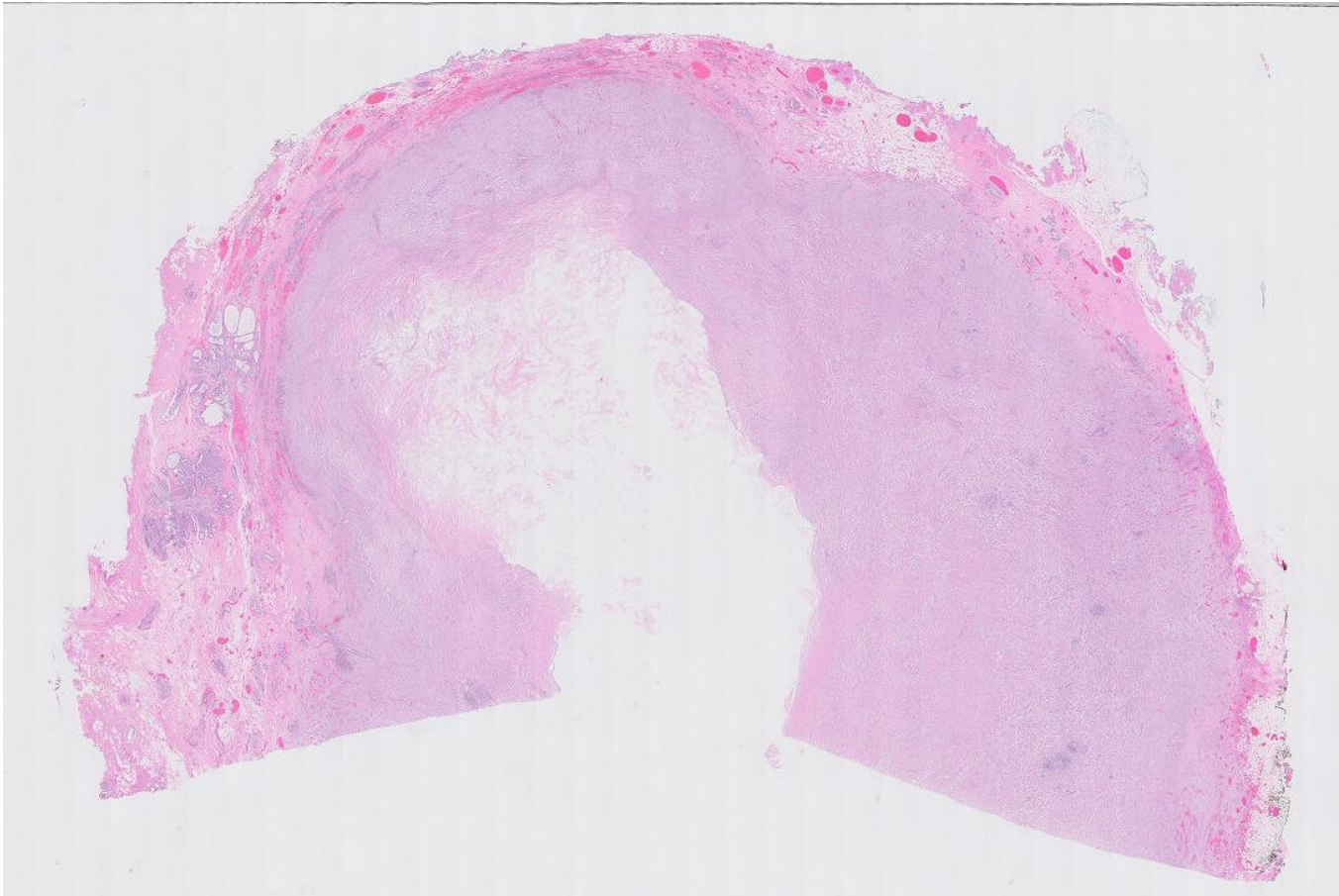


Case 28

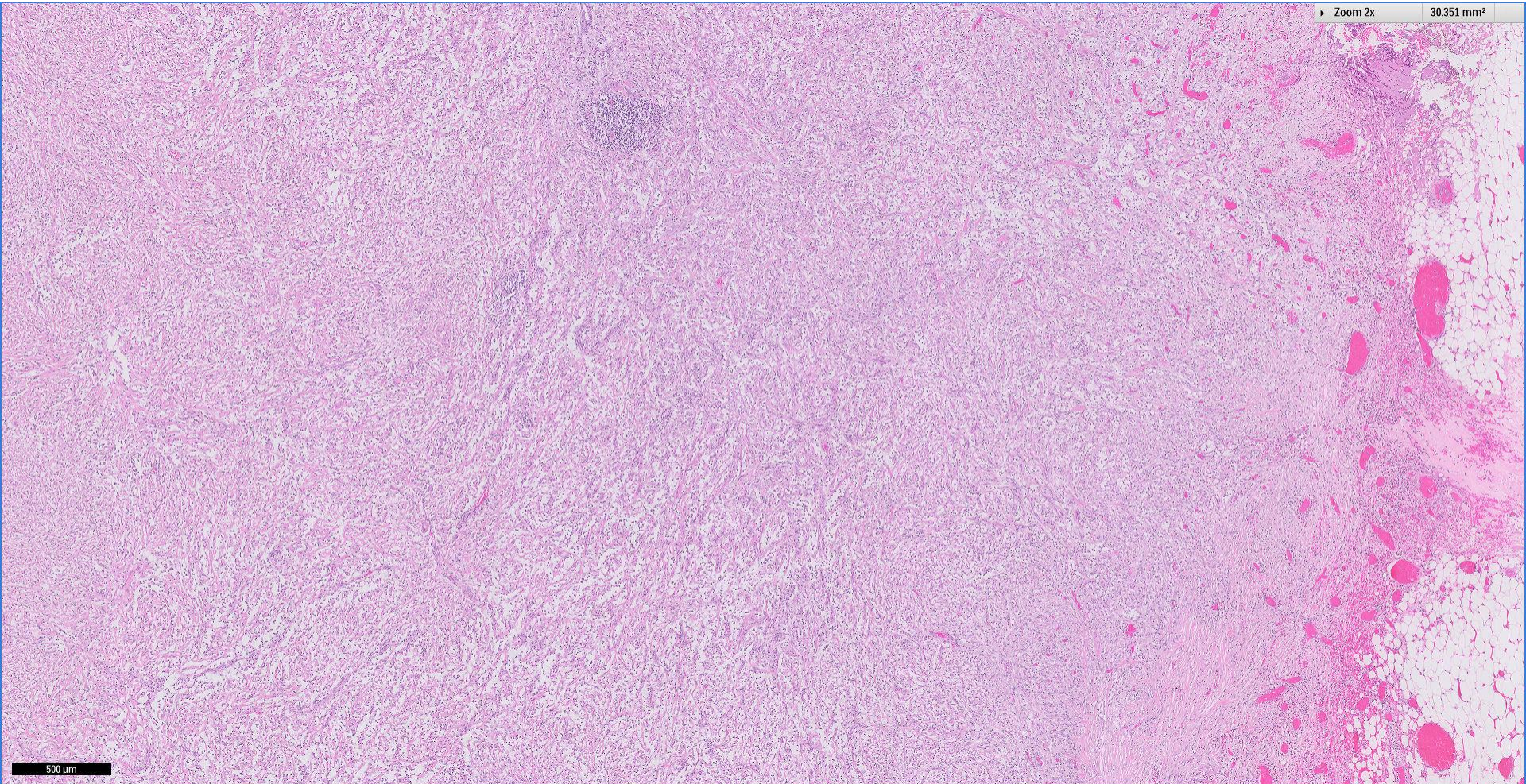
49 year old Indian female.
Excision biopsy of a right breast 3
o'clock lump.

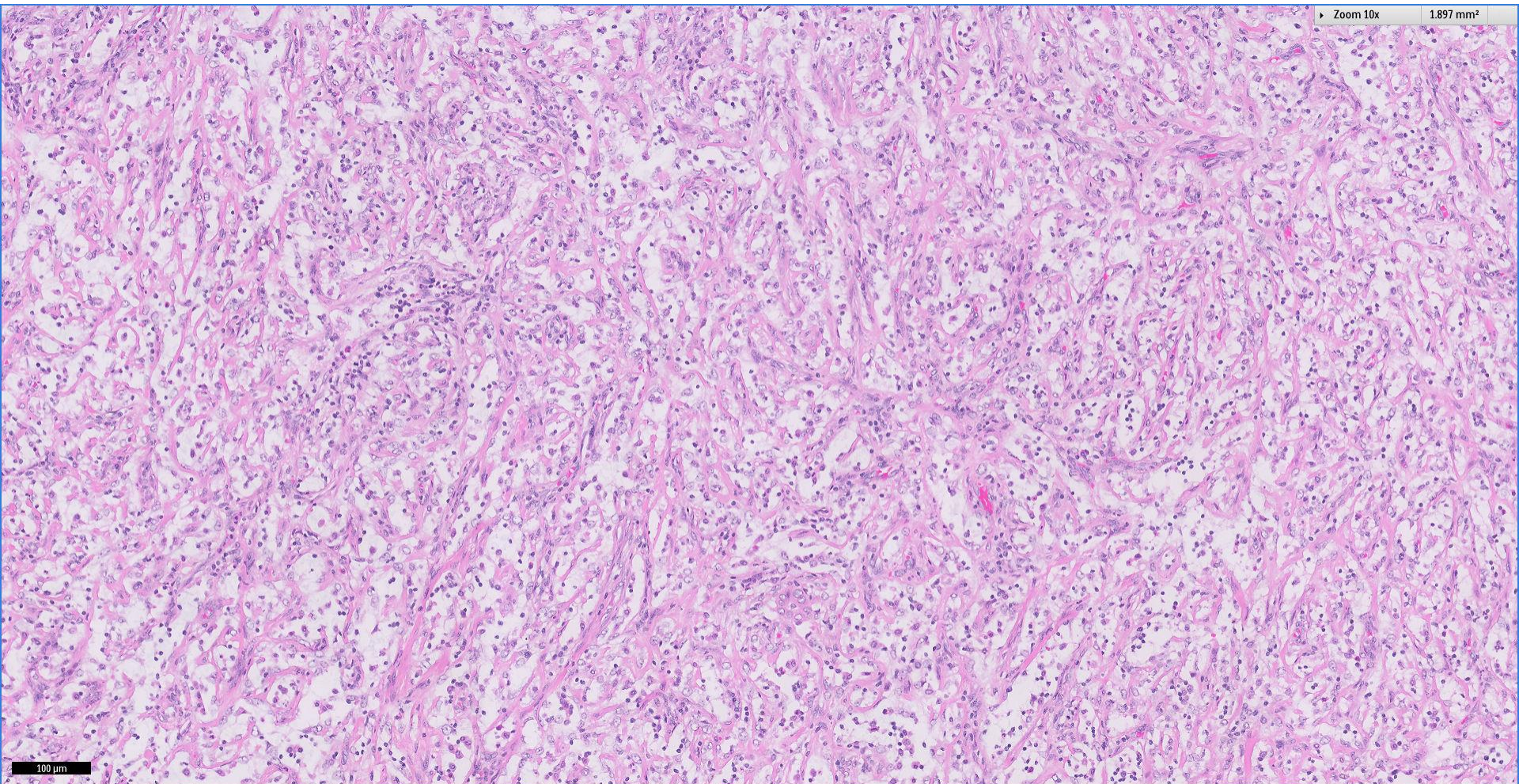


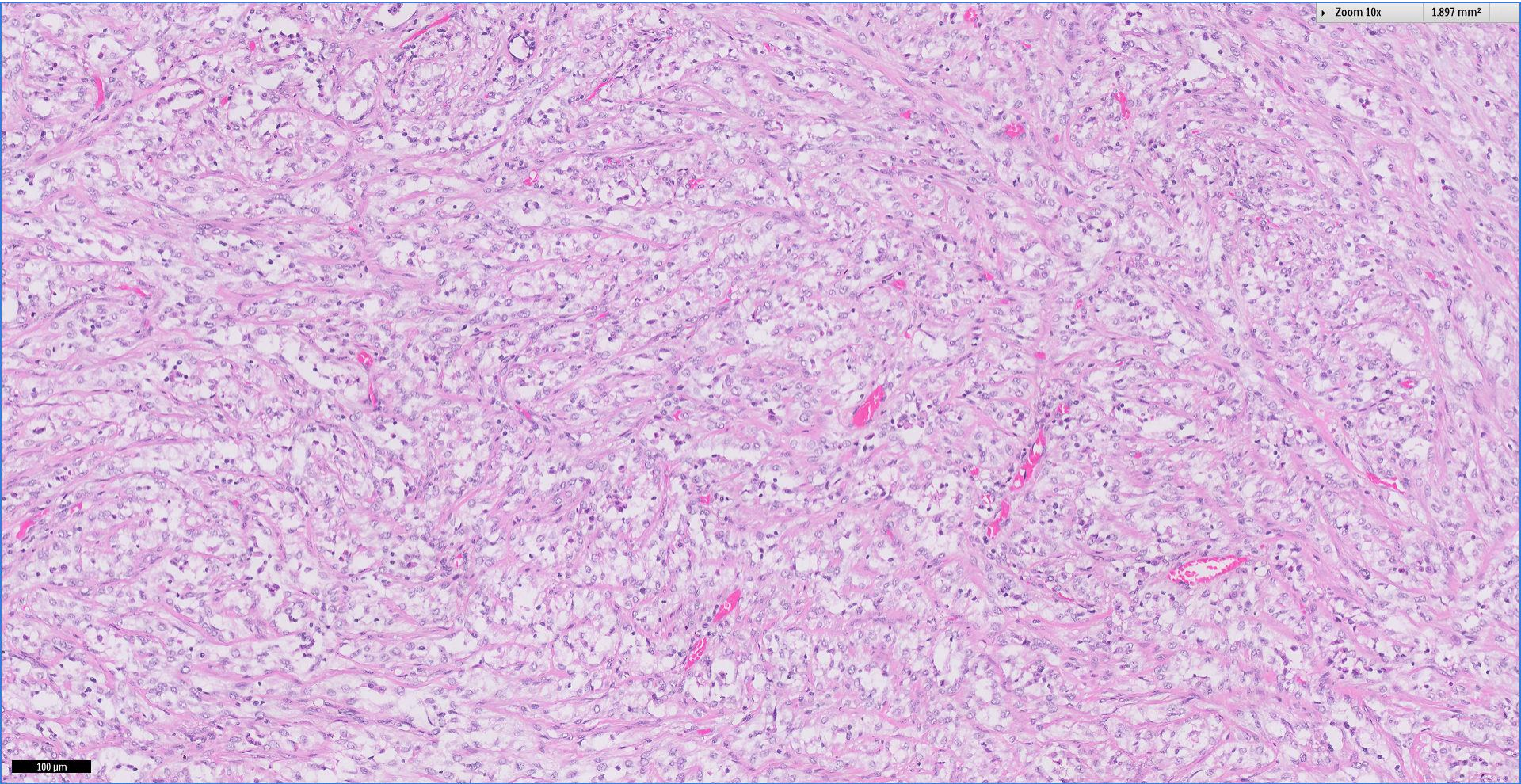


Division of Pathology
Singapore General Hospital







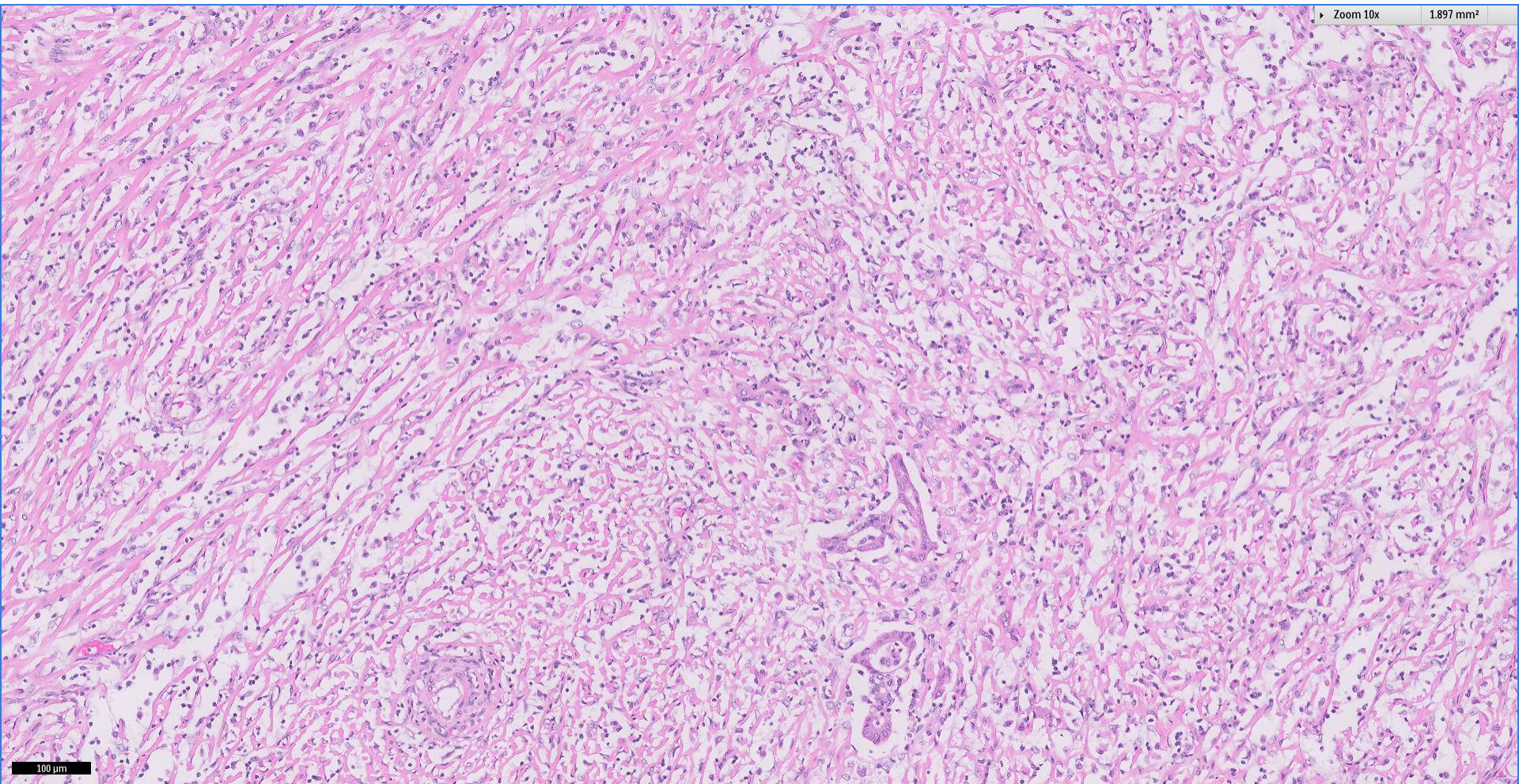


100 μ m



Division of Pathology
Singapore General Hospital





Thank You