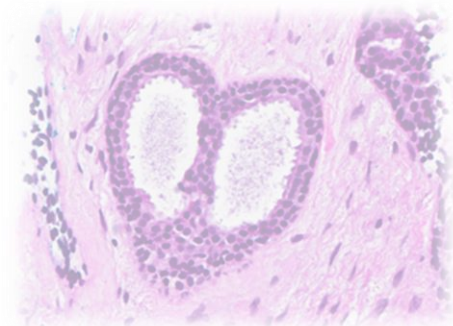
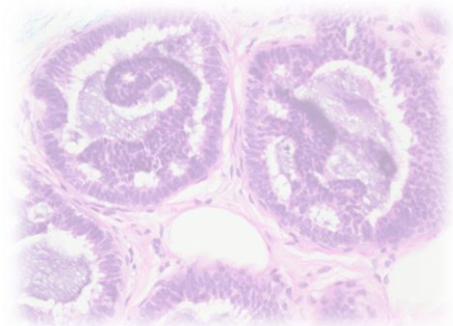
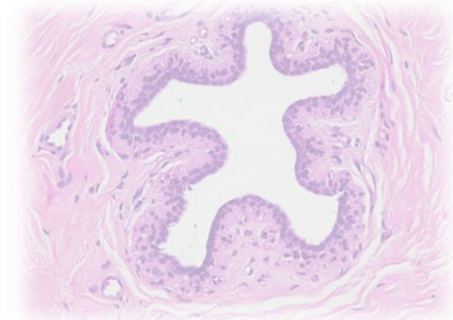
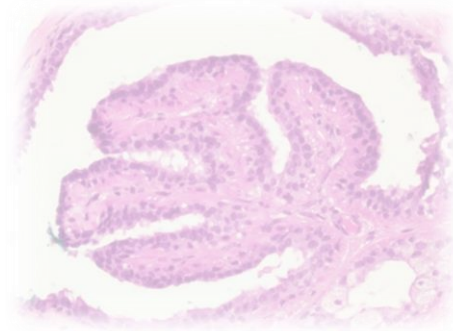
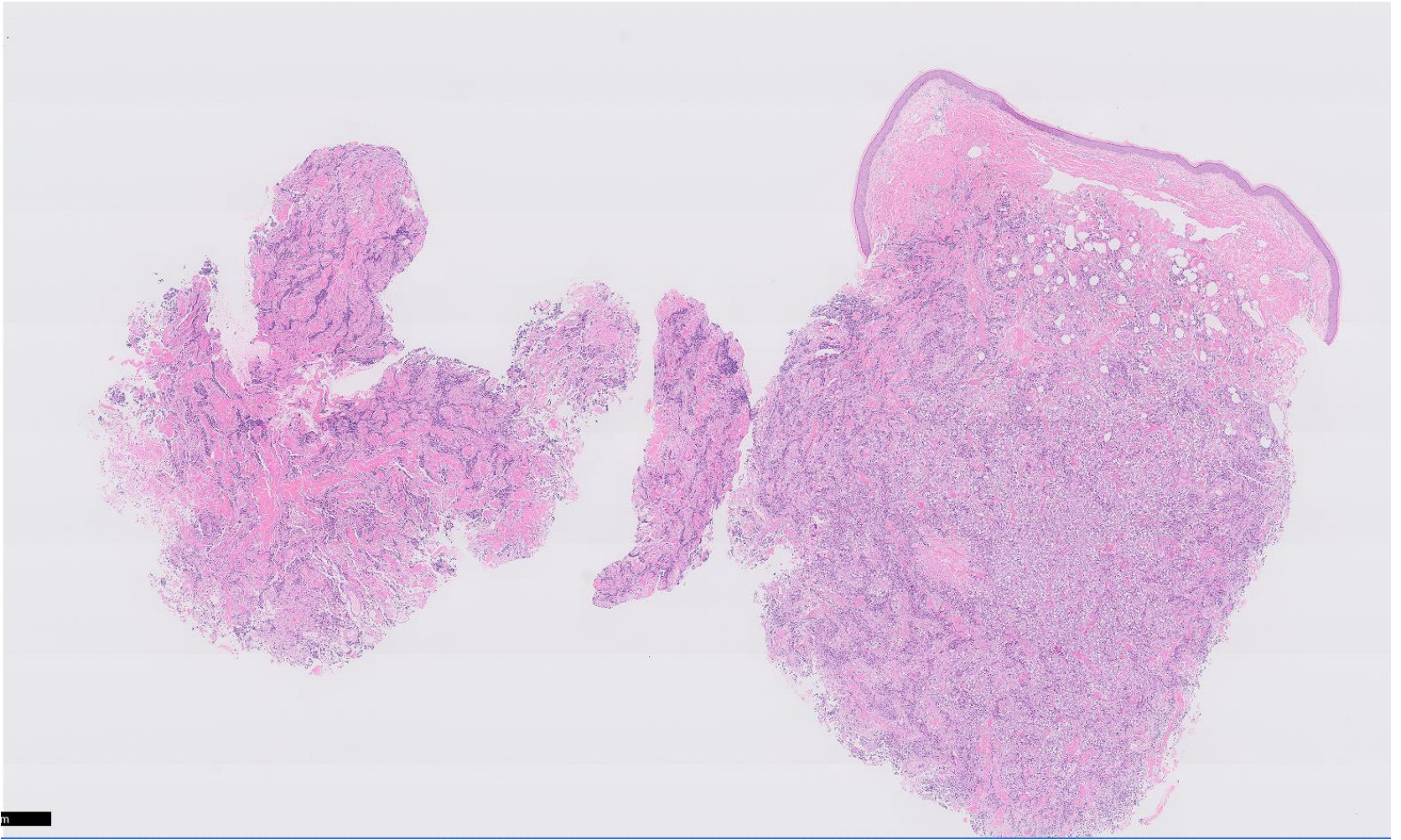
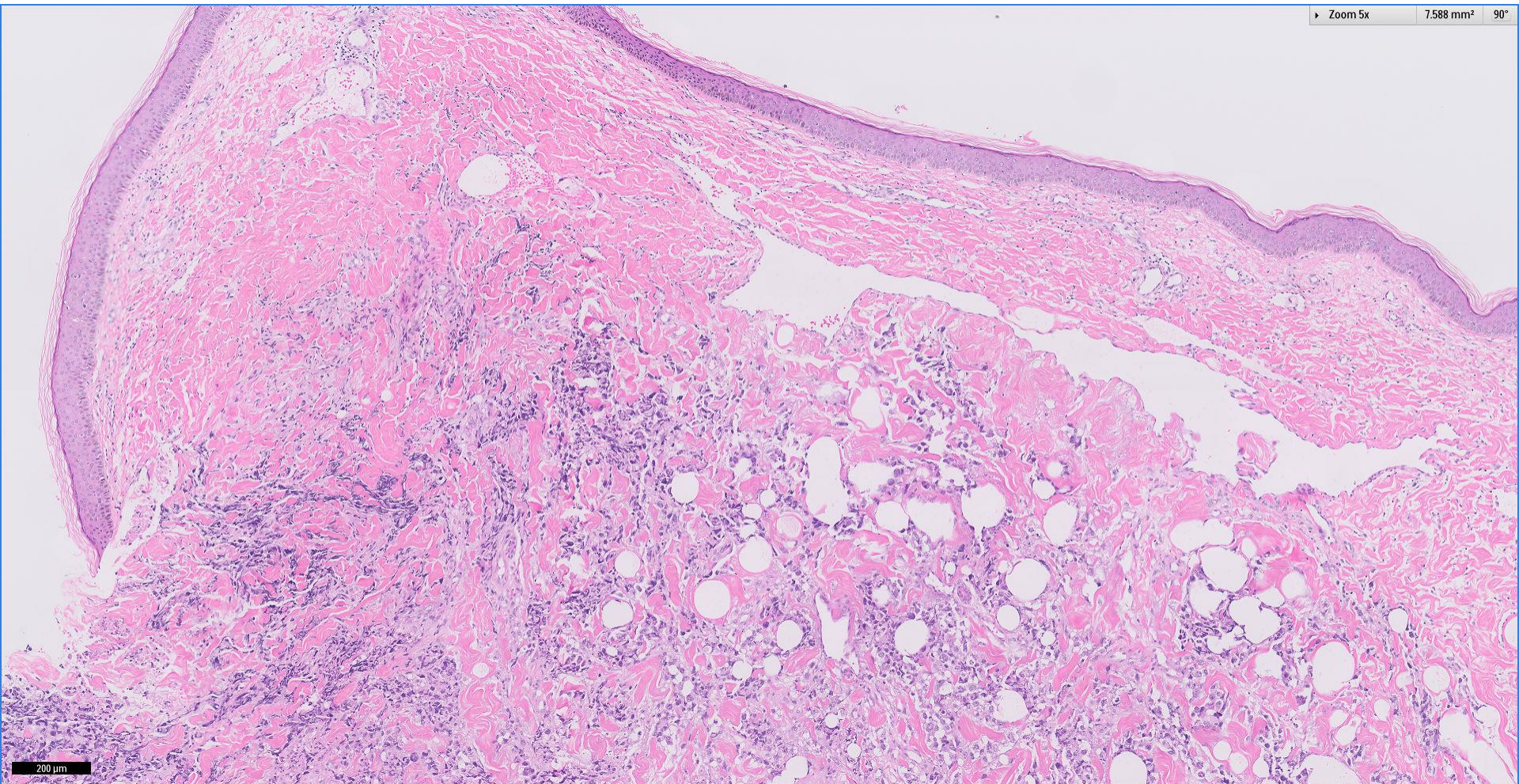


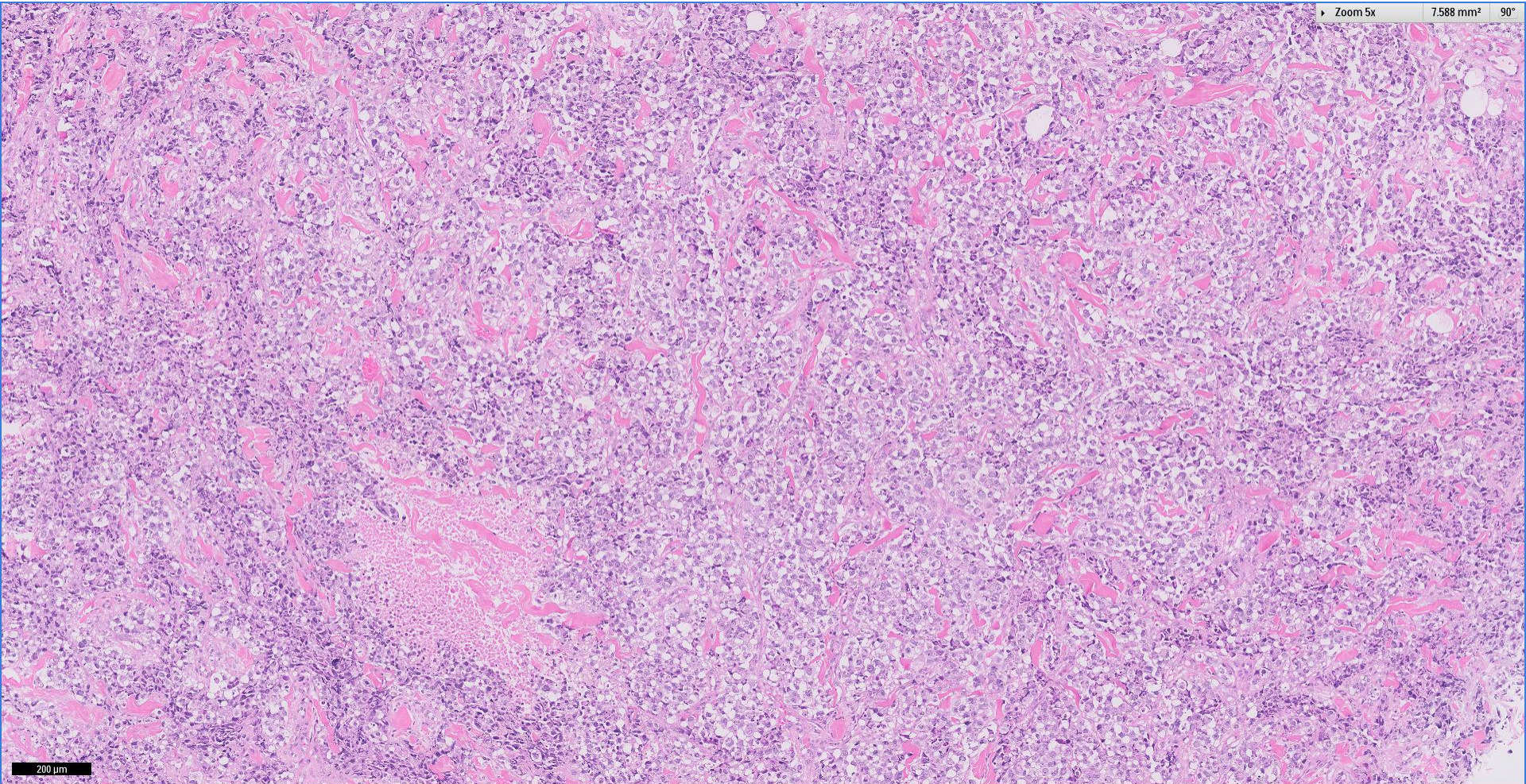
## Case 27

61 year old Chinese female.  
Wedge biopsy, right breast tumour.  
Previous core biopsies of the right breast tumour and right axillary lymph node were diagnosed as 'necrotic tumour, consistent with carcinoma' and 'metastatic carcinoma' respectively.

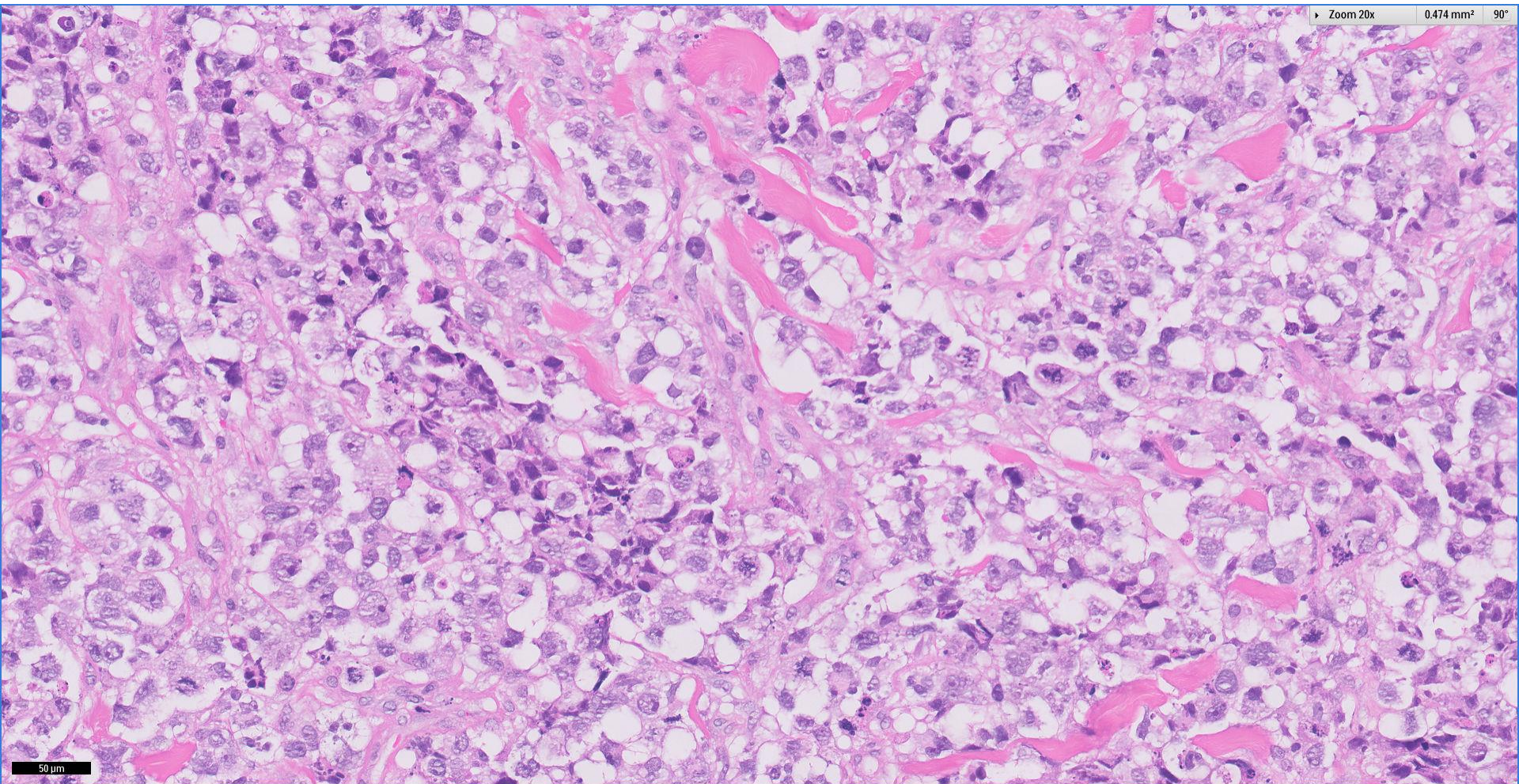


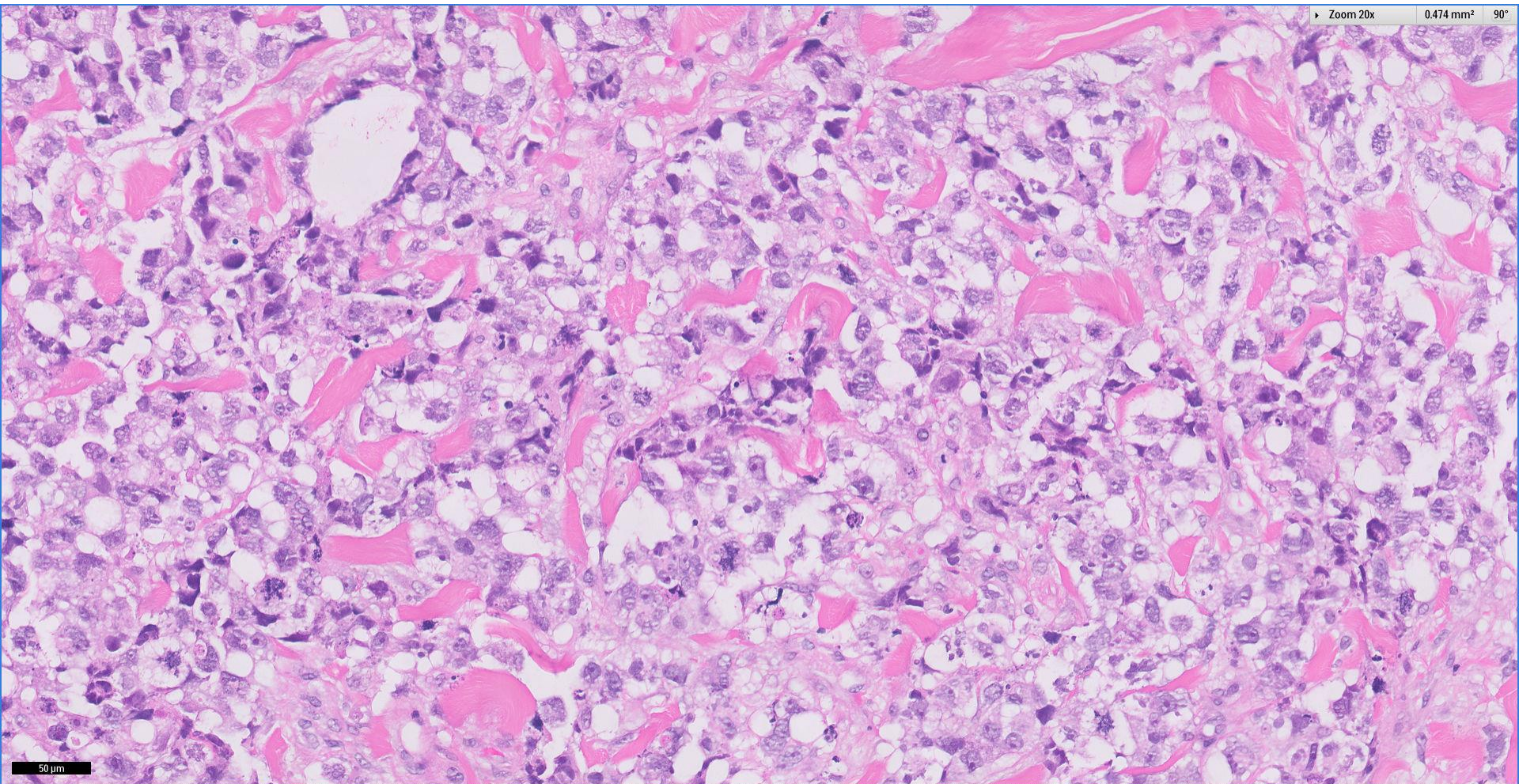






200 µm





Division of Pathology  
Singapore General Hospital



*Thank You*