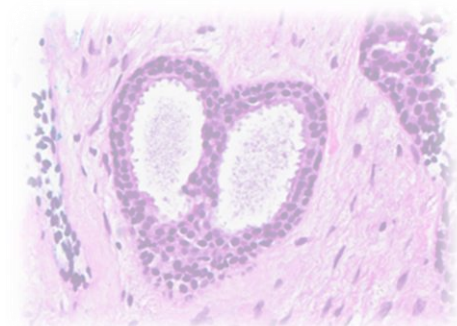
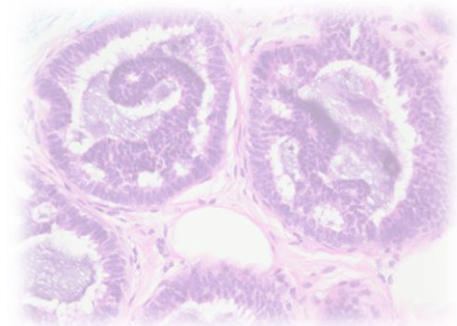
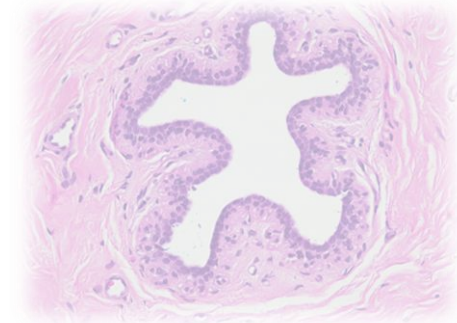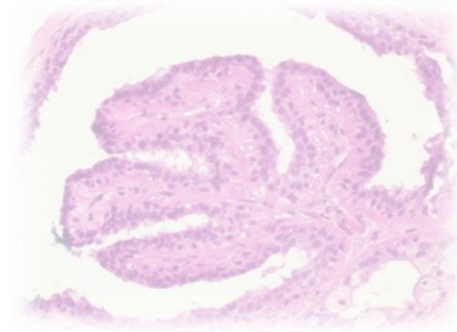
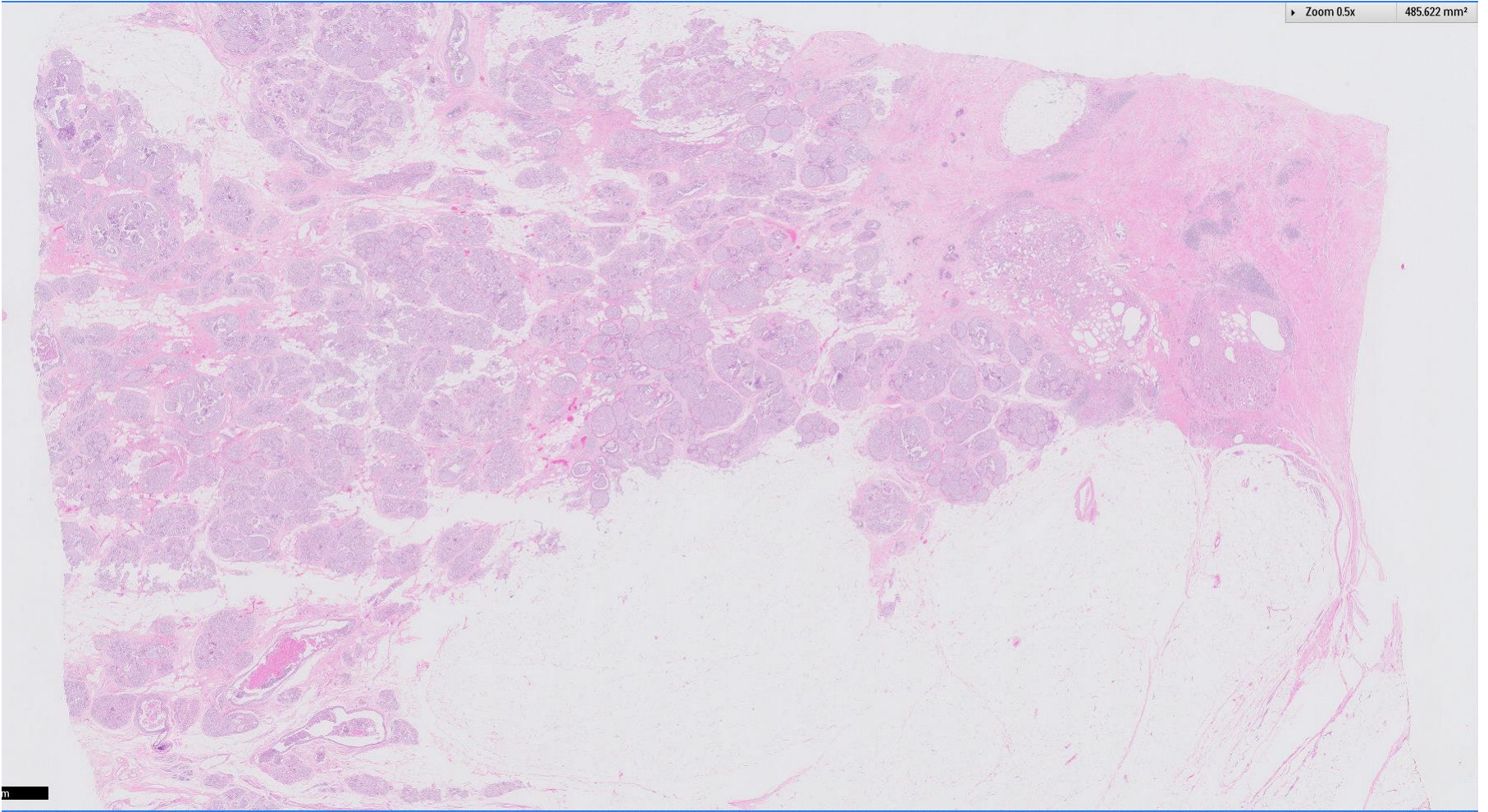


Case 26

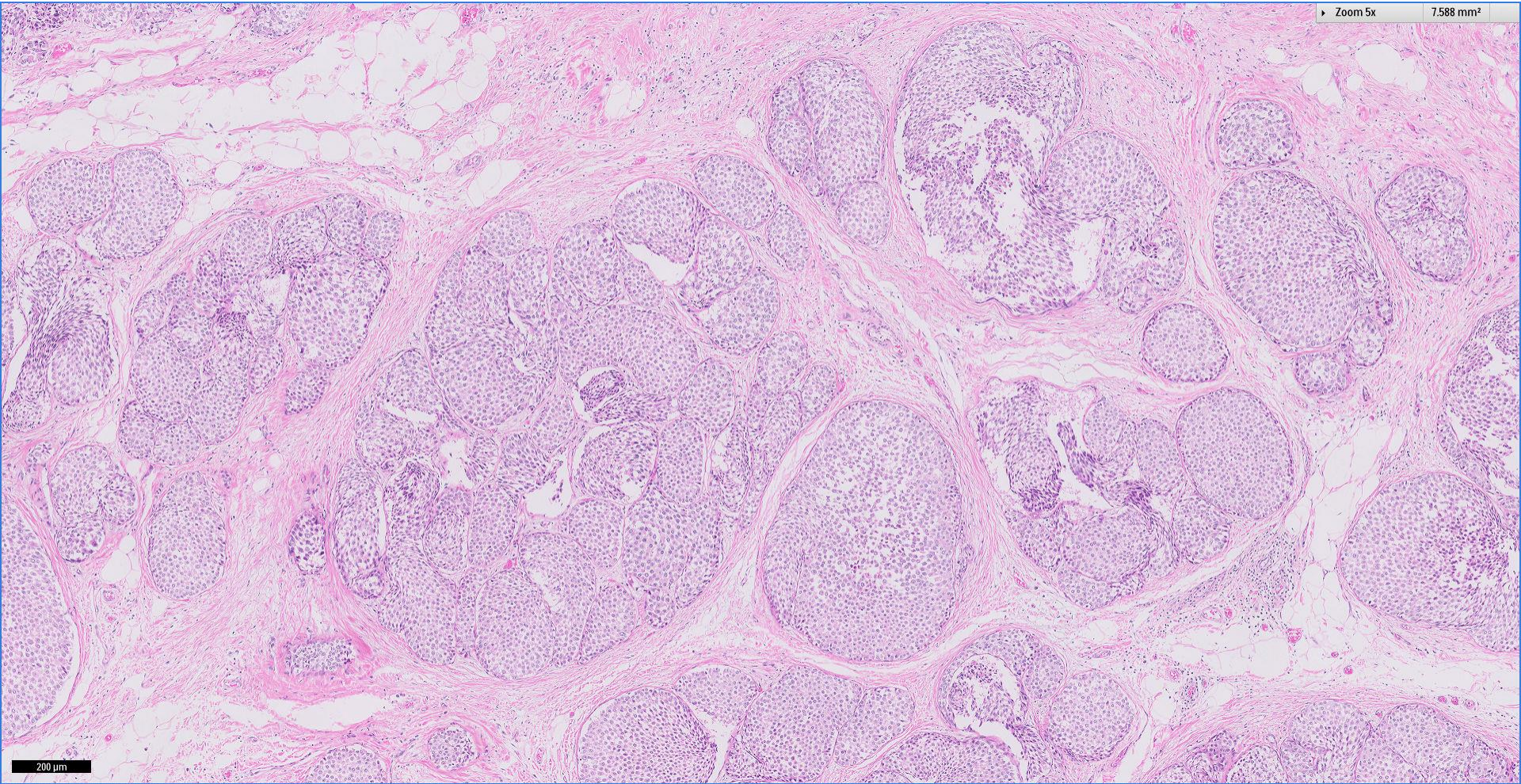
39 year old Chinese female.
Right skin sparing mastectomy.





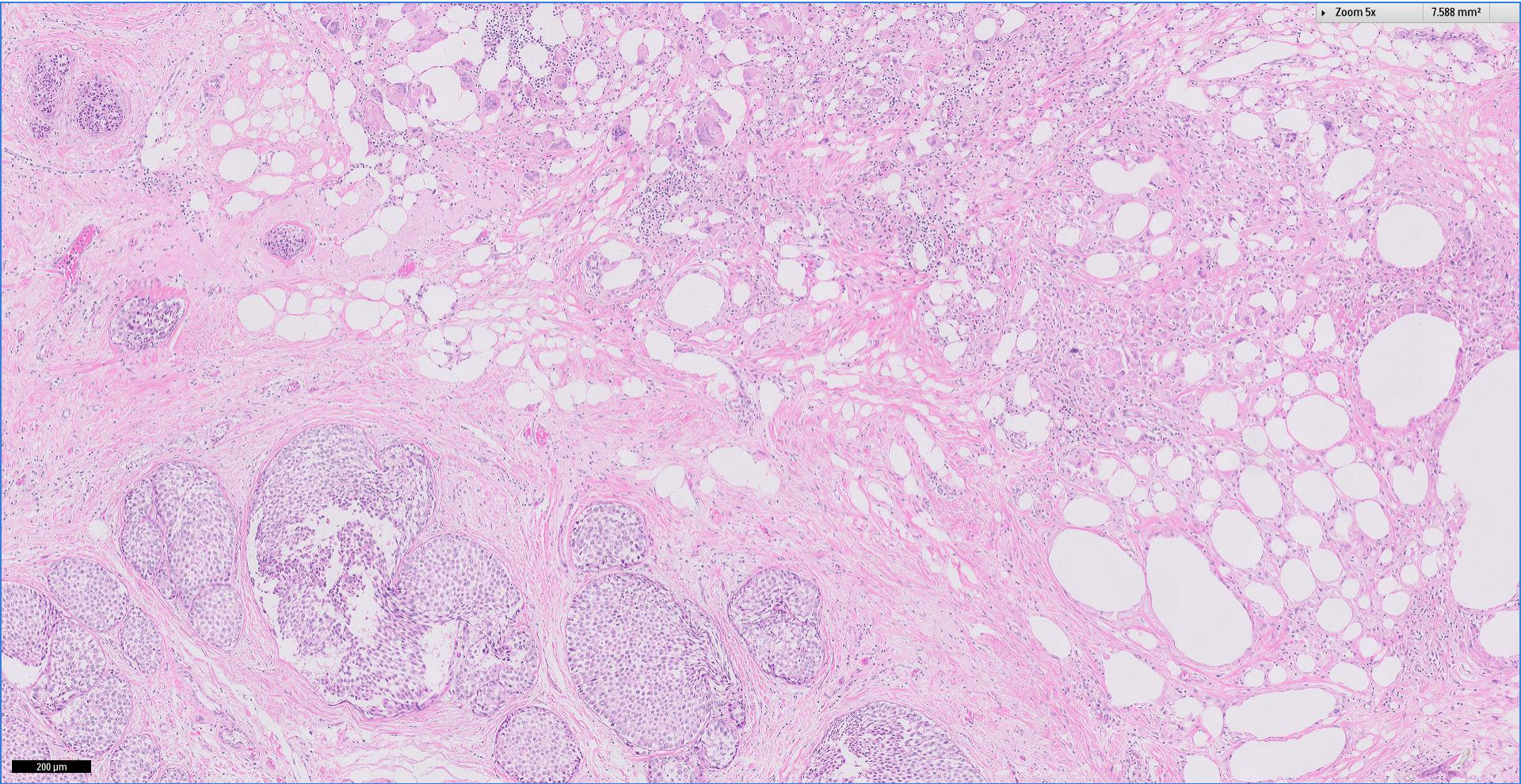
Division of Pathology
Singapore General Hospital

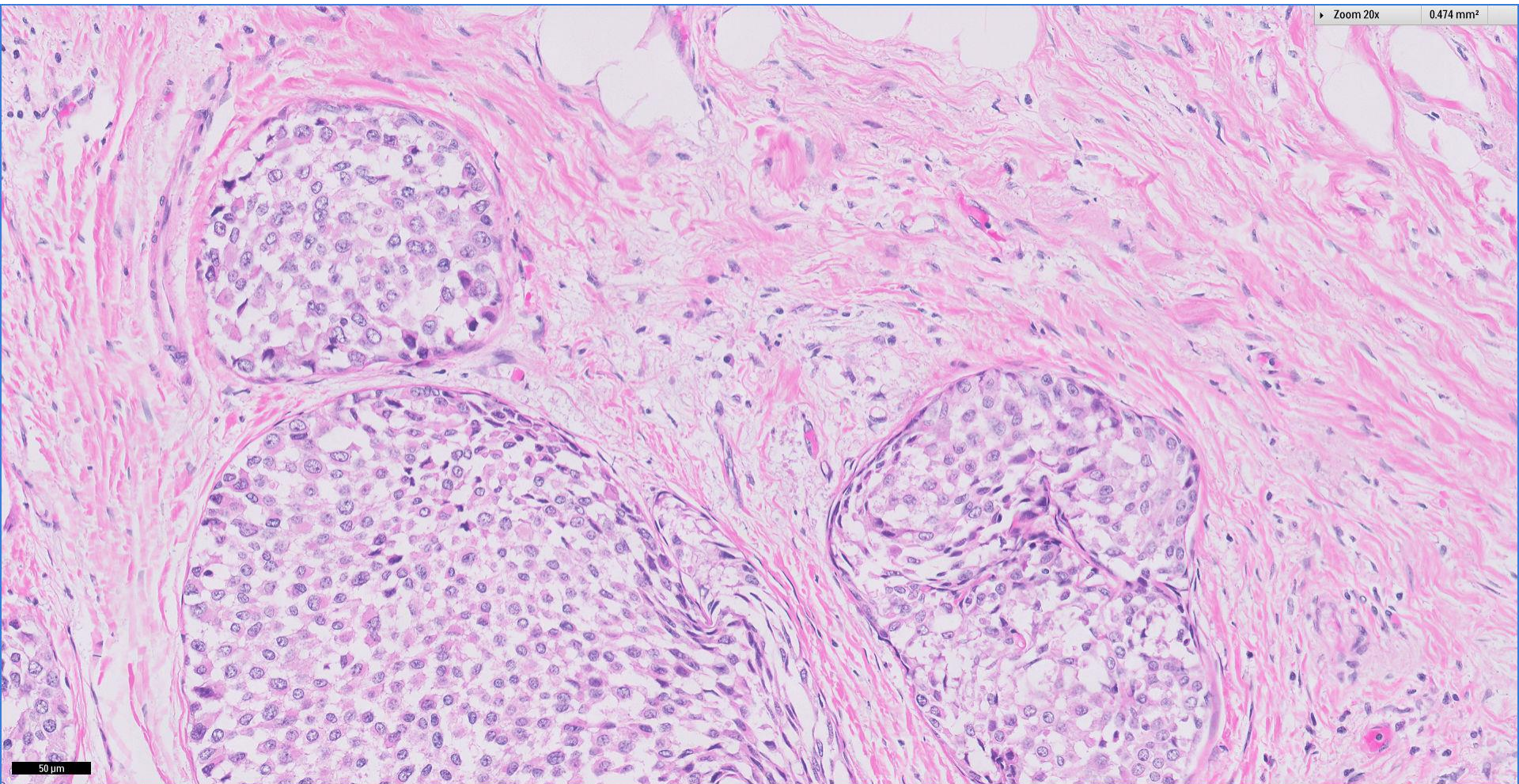


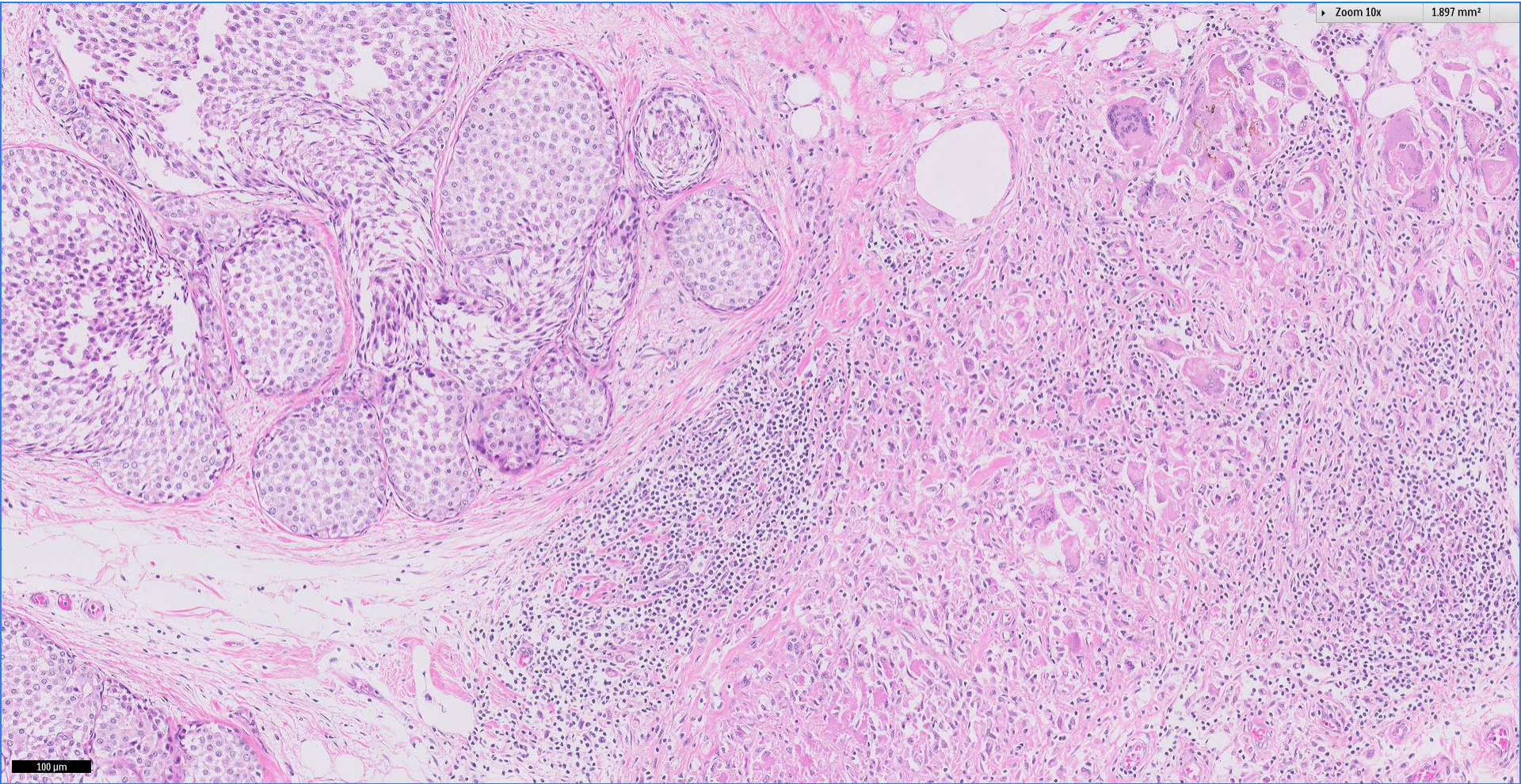


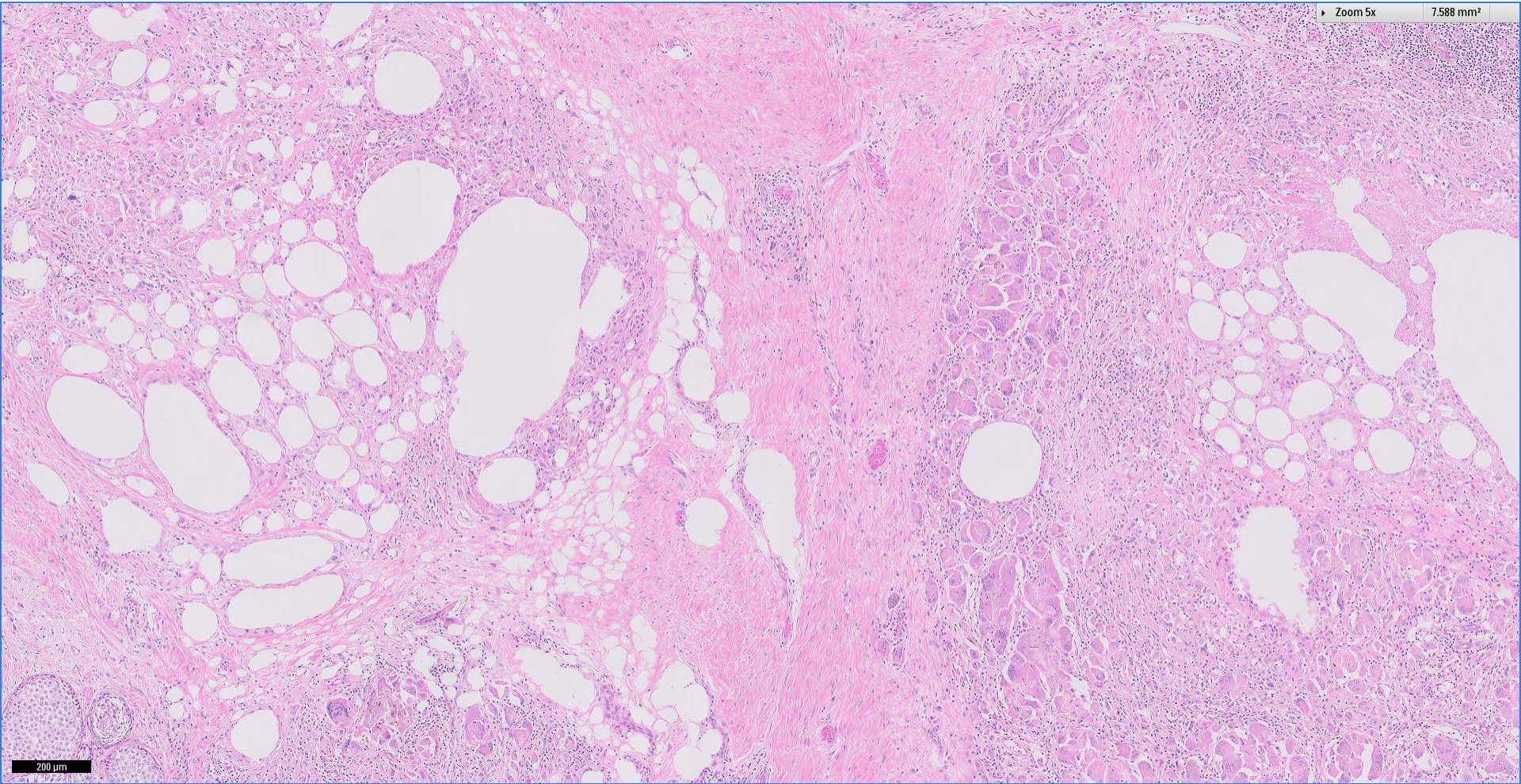
Division of Pathology
Singapore General Hospital











Thank You