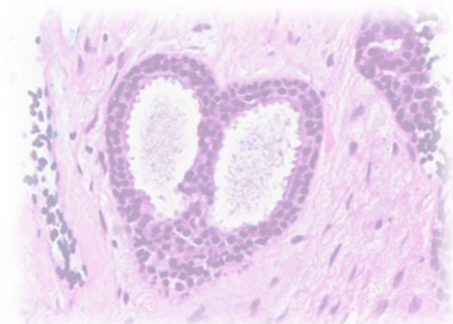
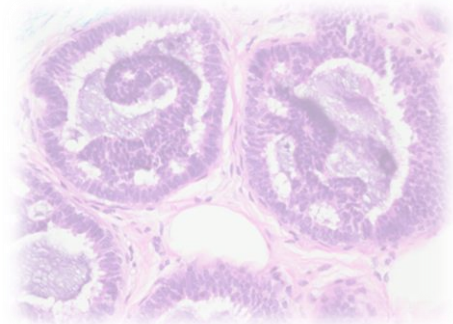
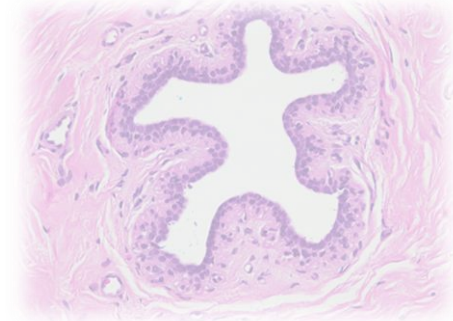
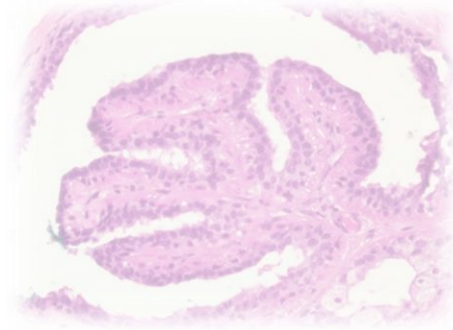
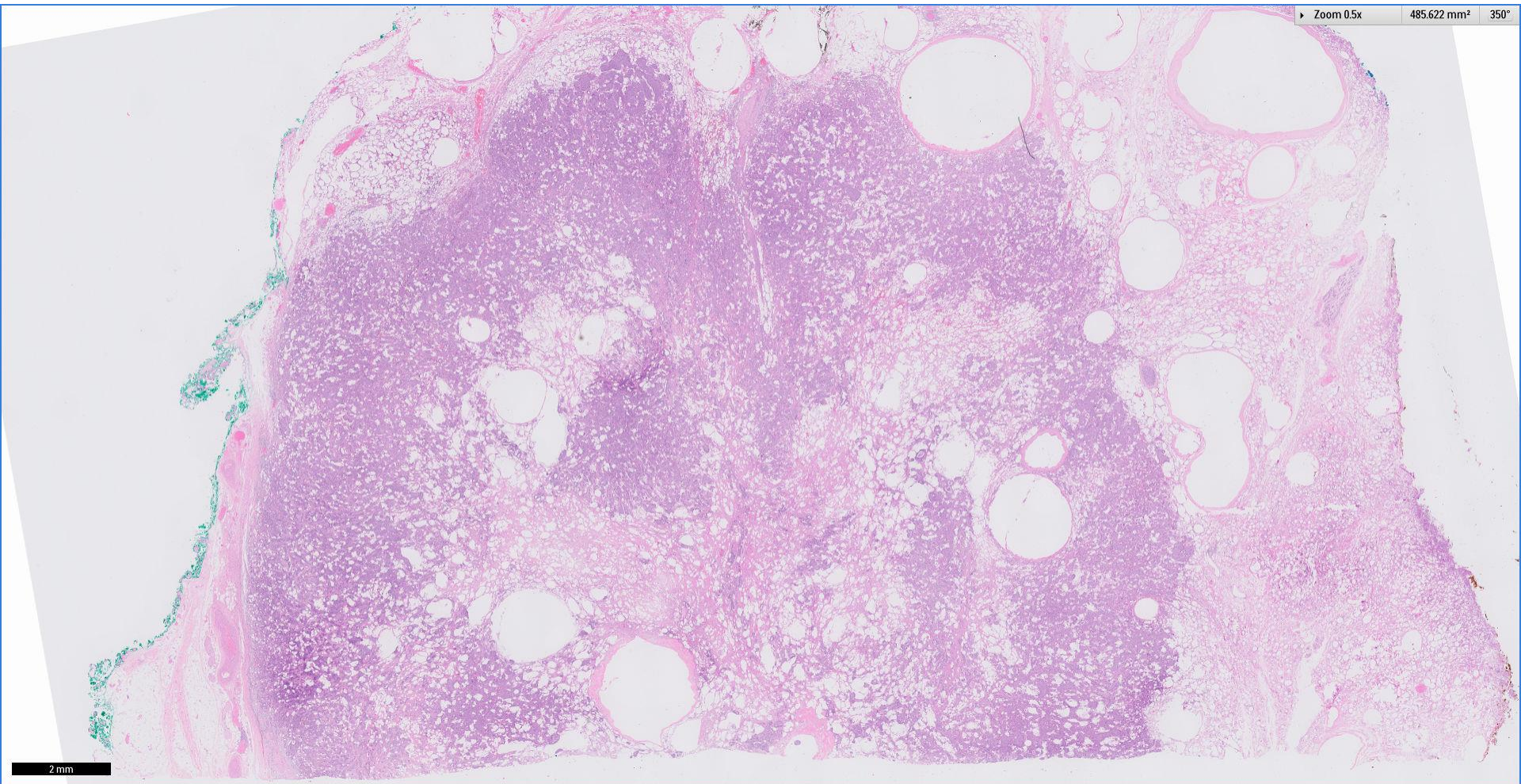


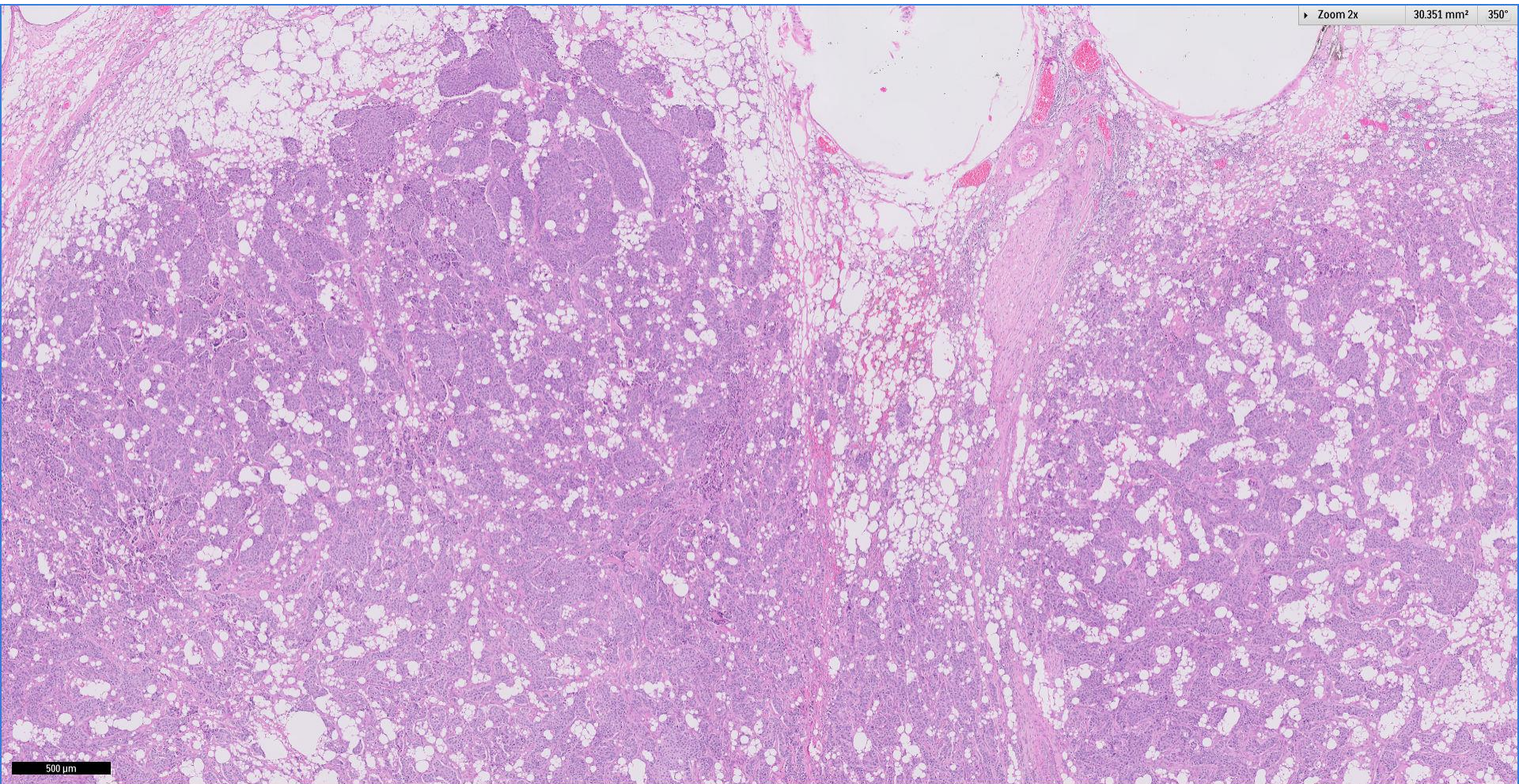
Case 24

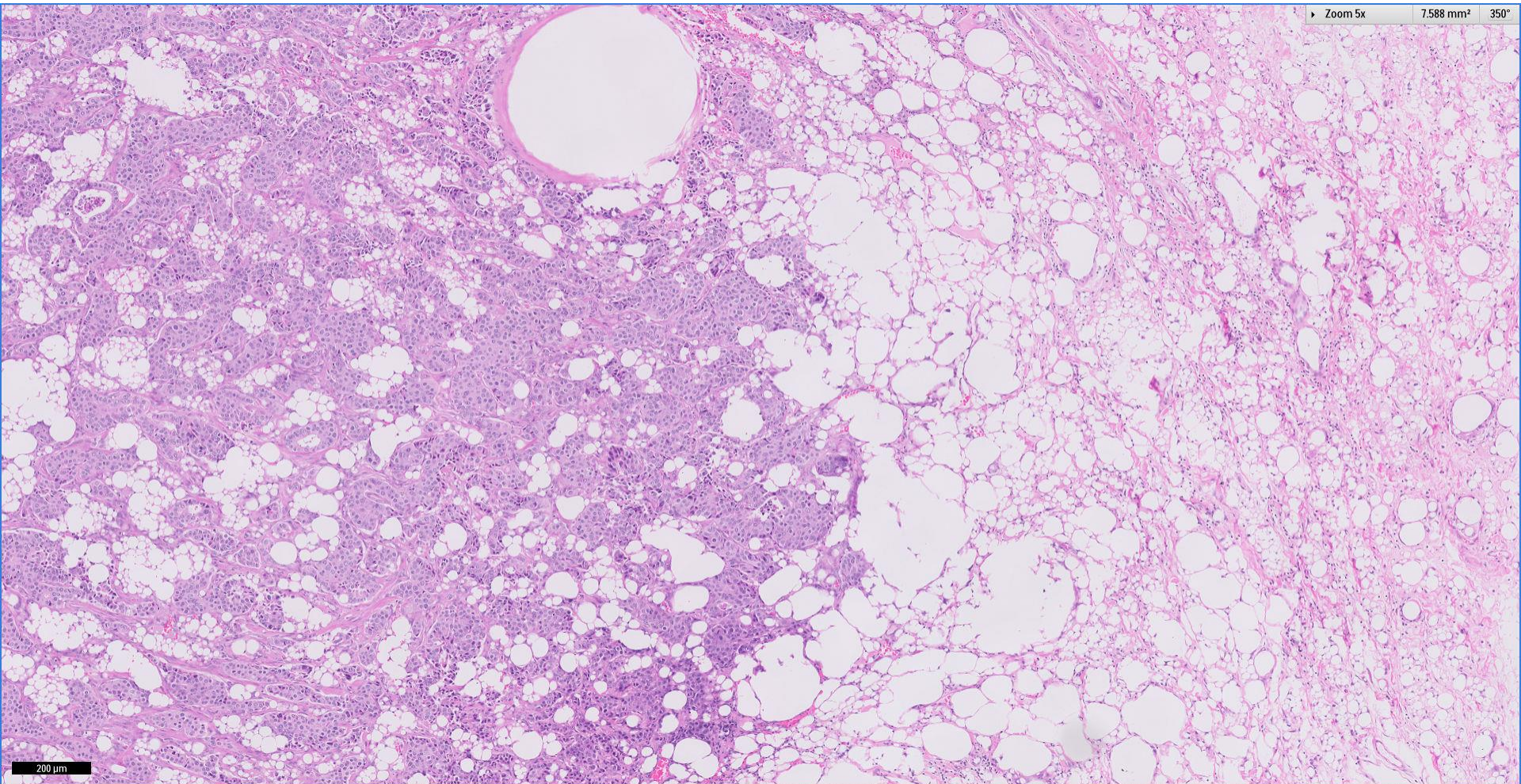
37 year old female.

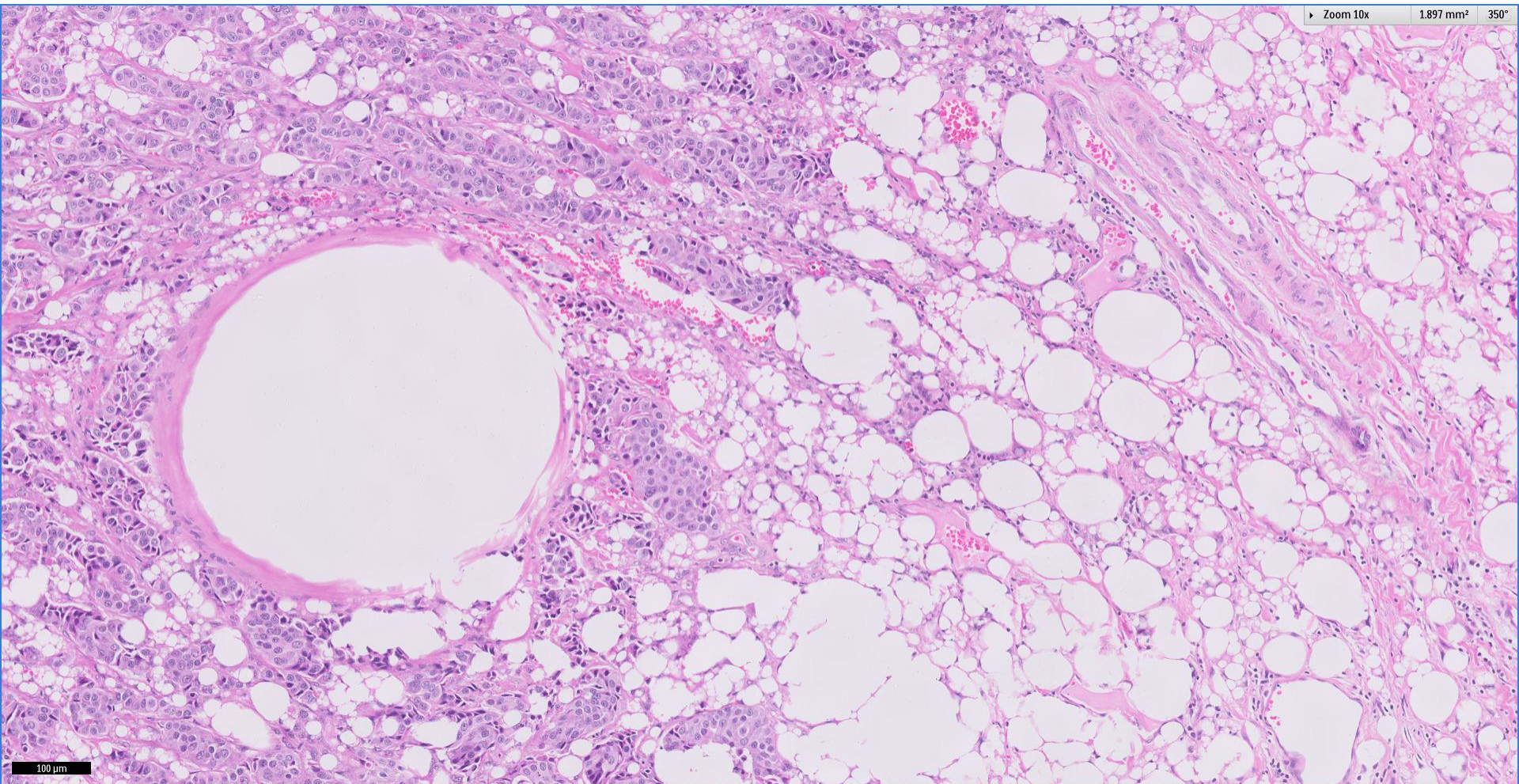
Right breast lump, excision biopsy.

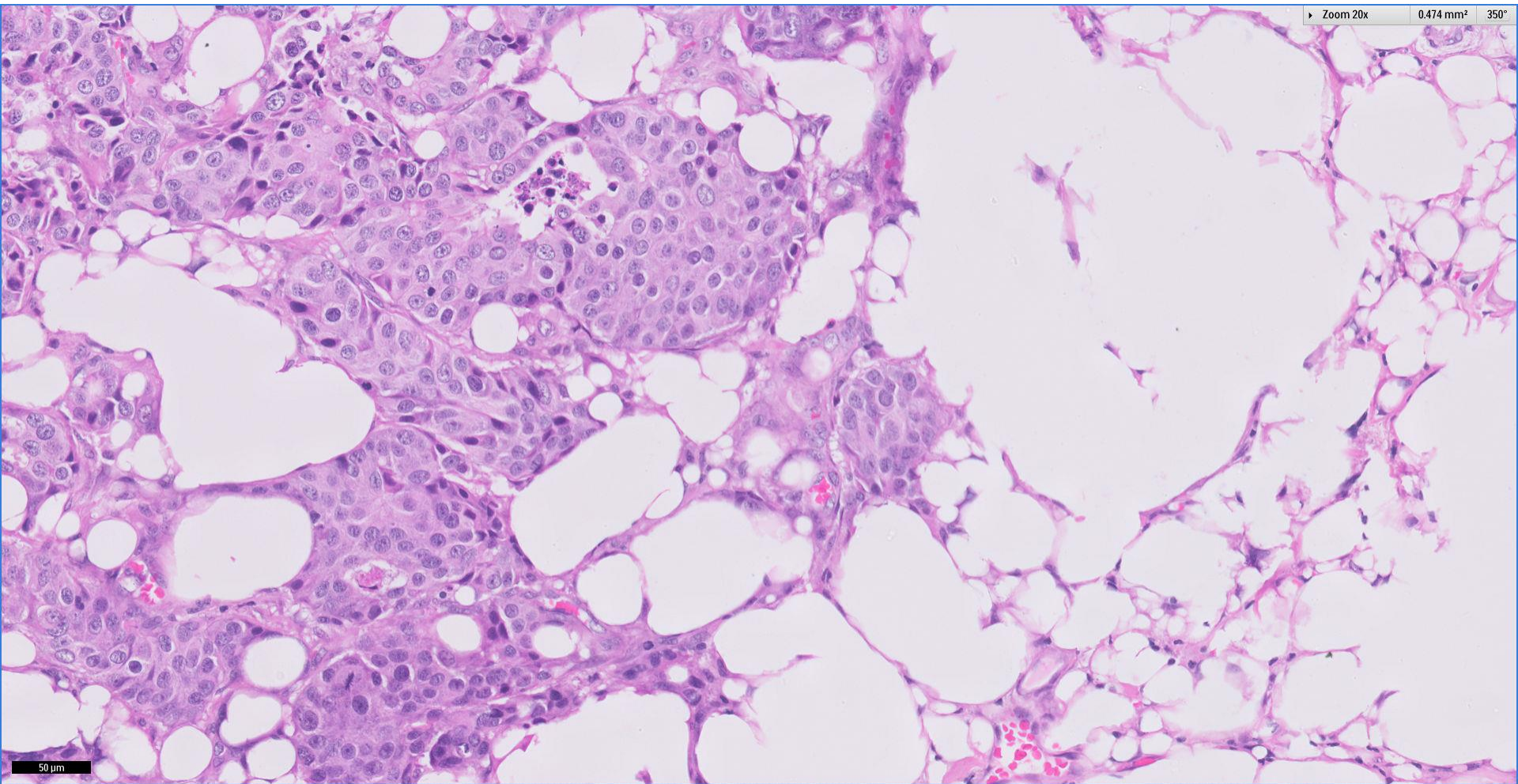












Division of Pathology
Singapore General Hospital



Thank You