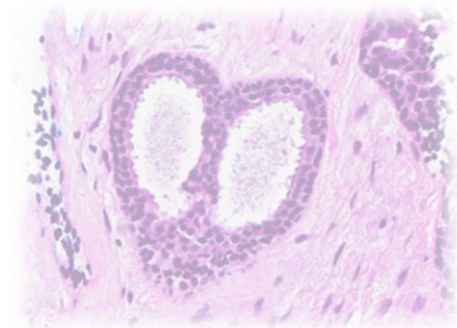
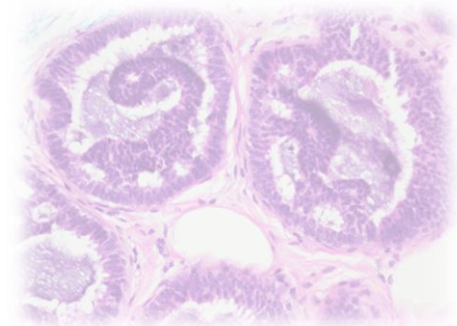
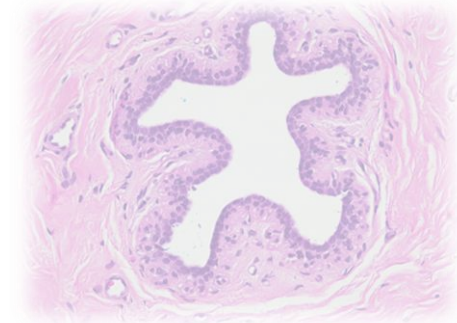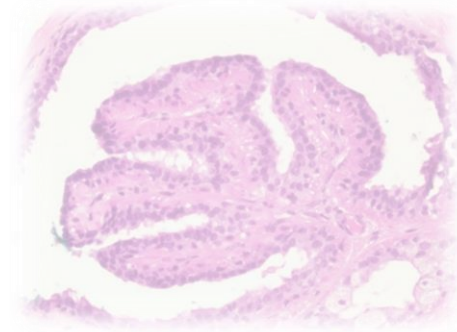
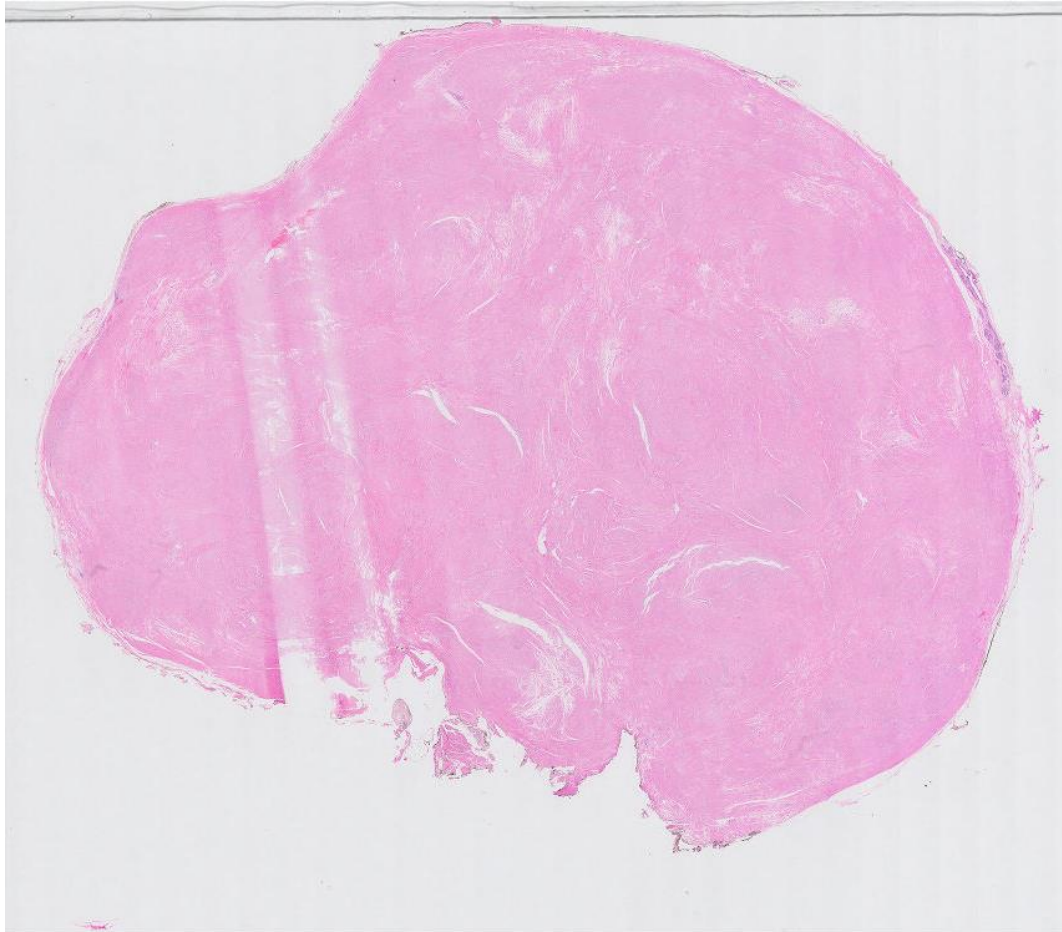


## Case 22

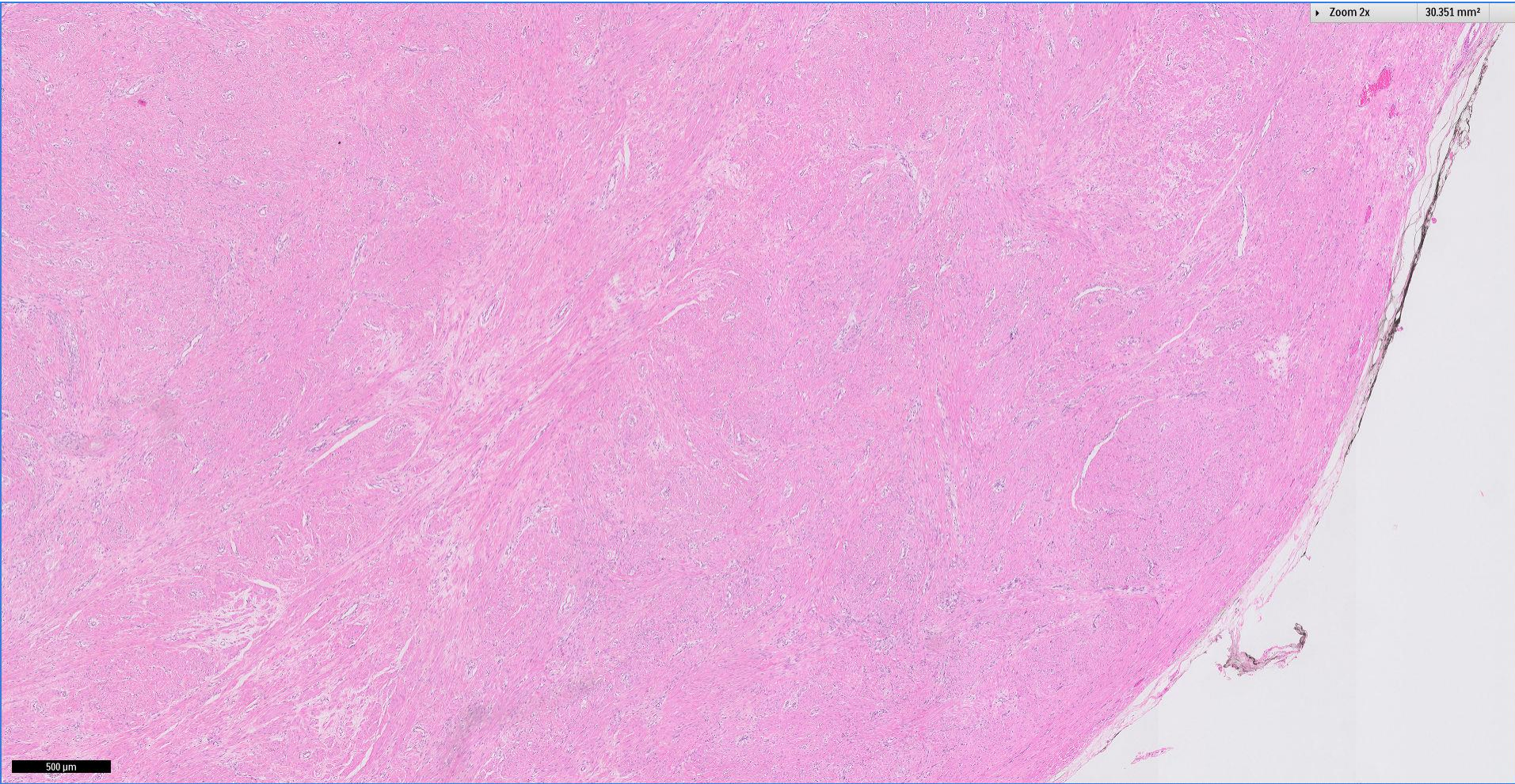
37 year old Chinese female.  
Left breast lump, excision biopsy.





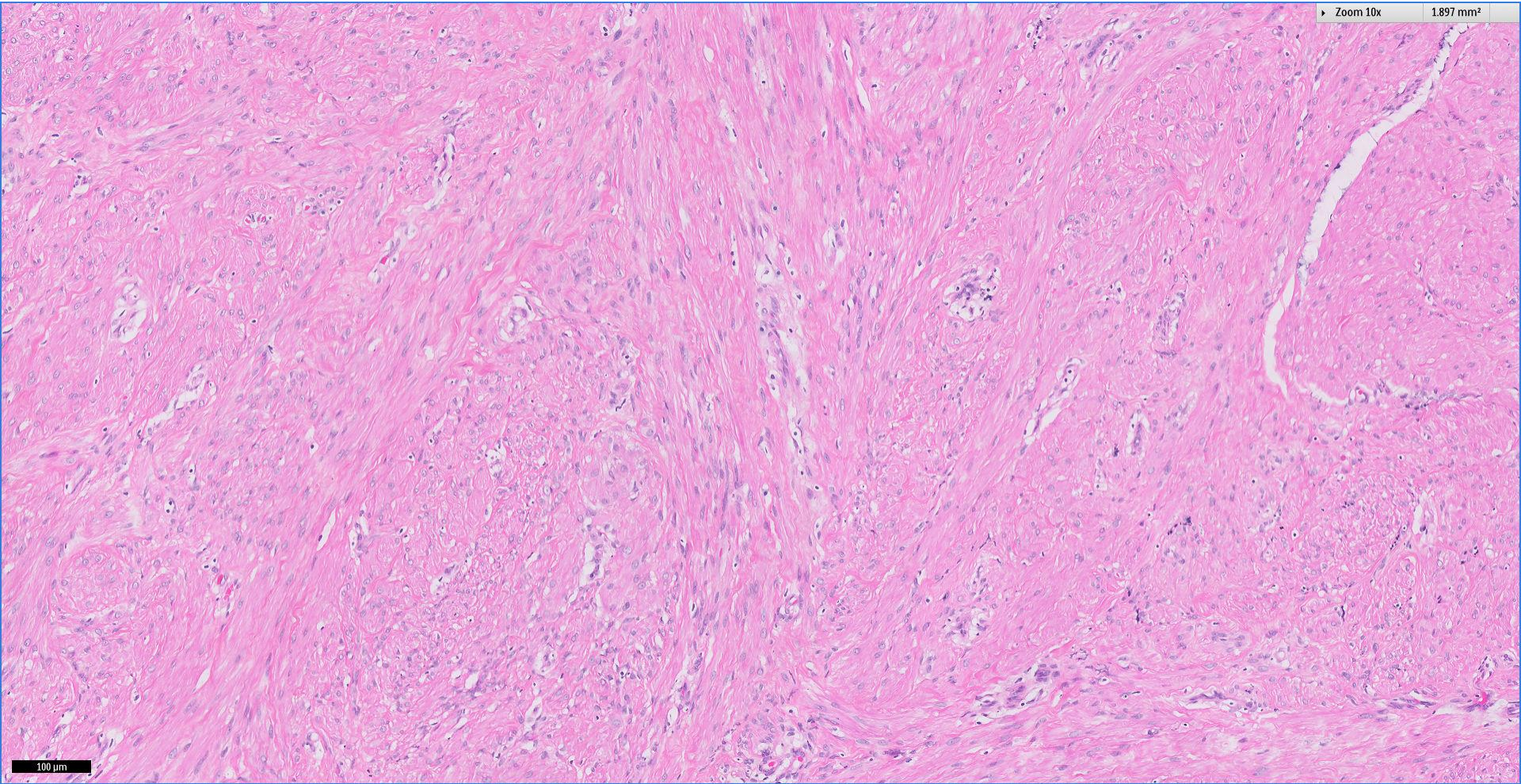
Zoom 2x

30.351 mm<sup>2</sup>



Division of Pathology  
Singapore General Hospital



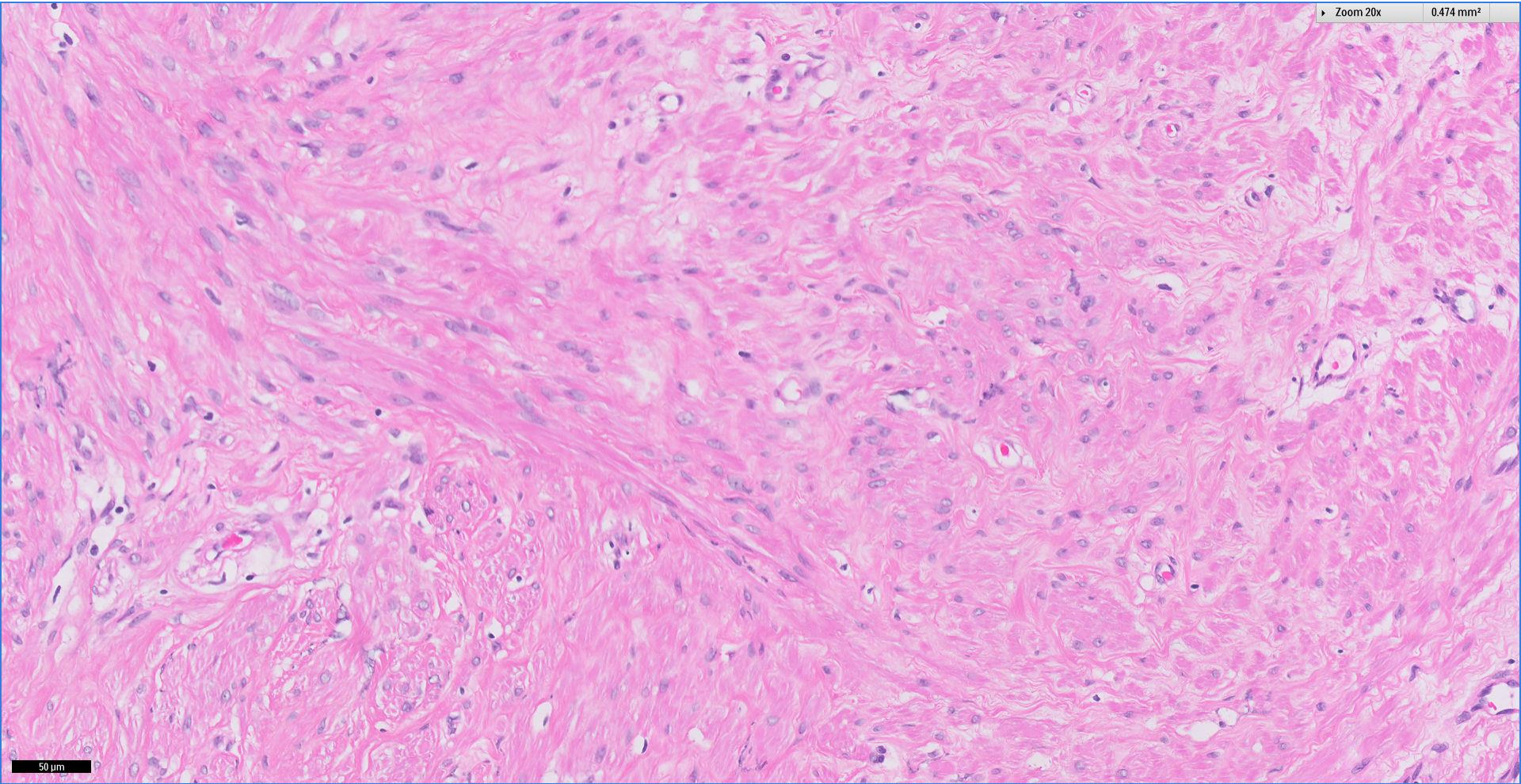


100 µm



Division of Pathology  
Singapore General Hospital



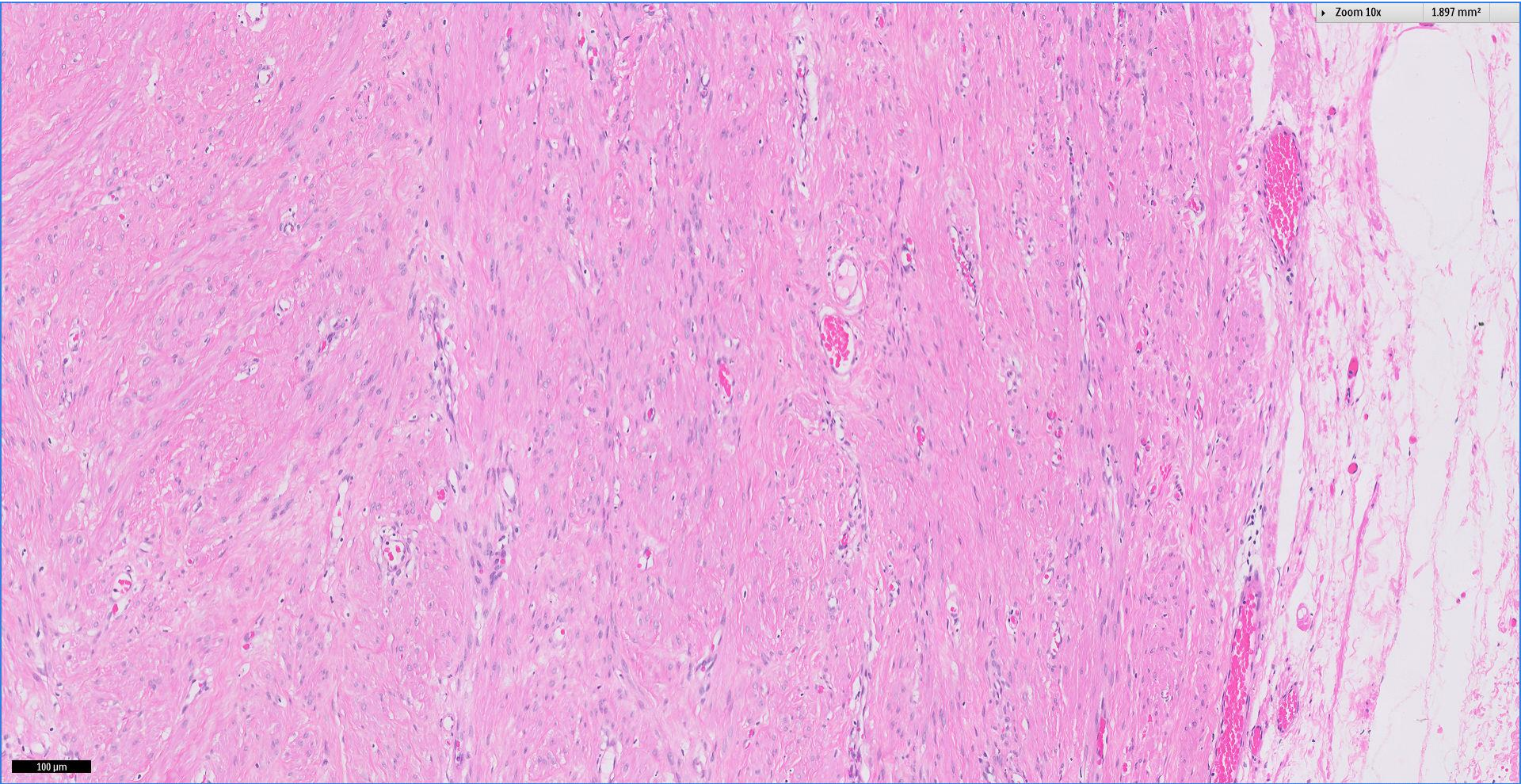


50 μm



**Division of Pathology**  
**Singapore General Hospital**





100 µm



**Division of Pathology**  
**Singapore General Hospital**



*Thank You*