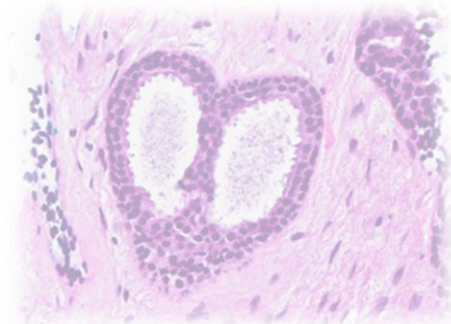
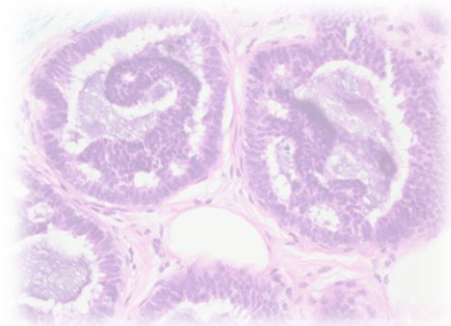
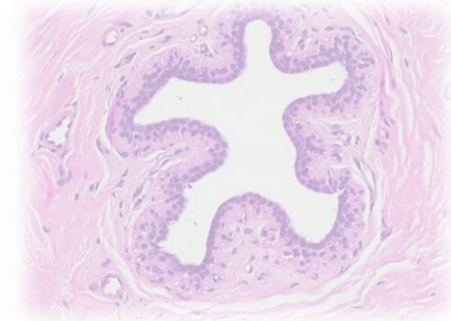
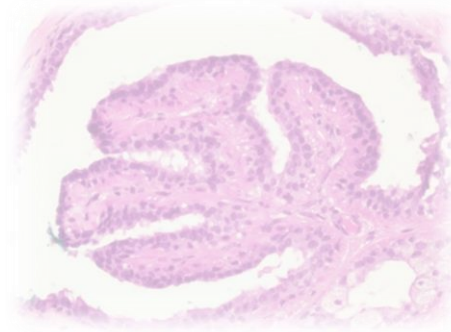
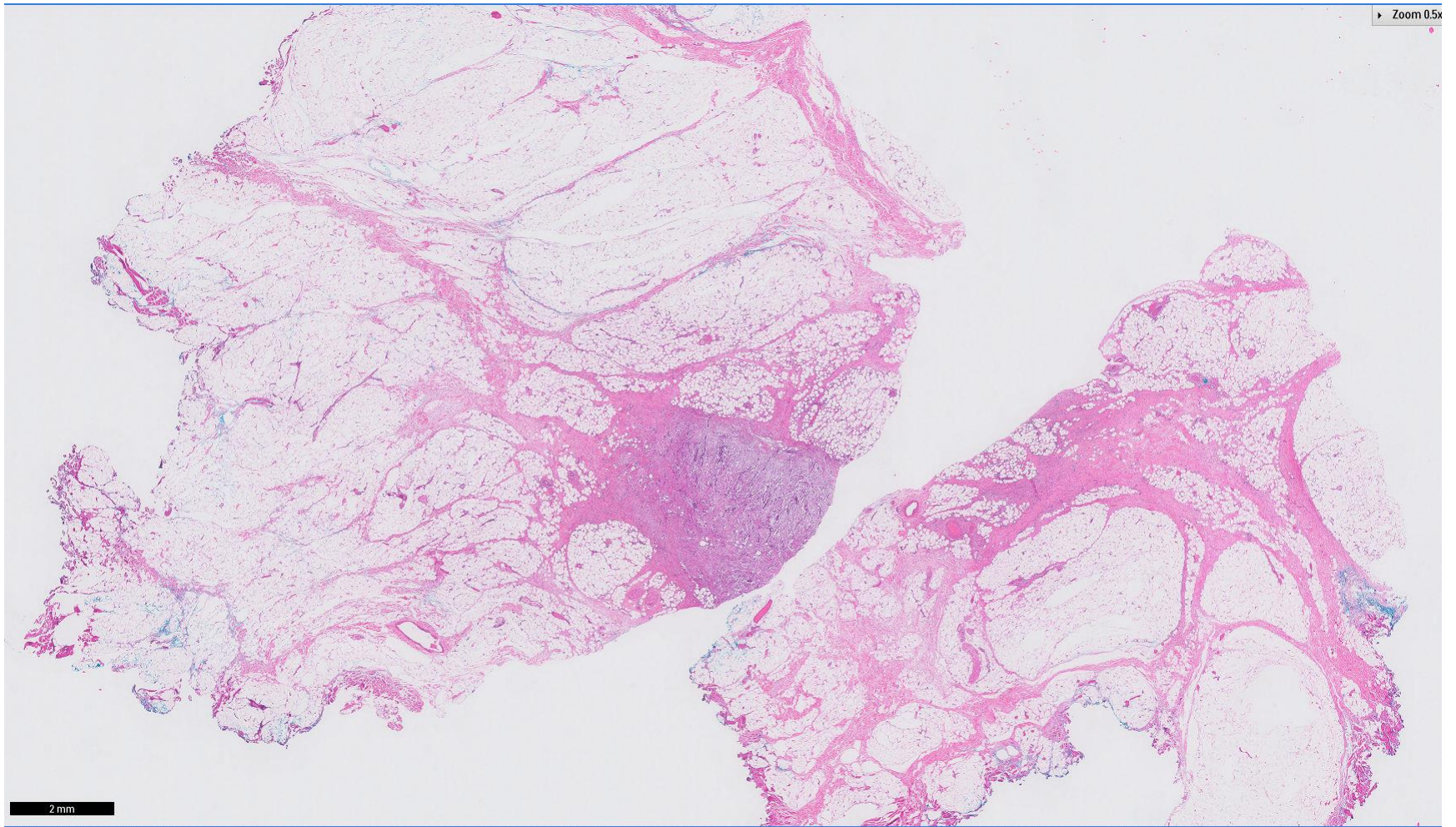
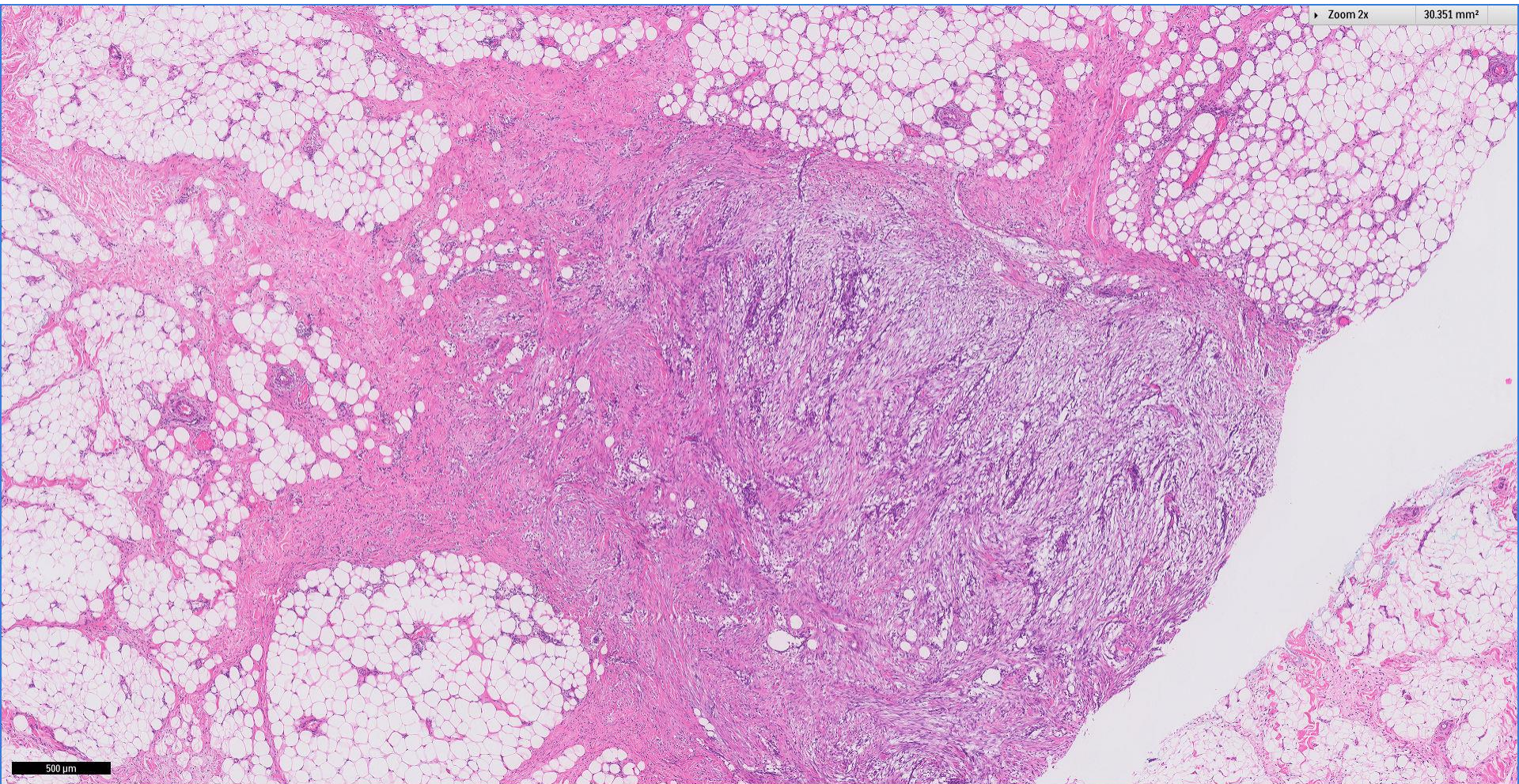


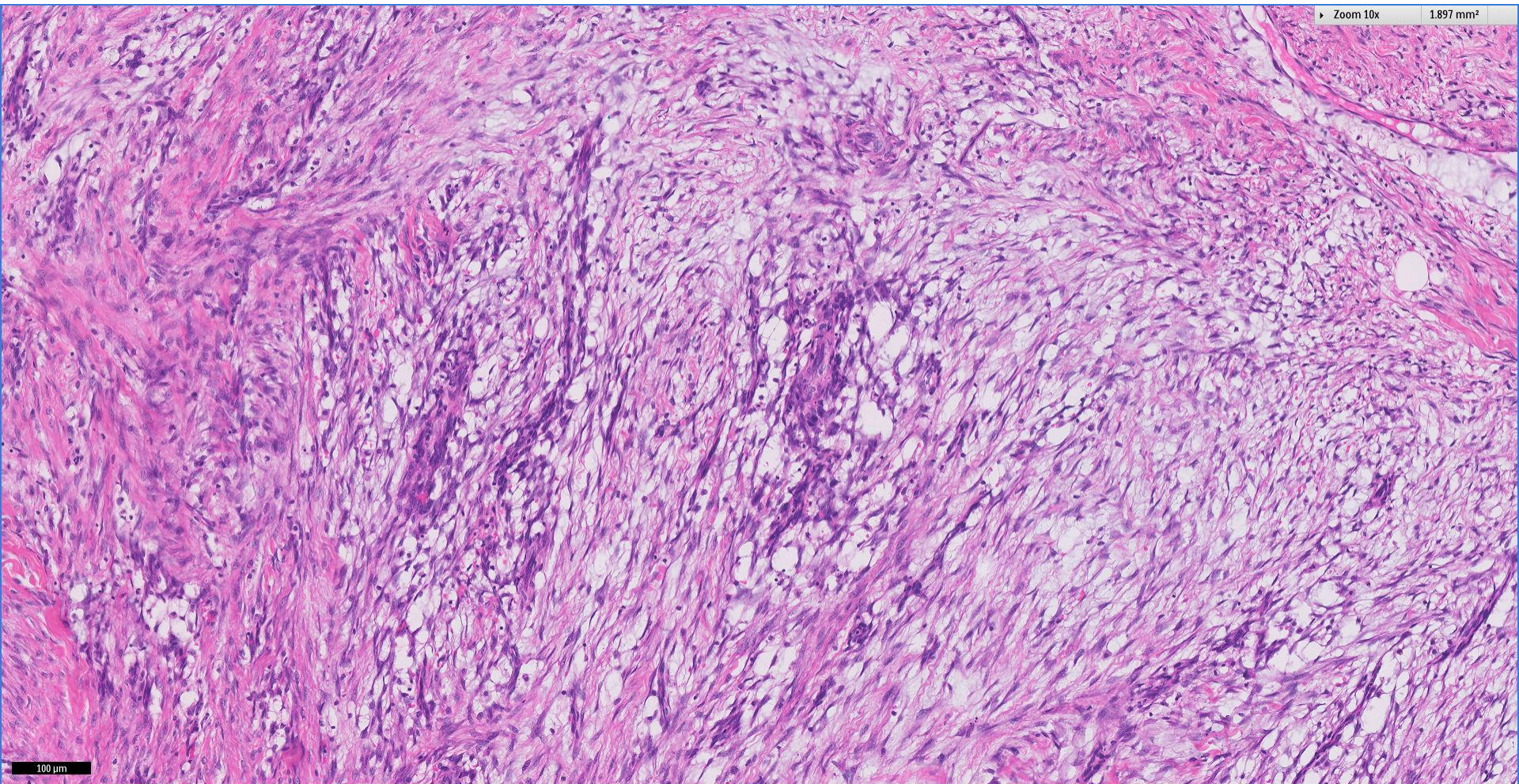
Case 21

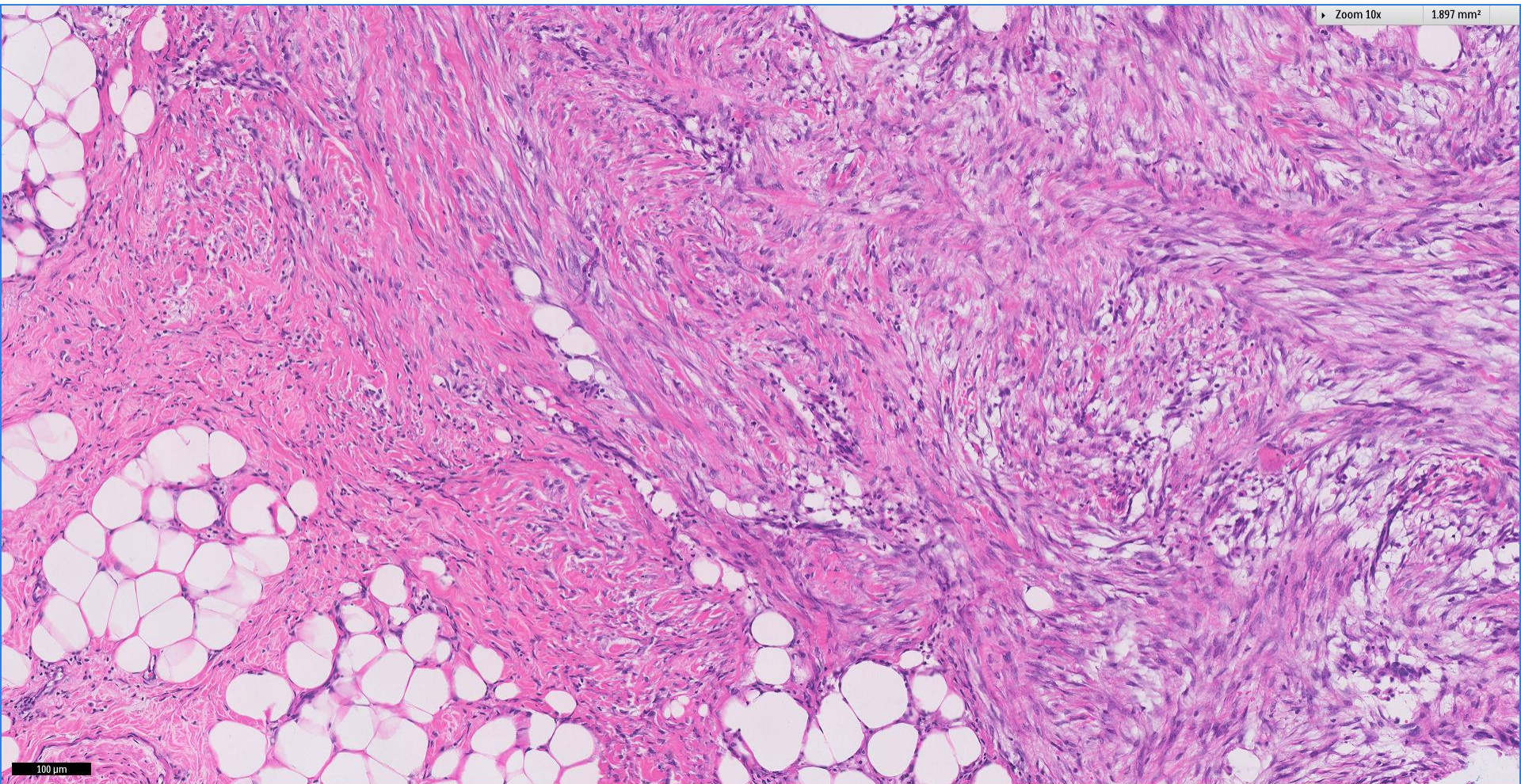
63 year old Indonesian female.
Right breast lump, excision biopsy.

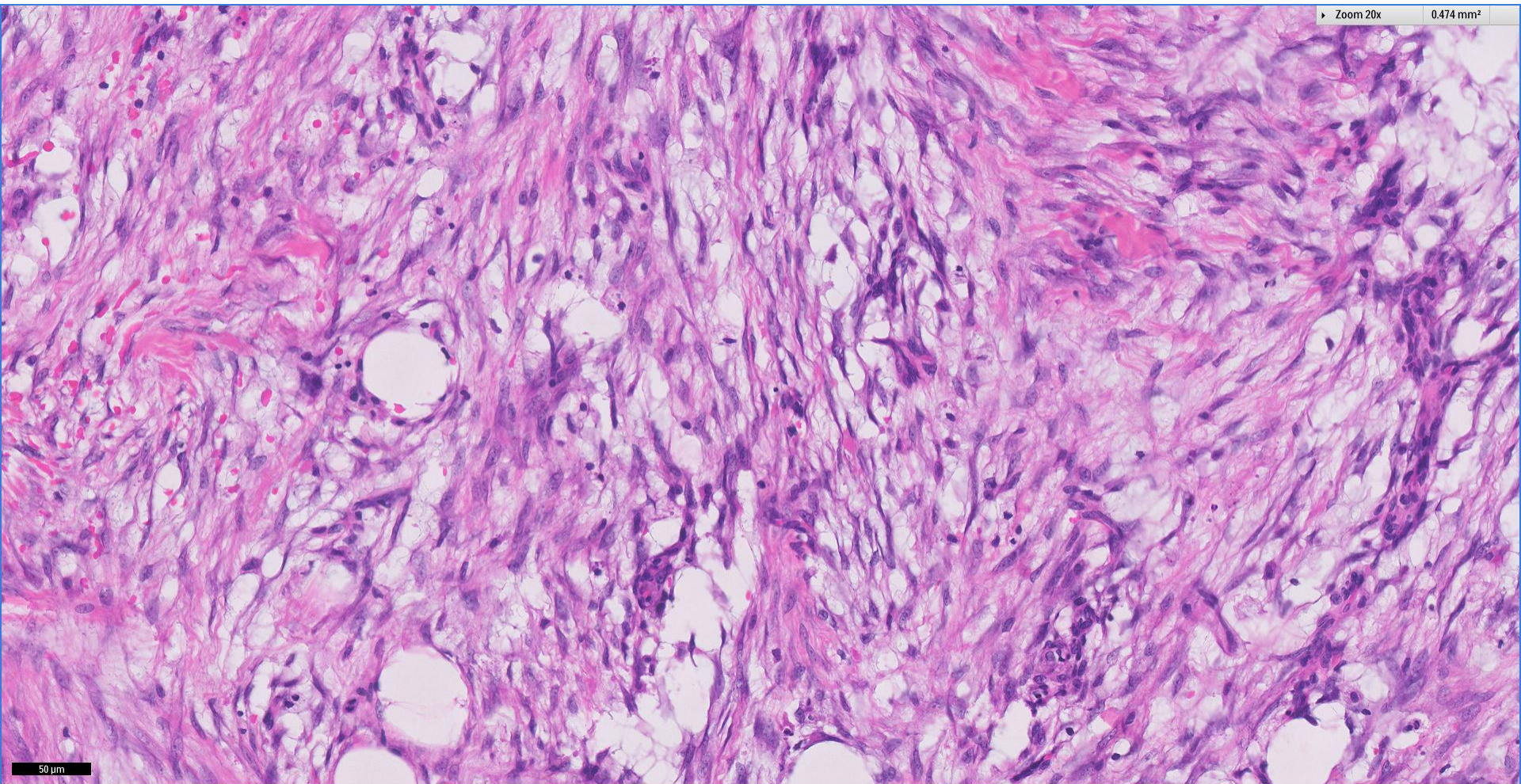












50 μm

Thank You