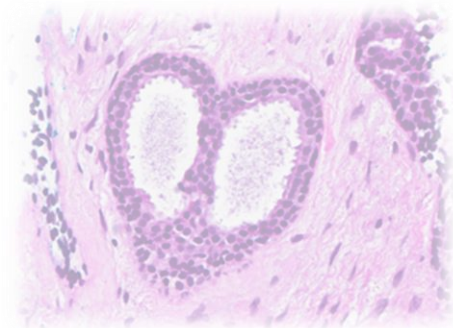
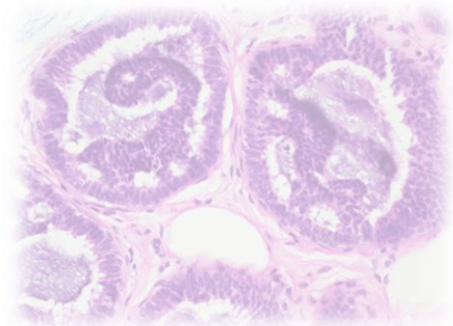
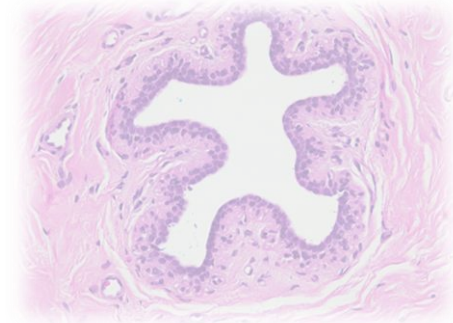
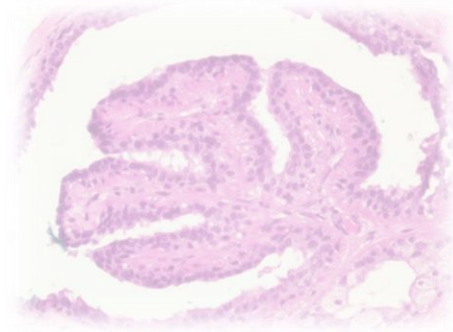
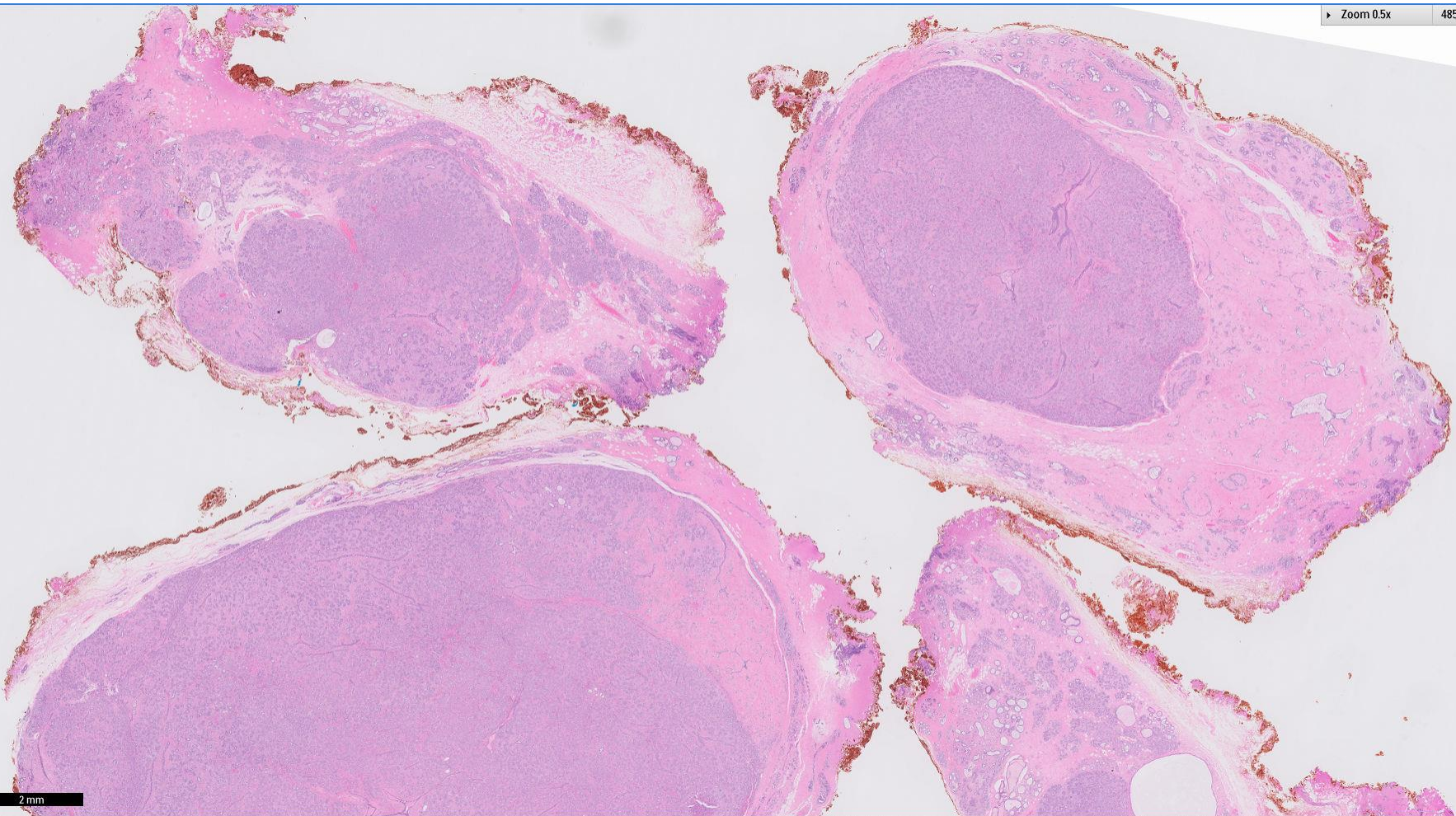


Case 20

29 year old Chinese female.
Right breast 10 o'clock lesion,
lumpectomy.



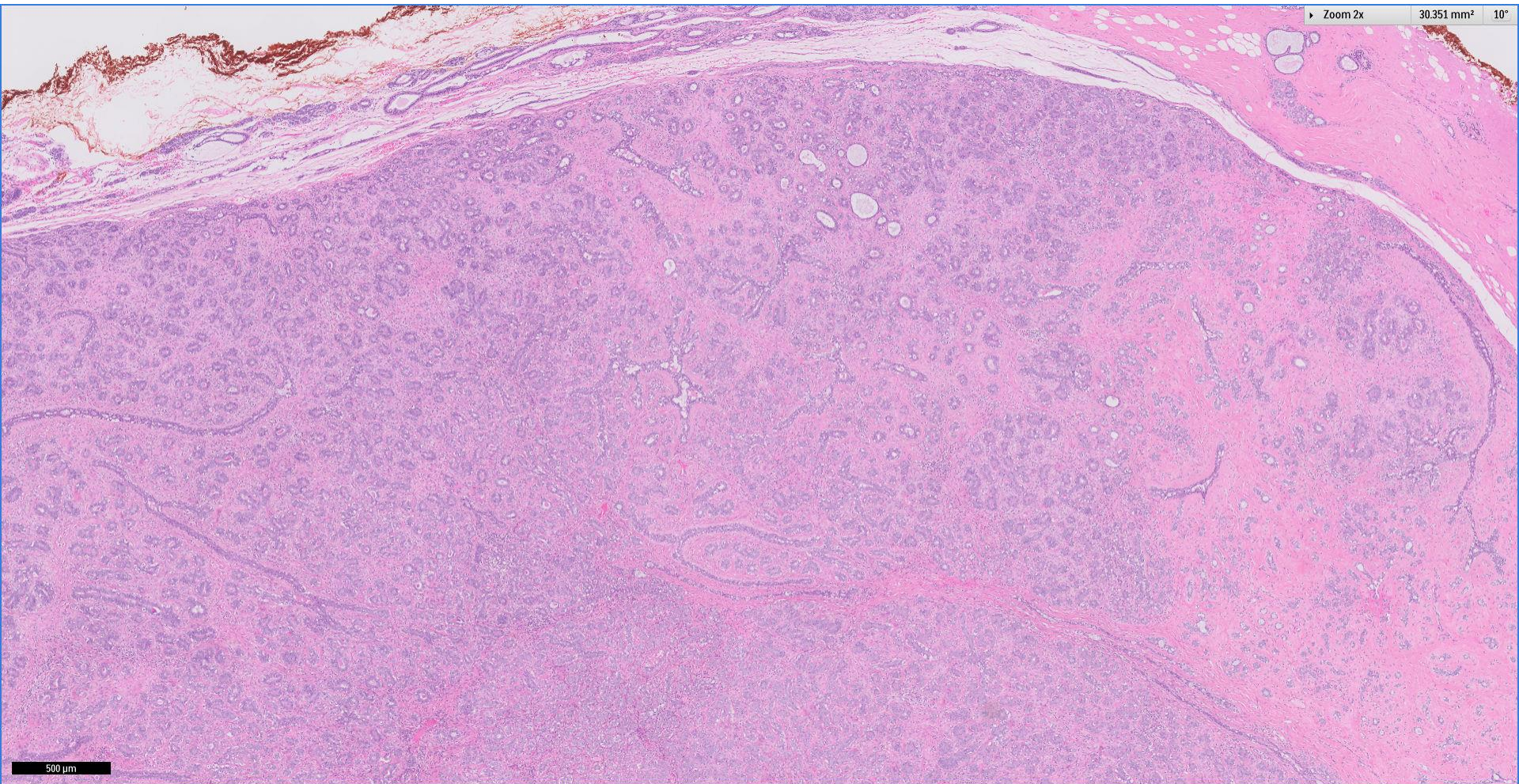


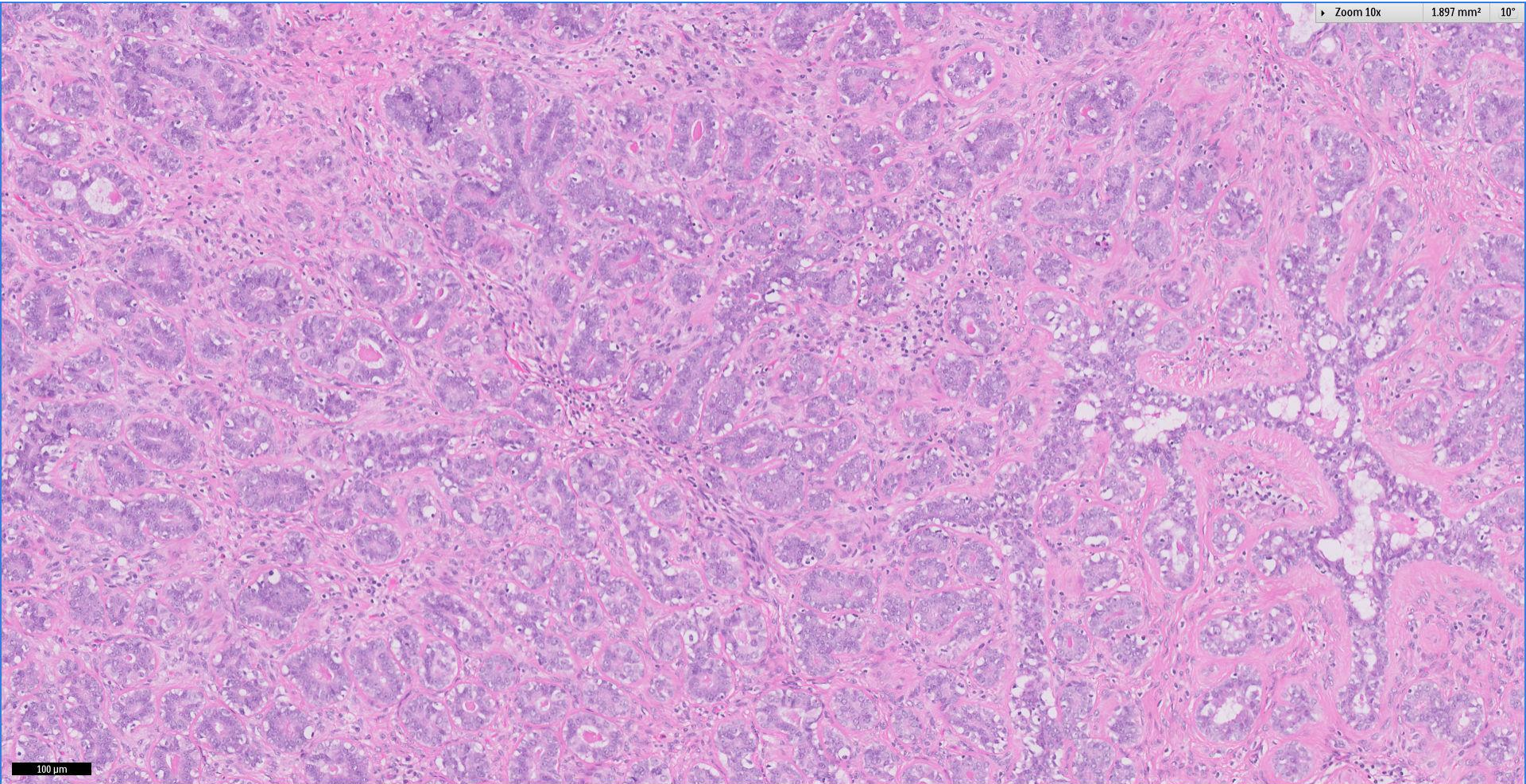
2 mm



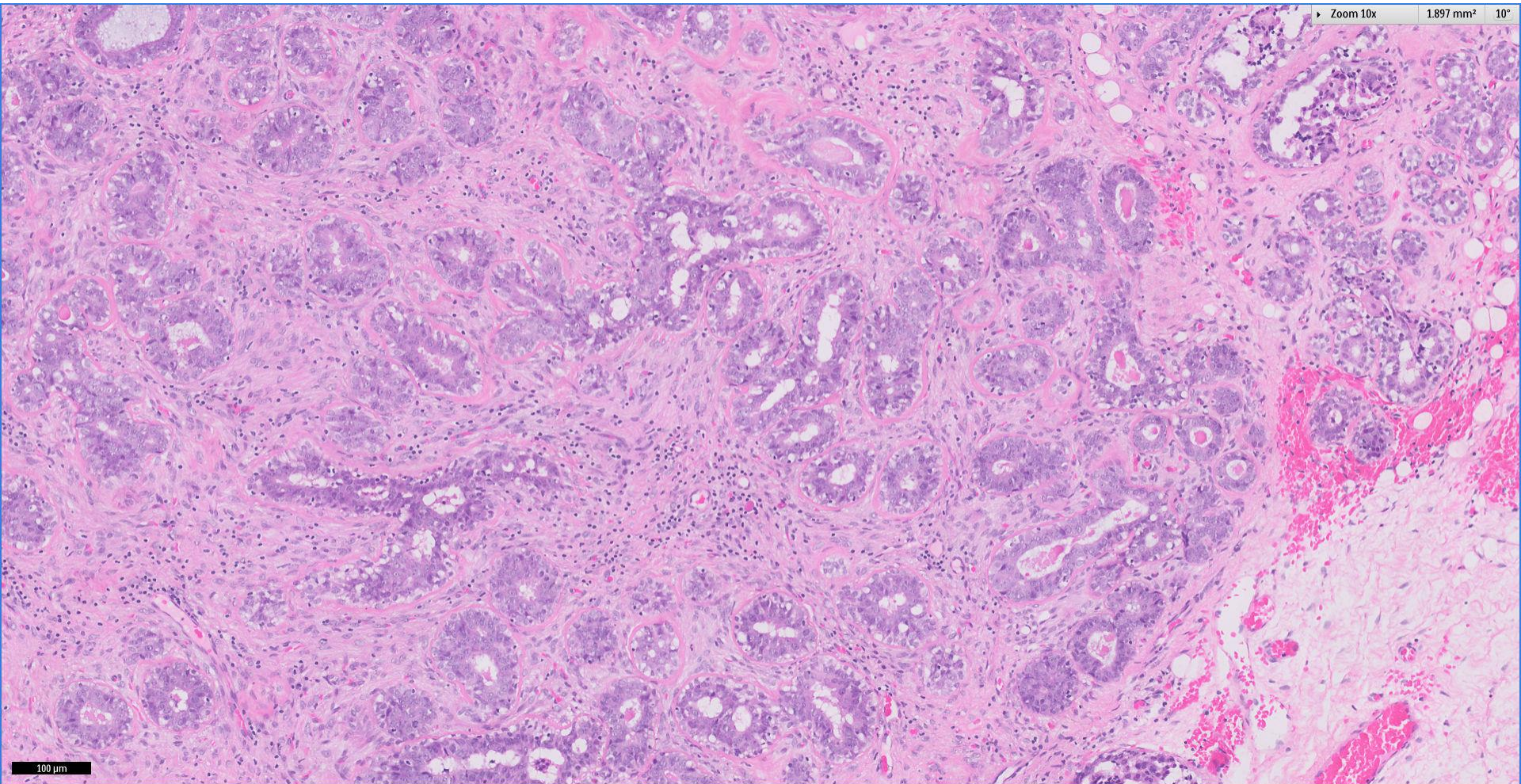
Division of Pathology
Singapore General Hospital





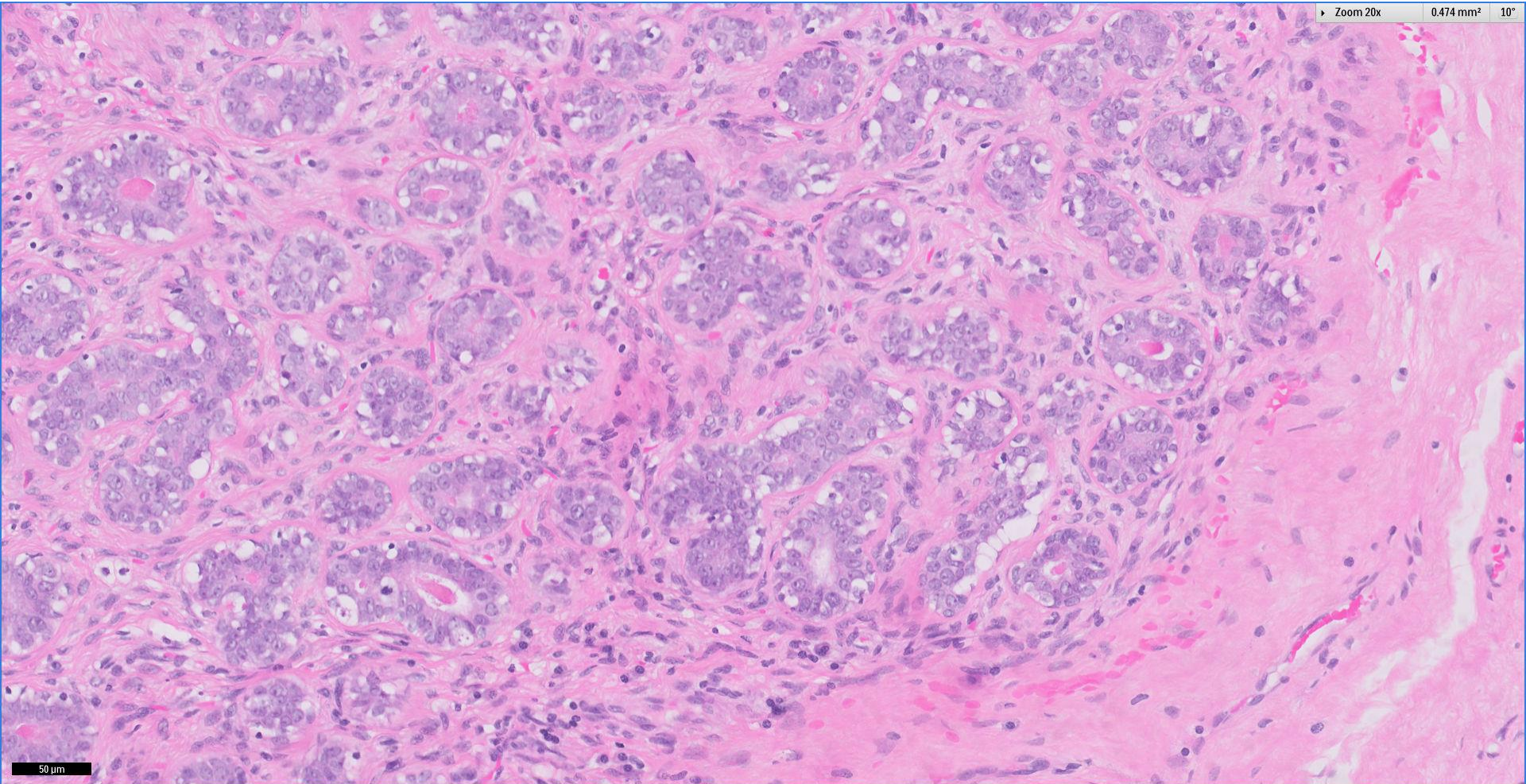


100 µm



Division of Pathology
Singapore General Hospital





50 μm

Thank You