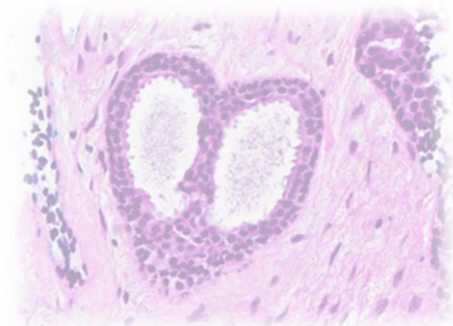
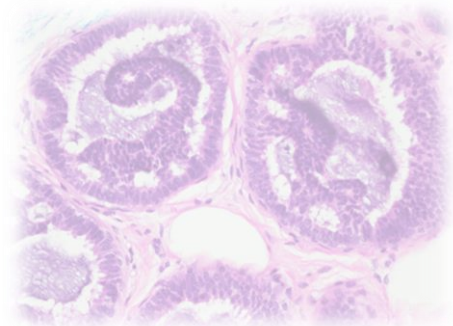
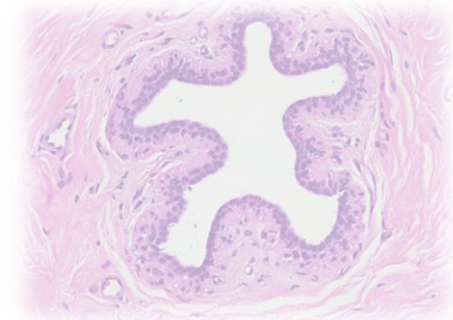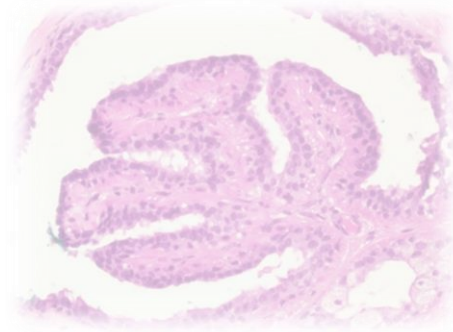
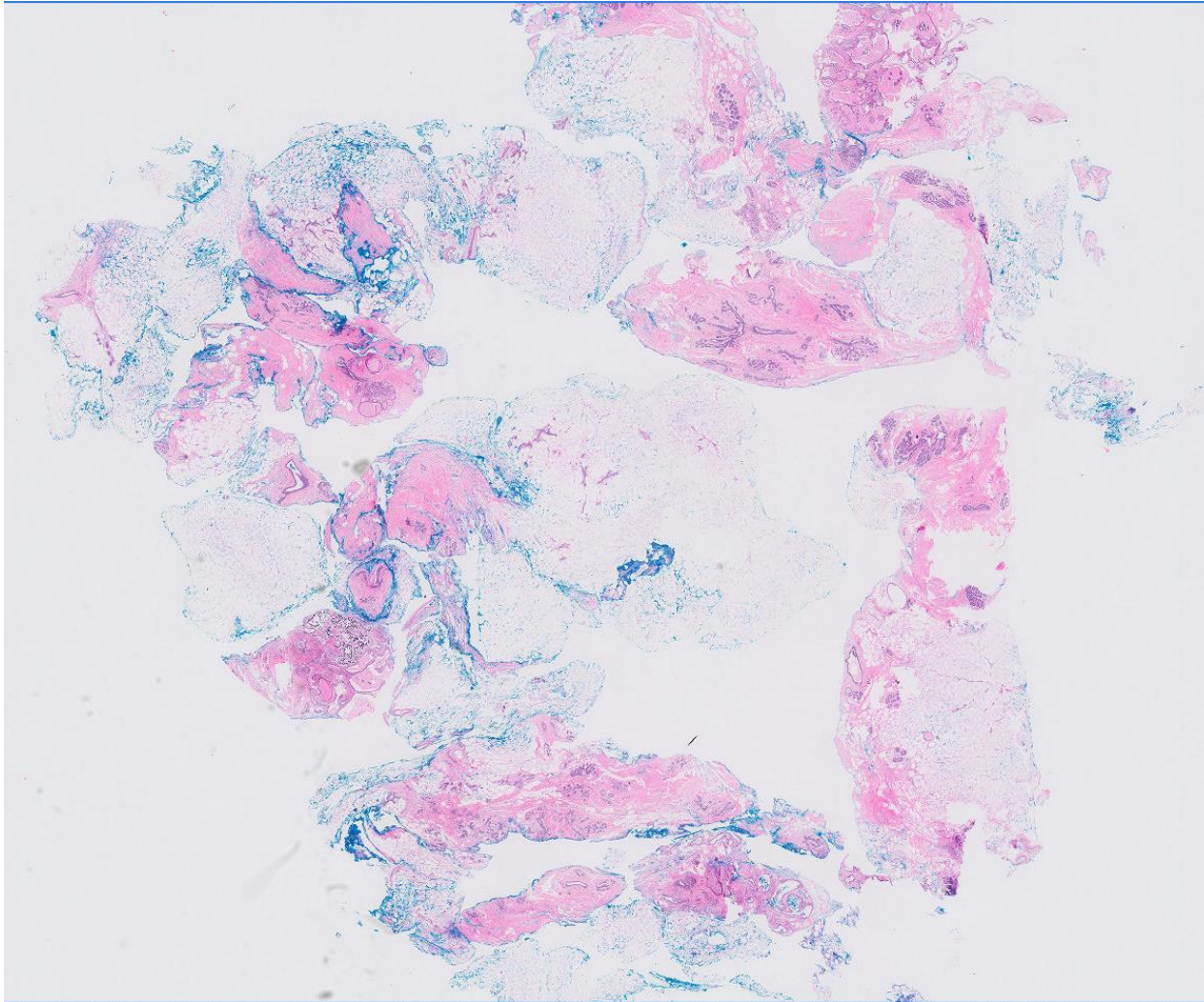


Case 19

44 year old Chinese female.

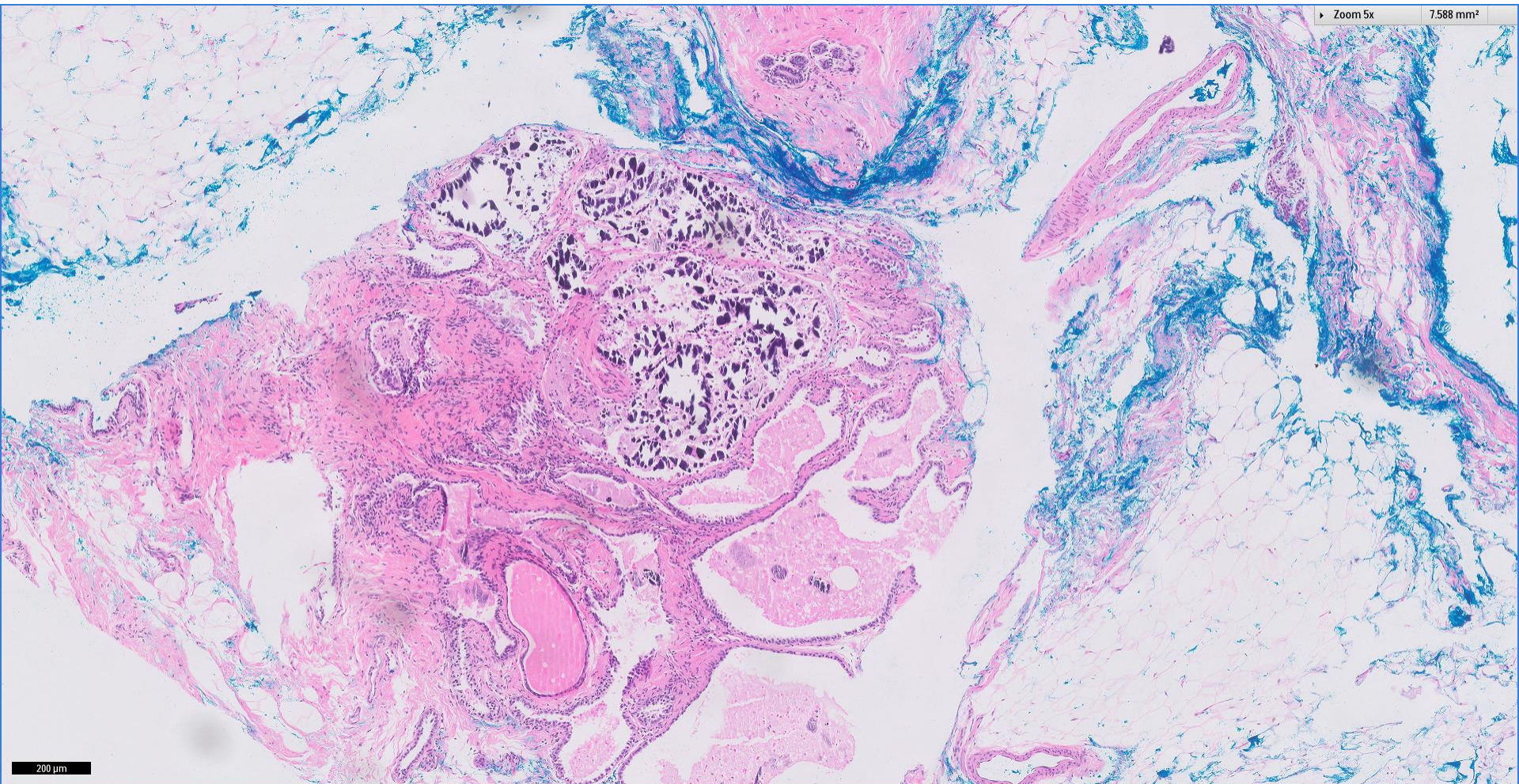
Stereotactic VAB for right breast UOQ
calcifications.

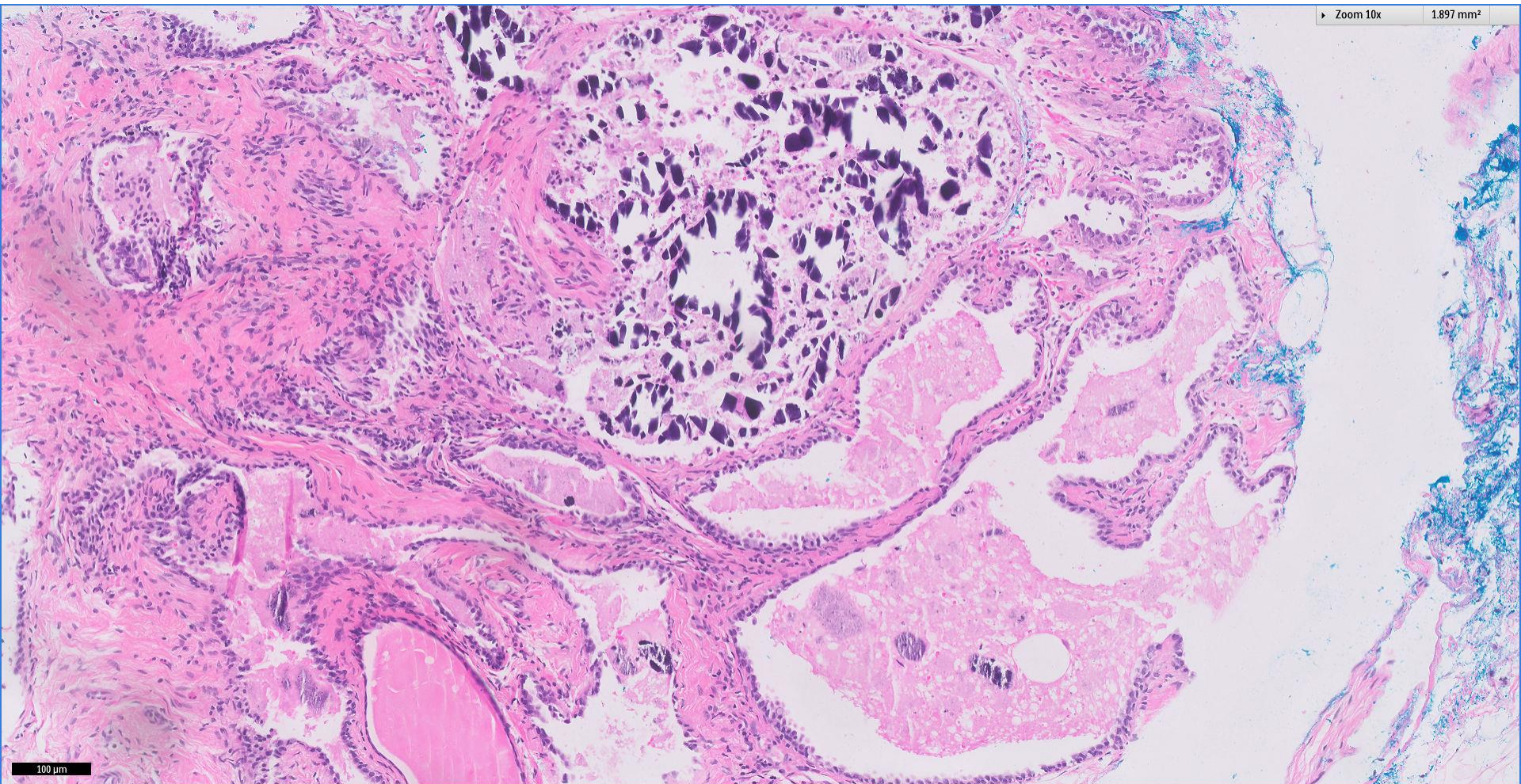


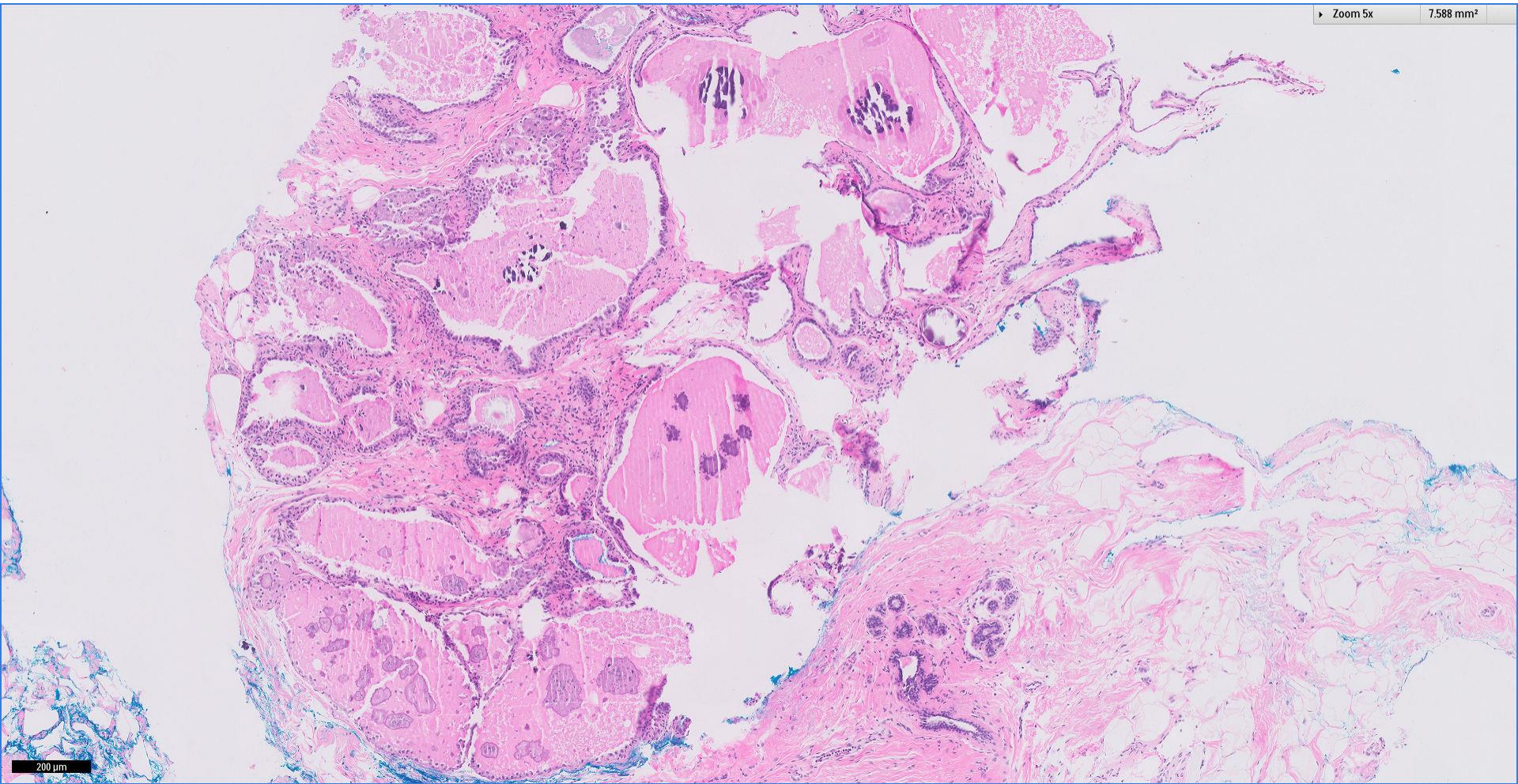


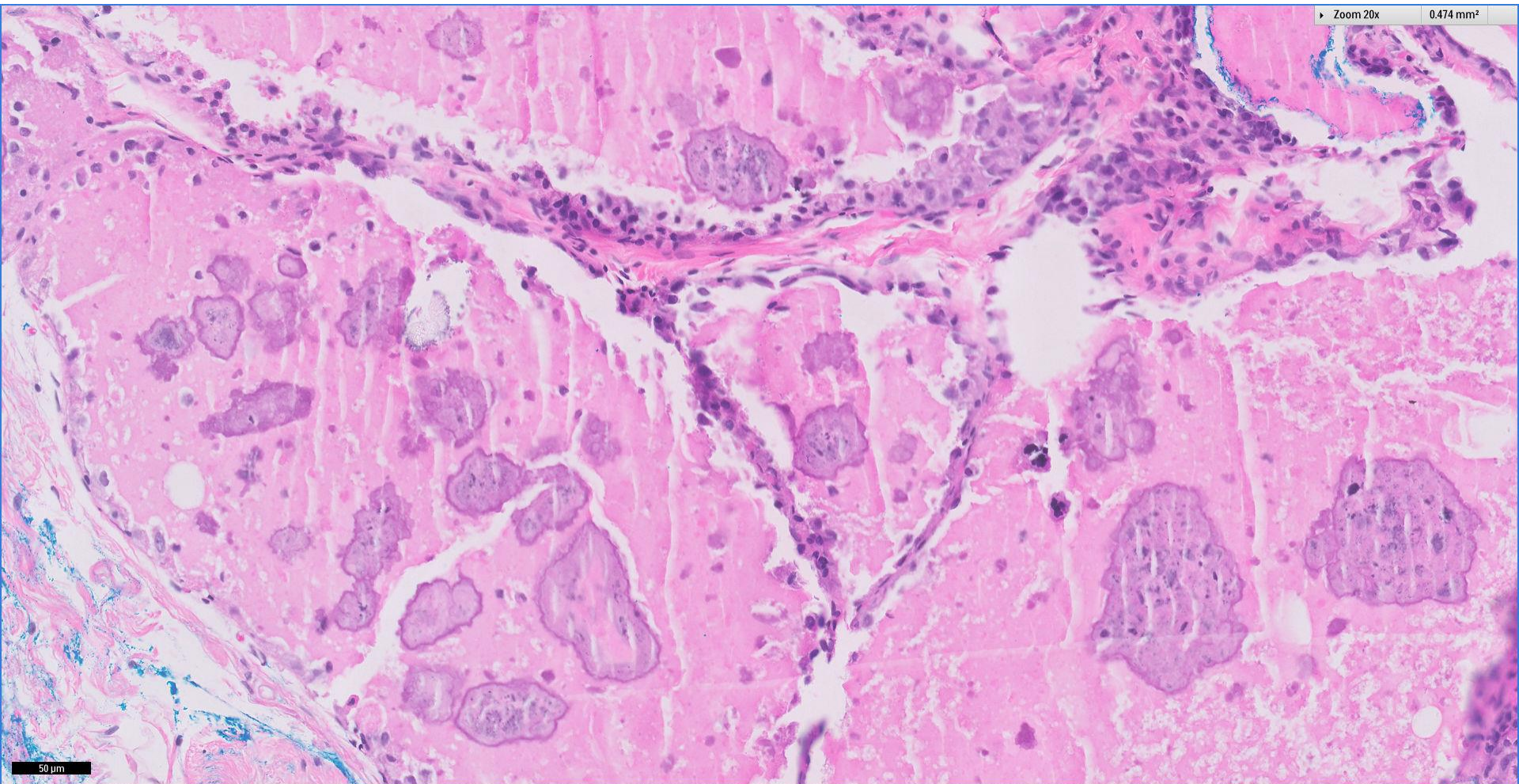
Division of Pathology
Singapore General Hospital











Division of Pathology
Singapore General Hospital



Thank You