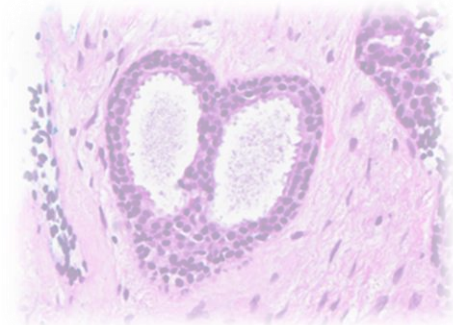
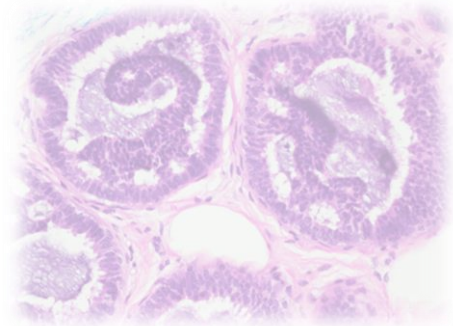
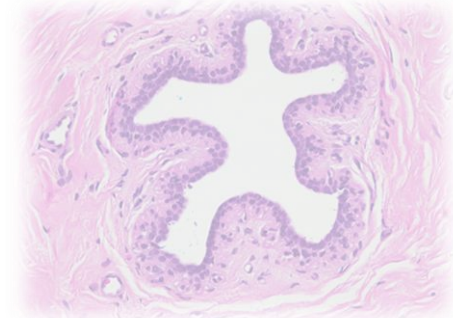
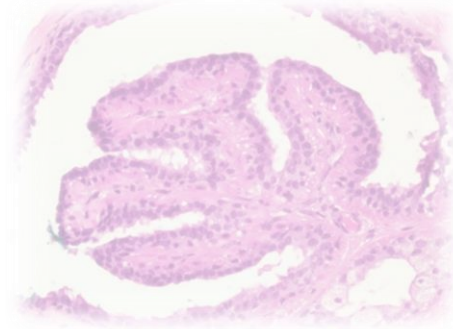
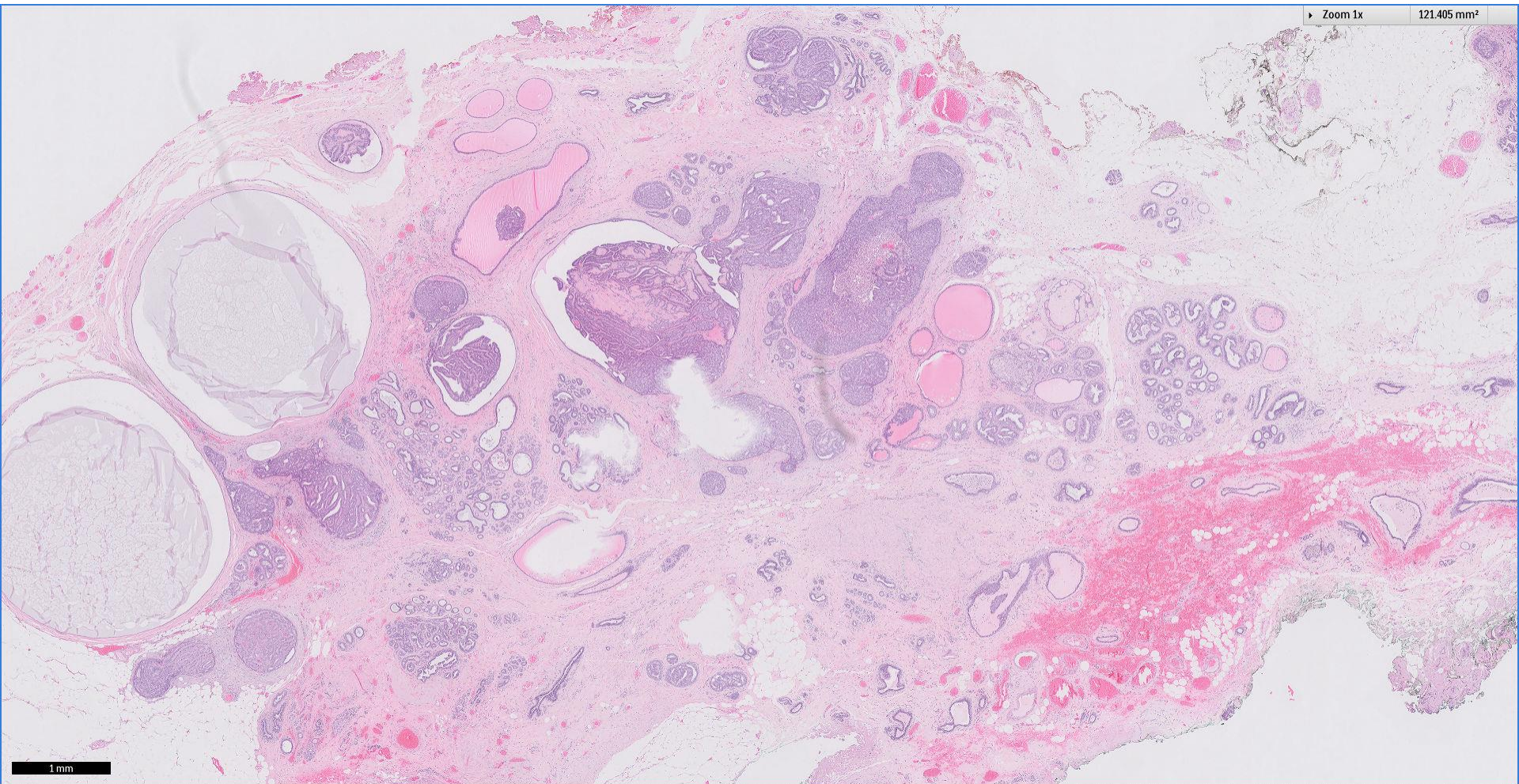
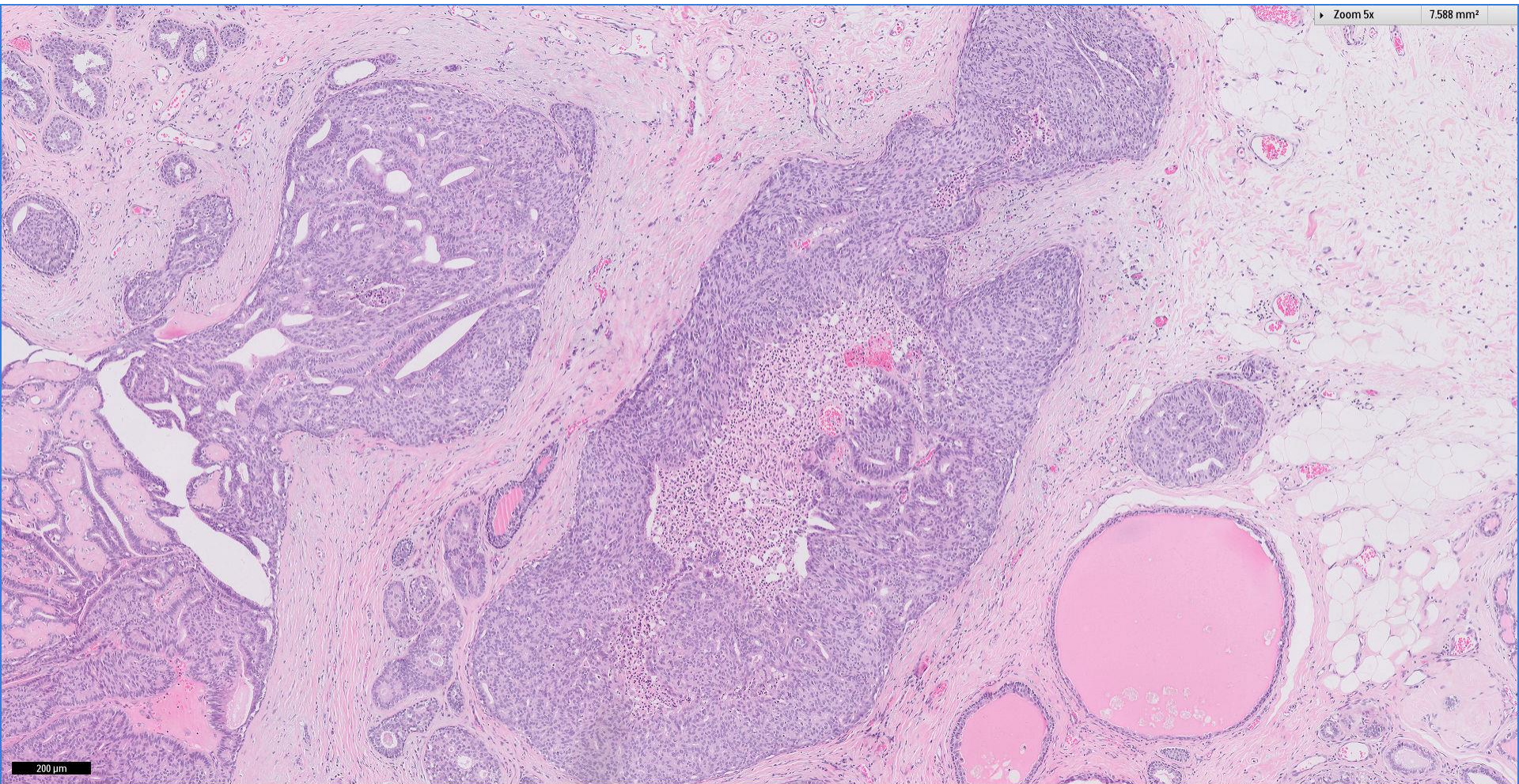


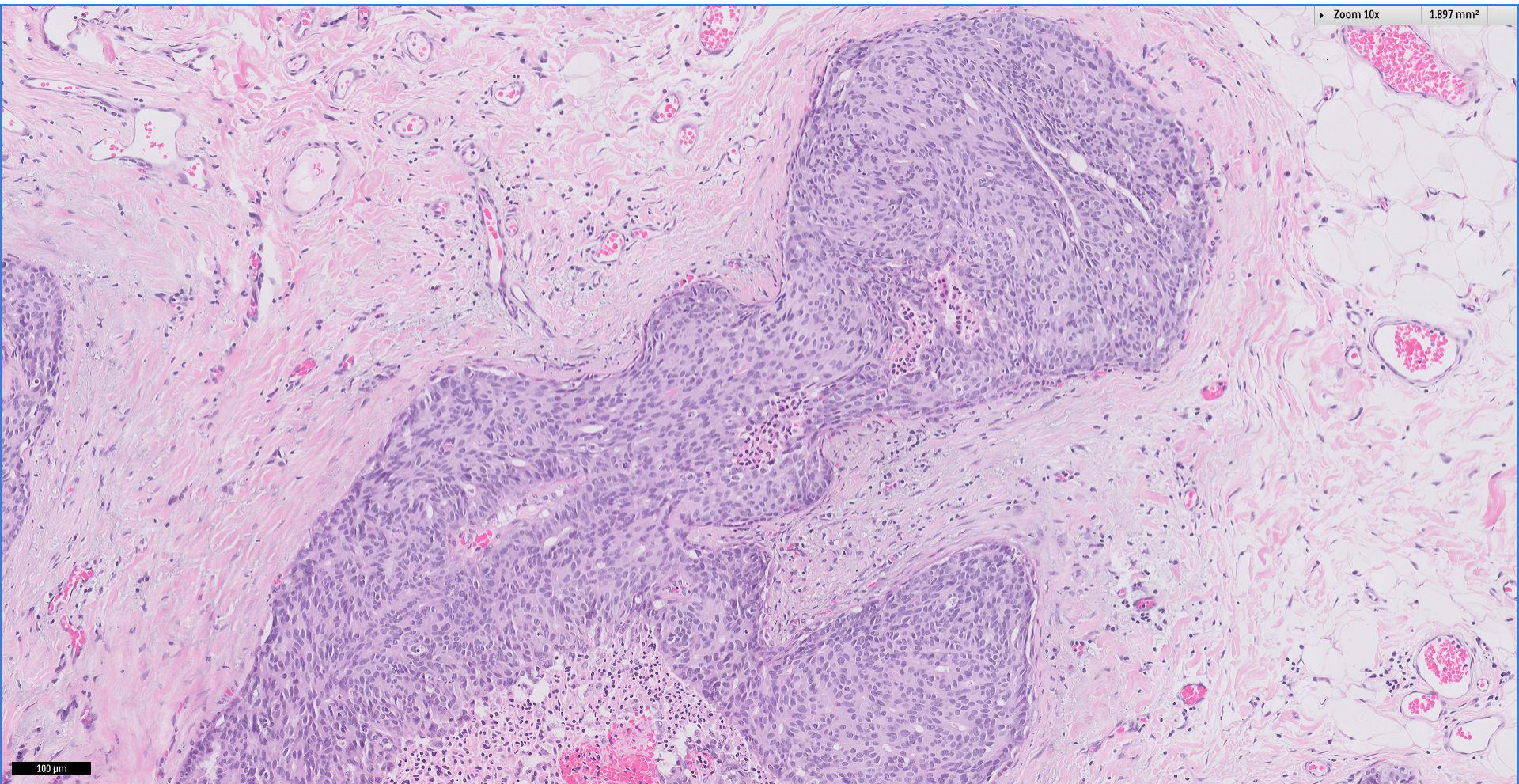
Case 16

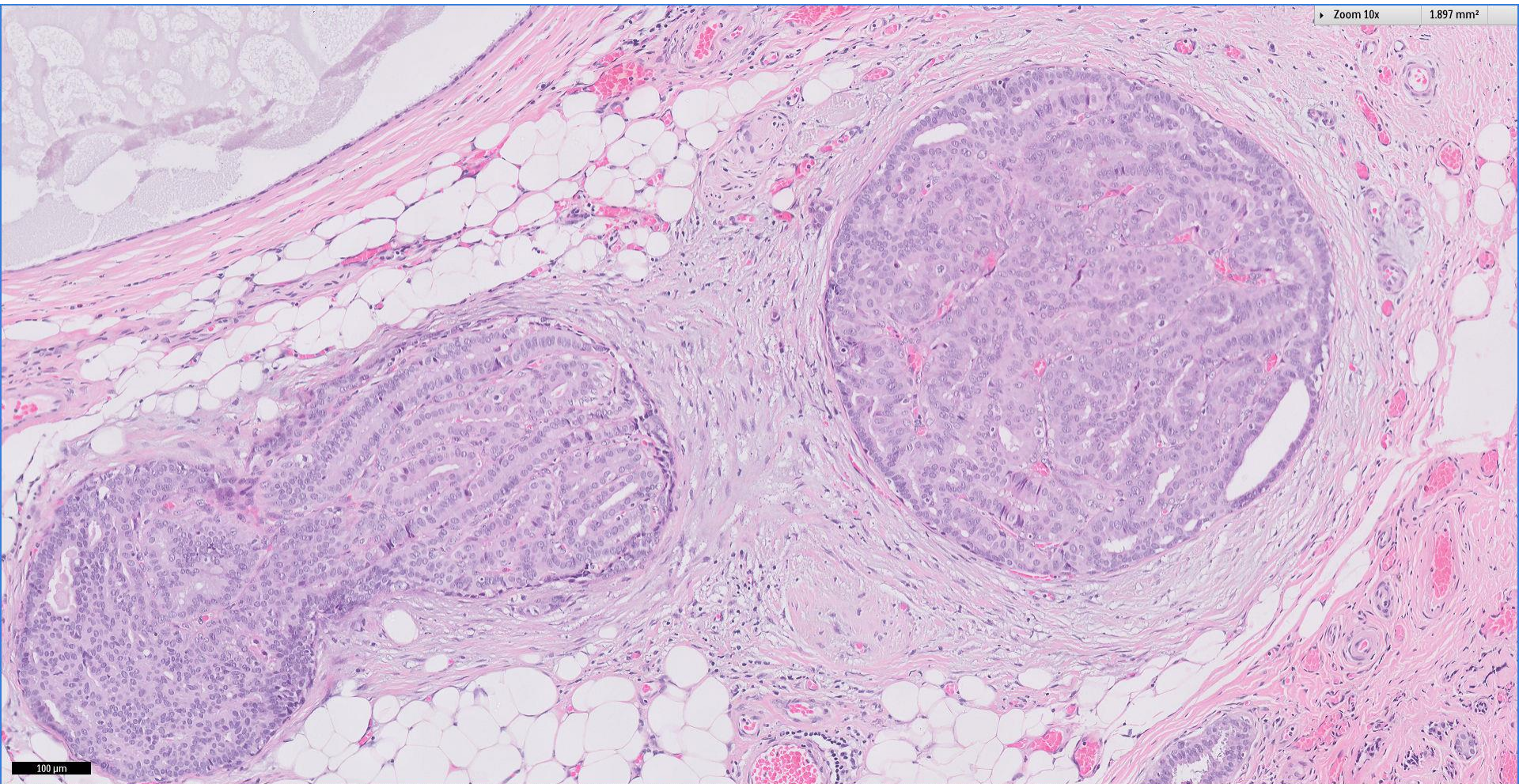
78 year old Chinese female.
Left breast lump, excision biopsy.





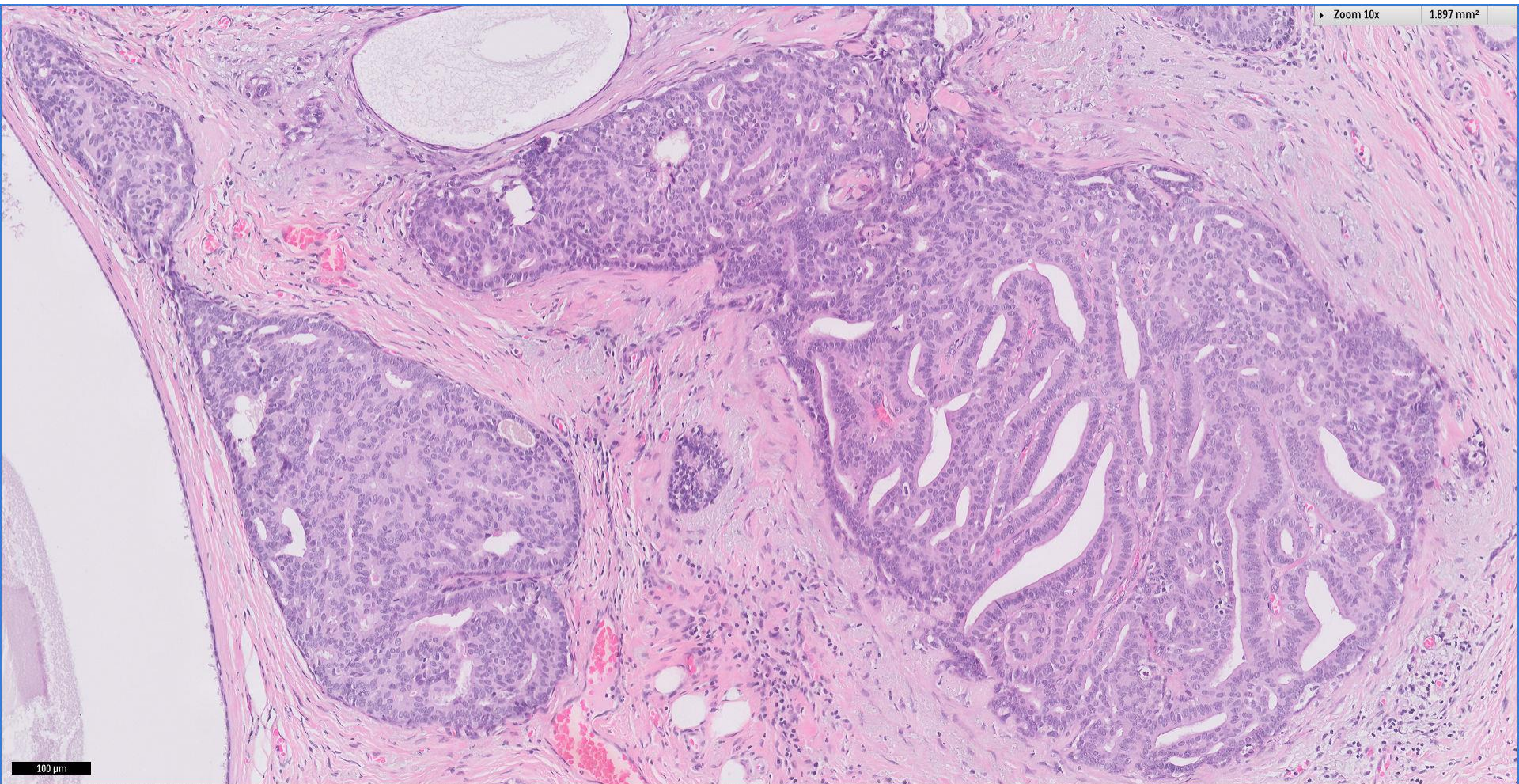






Division of Pathology
Singapore General Hospital





Division of Pathology
Singapore General Hospital



Thank You