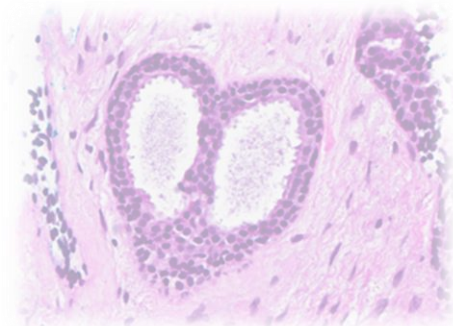
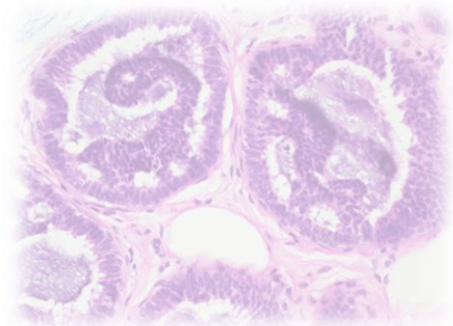
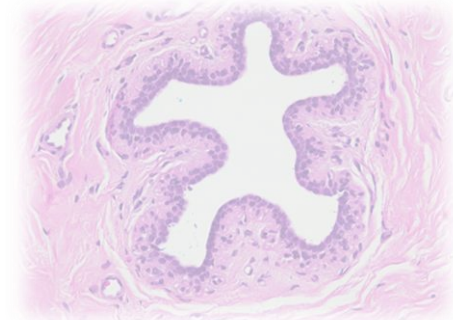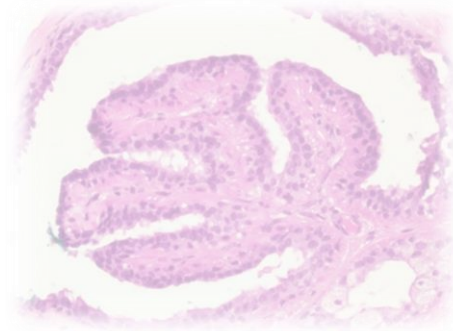
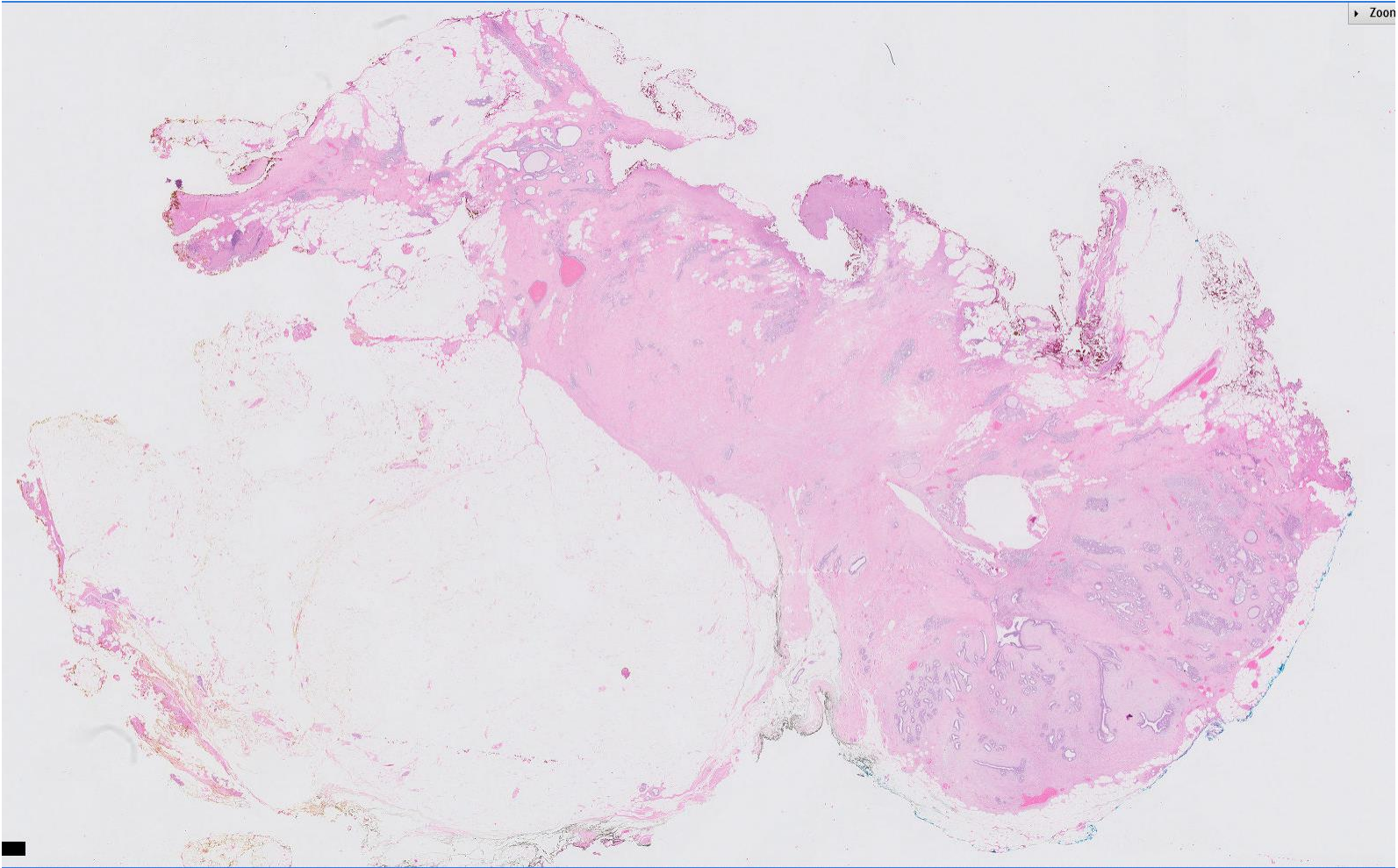
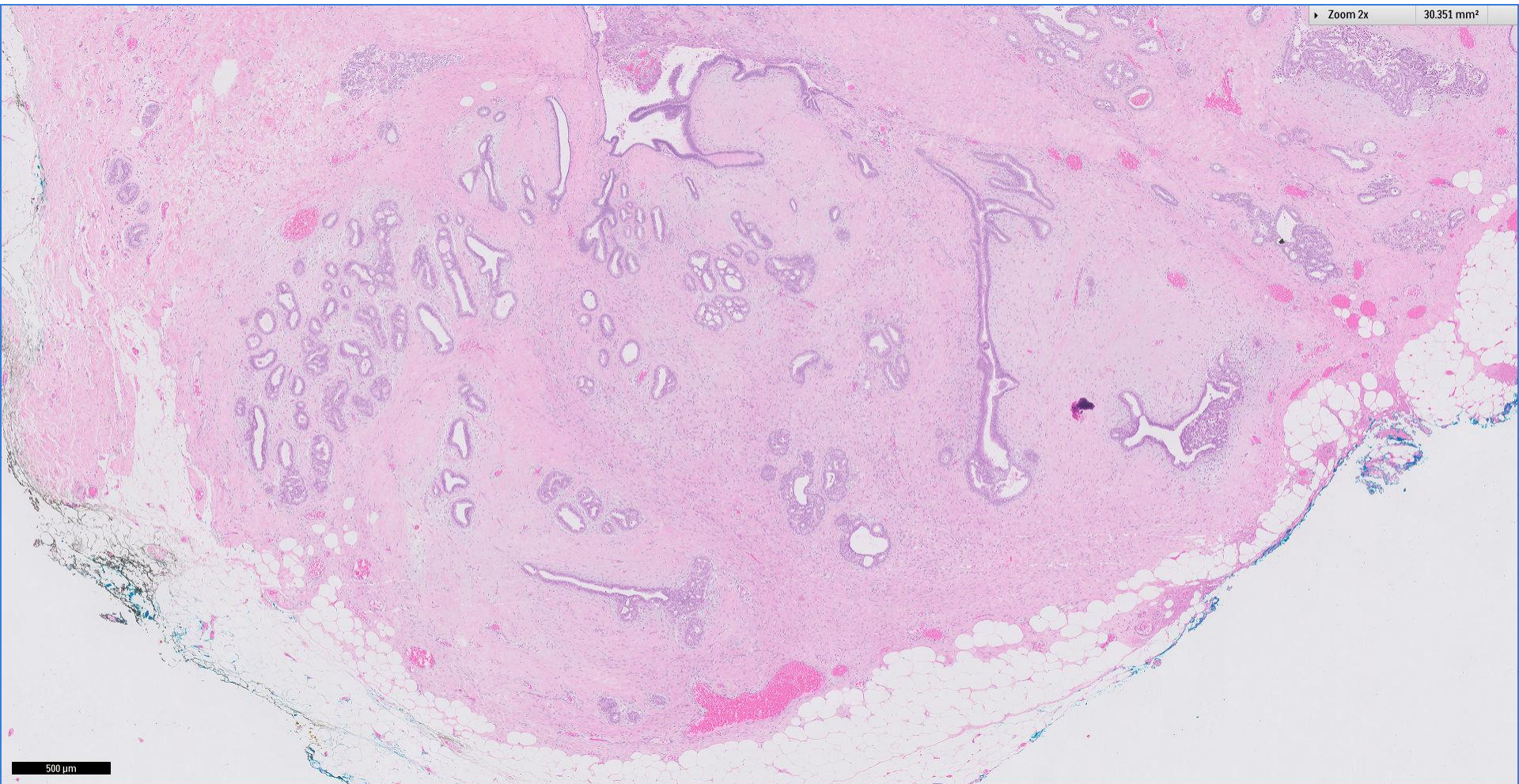


Case 15

53 year old Chinese female.
Right breast 12 o'clock nodule,
hookwire localisation excision biopsy.

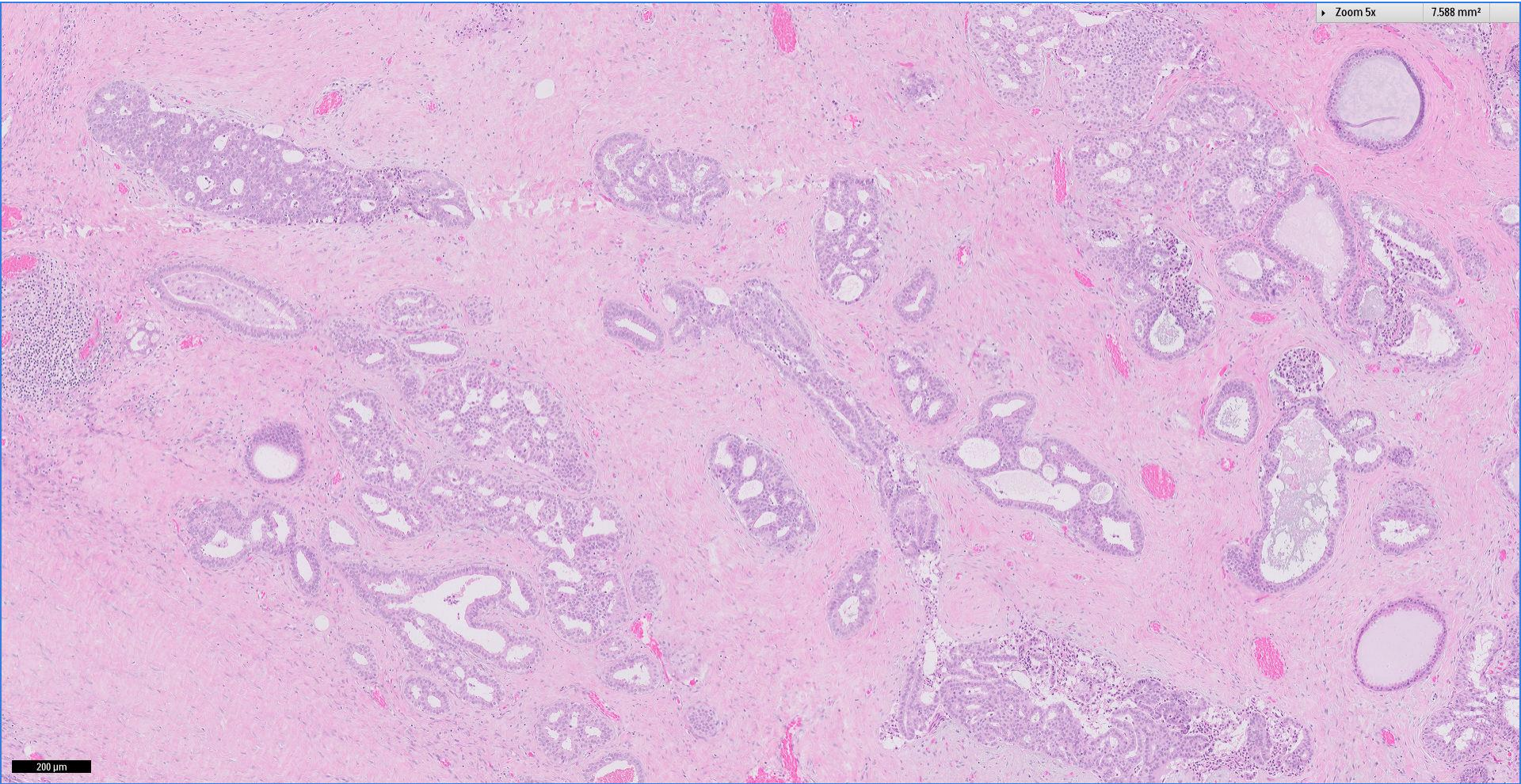


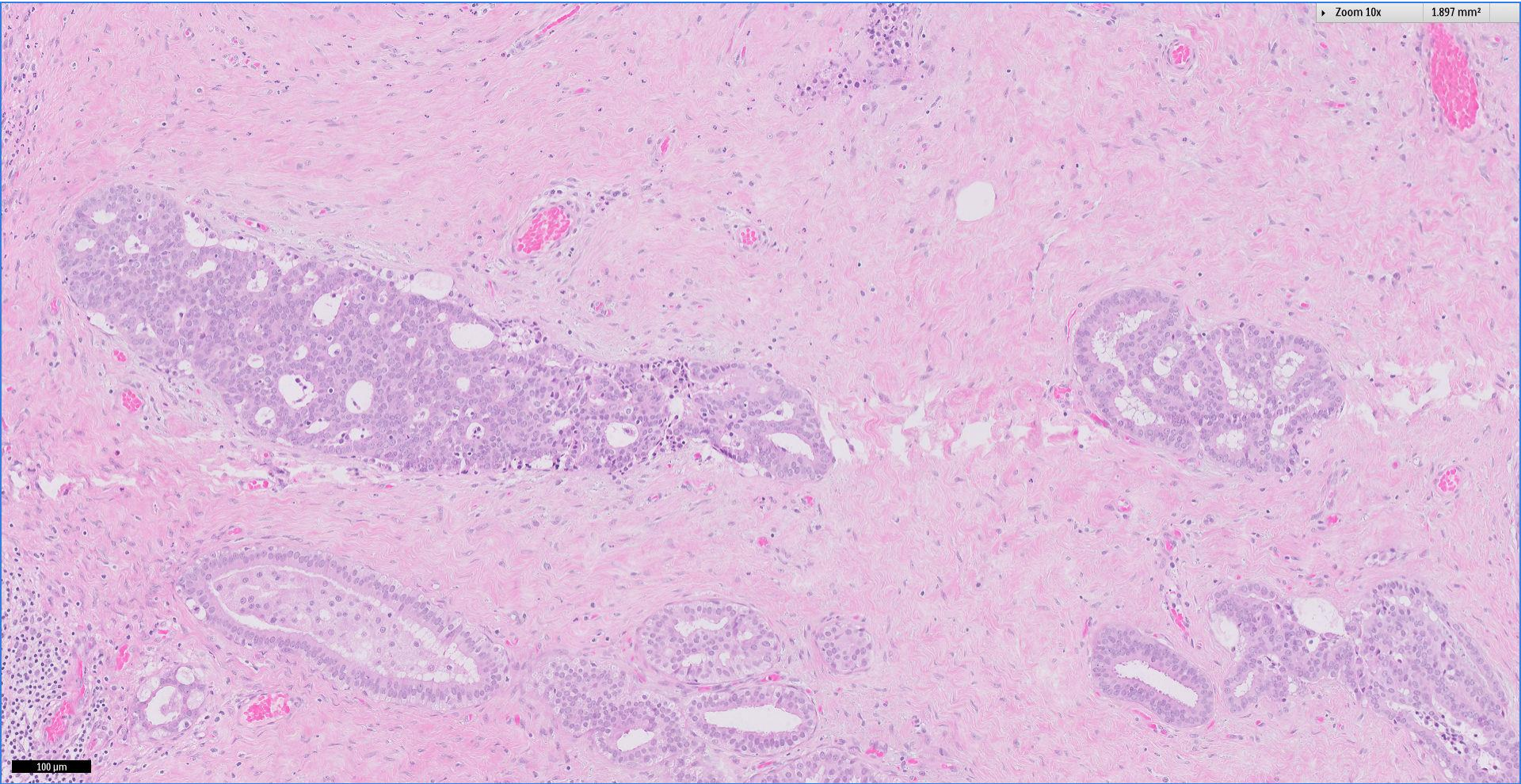


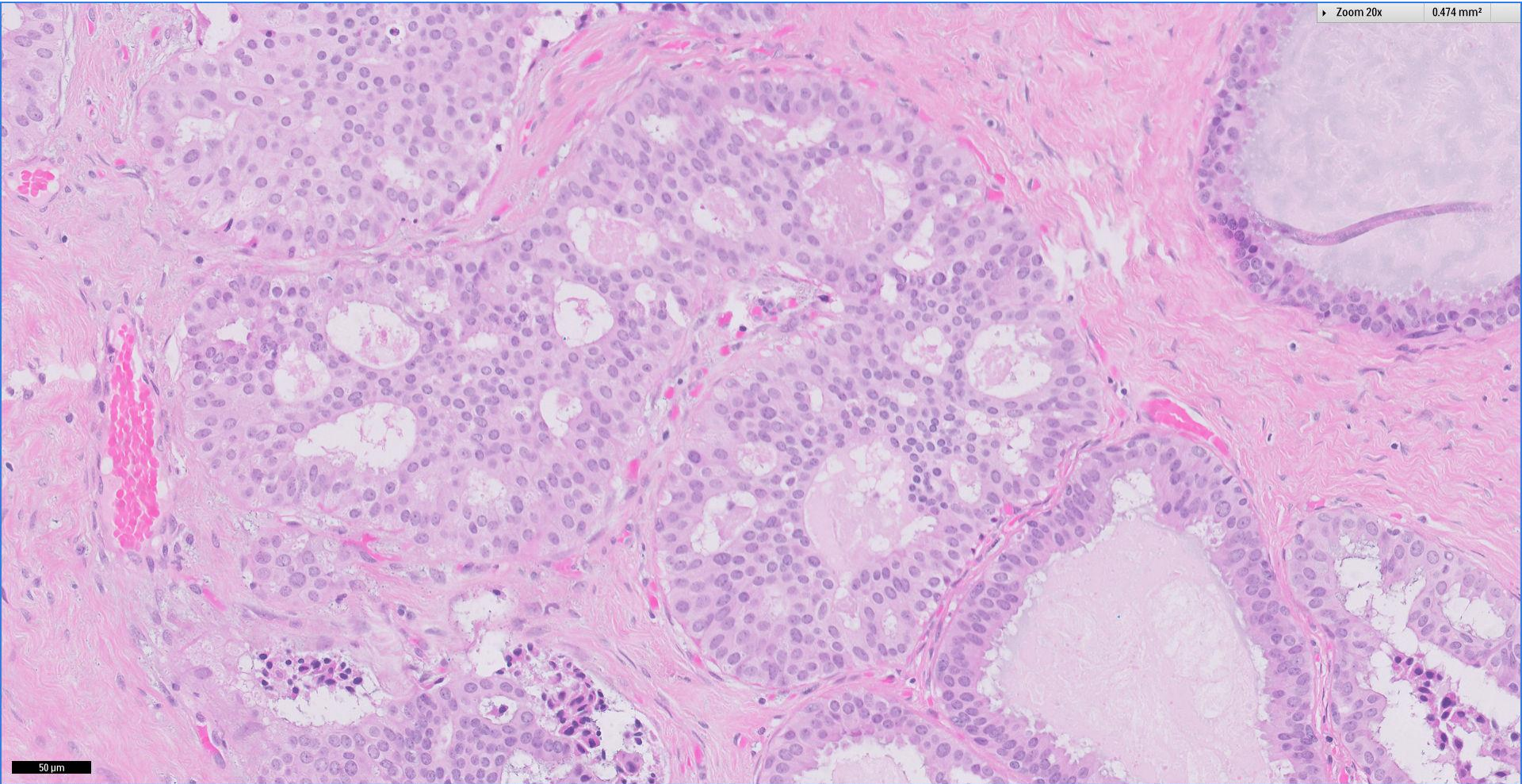


Division of Pathology
Singapore General Hospital









Division of Pathology
Singapore General Hospital



Thank You