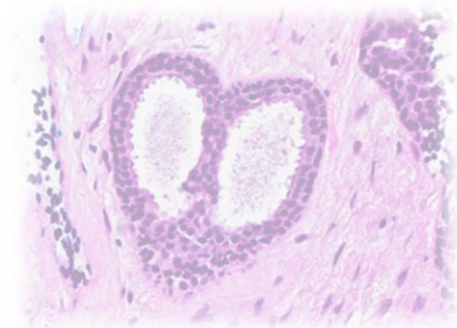
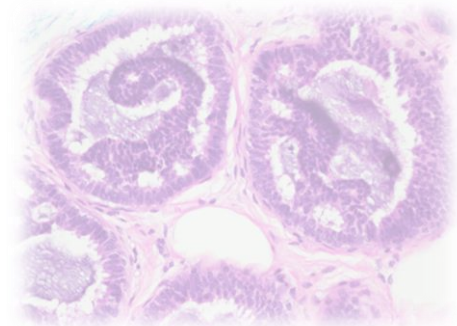
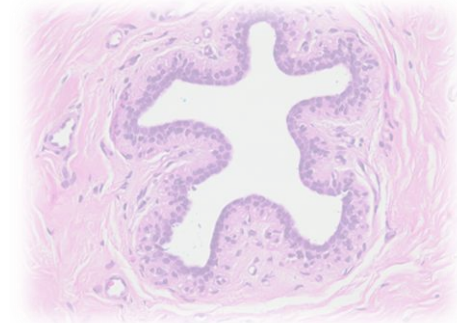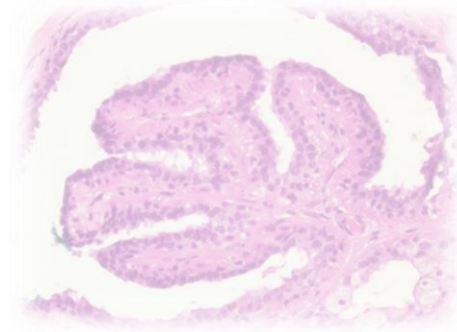
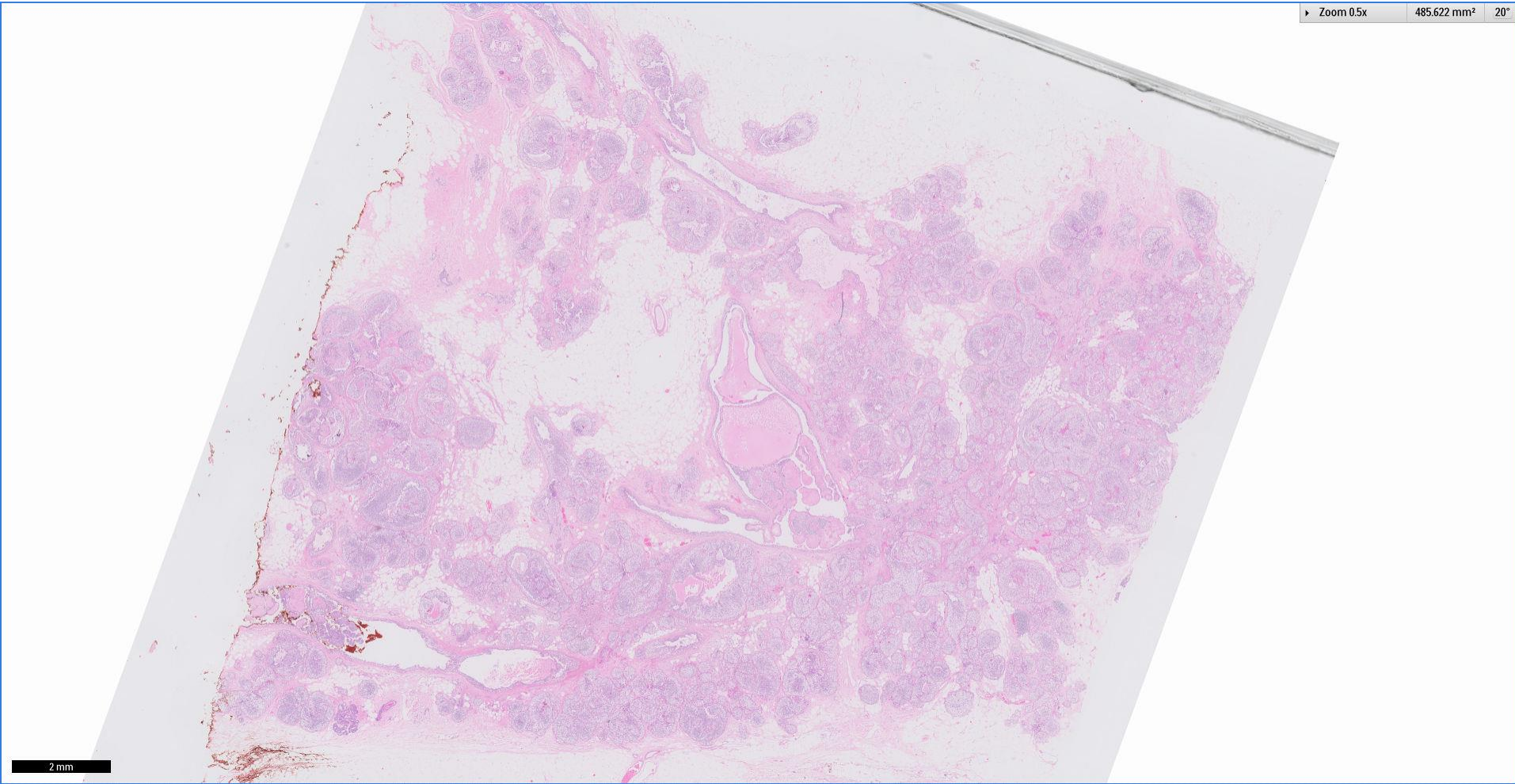


## Case 14

58 year old Chinese female.  
Right breast, nipple sparing  
mastectomy.

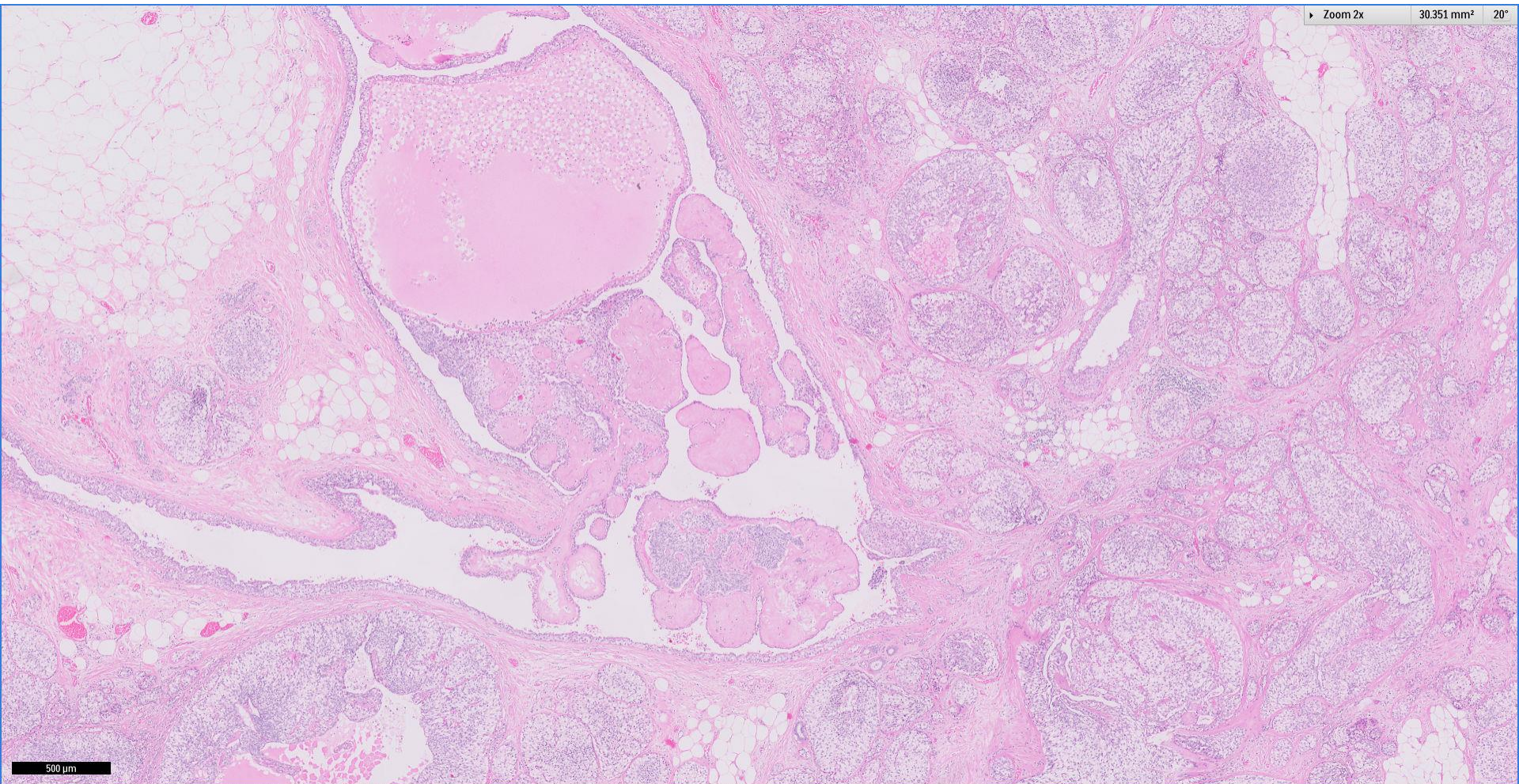




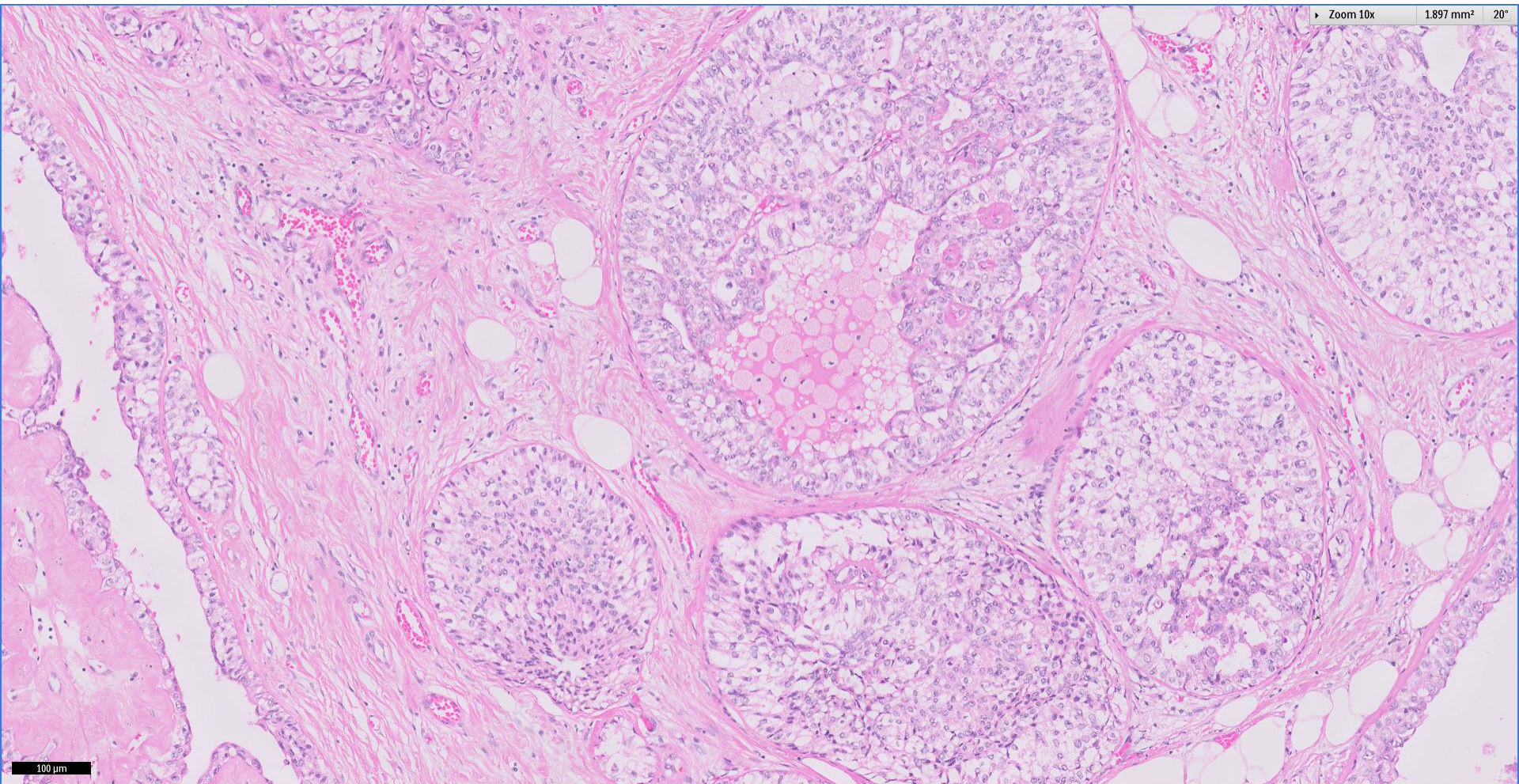
**Division of Pathology**  
**Singapore General Hospital**







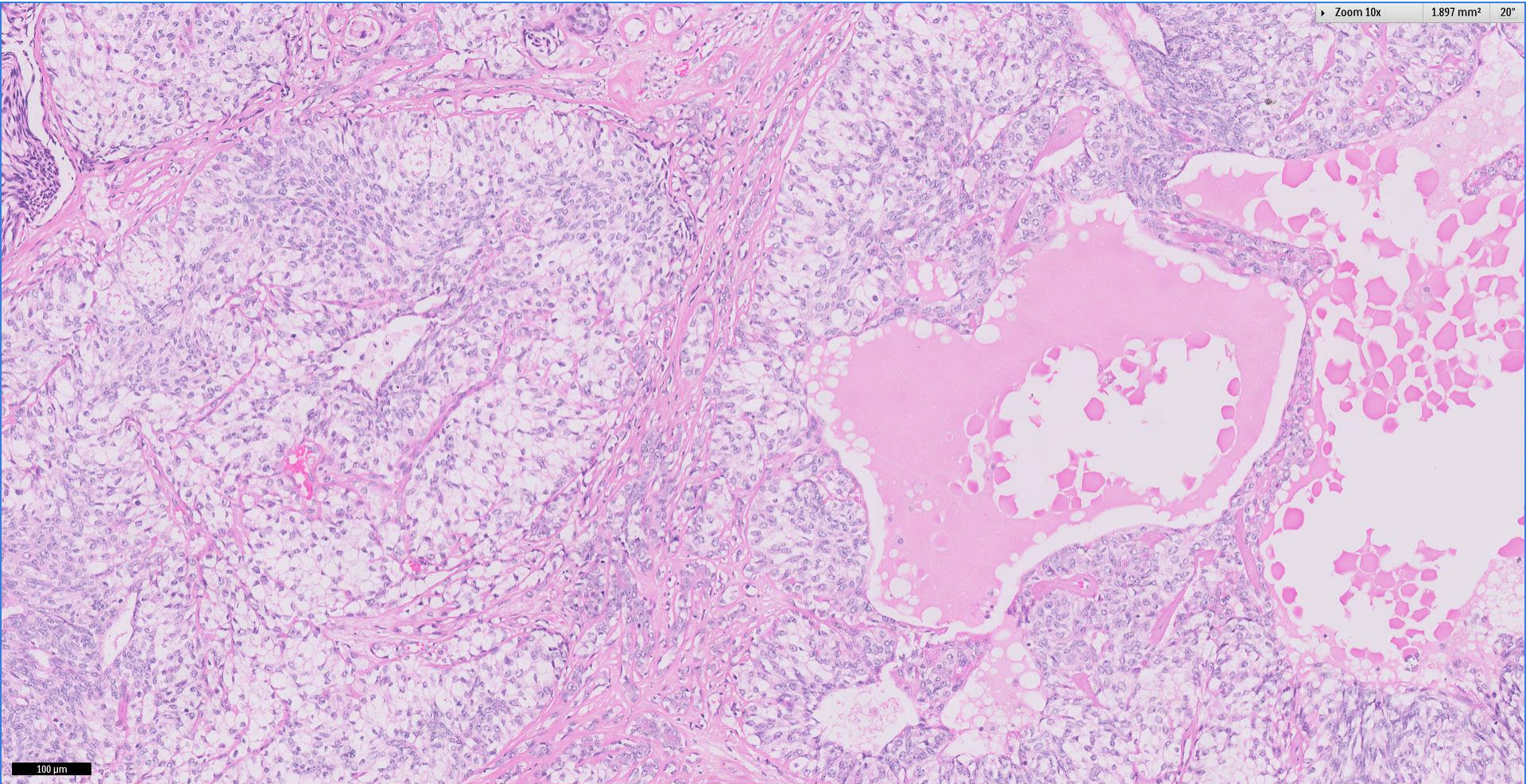




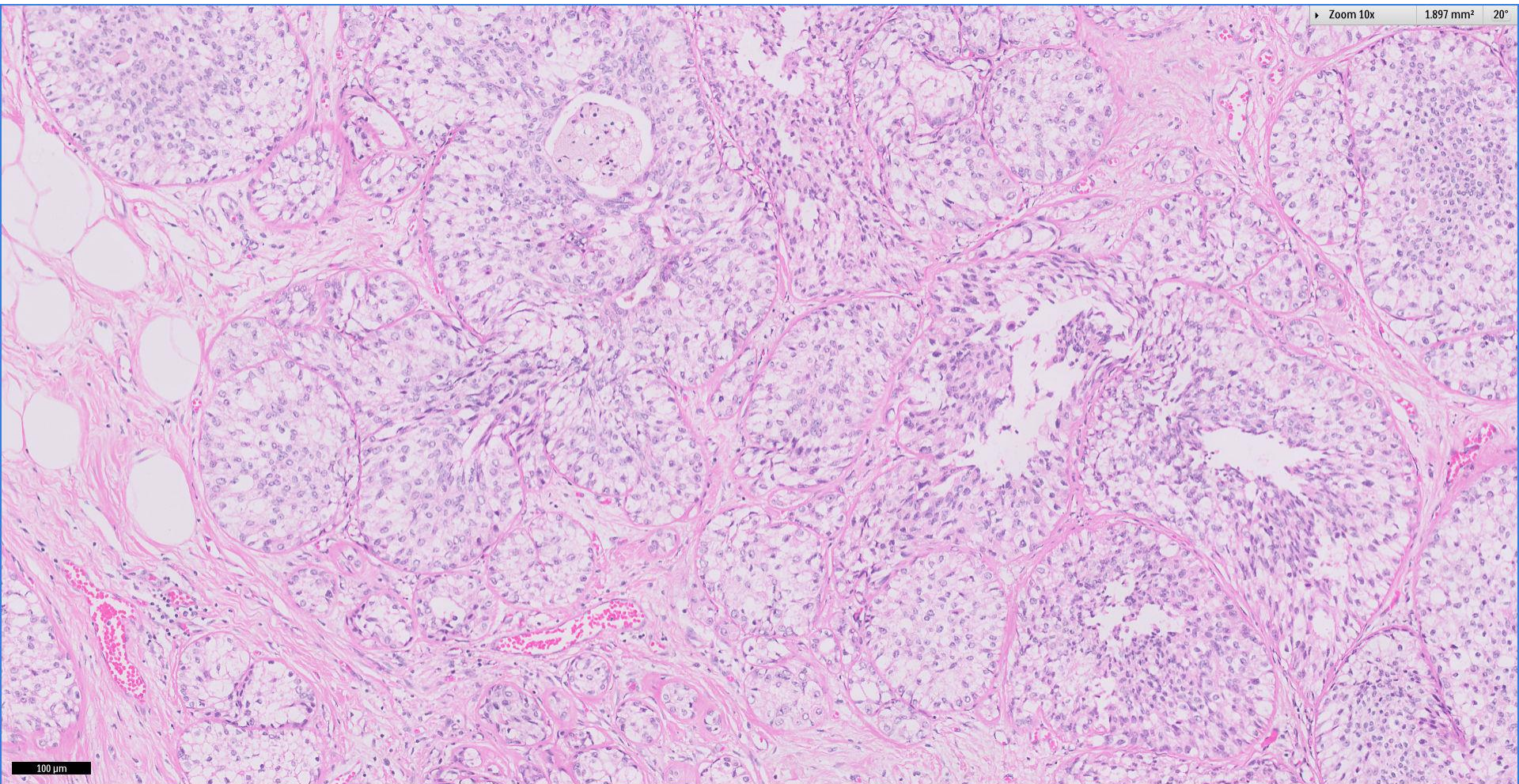
**Division of Pathology**  
**Singapore General Hospital**













*Thank You*