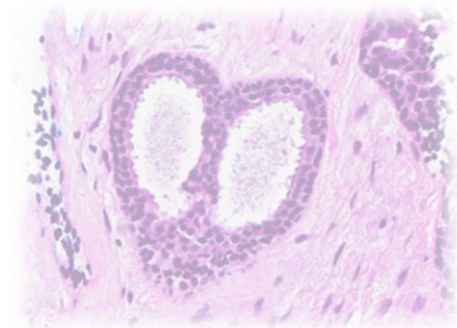
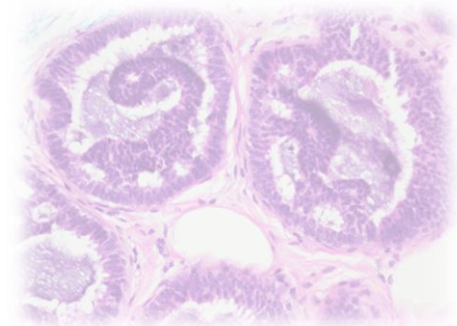
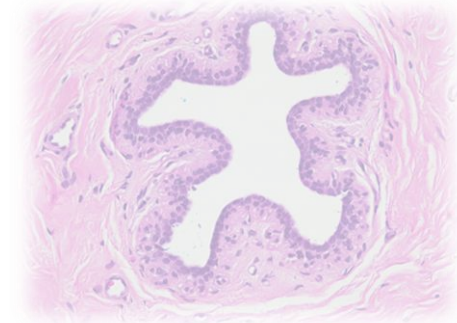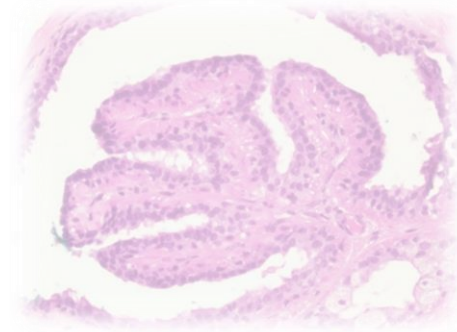
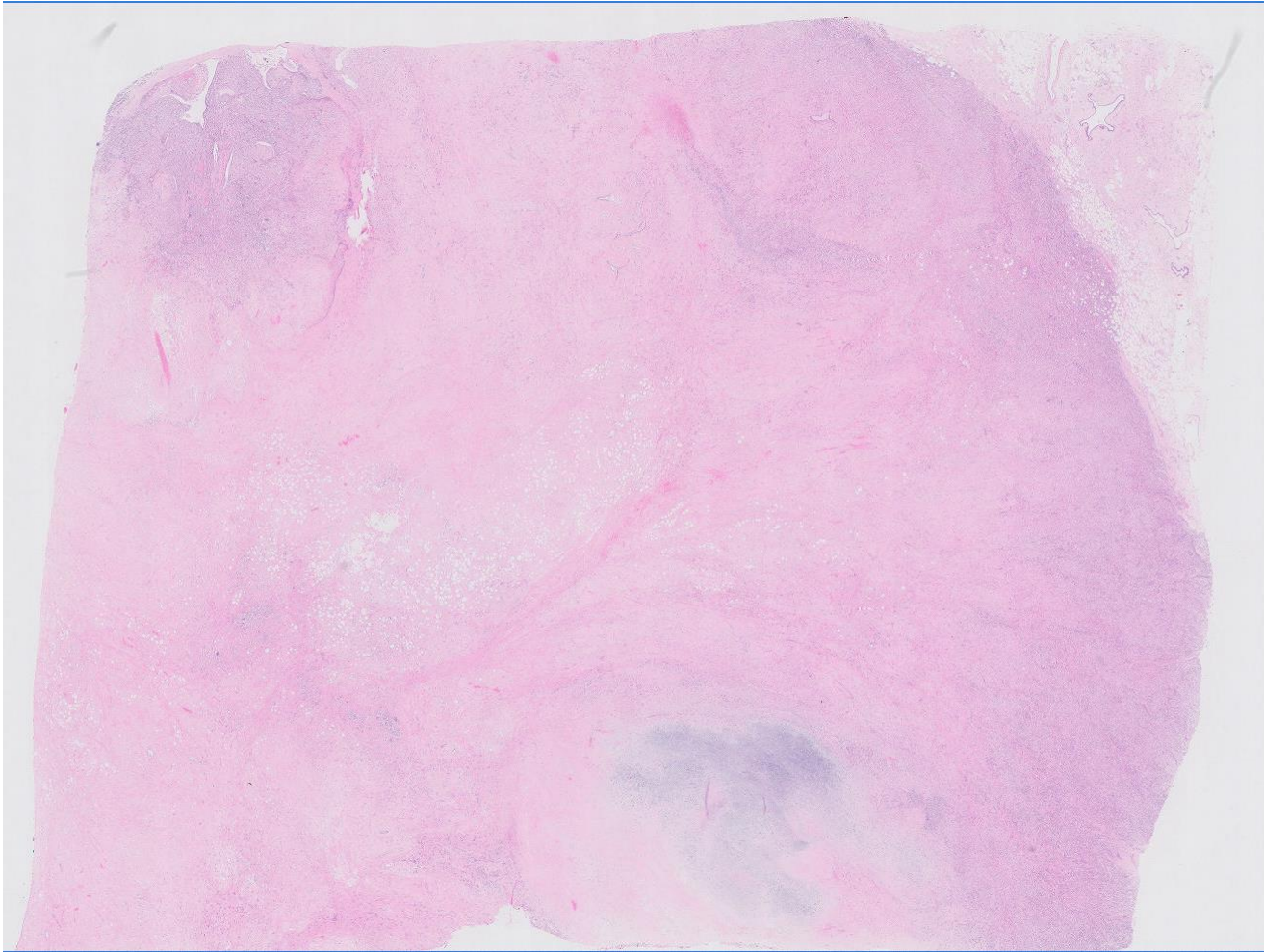


## Case 13

50 year old Chinese female.  
Left breast mastectomy for a 20cm  
mass.



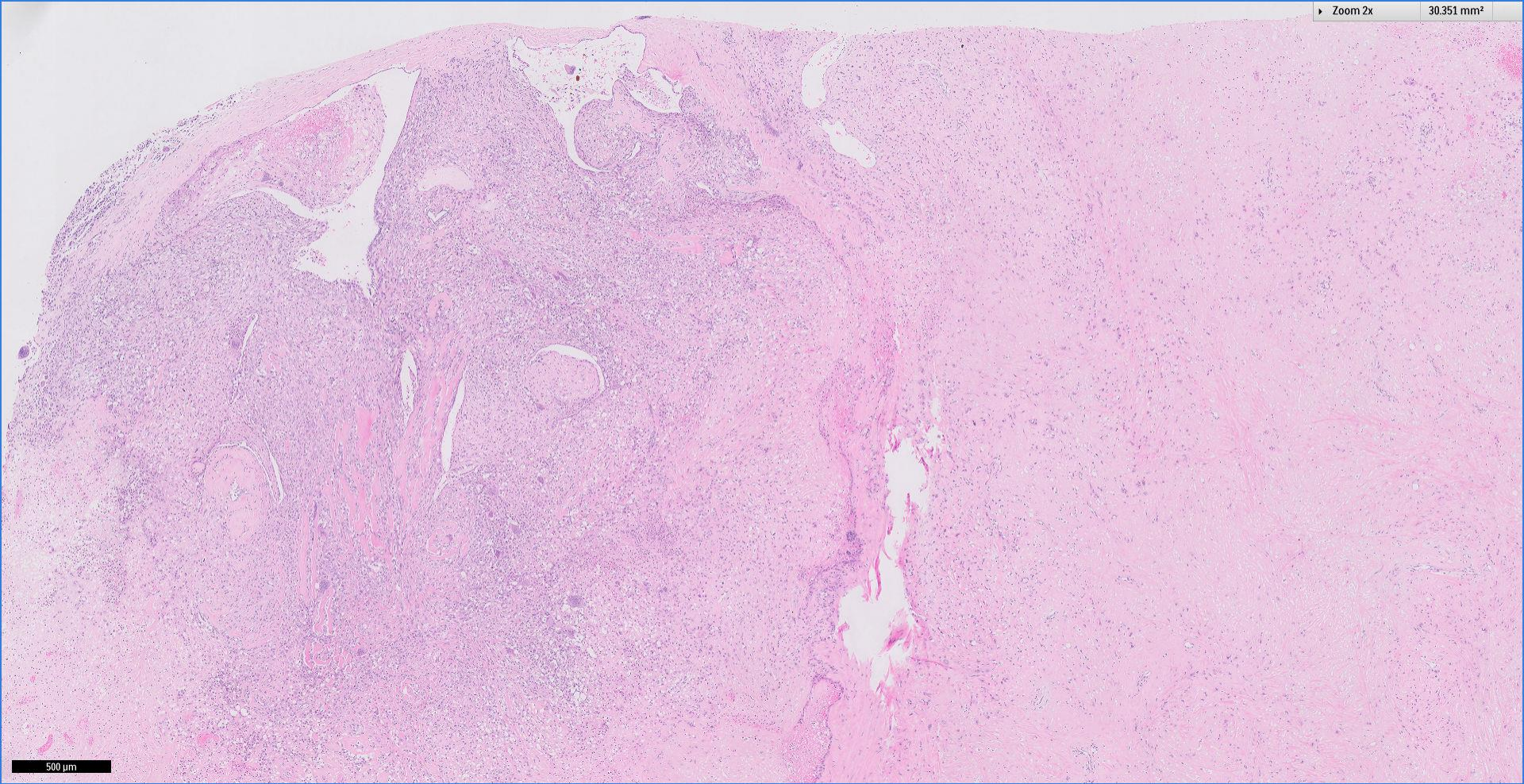


**Division of Pathology**  
**Singapore General Hospital**



Zoom 2x

30.351 mm<sup>2</sup>



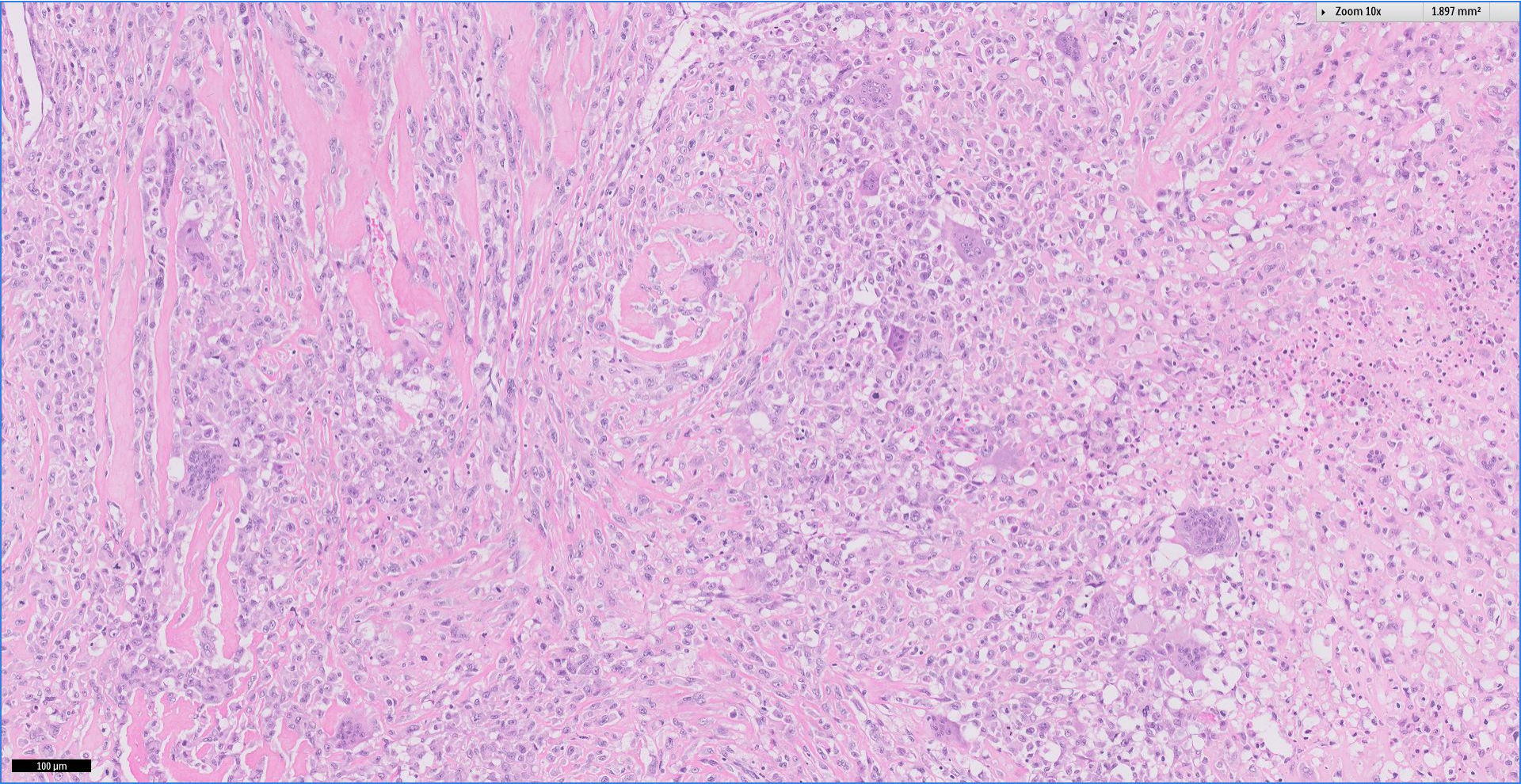
500 µm



Division of Pathology  
Singapore General Hospital



Zoom 10x 1.897 mm<sup>2</sup>

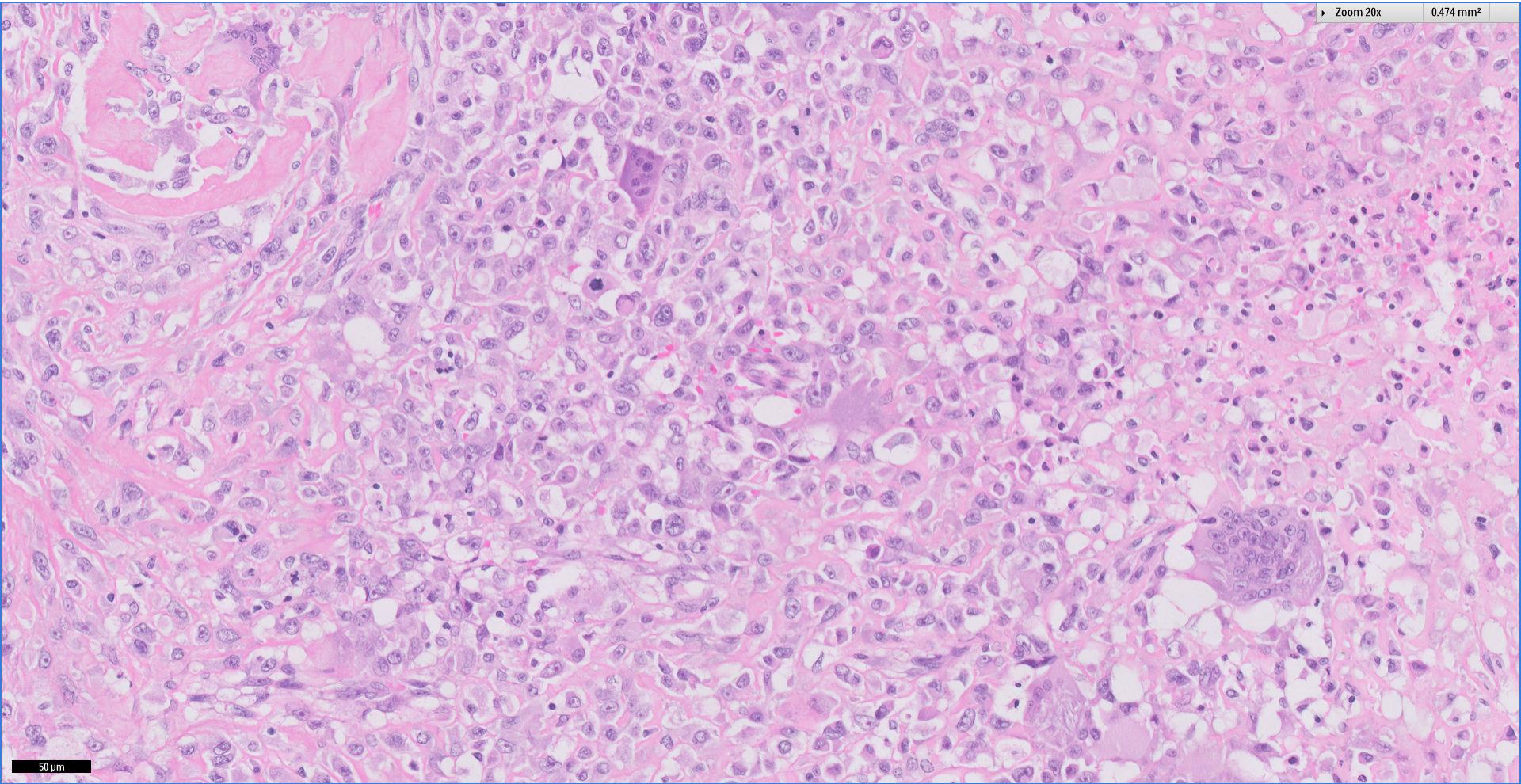


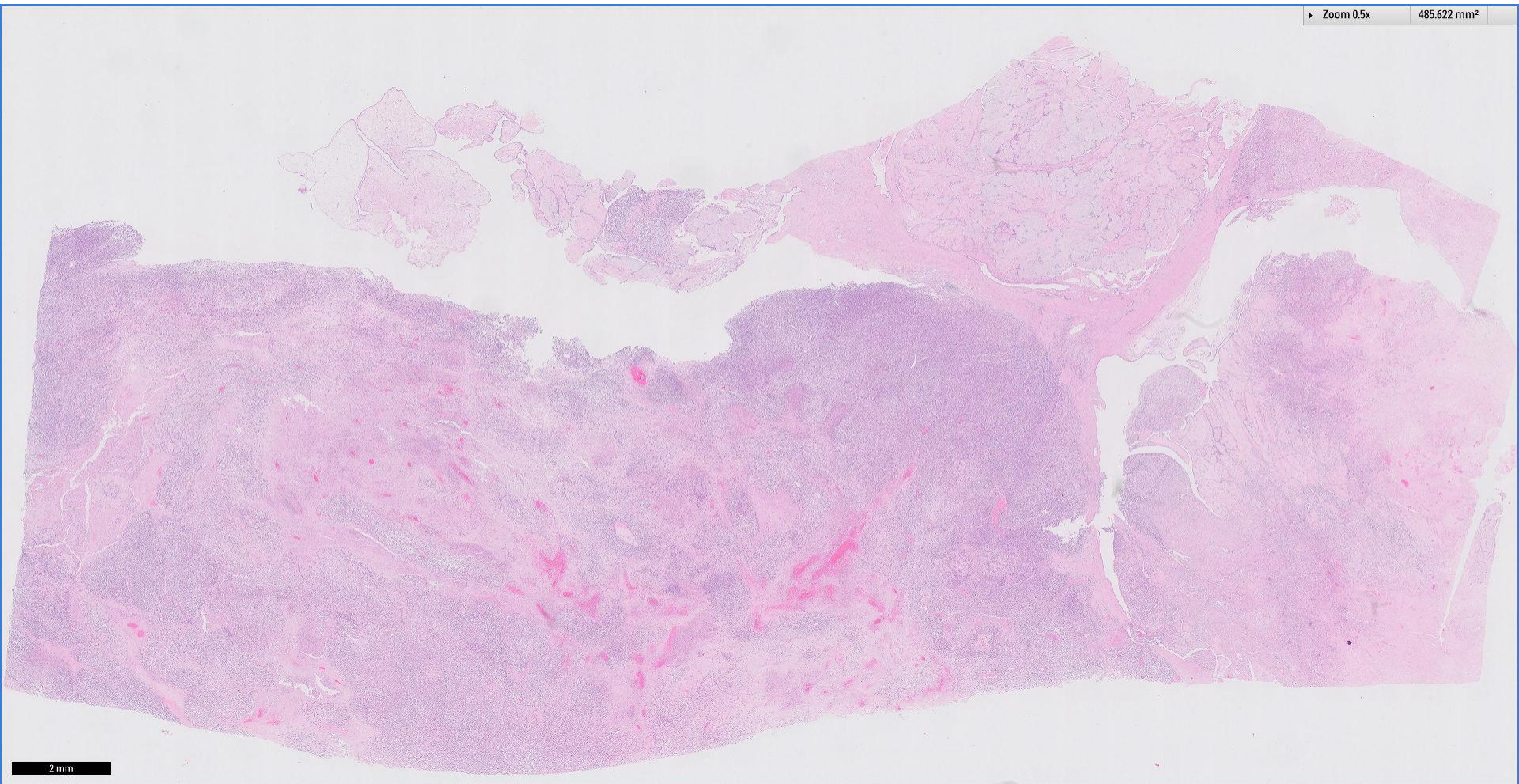
100 µm

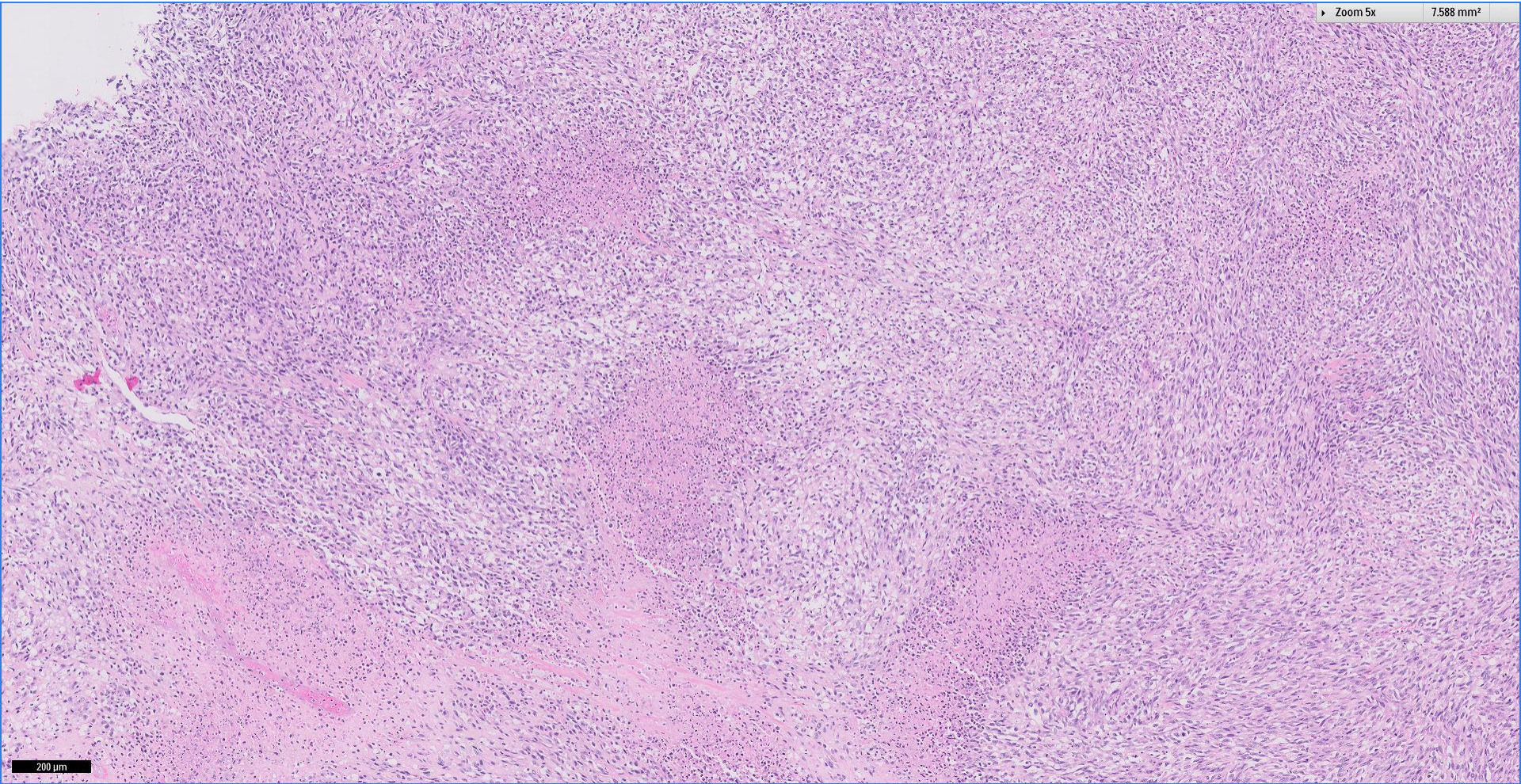


**Division of Pathology**  
**Singapore General Hospital**







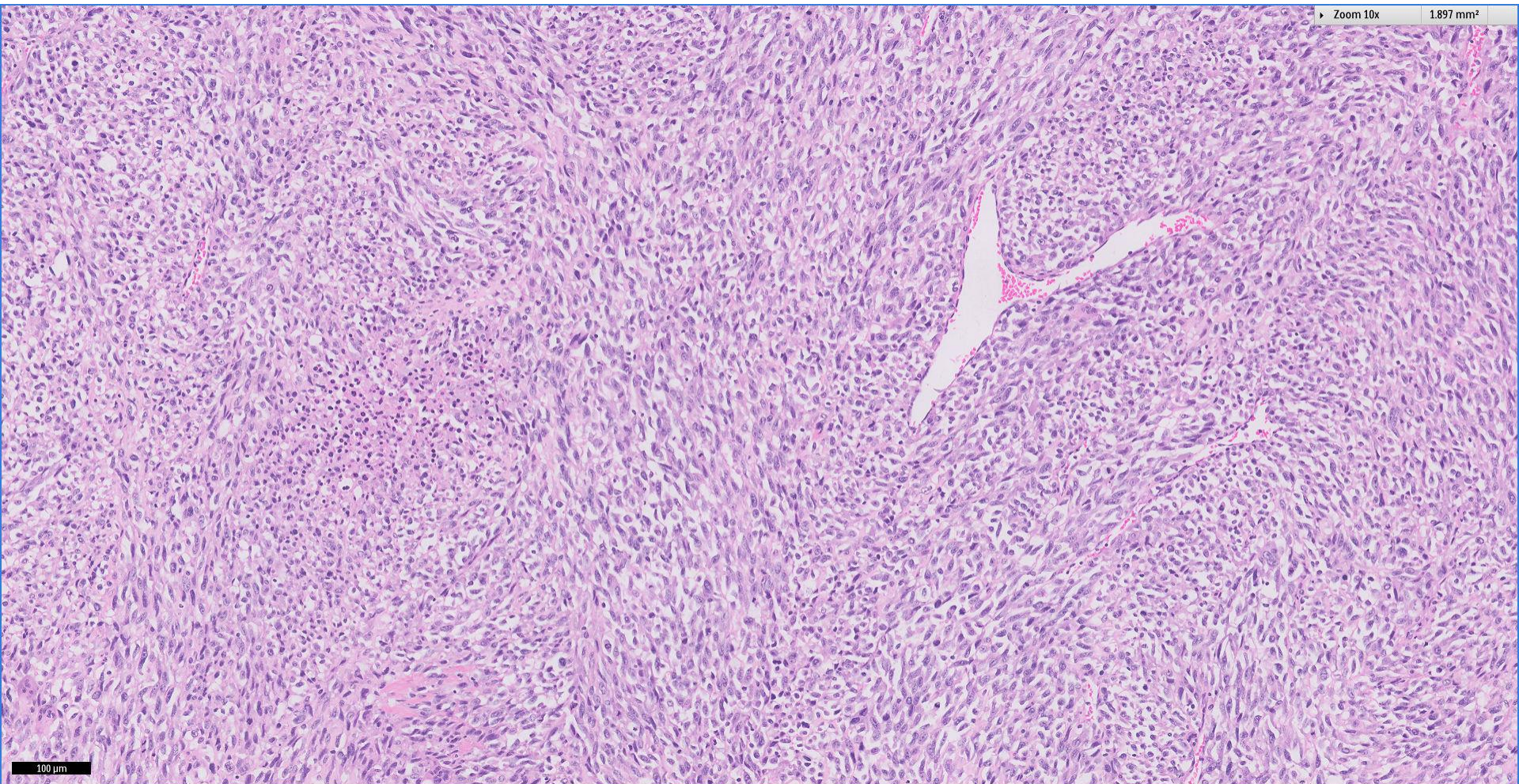


200 µm

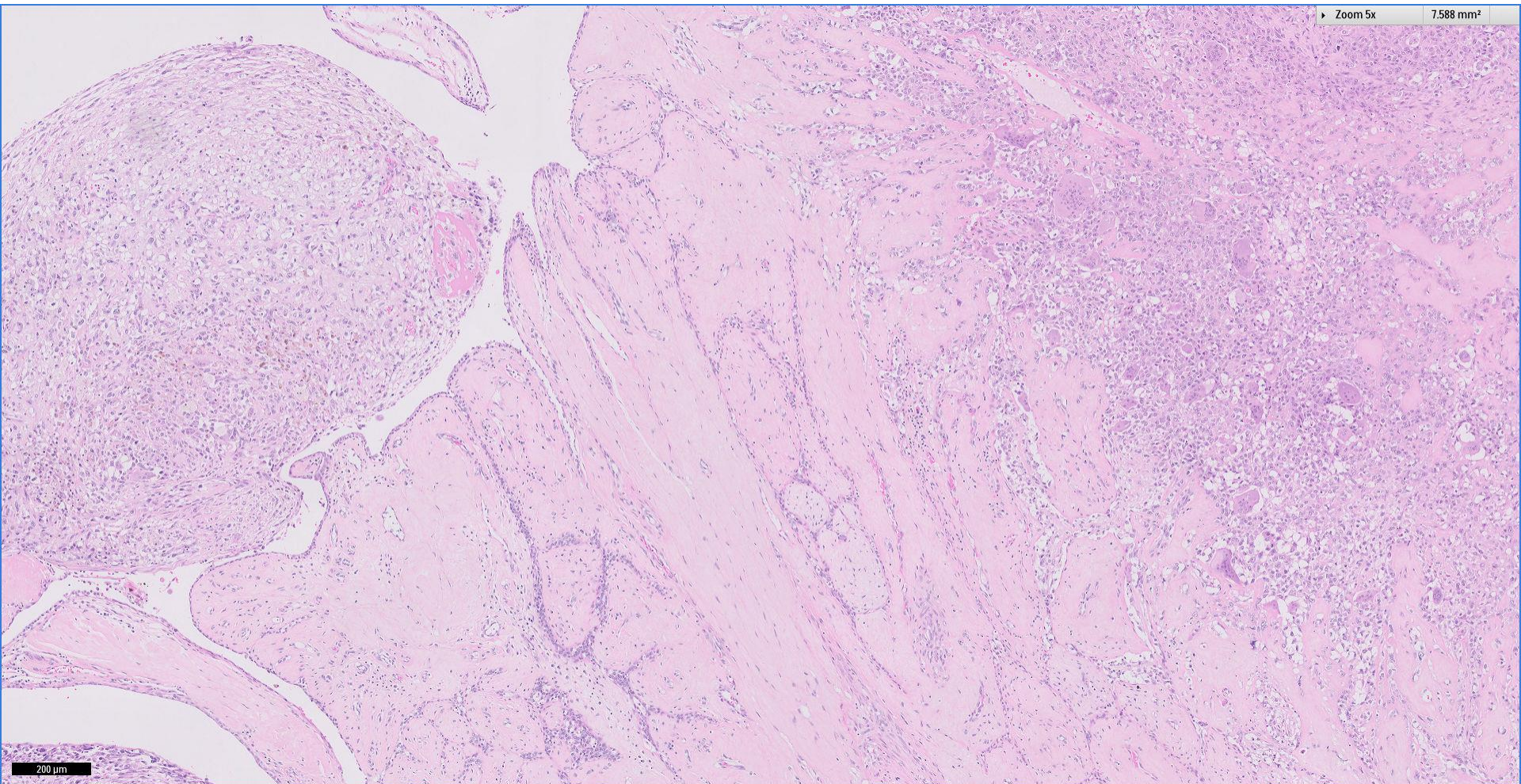


**Division of Pathology**  
**Singapore General Hospital**









*Thank You*