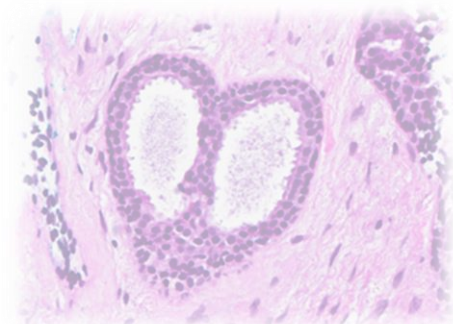
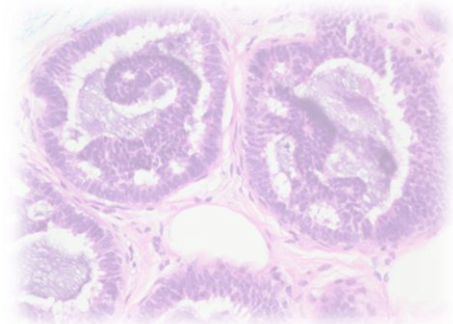
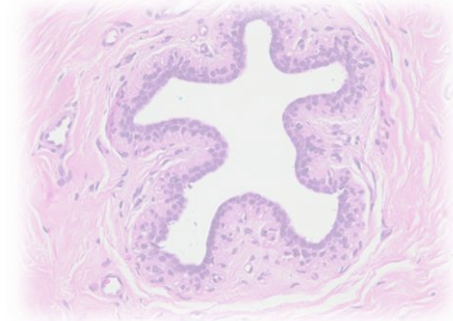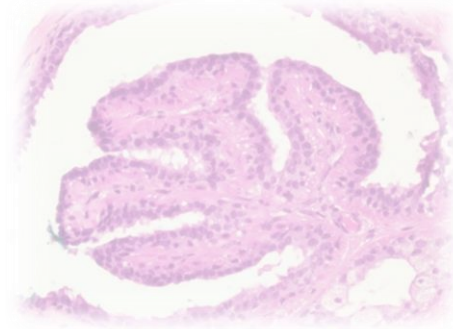
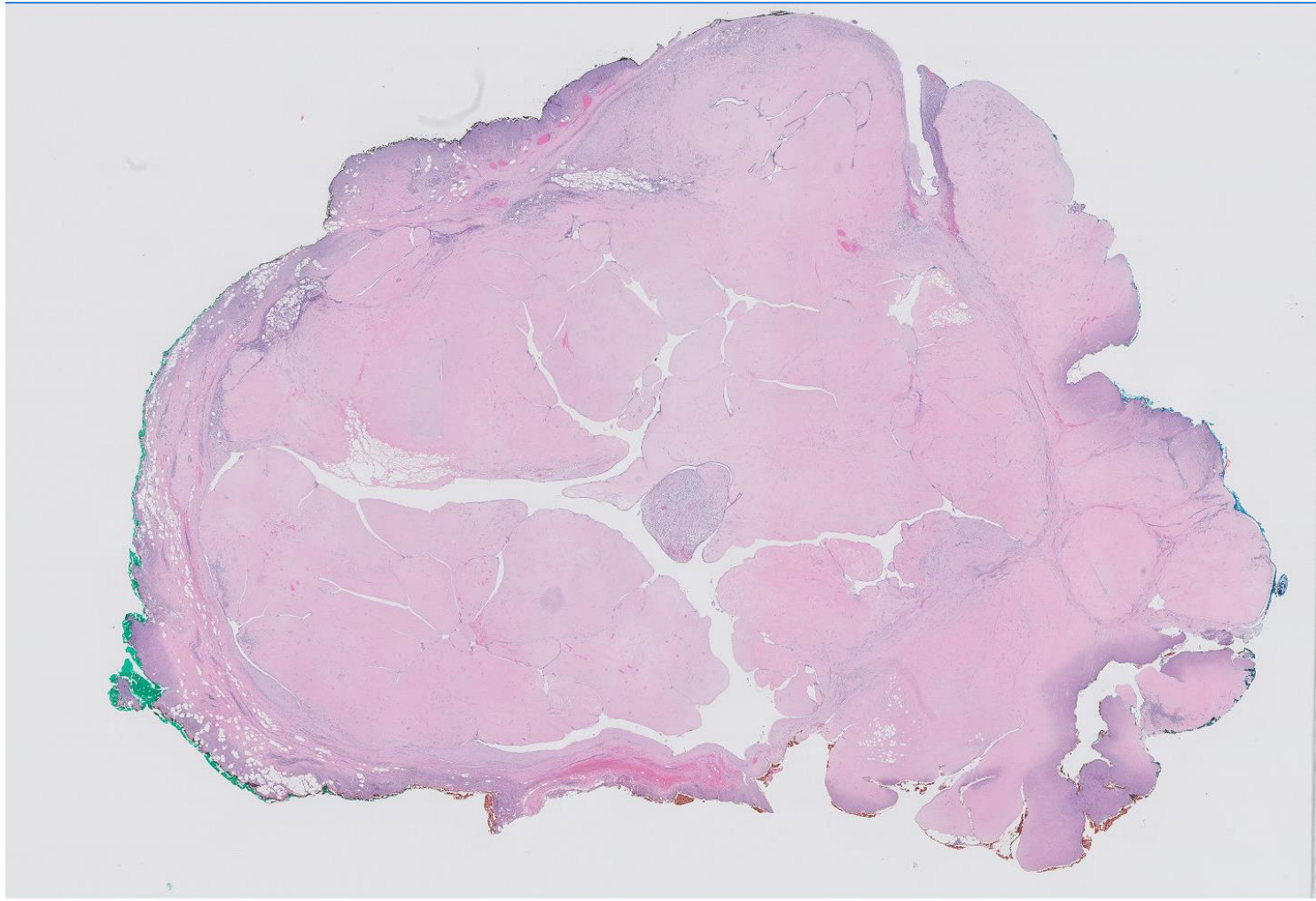


Case 12

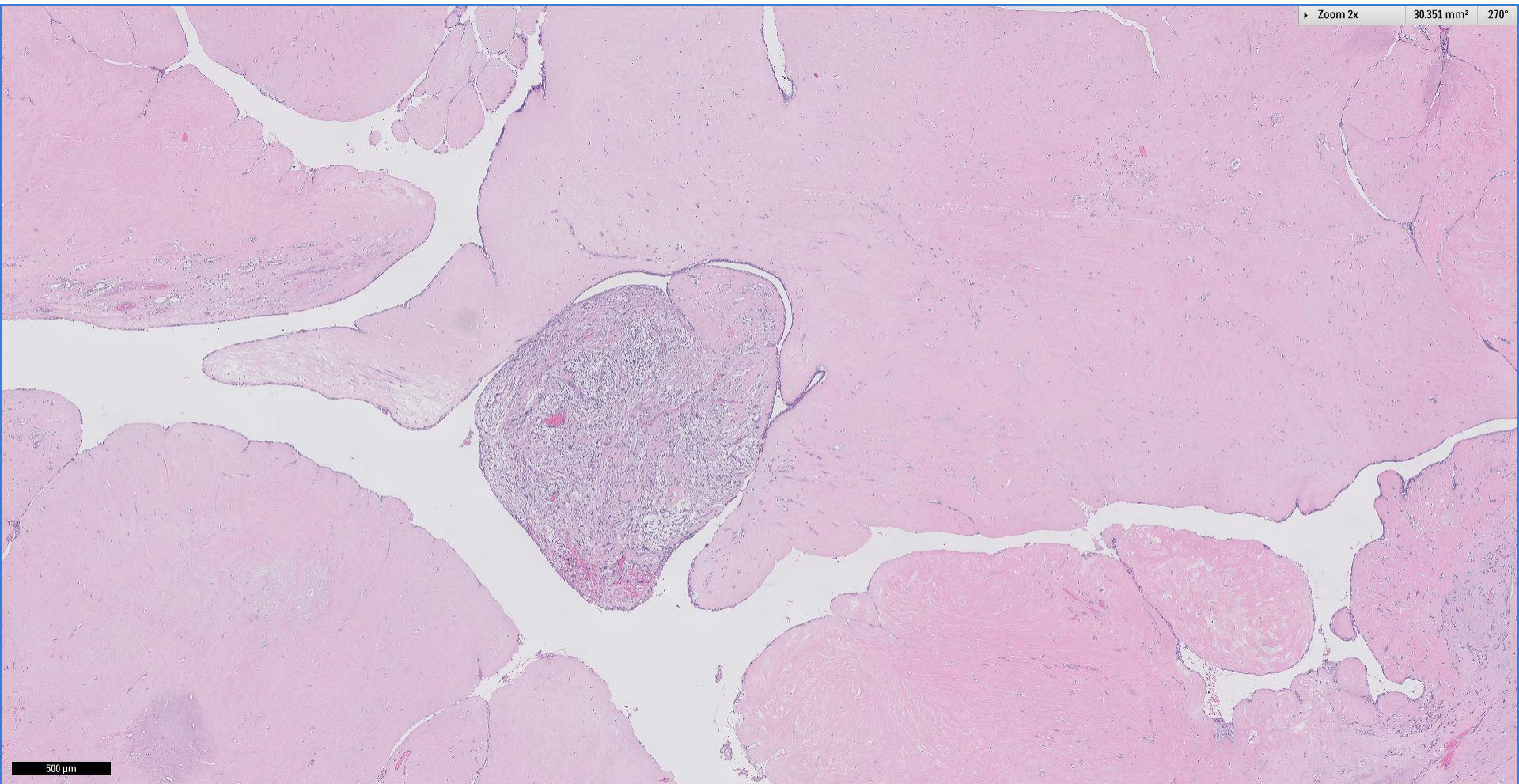
45 year old Indian female.
Left breast 2:00 lesion, excision
biopsy.

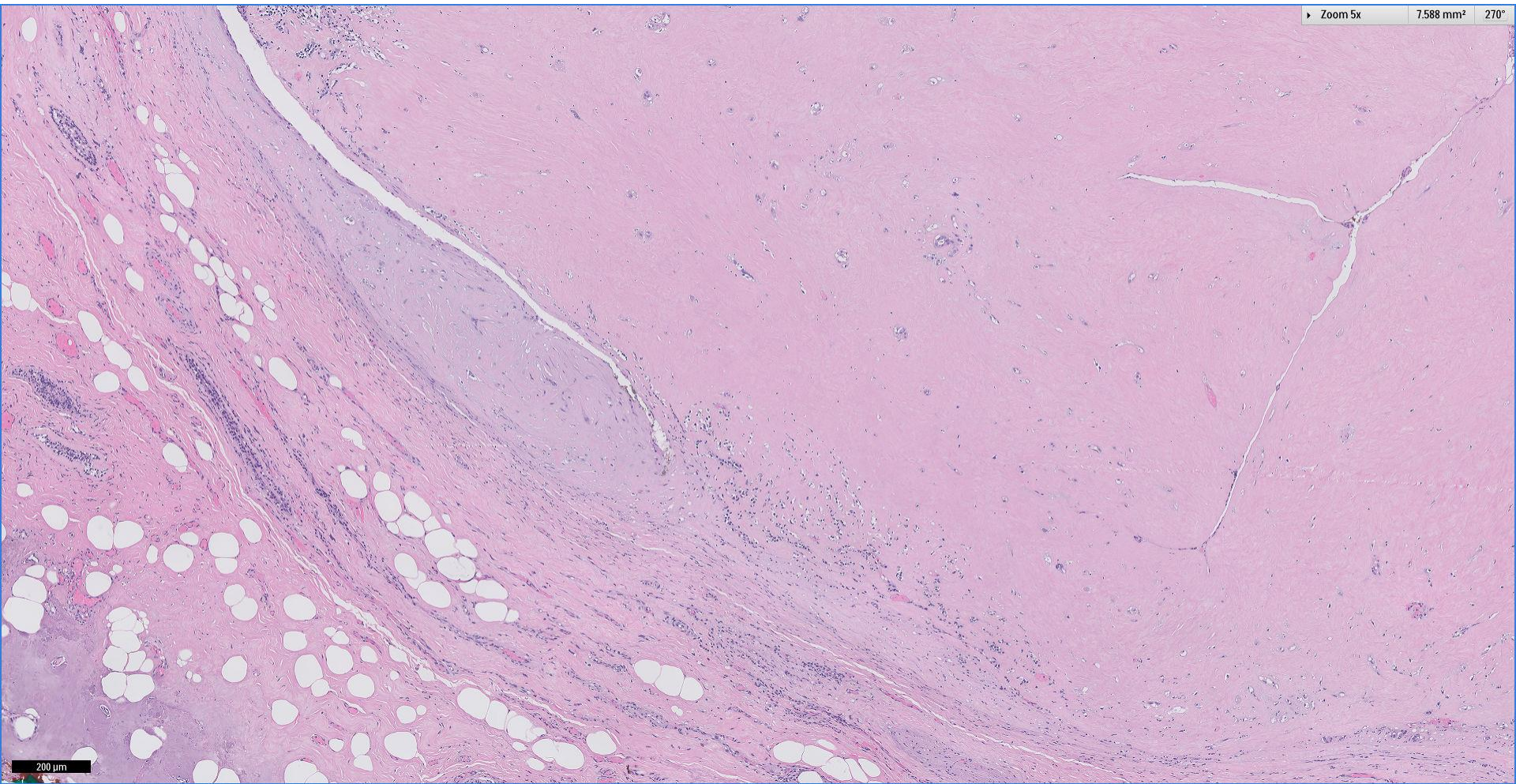




Division of Pathology
Singapore General Hospital

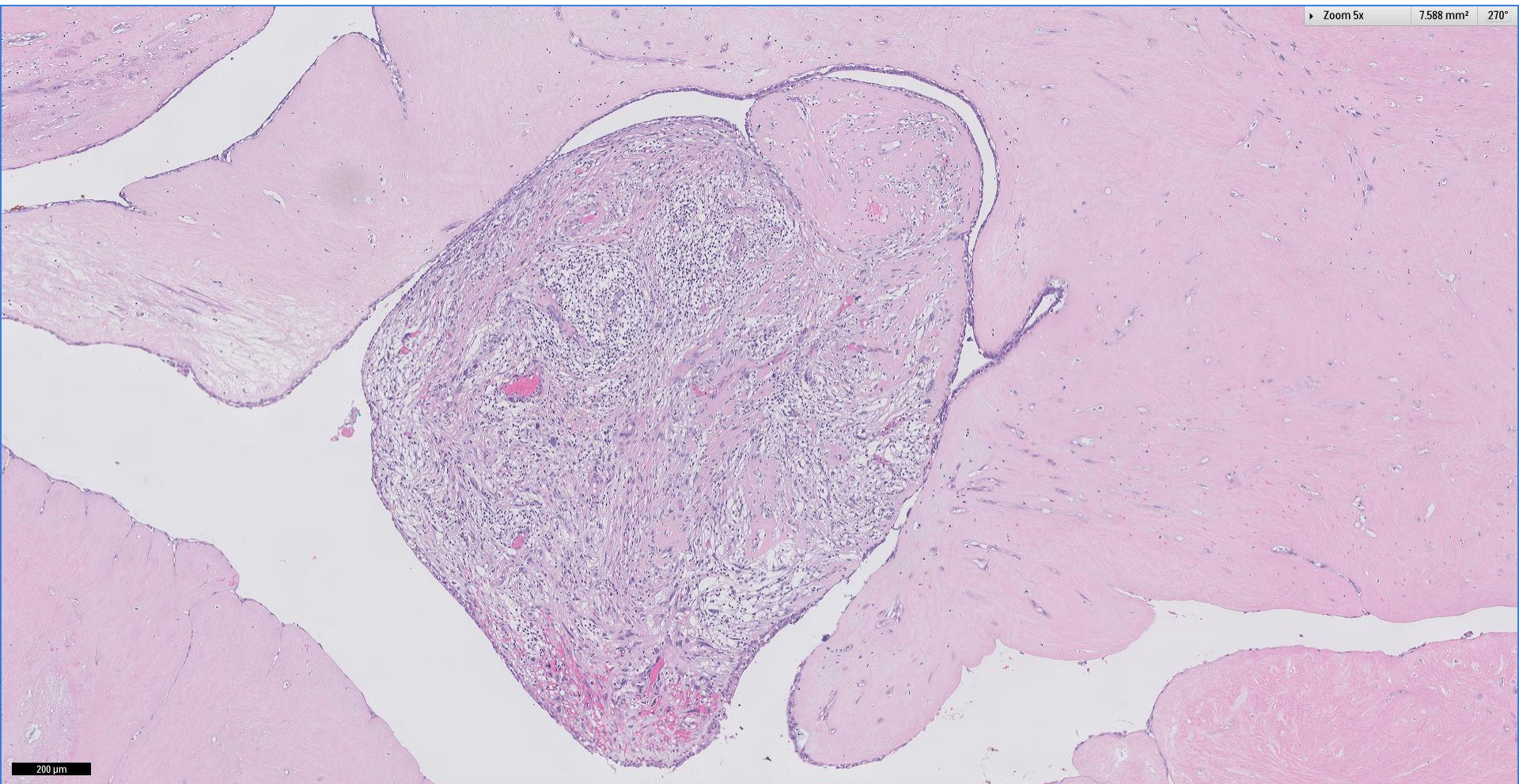


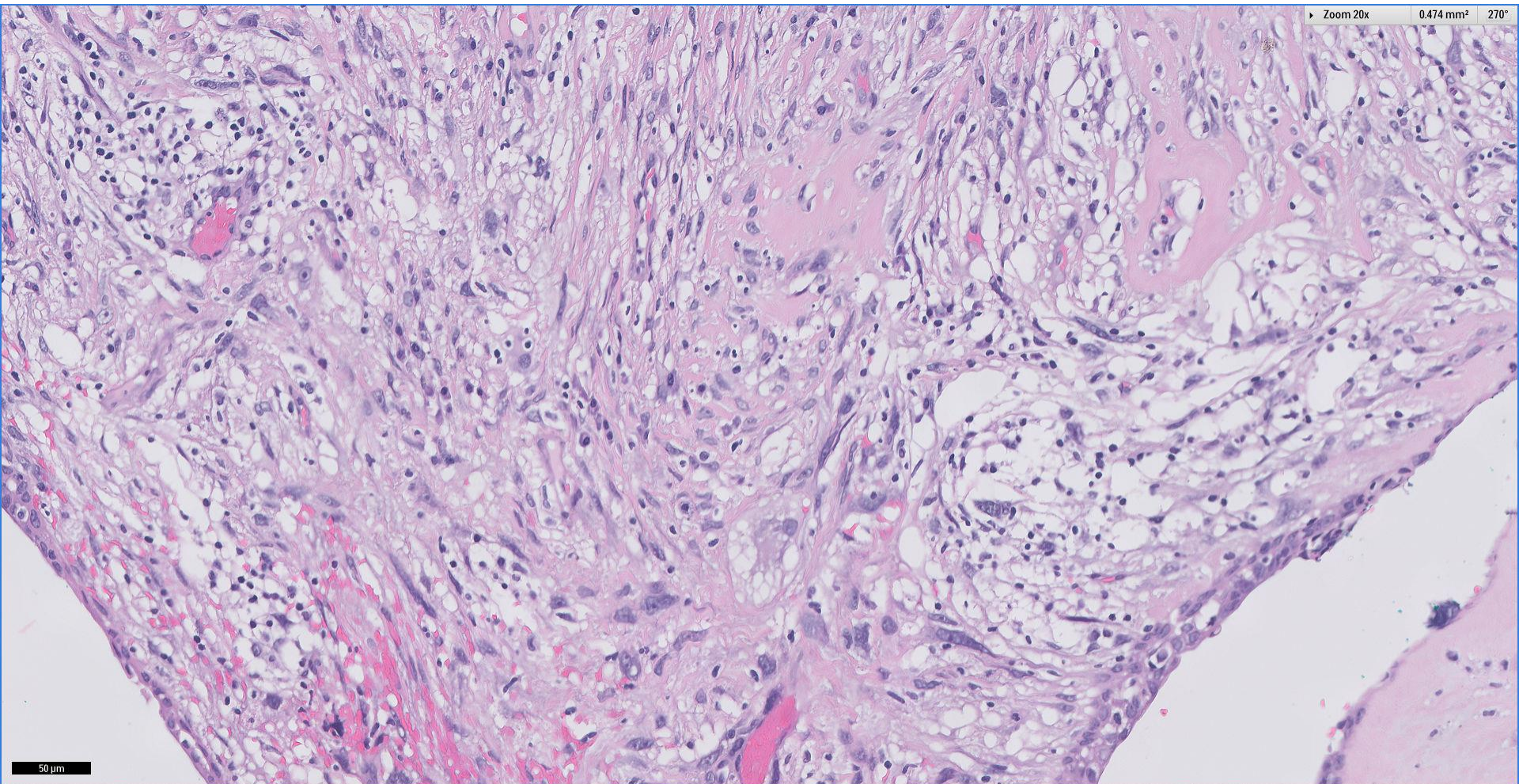


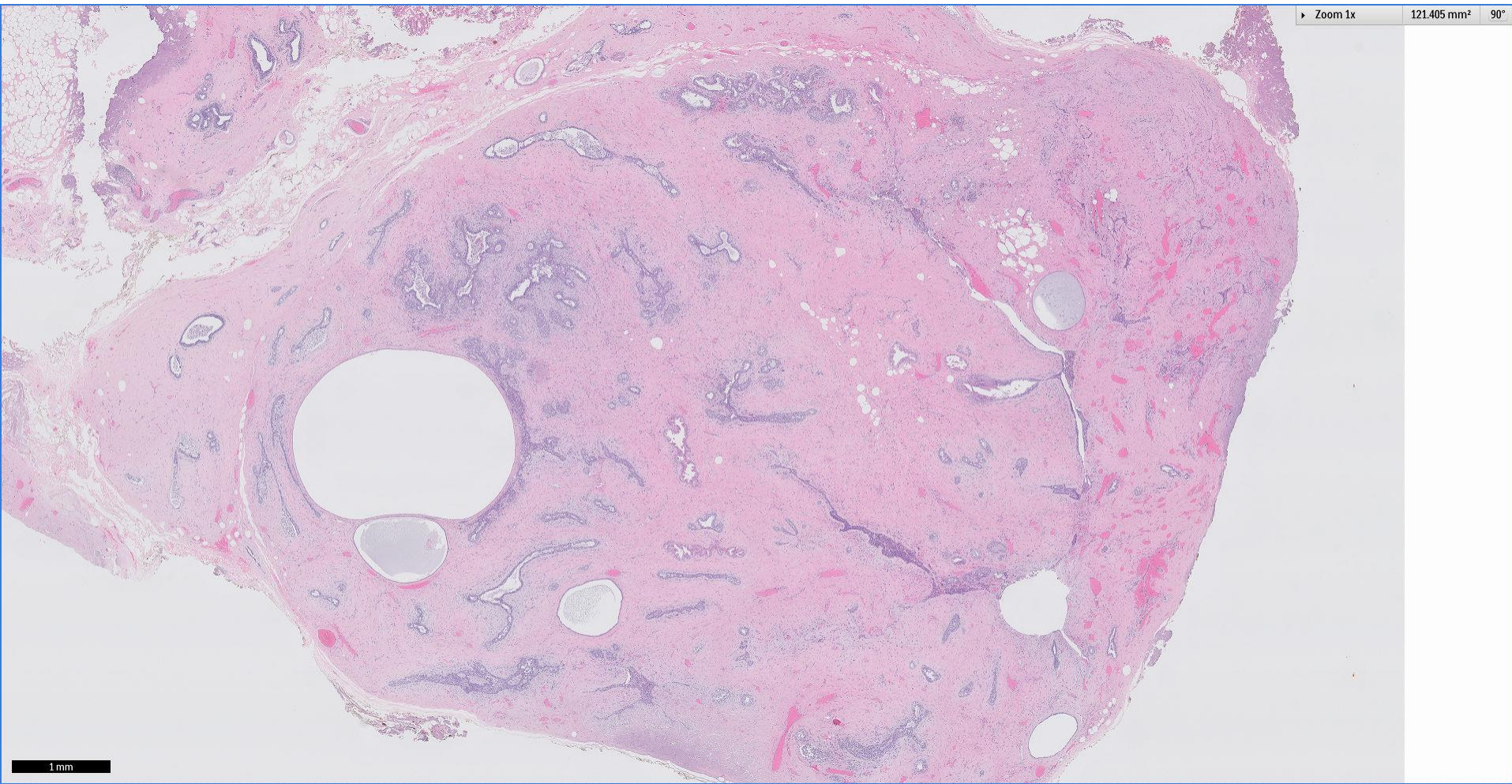


Division of Pathology
Singapore General Hospital



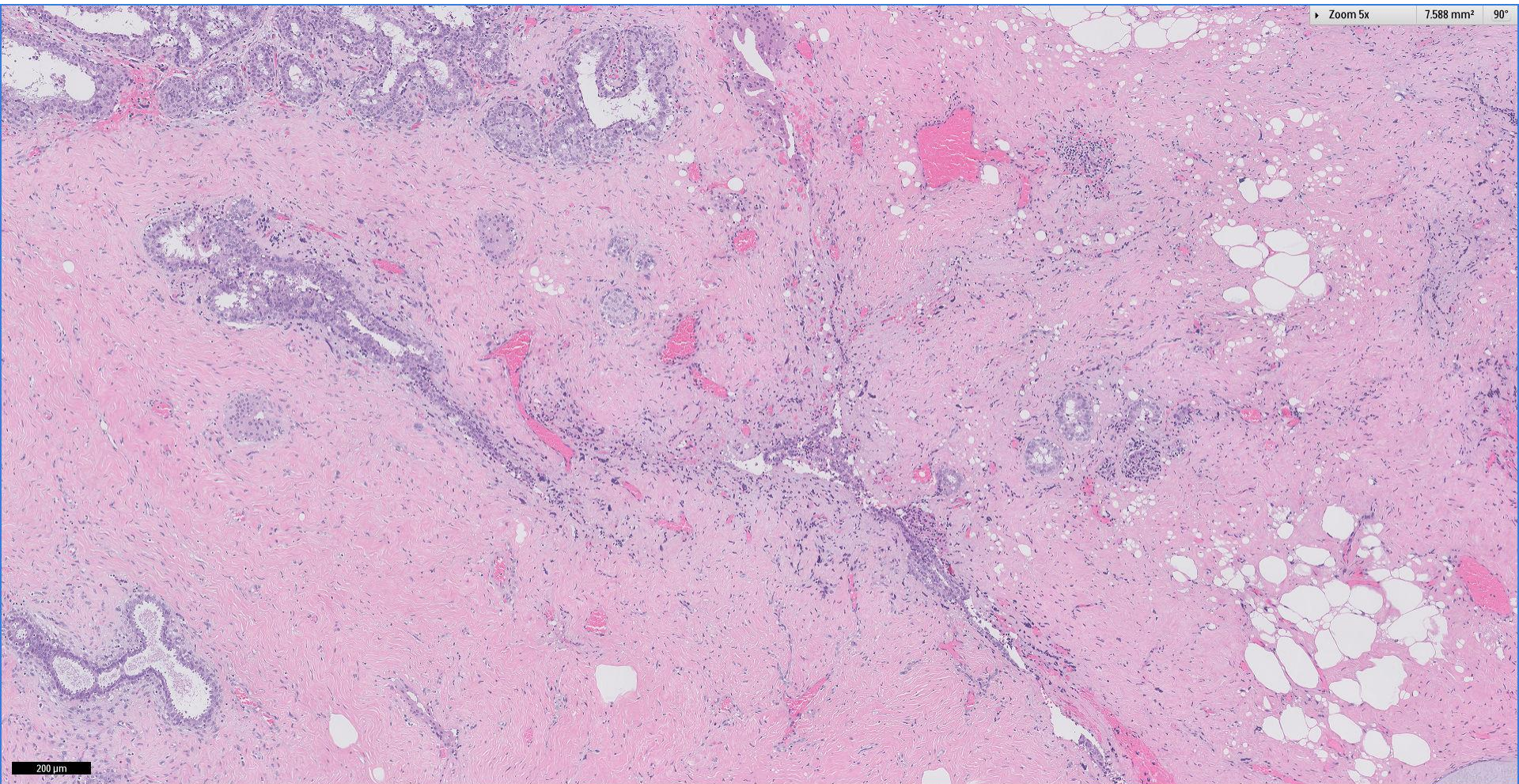


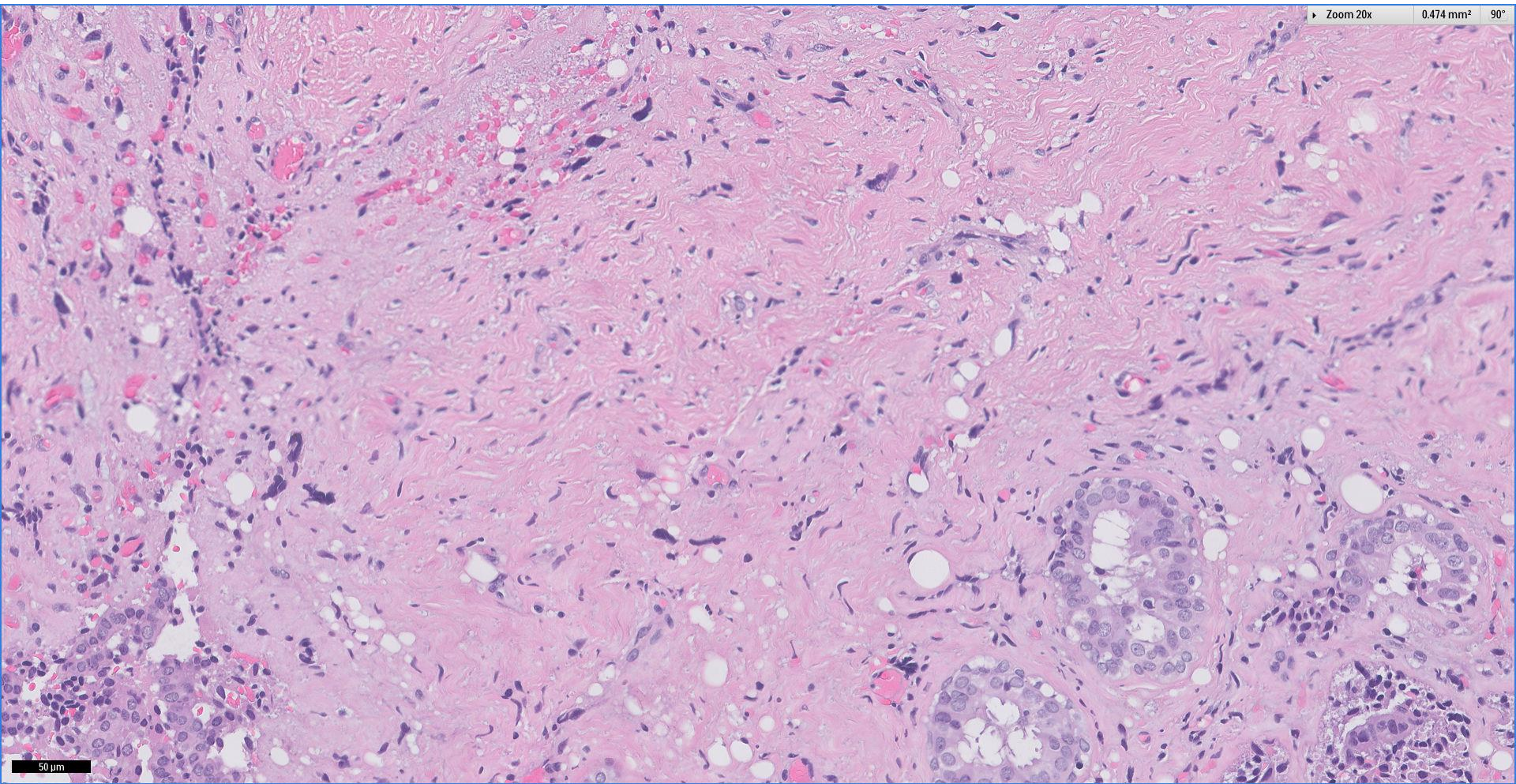




Division of Pathology
Singapore General Hospital







Zoom 20x 0.474 mm² 90°

50 μm

Thank You