

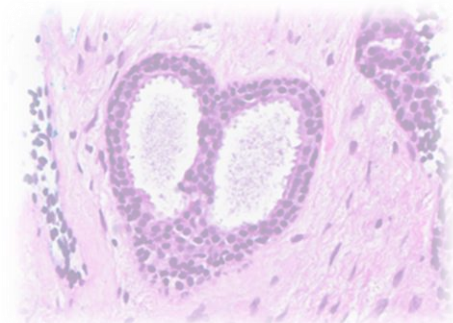
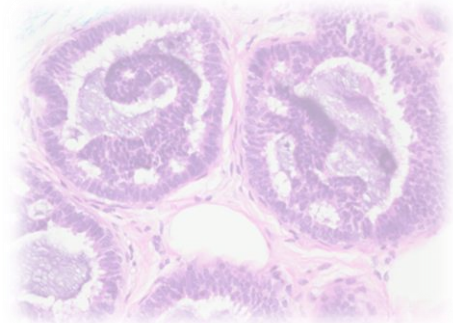
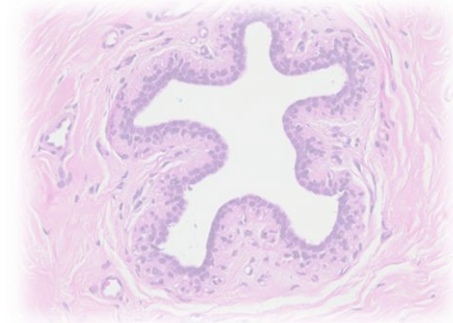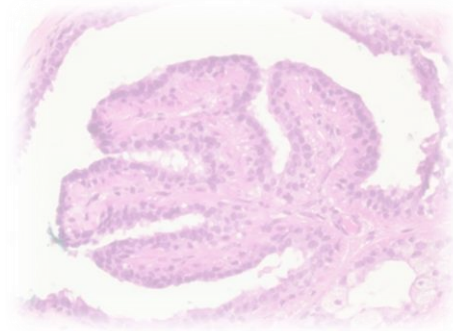
Case 11

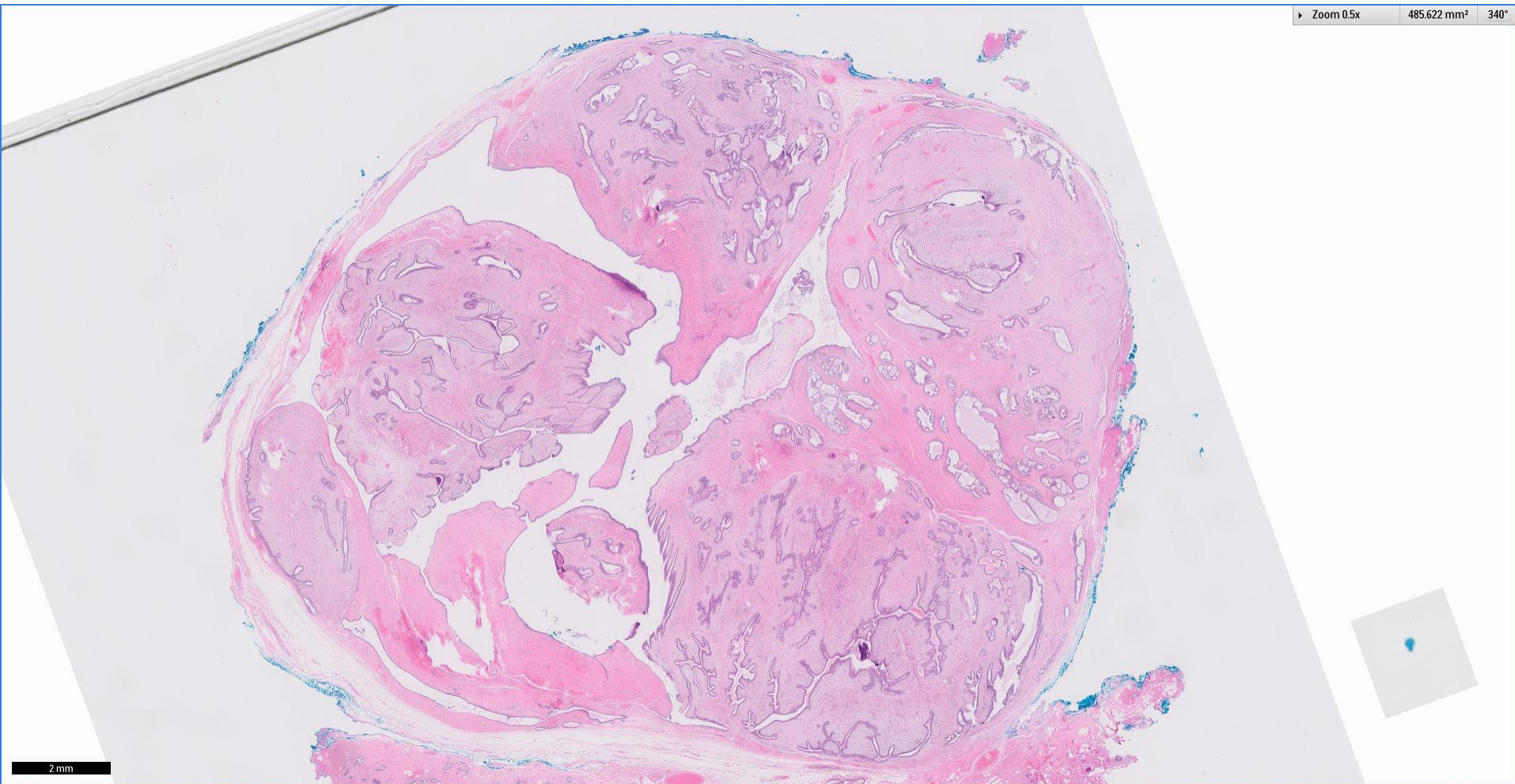
27 year old Chinese female.

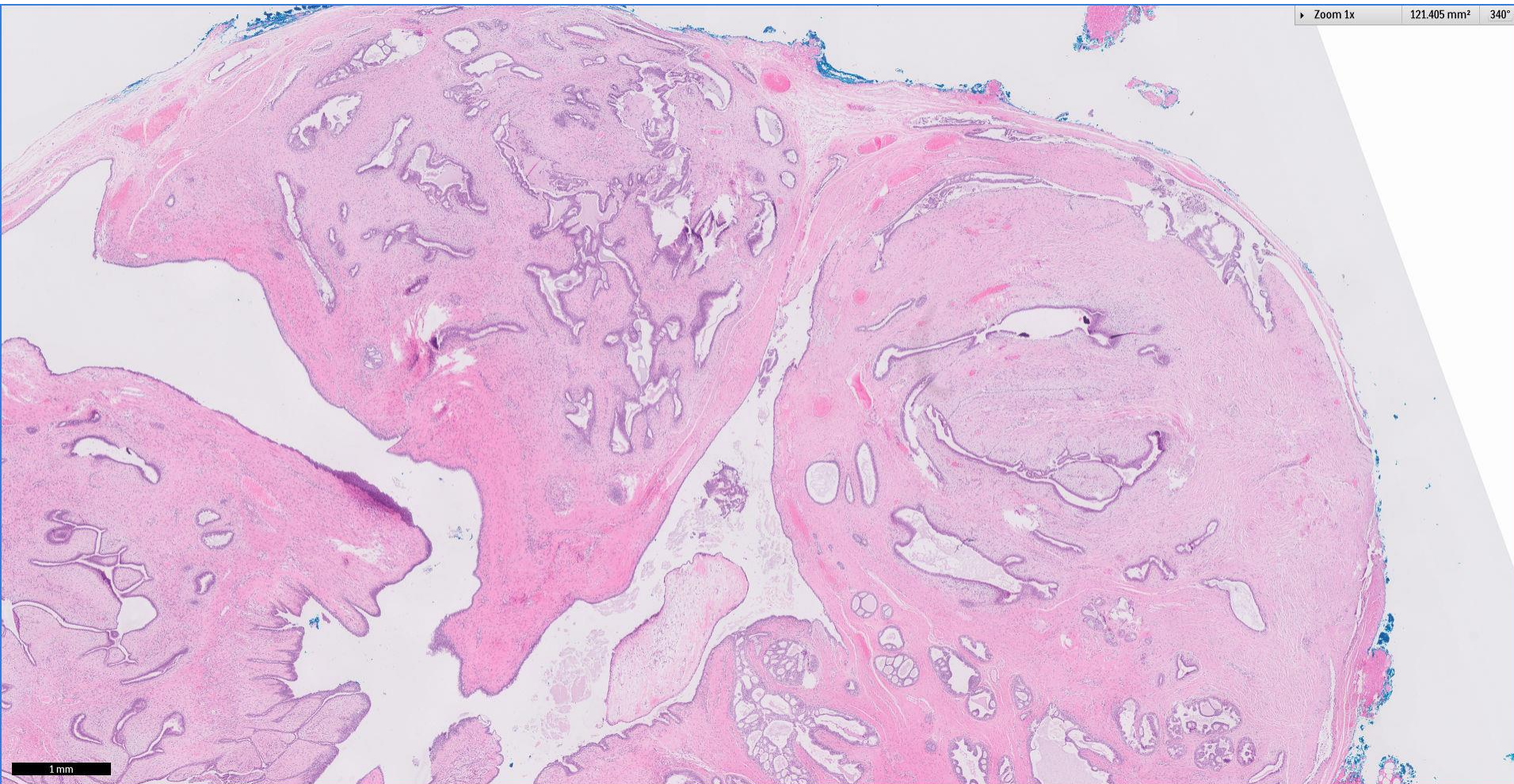
Left breast lumps at 1 o'clock and 5 o'clock.

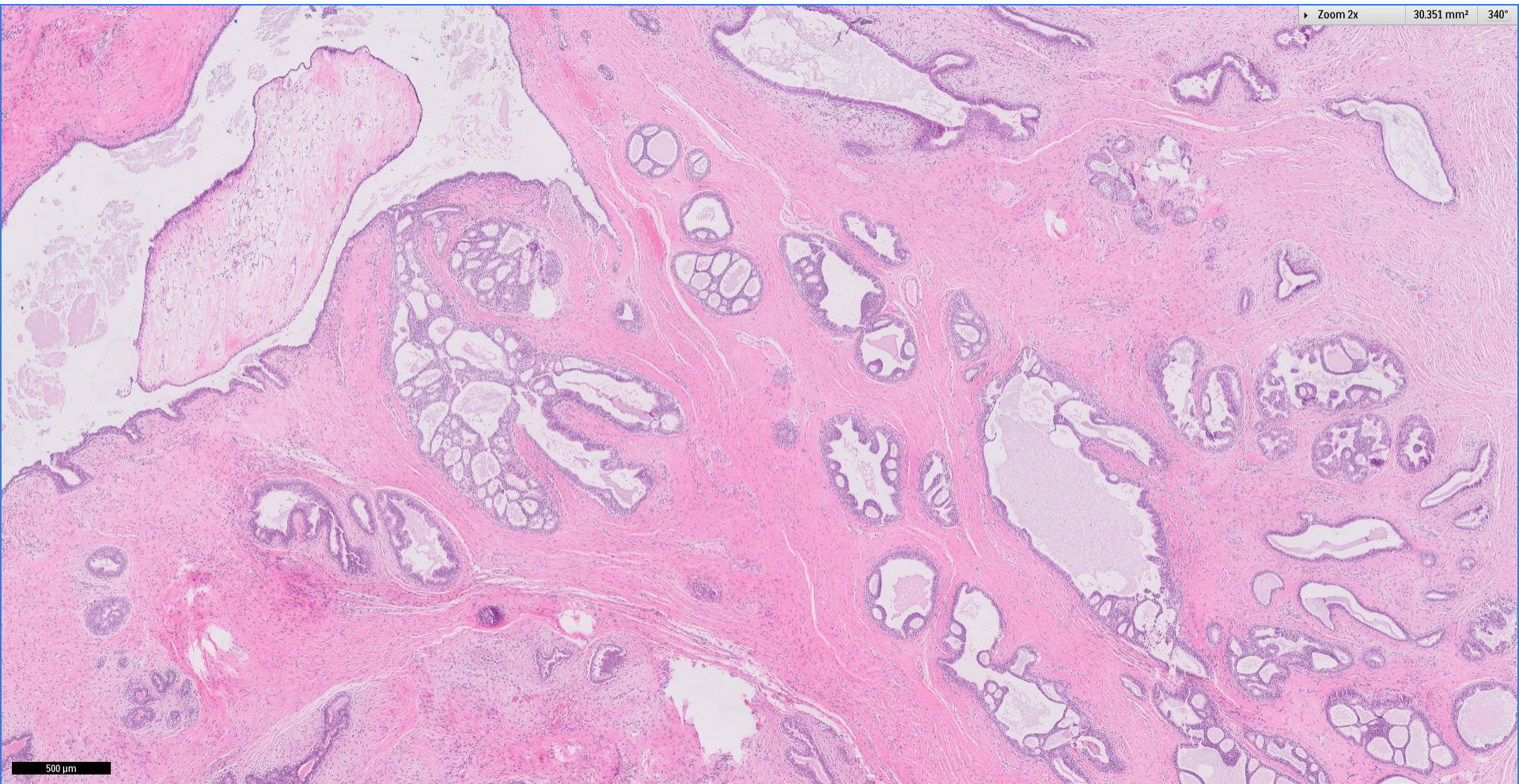
The 1 o'clock breast lump showed a fibroadenoma.

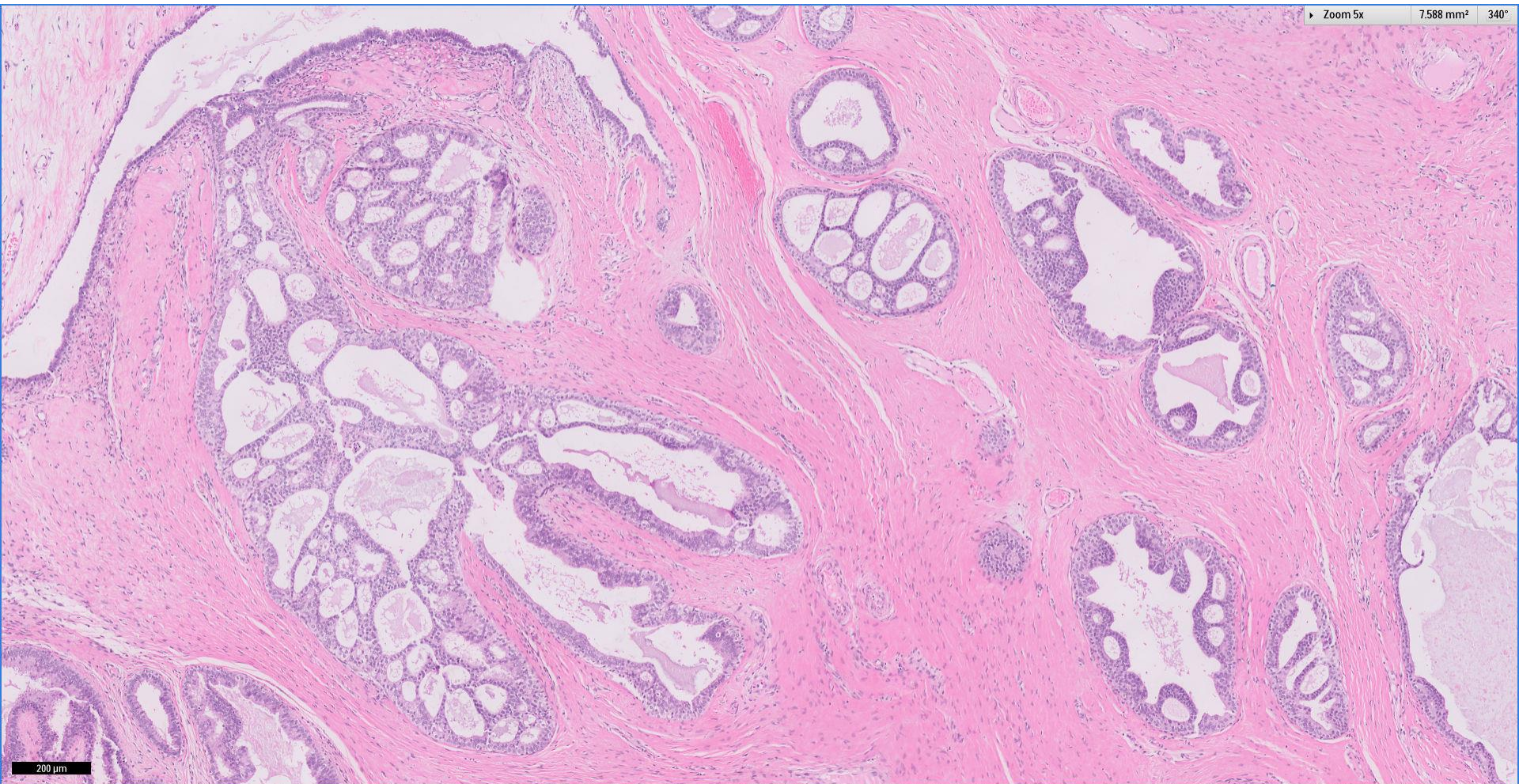
Section provided of the 5 o'clock lump.

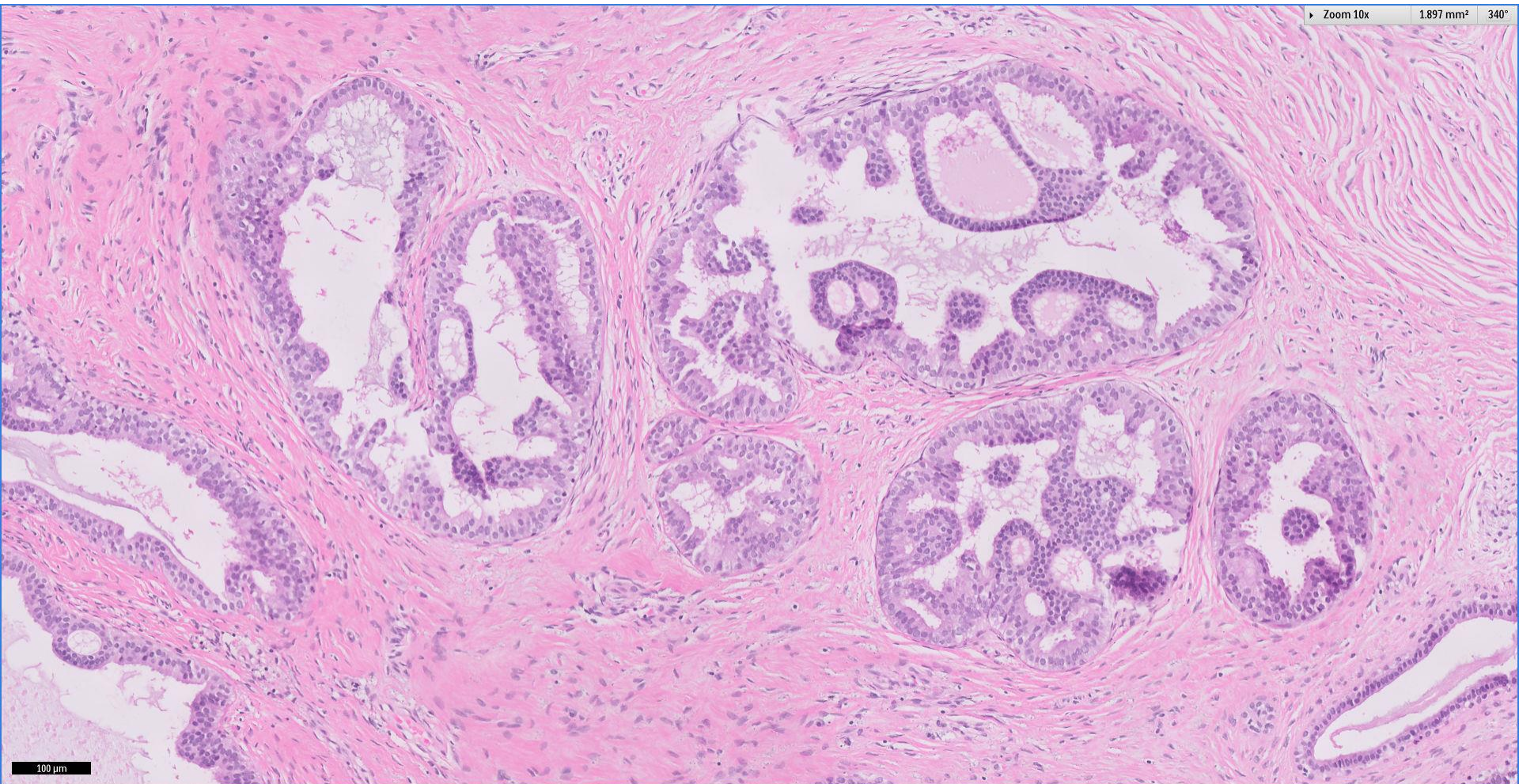












Thank You