

Case 9

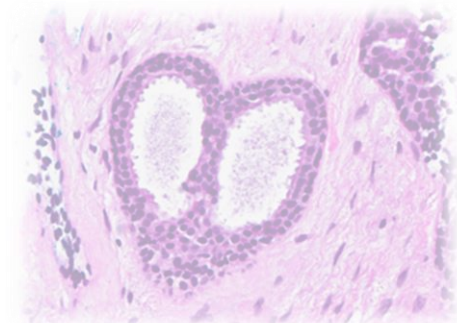
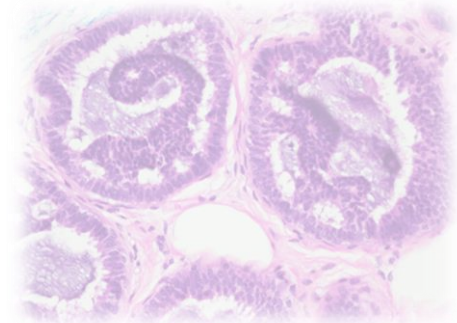
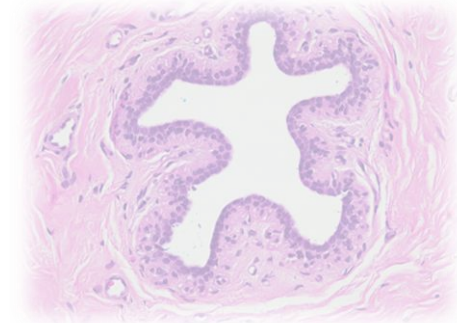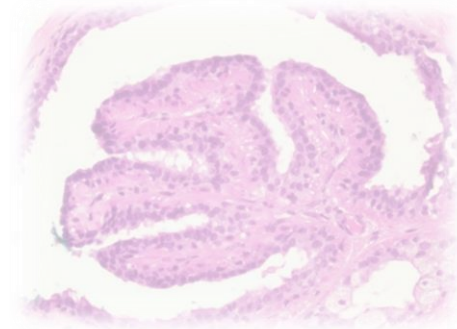
67 year old Thai female.

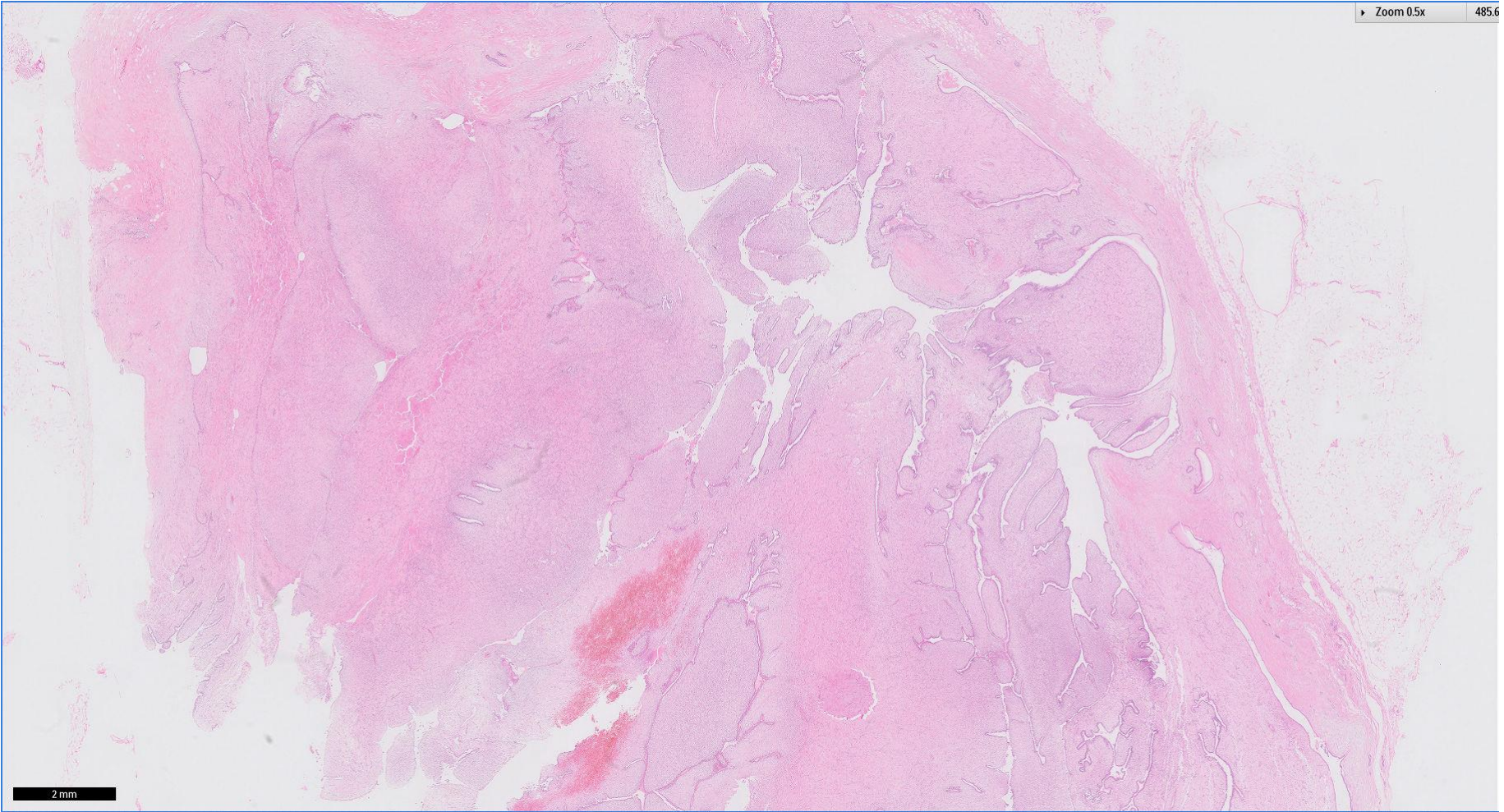
Right breast palpable mass.

Radiology showed an 8.7 x 6.7cm well-defined macrolobulated mass with calcifications at the right breast UOQ, classified as BIRADS 4.

Section provided of the mass.

*Contributed by Dr Kittisak Wongchansom,
Bangkok Thailand*



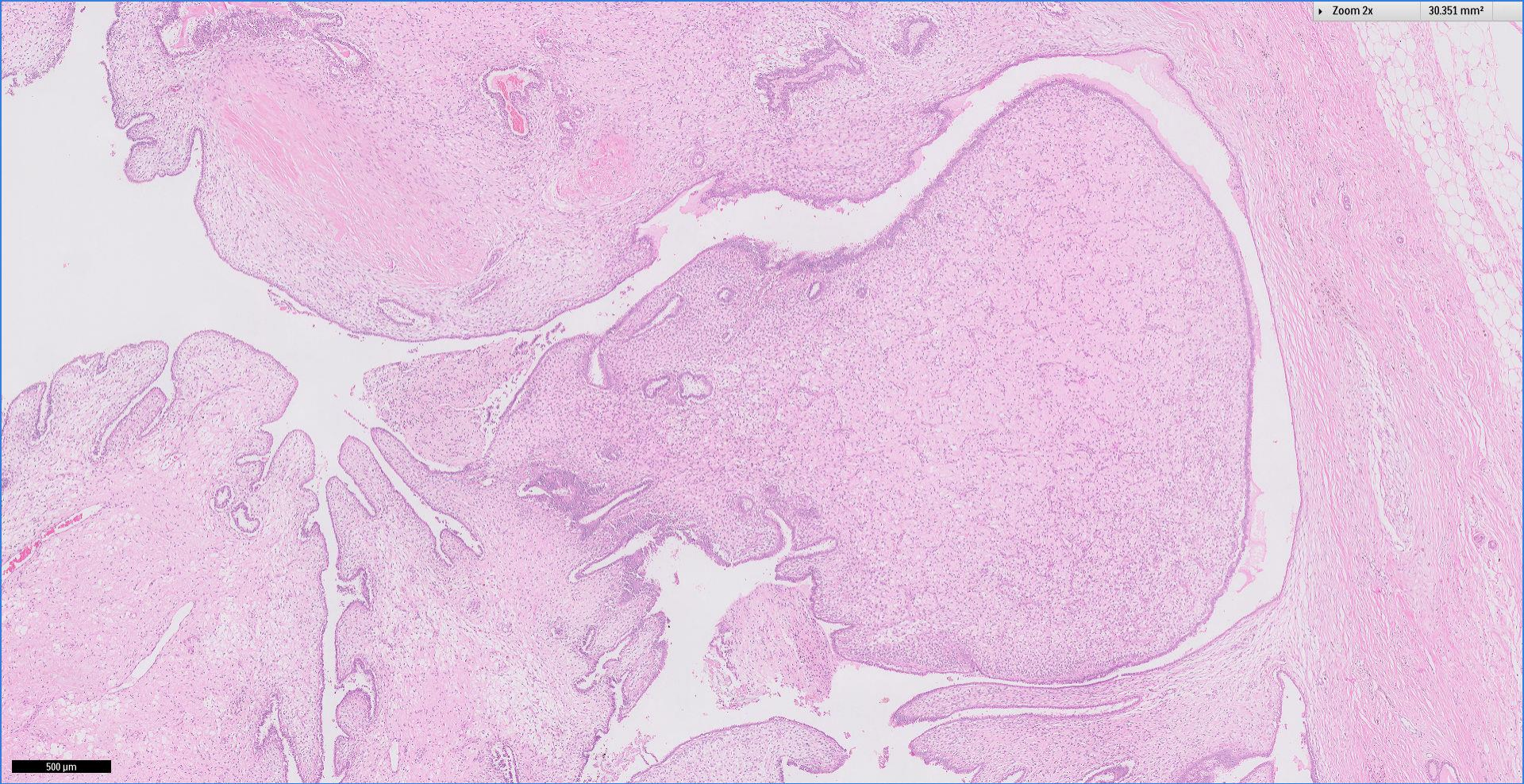


2mm



Division of Pathology
Singapore General Hospital



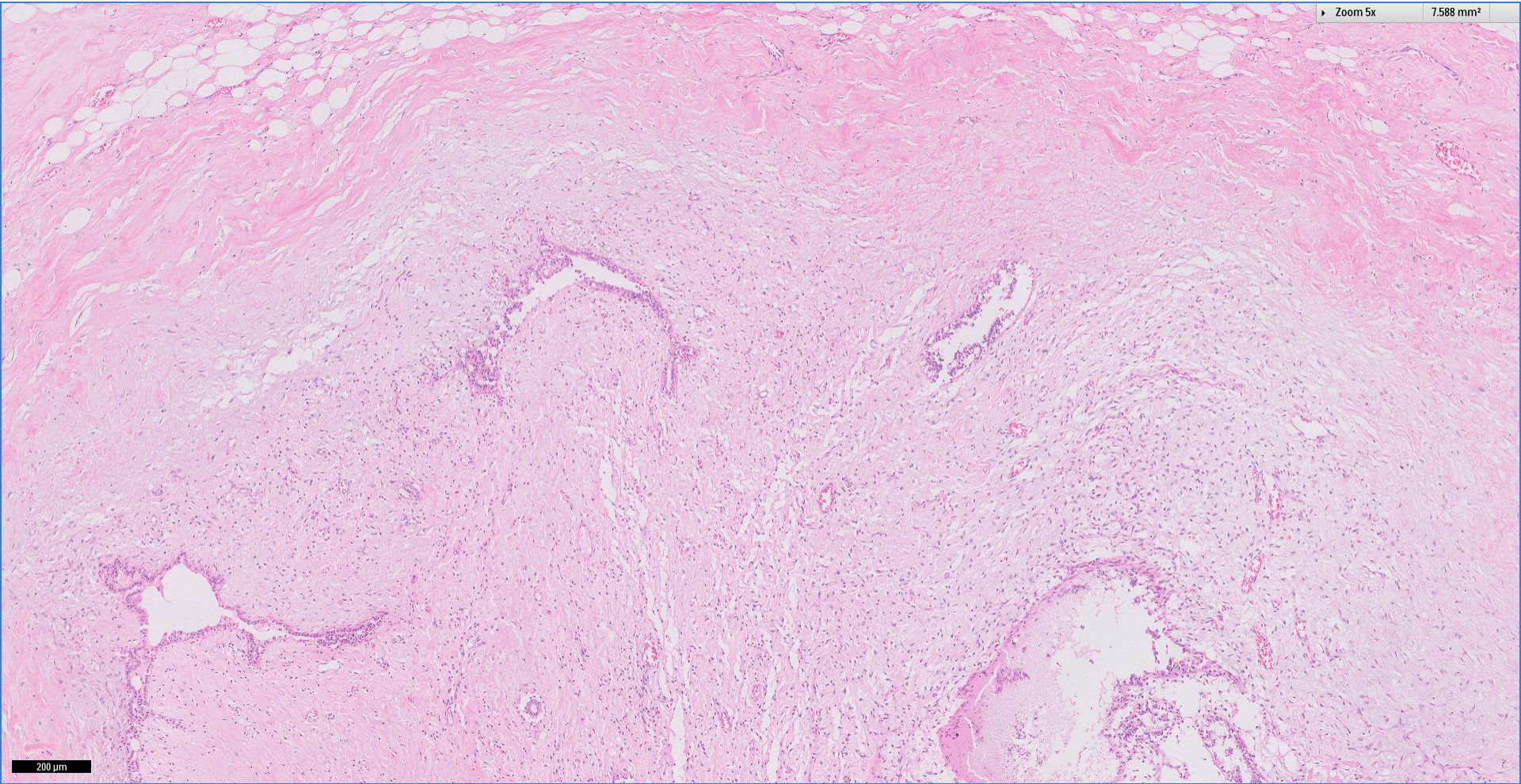


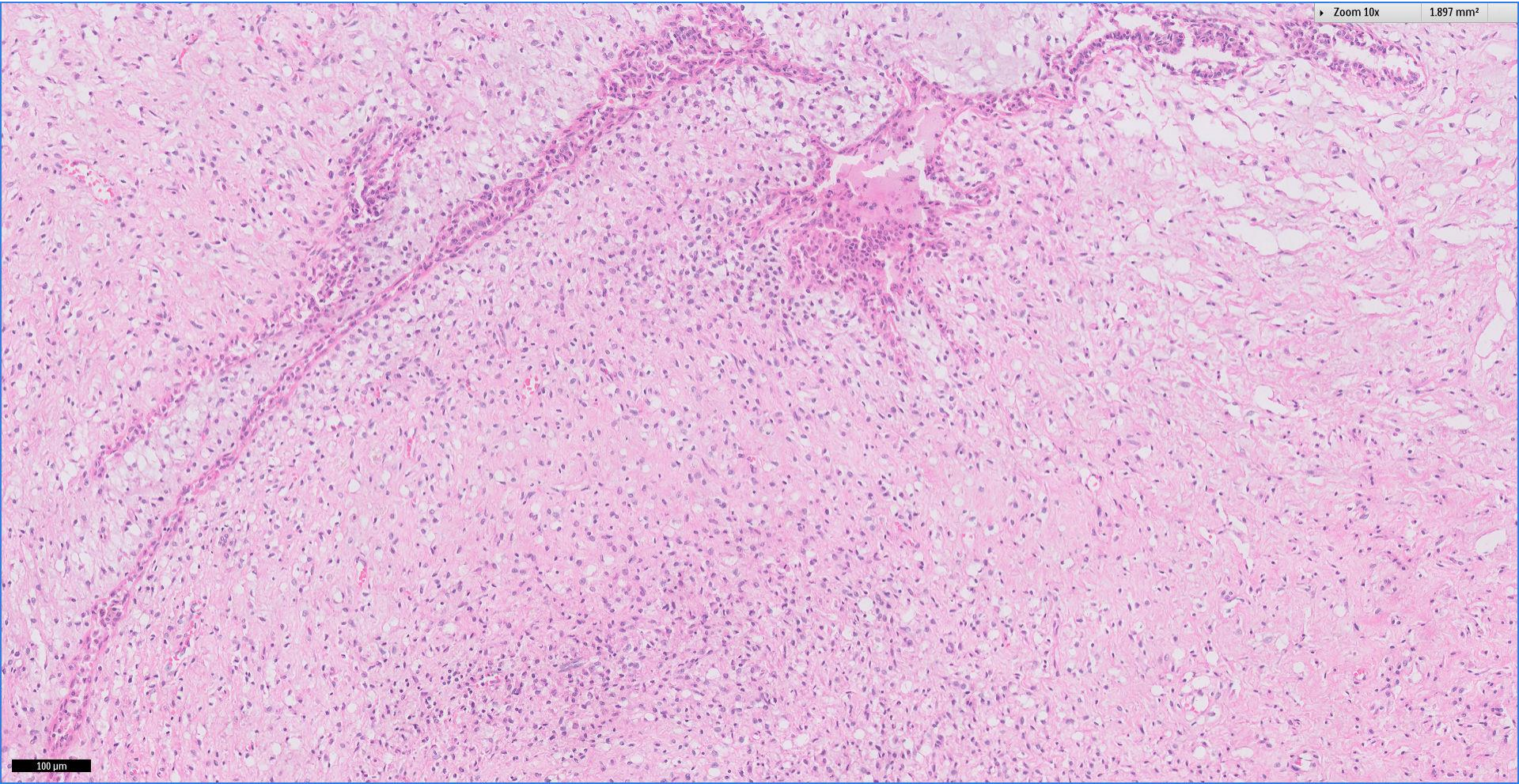
500 μm



Division of Pathology
Singapore General Hospital





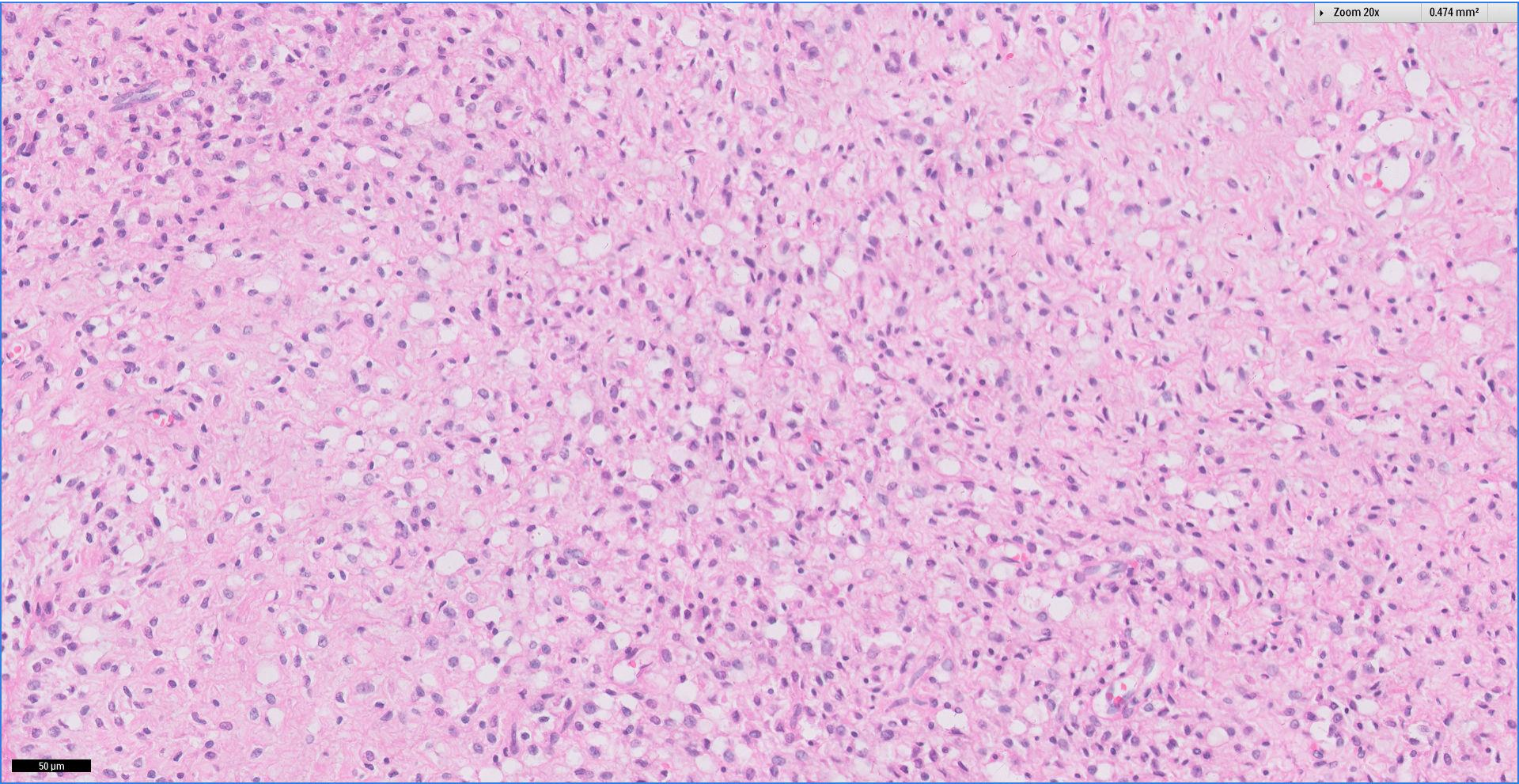


100 µm



Division of Pathology
Singapore General Hospital





50 μm



Division of Pathology
Singapore General Hospital



Thank You