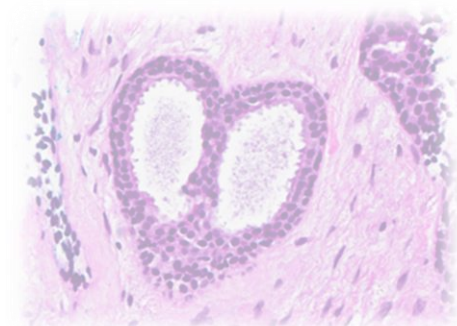
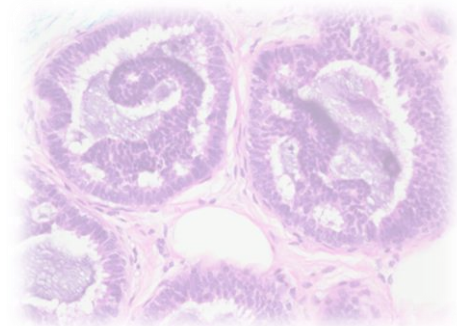
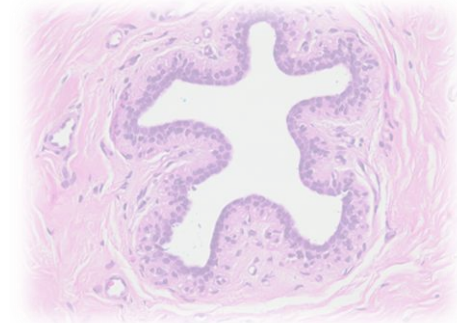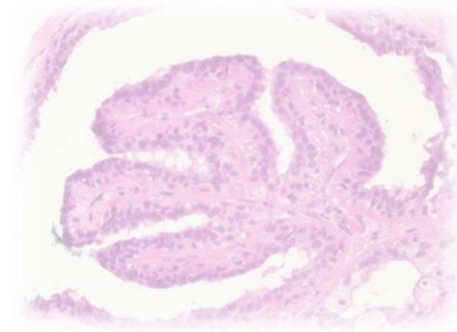
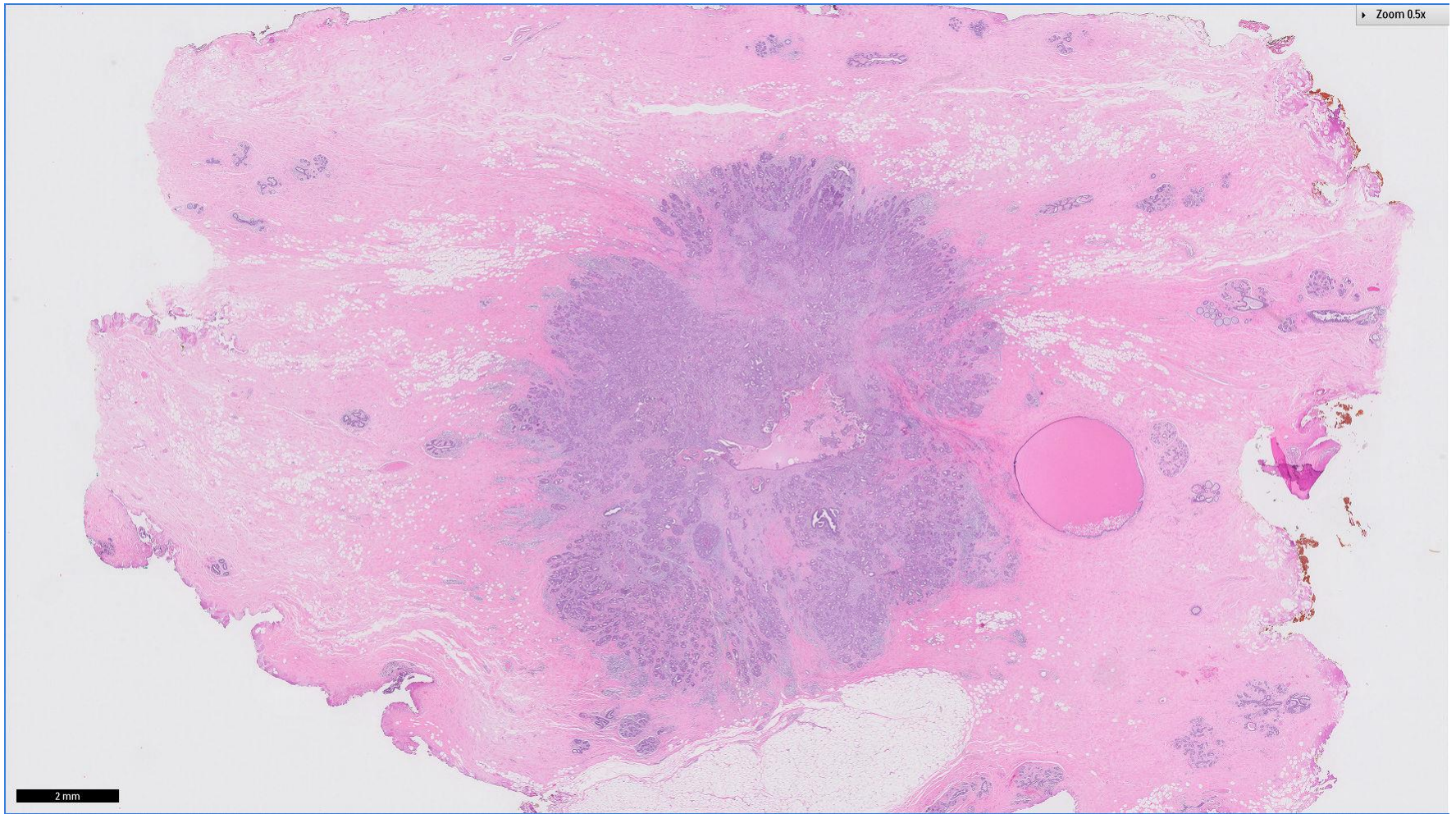


## Case 8

38 year old Chinese female.  
Left breast wide excision.





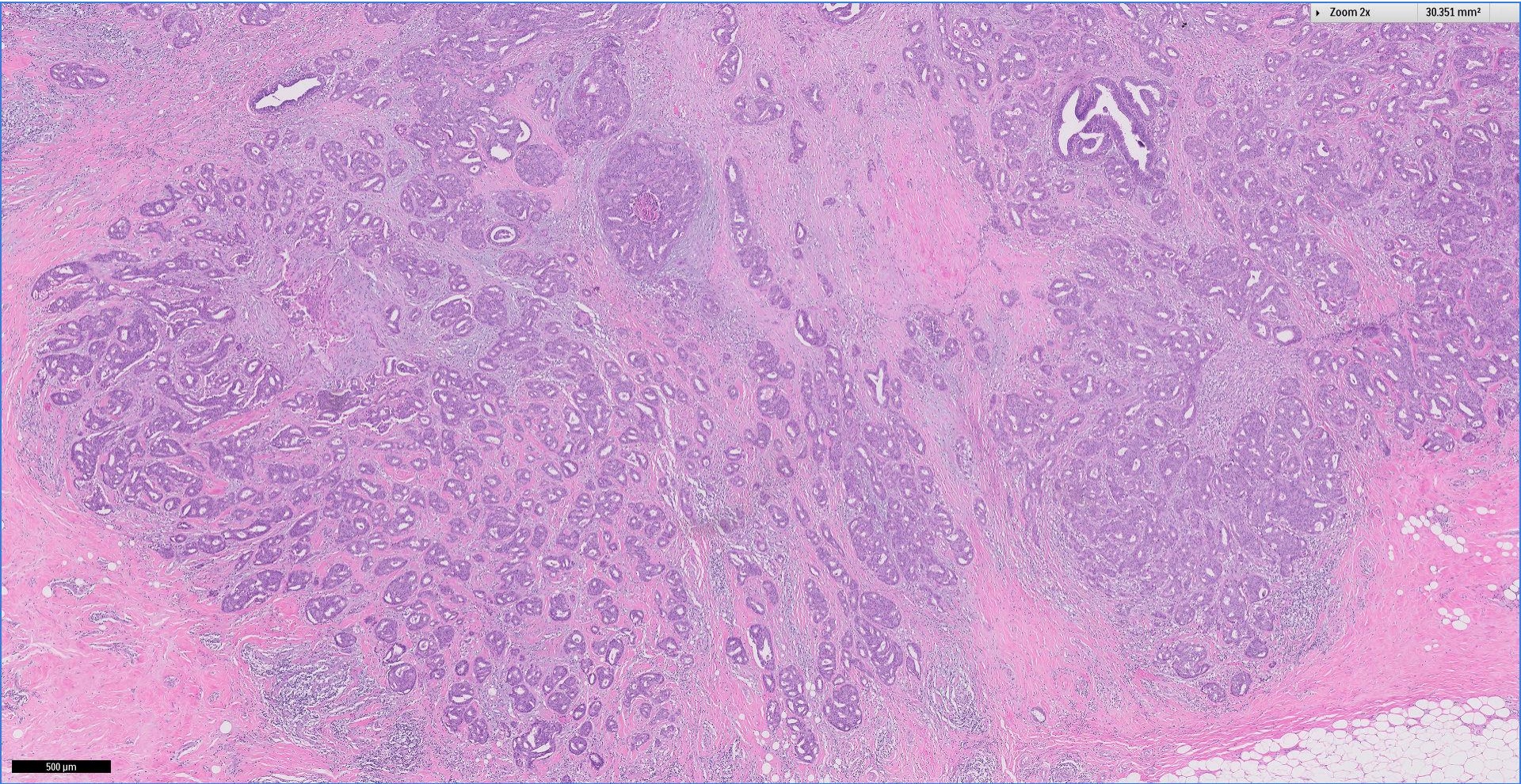
Division of Pathology  
Singapore General Hospital





Zoom 2x

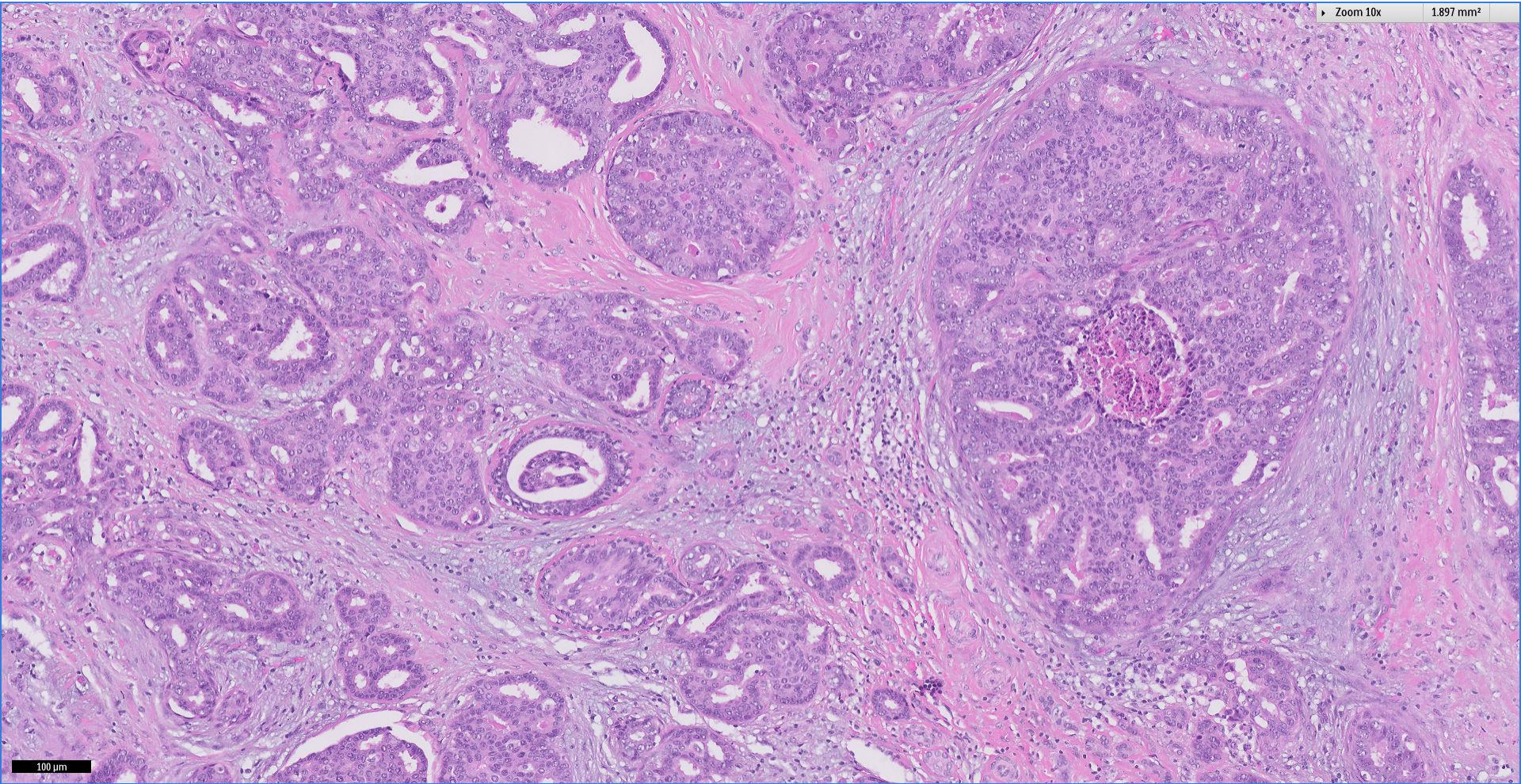
30.351 mm<sup>2</sup>



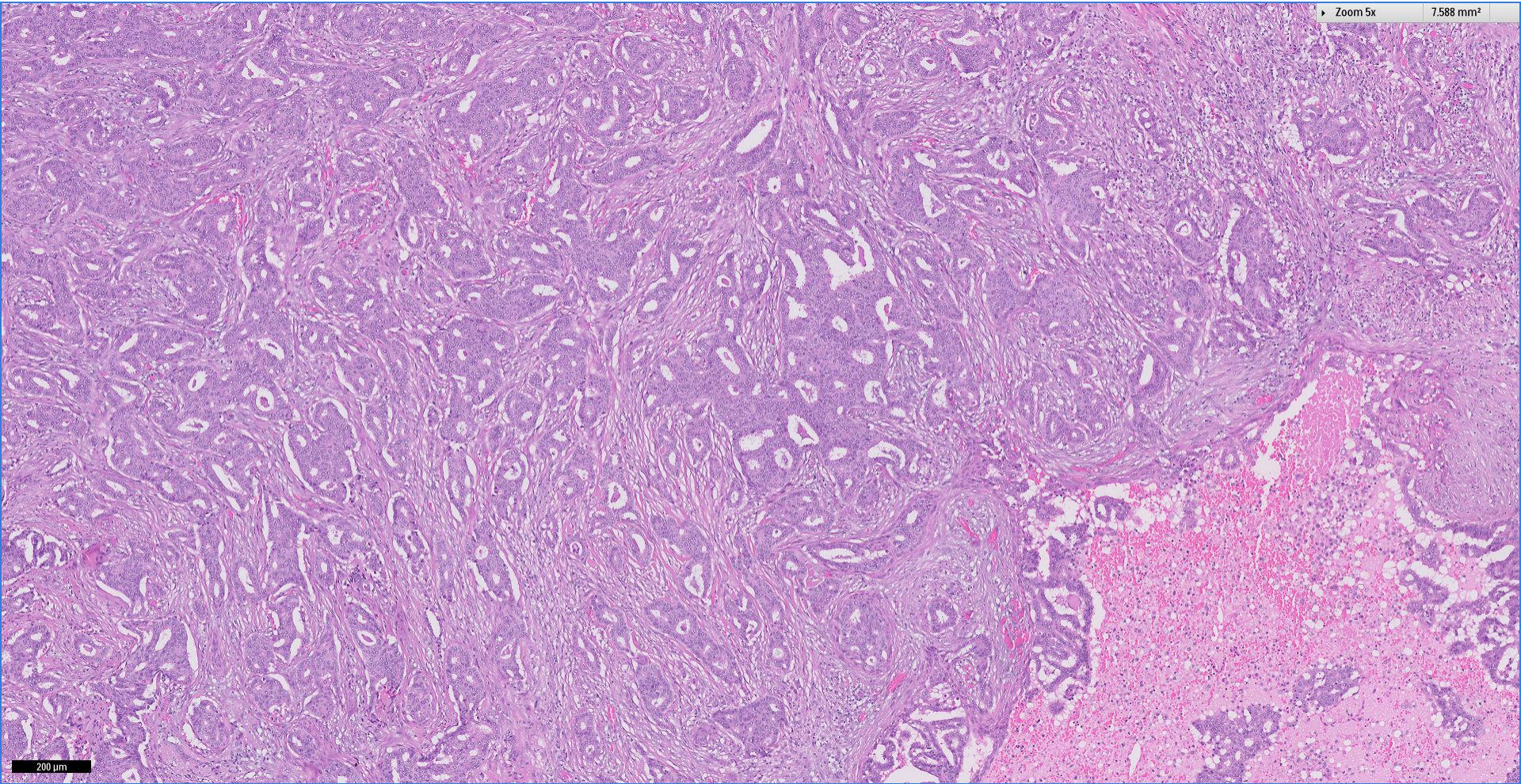
Division of Pathology  
Singapore General Hospital



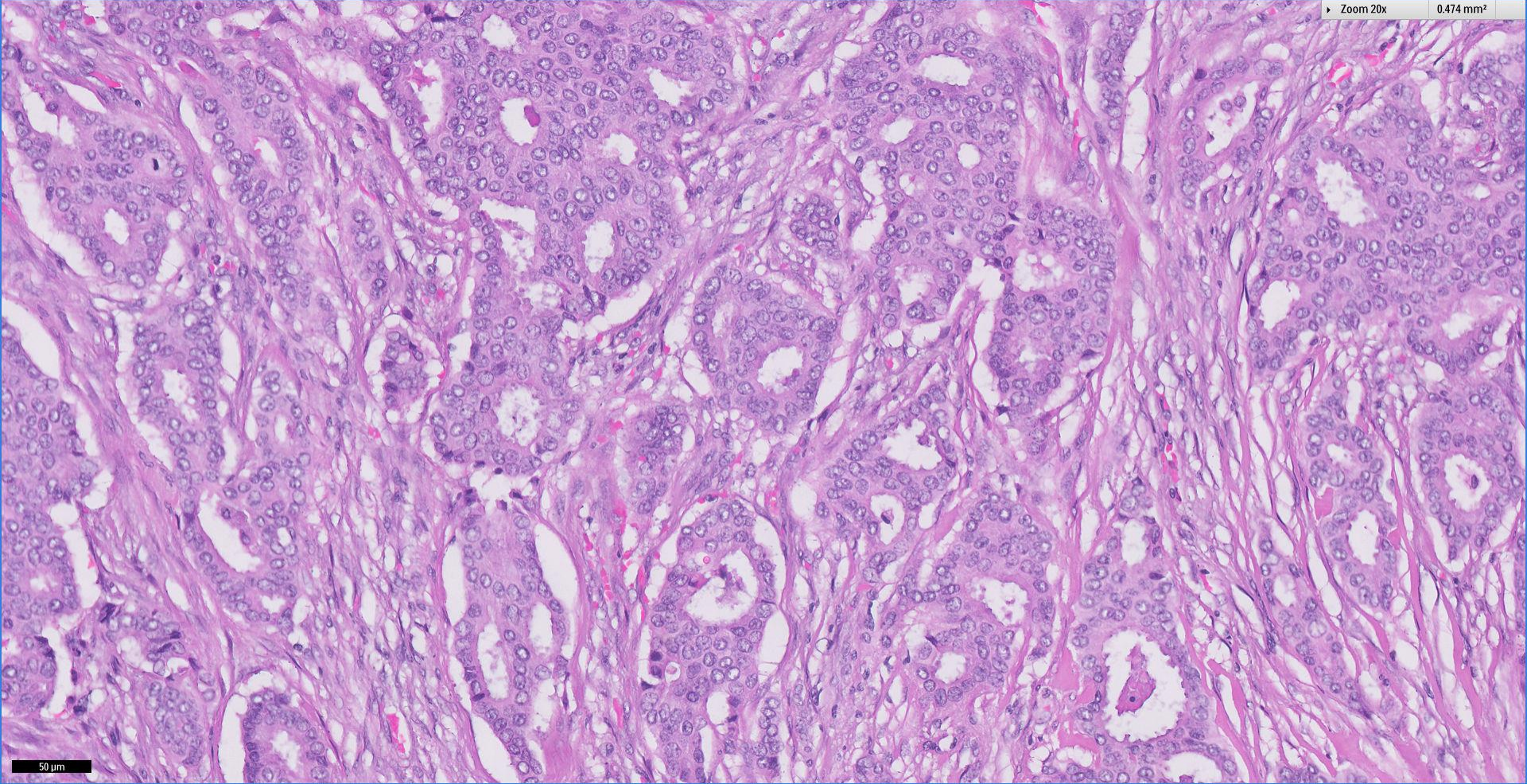












50 µm



Division of Pathology  
Singapore General Hospital





*Thank You*