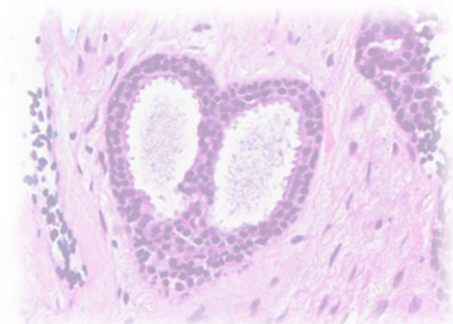
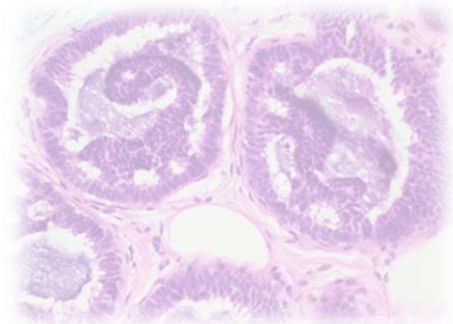
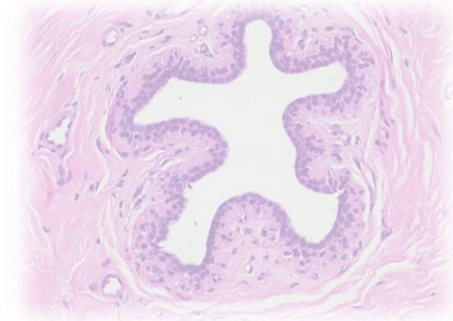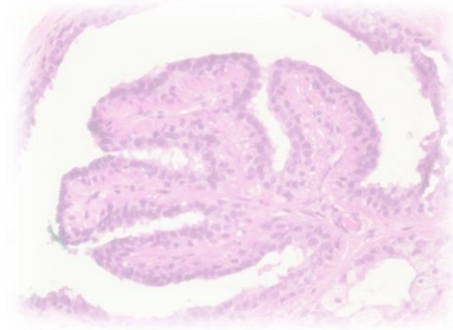
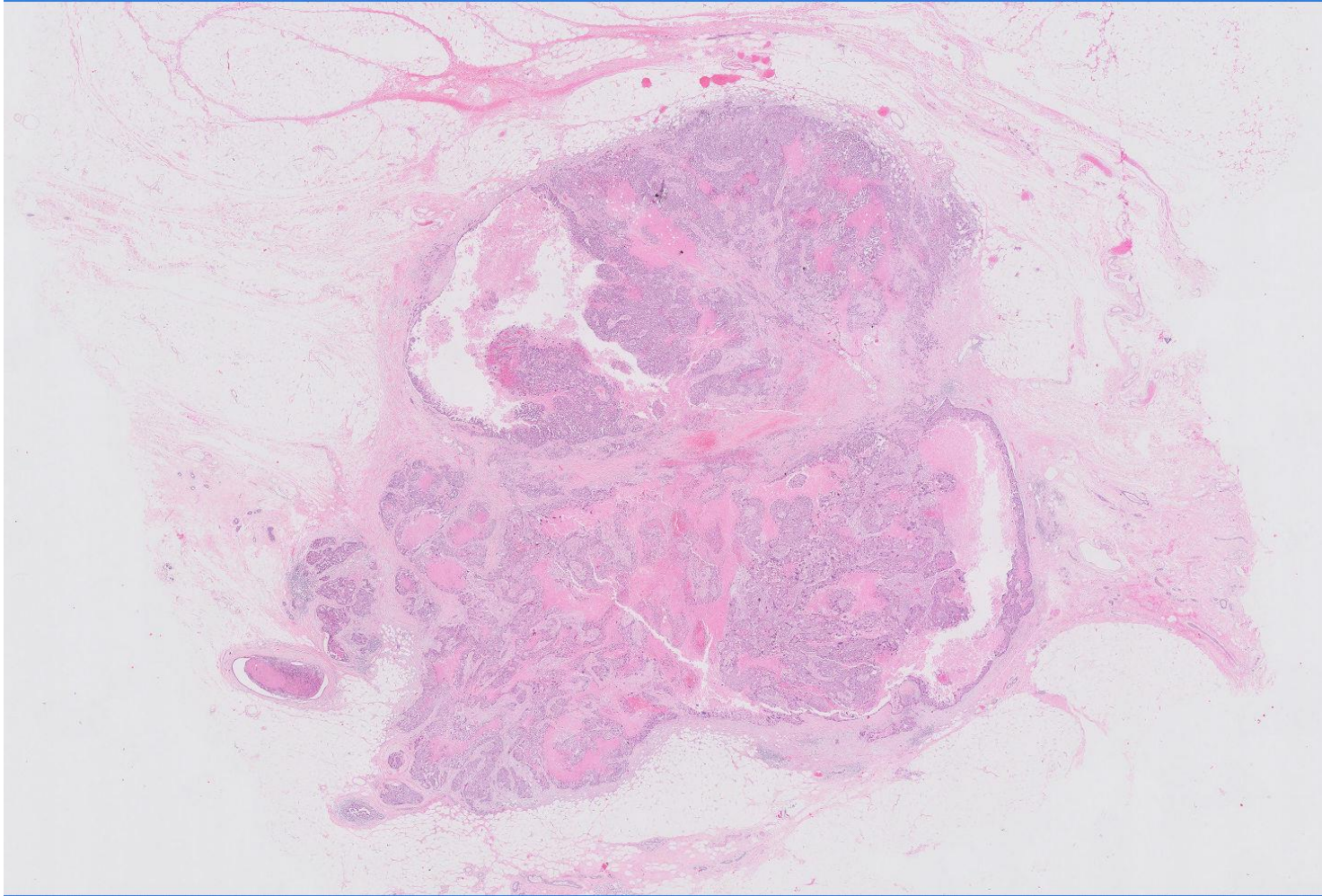
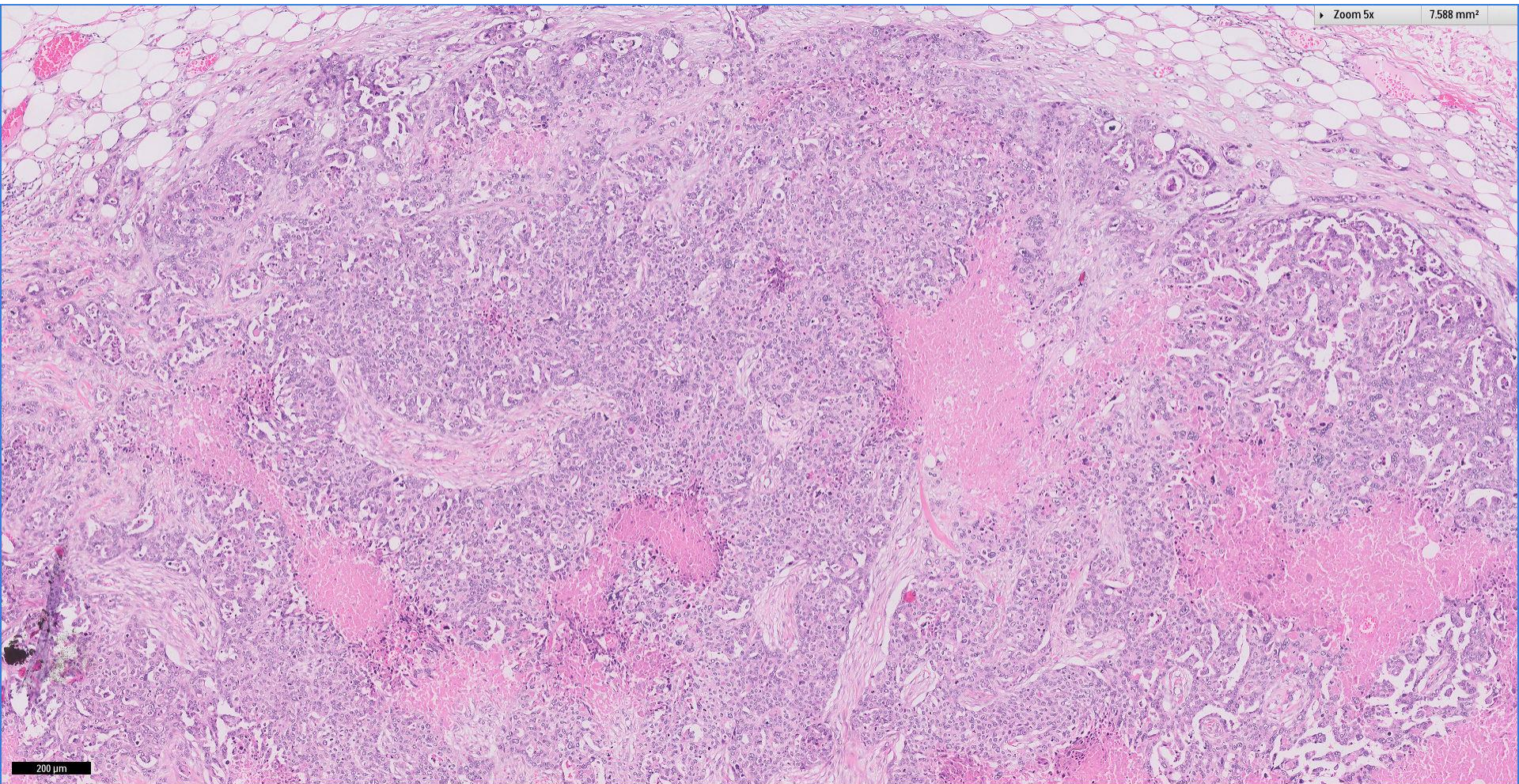


Case 6

75 year old female.
Left breast mastectomy.



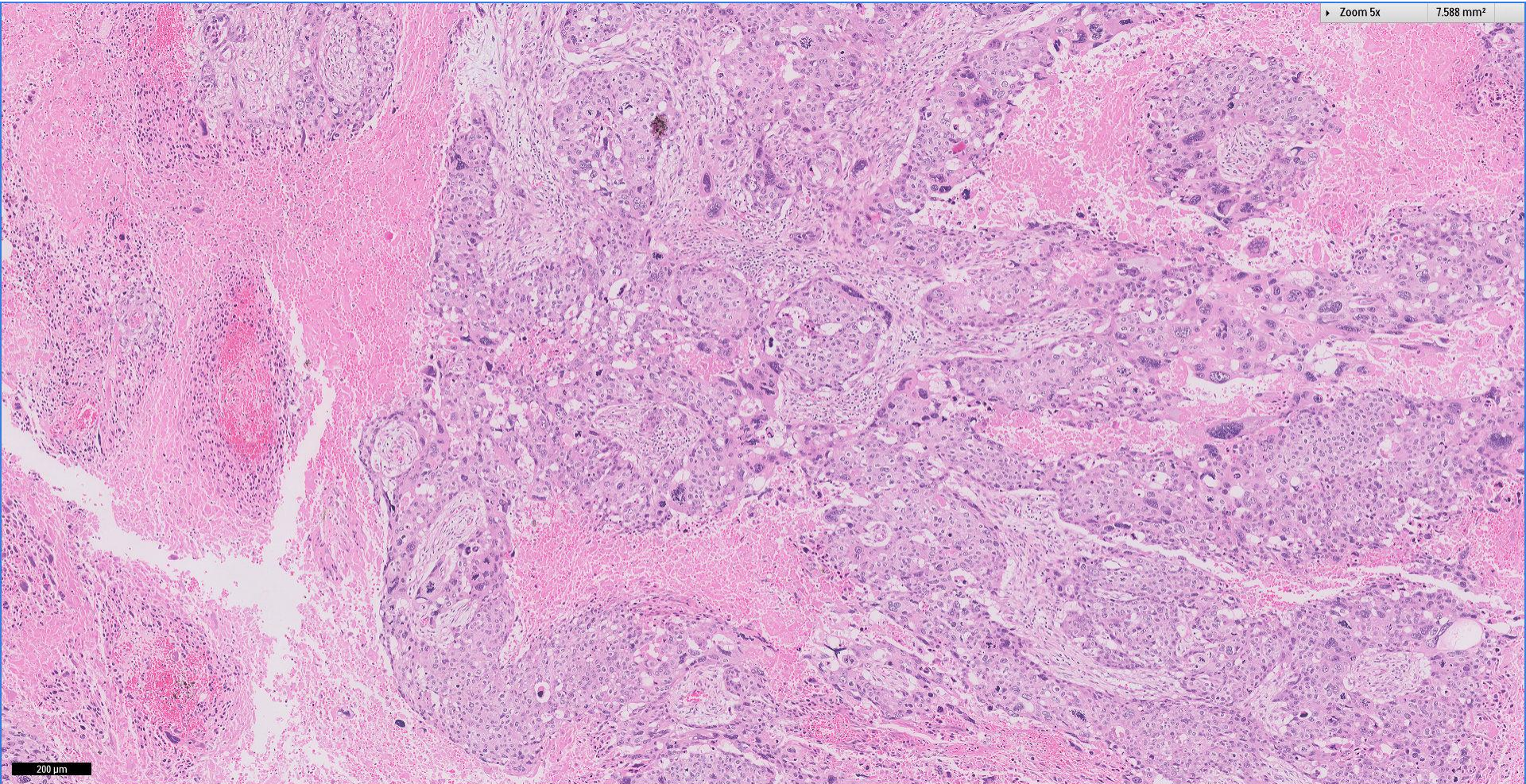


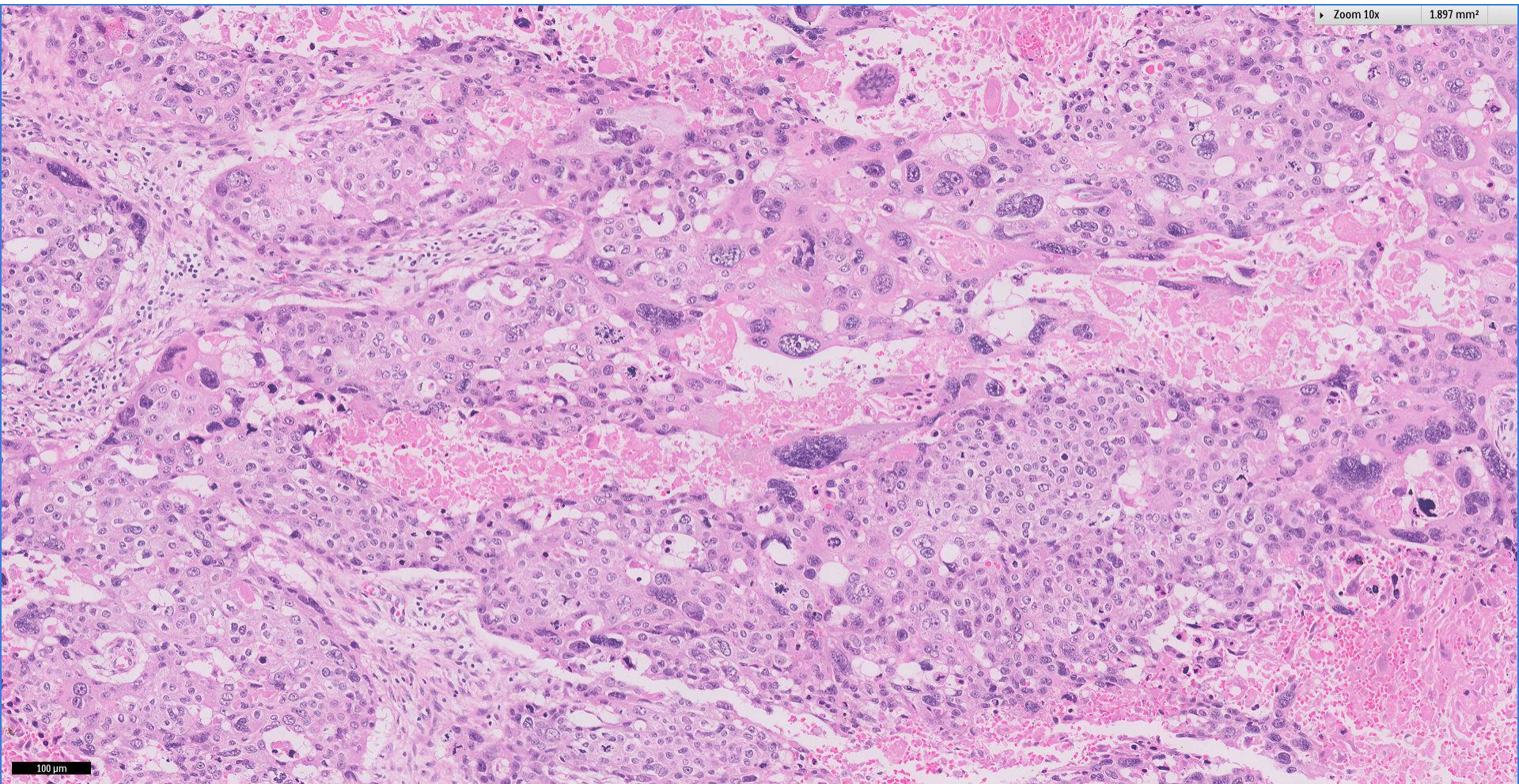


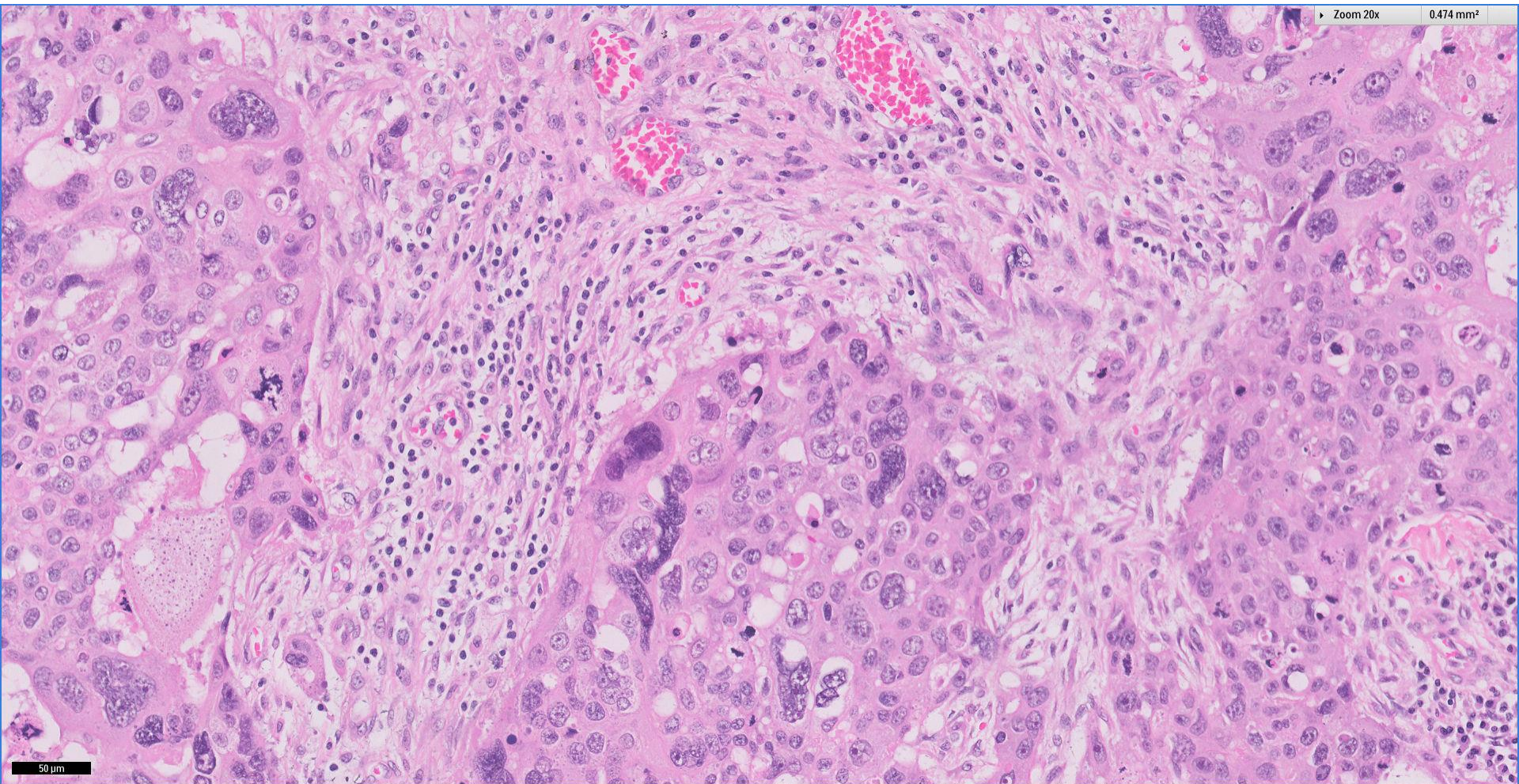
Division of Pathology
Singapore General Hospital



Zoom 5x 7.588 mm²







Thank You