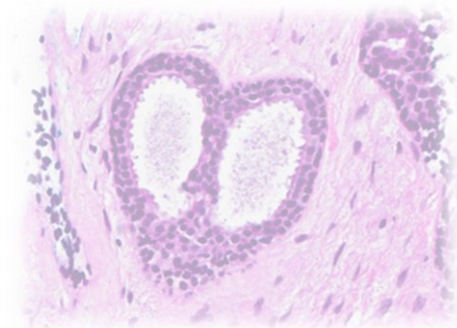
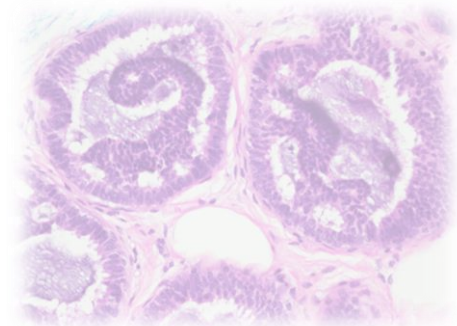
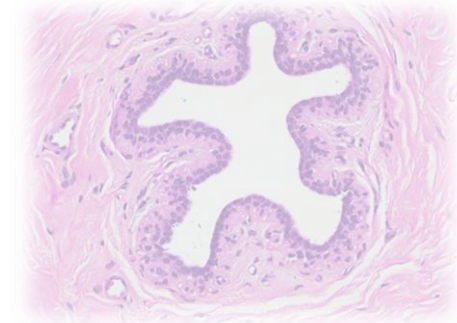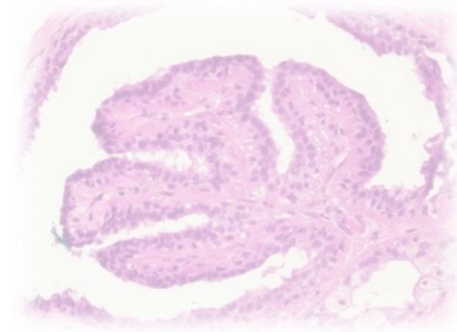
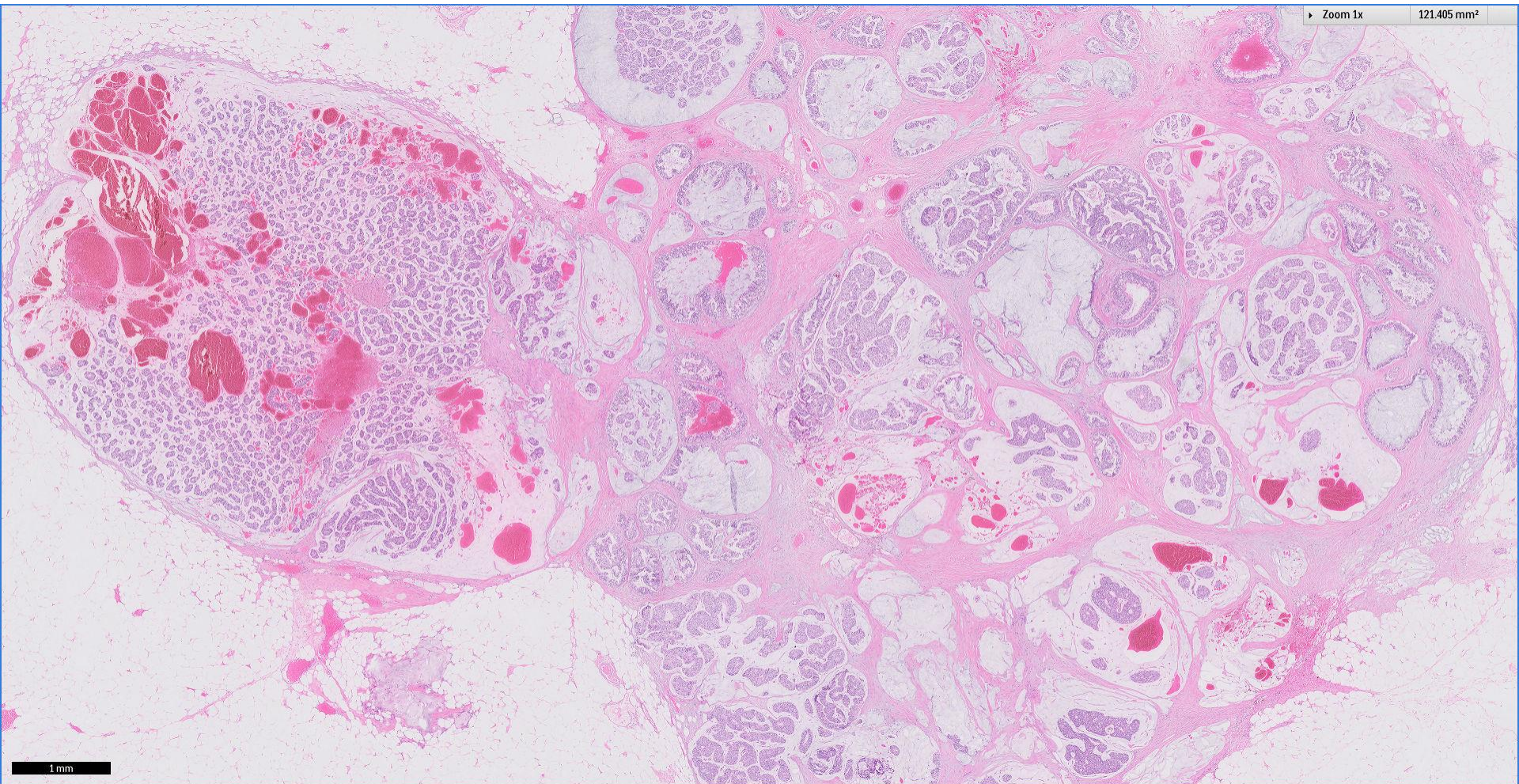


## Case 4

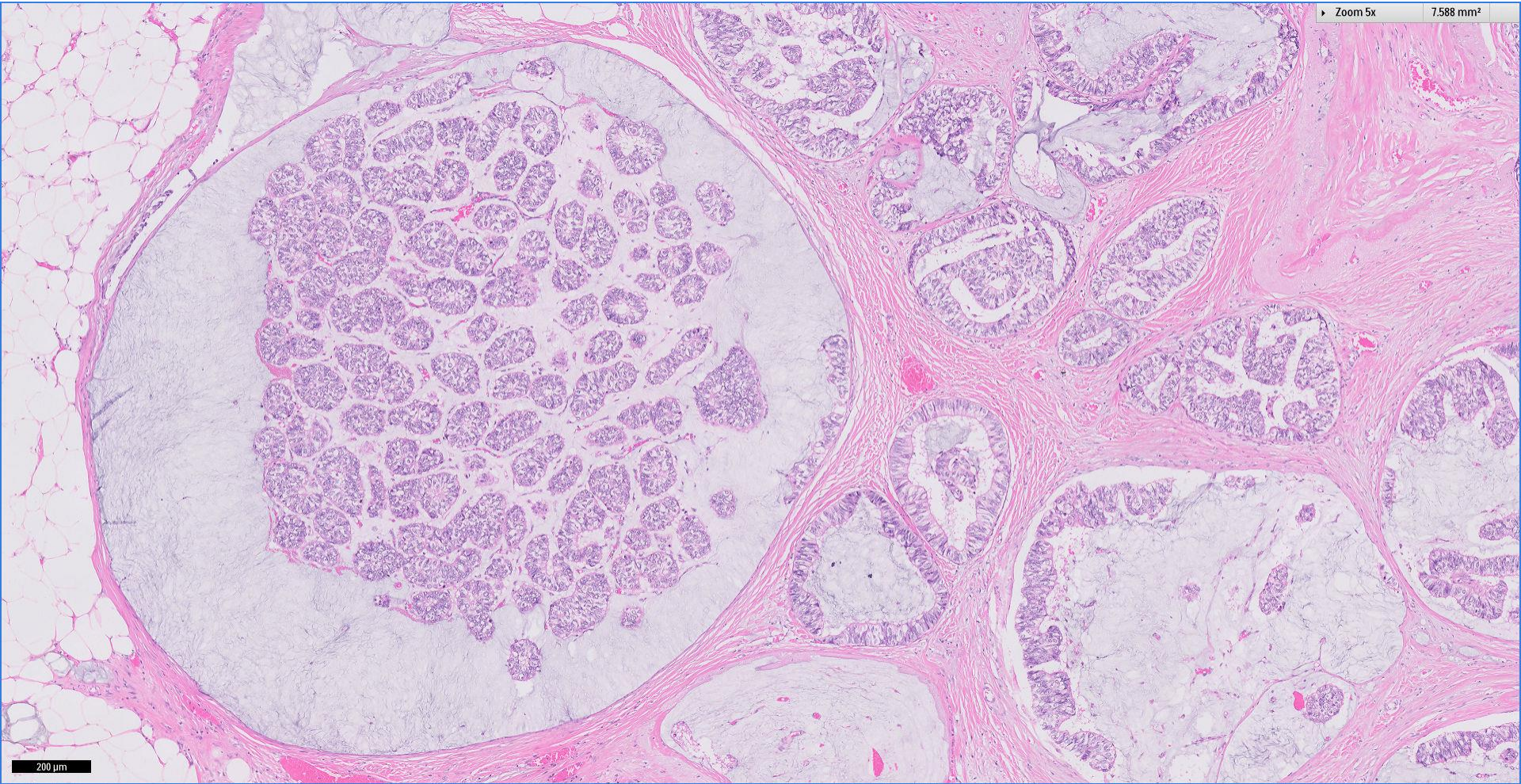
45 year old Chinese female.

Right breast skin sparing mastectomy.



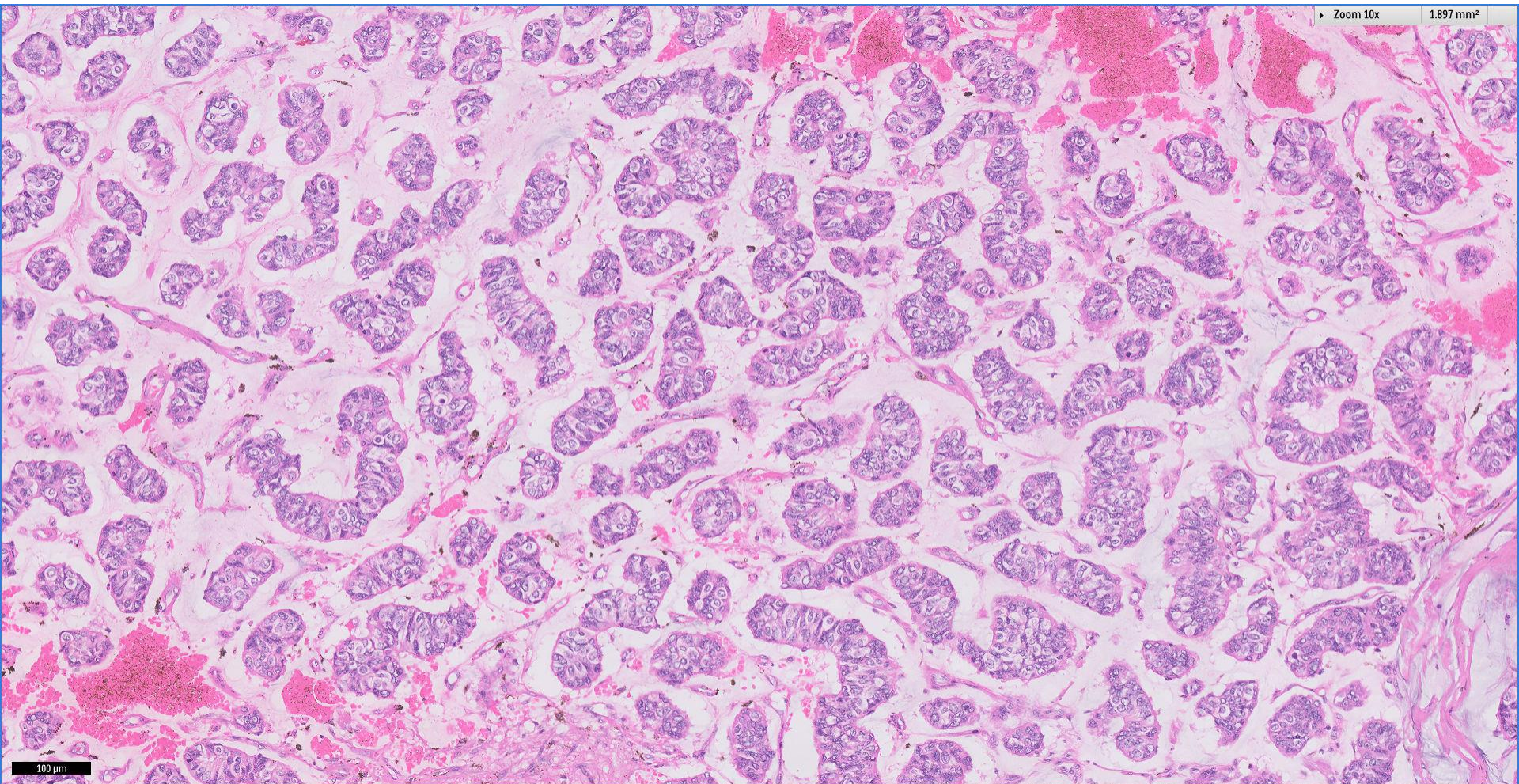


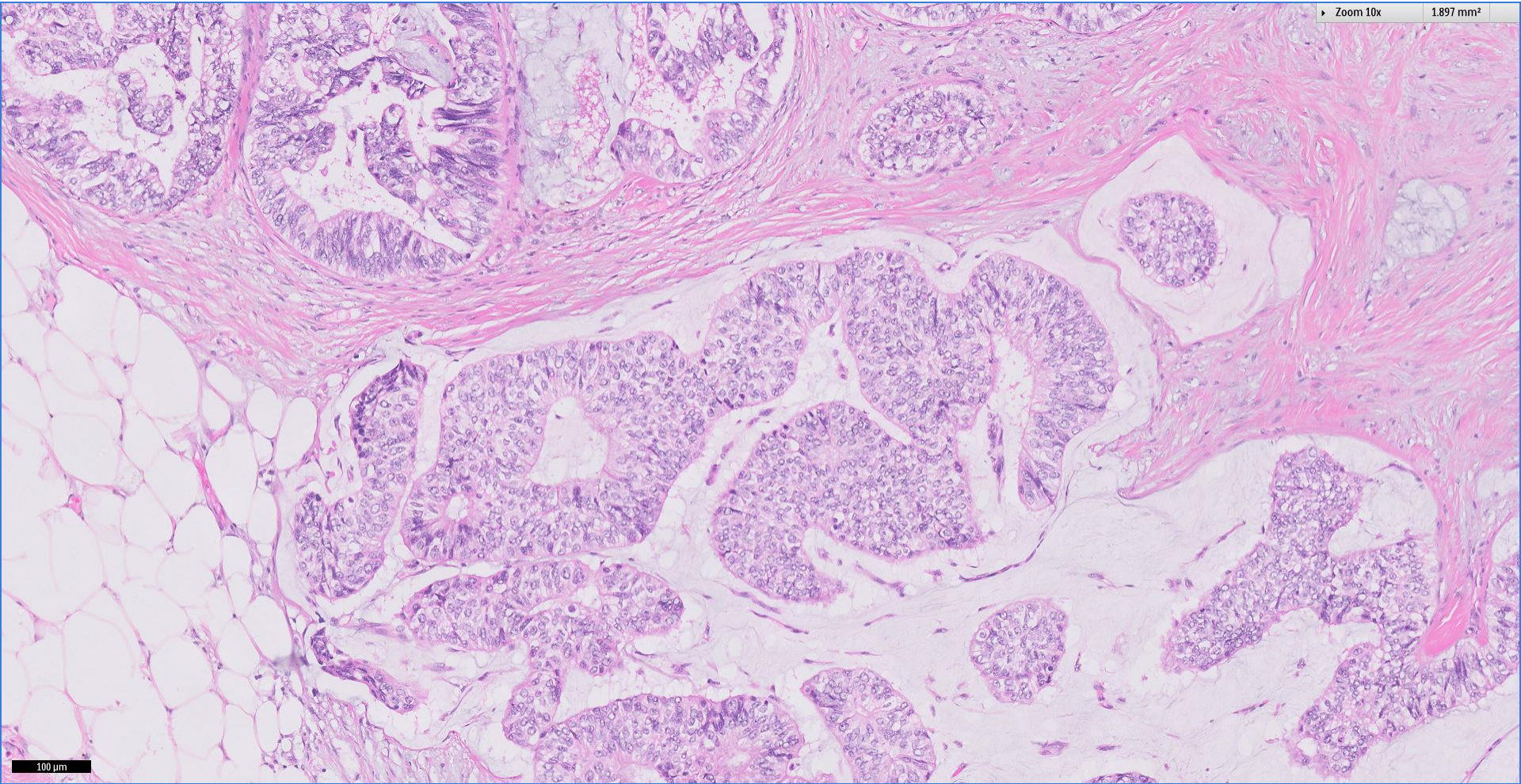
Zoom 5x 7.588 mm<sup>2</sup>

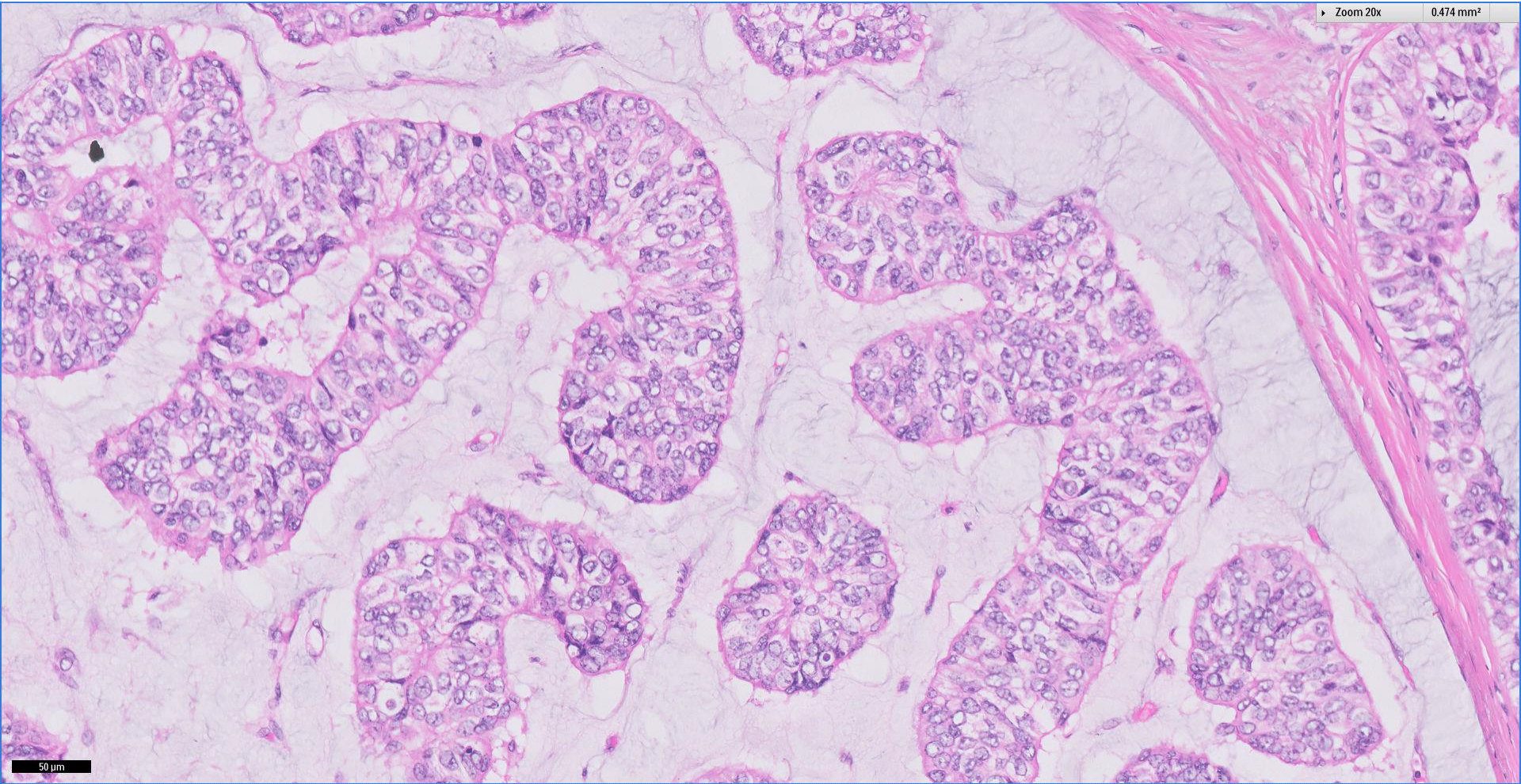


Division of Pathology  
Singapore General Hospital









Division of Pathology  
Singapore General Hospital



*Thank You*